

Chemical disbudding of goat kids with subcutaneous administration of synthetic eugenol: Histopathology and morphometry

Mohammad Farajli Abbasi^{1*}, Mohammad Mahdi Molaei¹, Reza Kheirandish², Ali Mostafavi³

¹ Department of Clinical Sciences, Faculty of Veterinary Medicine, Shahid Bahonar University of Kerman, Kerman, Iran; ² Department of Pathobiology, Faculty of Veterinary Medicine, Shahid Bahonar University of Kerman, Kerman, Iran; ³ Department of Chemistry, Faculty of Science, Shahid Bahonar University of Kerman, Kerman, Iran.

Article Info	Abstract
<p>Article history:</p> <p>Received: 27 September 2017 Accepted: 21 November 2017 Available online: 15 September 2018</p> <p>Key words:</p> <p>Disbudding Goat kid Histopathology Radiology Synthetic eugenol</p>	<p>This study was conducted to evaluate the effect of subcutaneous administration of synthetic eugenol (EG) for disbudding of goat kids, as a new chemical method. Thirty apparently healthy Raieni (Cashmere) goat kids (five-day-old) were divided randomly into six groups (n = 5). In the pathology (P) groups (P₃, P₈ and P₆₀ according to the sample collection day after injection) an amount of 0.10 mL of EG was subcutaneously administrated in both horn buds. In the disbudding 1 and 2 (DB₁, DB₂) groups, 0.10 mL of EG, and in the control (C) group 0.10 mL normal saline was subcutaneously injected in the right horn buds, respectively. Eugenol injection in DB₂ group was done in twelve-day-old goat kids. The left horn buds of DB₁, DB₂ and C groups were considered as control of horn outgrowing. The horn buds, kidneys, liver, lung, brain and heart, tissue specimens were collected from P₃ and P₈ groups, and bud skin samples were collected from P₆₀ group. The results showed that the EG was able to stop the horn growth in the first week of goat life. There was no significant difference between left and right horn size in the C group. Histopathological study revealed complete necrosis of bud tissue in dermal and epidermal layers, in P₃ animals. Healing and re-epithelialization were seen in the samples taken from P₈ group. Subcutaneous injection of the synthetic EG can be considered as a new method for goat kids disbudding.</p> <p style="text-align: right;">© 2018 Urmia University. All rights reserved.</p>

جوانه‌زدایی بزغاله به روش شیمیایی به وسیله تزریق زیر جلدی اوژنول صنعتی: بررسی هیستوپاتولوژی و مورفومتری

چکیده

هدف از این مطالعه بررسی تأثیر تزریق زیر جلدی اوژنول صنعتی خالص بر جوانه‌زدایی شاخ بزغاله‌ها به‌عنوان یک روش شیمیایی بود. در این مطالعه از ۳۰ رأس بزغاله رایینی (کشمیر) در شش گروه استفاده شد (n=5). در گروه‌های پاتولوژی (P) شامل گروه‌های P₃، P₈ و P₆₀ (بر اساس زمان اخذ نمونه باقی بعد تزریق) مقدار ۰/۱۰ میلی‌لیتر اوژنول در جوانه‌شاخی هر دو سمت تزریق شد. در گروه جوانه‌زدایی ۱ (DB₁) و جوانه‌زدایی ۲ (DB₂) مقدار ۰/۱۰ میلی‌لیتر اوژنول و در گروه کنترل (C) ۰/۱ میلی‌لیتر نرمالین سالین در جوانه‌شاخی سمت راست، به‌دقت و به‌صورت زیر جلدی تزریق شد. در گروه DB₂ تزریق در بزغاله‌های ۱۲ روزه انجام شد. جوانه‌های شاخی چپ در گروه‌های DB₁، DB₂ و C جهت اطمینان از شاخدار بودن بزغاله دست نخورده باقی ماندند. نمونه‌های پاتولوژی از بافت جوانه‌شاخی، کلیه‌ها، کبد، ریه، مغز و قلب از گروه‌های P₃ و P₈ تهیه شد و از گروه P₆₀ تنها نمونه پوستی جوانه‌شاخی اخذ گردید. نتایج مطالعه، تأثیر جوانه‌زدایی و توقف رشد شاخ به وسیله اوژنول در هفته اول زندگی بزغاله‌ها را تأیید کردند. هیچ تفاوت معنی‌دار در میزان رشد شاخ در بین بزغاله‌های گروه C دیده نشد. در بررسی هیستوپاتولوژیک نمونه‌های بافت جوانه شاخی P₃، نکروز در لایه‌های اپیدرم و درم مشاهده شد. روند التیام و تشکیل لایه اپیتلیومی جدید در نمونه‌های P₈ مشهود بود. براساس این مطالعه تزریق زیر جلدی اوژنول را میتوان به‌عنوان یک روش نوین شیمیایی برای جوانه‌زدایی در بزغاله‌ها به کار گرفت.

واژه های کلیدی: اوژنول صنعتی، بزغاله، جوانه‌زدایی، رادیولوژی، هیستوپاتولوژی

*Correspondence:

Mohammad Farajli Abbasi. DVM, DVSc
Neuro Science Research Center, Kerman University of Medical Sciences, Kerman, Iran.
E-mail: mohammad.f.abbasi@vet.uk.ac.ir



This work is licensed under a Creative Commons Attribution-NonCommercial 4.0 International License which allows users to read, copy, distribute and make derivative works for non-commercial purposes from the material, as long as the author of the original work is cited properly.

Introduction

Horns grow out from horn bud of frontal bone origin in the domestic animals. In wild species of animals such as deer, horn growth has a high rate, and it is annually, but in domestic animals, the horn growth continues from birth to death. In domestic animals, horn base diameter increases during animal aging. Anatomically, horns of sheep and goats grow almost behind the eyes and in the lateral position. In animal species, a separate bone center is responsible for the production of different parts of the horn. In the goat kids, the attachment of the horn to the skull bone and the opening of the frontal sinuses to the middle hole of the horn will be completed later, but the sinus do not move until the end of the horn.¹ Because of horns uselessness in domestic animals contrary to the wild species which they can be used as a weapon, disbudding and dehorning domestic animals have long been considered by breeders and clinicians.^{2,3} The inclination to fight with each other, hurt the people or destroy the farm facilities are more conceivable behaviors in the horned animals.^{3,4}

Various techniques are used for dehorning and disbudding, so they are classified generally into physical and chemical methods. Chemical methods have two types of topical (sodium hydroxide, potassium hydroxide, calcium hydroxide and horn pencil) or injectable agents (calcium chloride). Each disbudding method has its own disadvantages and risks, such as the possibility of damage to lateral structures such as eyes or the frontal bone, therefore, concurrent application of analgesic or anesthetic agents are required. These injuries due to dehorning require medical or surgical treatments.^{3,5} Physical methods include hot iron (internal or external heat source), knife, scissor and tubing. All of physical procedures are very painful and need local or general anesthesia for performing. In addition, there are risks such as bleeding, secondary inflammation, infection, or even death. They are not always economical and peaceful, and need great skill and precision to prevent possible damage to technician or contractors. The possibility of the horn regrowth is the other complication of dehorning or disbudding by physical and chemical methods.⁶⁻⁹ One of the newest methods for disbudding is the subcutaneous (SC) injection of clove essential oil into the horn bud.¹⁰

Eugenol (EG; 4-allyl-2-methoxyphenol, chemical formula: $C_{10}H_{12}O_2$) is a component of essential oil especially in *Pimenta racemosa* (bay leaves), *Cinnamomum verum* (cinnamon leaf) and *Syzygium aromaticum* (clove).^{11,12} Eugenol has some anti-inflammation, anti-microbial, anti-fungal, anti-spasmodic and anti-oxidant effects, with well documented pathways.^{11,13,14} It tastes very acrid and has a phenolic smell. Eugenol phenolic structure performs its anti-microbial activity via protein denaturation and cell

membrane reaction.¹⁵ Its anti-inflammatory activity is due to cyclooxygenase type II enzyme inhibition and selective binding to capsaicin receptor which induces its analgesic activity.^{16,17} The EG has been used in folk medicine, mouth hygiene, as the flavor in food and perfume industrial, and as an anesthesia agent in fish and dental analgesia.^{11,13,15,16} The effectiveness of the clove essential oil was demonstrated in the author's previous work.¹⁰ Since the essential oil is expensive and difficult to obtain, this study was performed to investigate the efficacy of SC injection of synthetic pure EG (100%) in goat kids disbudding, because of its low price and availability.

Materials and Methods

Five-day-old healthy Raeini (Cashmere) goat kids ($n = 30$) from both sexes were randomly divided into six groups ($n = 5$). Shahid Bahonar University of Kerman research ethic committee had approved this study (13.1.2017-11/123). All stages of experimental procedures were carried out in accordance with the instructions for working with laboratory animals.

In pathology (P) groups (P_3 , P_8 and P_{60} according to the sample collection day after injection), 0.10 mL of EG resin extract (Merck Darmstadt, Germany) was administered subcutaneously in both horn buds of five-day-old goat kids. Animals of P_3 and P_8 groups were slaughtered according to Islamic principles three and eight days after injections, respectively, and 1×1 cm specimens were taken from the skin of the horn buds, kidneys, liver, lung, brain and heart. In P_{60} group, skin specimen was taken from the horn buds, following local analgesia, with a 7-mm biopsy punch. In disbudding 1 group (DB_1) 0.10 mL of EG was subcutaneously administered in right horn buds of five-day-old goat kids and in disbudding 2 group (DB_2) 0.10 mL of EG was subcutaneously injected in right horn buds of 12-day-old goat kids. In the control group (C), 0.10 mL normal saline was subcutaneously administered in right horn buds of five-day-old goat kids. The left horn bud of DB_1 , DB_2 and C groups goat kids were considered as control of horn outgrowing. All the injections were done subcutaneously, under the cranial edge of horn buds.

Morphometric evaluation. For the evaluation of EG effects on horns growth, the longitudinal and transverse growth (i.e. diameter) of the right and left horns in DB groups were measured by caliper weekly for eight weeks.

Histopathologic evaluation. After goats were scarified, skin specimens (1×1 cm) were taken from right horn buds, and also specimens from vital organs (kidney, liver, lung, brain) in P_3 and P_8 groups were collected. In P_{60} group, only skin samples were collected under local analgesia by biopsy punch. The collected samples were fixed in 10.00% buffered formalin, embedded in paraffin wax, sectioned at 5 μ m thickness, and stained with hematoxylin and eosin (H & E) for light microscopy.

Radiographic evaluation. To evaluate the frontal bone for possible injury, radiographs were taken every two weeks until eight weeks in DB₁ group. The radiographs were taken in lateral and rostro-caudal position (kV = 65 and MAs = 1.50) using HF x-ray machine (EcoRAY Co., Seoul, South Korea).

Statistical analysis. SPSS software (version 16.0; SPSS Inc., Chicago, USA) was used for statistical analysis of data. Statistical analysis was performed using repeated measures analysis of variance. A *p* value less than 0.05 was considered statistically significant. The results of histopathological and radiological studies were evaluated descriptively in all P groups and DB₁ group. All data were expressed as mean ± SD.

Results

Morphometric evaluation. According to the morphometric measurements, results showed that the EG stopped horn longitudinal and transverse growth in all right horns in the DB₁ group (Figs. 1 and 2). There was a significant difference between right and left horn growth (*p* < 0.05).

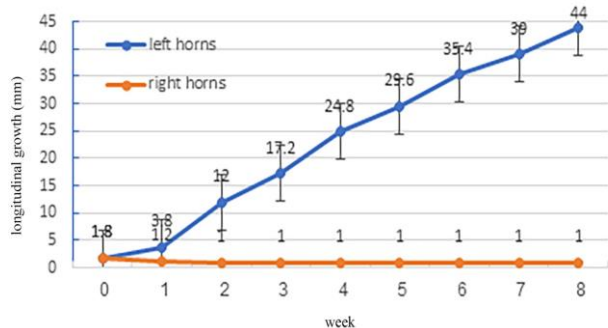


Fig. 1. Right and left horns longitudinal growth in DB₁ group showed significant difference during eight weeks.

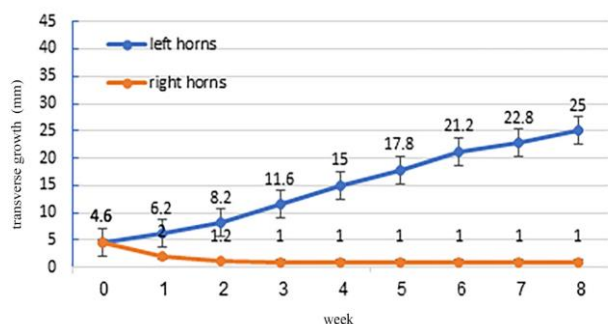


Fig. 2. Right and left horns transverse growth in DB₁ group showed significant difference during eight weeks.

Horn growth was seen in all left and right horns in C group with no significant difference. In DB₂ group, EG administration in right bud couldn't stopped right horn growth and there was no significant difference between the growth of left and right horns.

Histopathological evaluation. In control group, there was no gross changes in the horn bud region or adjacent tissues, following normal saline injection. The remarkable changes in the horn bud skin such as dark red to black color after 24 hr (gross necrotic appearance) occurred in horn bud skin during the first week after EG injection. After 60 days of injection, the diameter of the lesions reduced to half of the first week. The microscopic examination of right horn bud samples of P₃ group, showed complete necrosis of horn bud, and dermal appendices to the epidermis in the injection sites. Keratinocytes of epidermal layer had eosinophilic cytoplasm with pyknotic or karyorrhectic nuclei. Desmosome junctions between epidermal cells were invisible. Nevertheless, the necrotic epidermis had remained in its place and did not remove. No remarkable inflammation observed in the derma. Hemorrhagic foci were seen in some areas. Re-epithelialization process had started from the margins of necrotic area and was moving under the injured epidermis (Fig. 3).

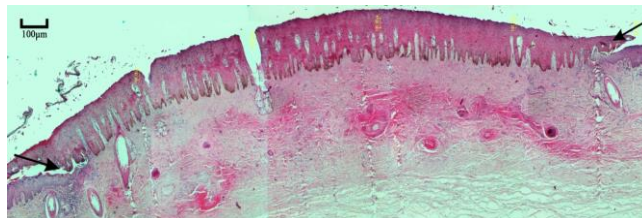


Fig. 3. Starting point of re-epithelialization from necrotic area margin (arrows) in group P₃ (H & E; Bar = 100 μm).

In the histopathological examination of samples from P₈ group, damaged area was covered by the overlapped new and old epithelium. Healing process as granulation tissue formation was observed in the dermis layer. Remained necrotic debris were being removed by macrophages especially in the peripheral zones of the injected sites. Few neutrophils were also seen (Fig. 4).

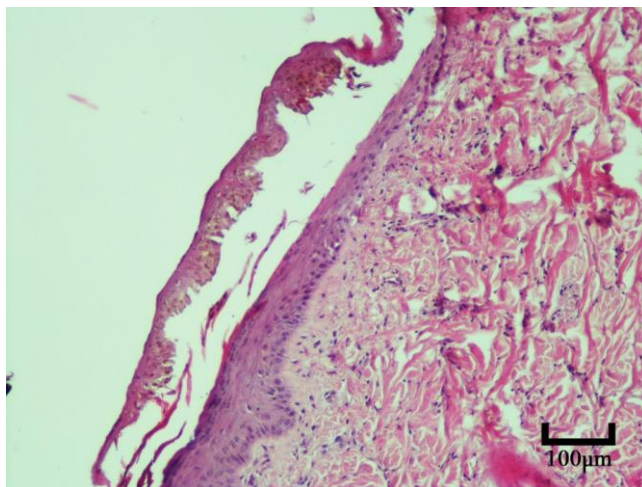


Fig. 4. Re-epithelialization completing under the remained necrotic epidermis in subgroup P₈ (H & E; Bar = 100 μm).

In P₆₀ group, necrotic areas due to injection were lined by a completed new keratinized epithelium with proper thickness. Repaired tissues contained some neo-vascularization foci, and remodeling and maturation was continuing (Fig. 5). The vital organs were normal in the microscopic study.

X-ray evaluation. In all plane radiographs, taken from the frontal bone and frontal sinus, there was no diagnostic sign of osteomyelitis in DB₁ group (Fig. 6).

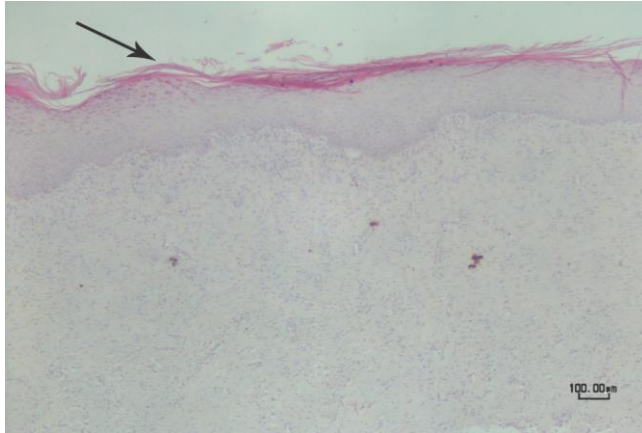


Fig. 5. Completed re-epithelialization and mature granulation tissue formation are seen in group P₆₀ (arrow), (H&E, Bar = 100 μm).

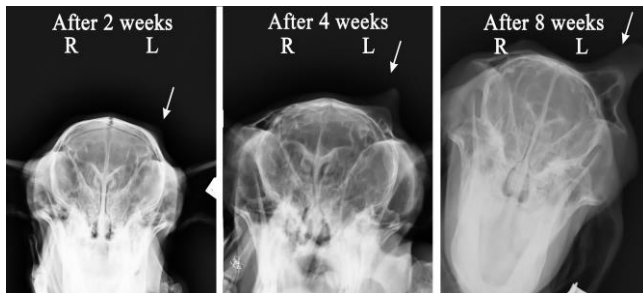

Fig. 6. Caudo-rostral radiographs from the skulls of goat kids (DB₁ group). There were no signs of radiographic changes on the bone around the right bud, which did not grow out due to EG injection. The left horn growth can be seen (arrows).

Discussion

Based on the results of the present study, there was a significant difference between the growth of left and right horns of the goats of DB₁ group. There was also a significant difference in the serial examinations of horn growth, during several weeks. Non-stop growth of the horn in the DB₂ group indicates that EG had no effect after the first week of goat kid's life. According to the results of X-ray examination, failure of the influence of EG after first week of the goat kid's life can be attributed to the growth of the horn and the protrusion of the frontal sinus to the middle hole of the horn. The histopathologic study showed that local administration of EG had no toxic or other side effects on the vital organs.

Eugenol as a phytochemical agent, is reported to have chemo-prevention effect on the progress of cancer. The molecular mechanisms of EG action, such as apoptosis in melanoma, osteosarcoma, leukemia, gastric, skin tumors and mast cells, have been well documented in previous studies.¹⁸⁻²¹ Pisano *et al.* reported the inhibitory effect of dimeric forms of dihydro-eugenol on melanoma cell line. 6,6'-dibromo dehydrodieugenol completely inhibited the melanoma cell line growth.¹⁹ Kim *et al.* demonstrated EG apoptosis action on G361 melanoma cell line and the reduction of cell's viability in 1 μM with time dependent method. Treatment cells showed compressed and segmented nuclei with Hoechst staining in microscopical study.²⁰ The results of a study by Pal *et al.*, confirmed chemo-preventive activity of the EG on skin carcinogens in mice in topical administration, and the tumor development reduction with oral treatment after 15 days.²¹ Reportedly, the anti-proliferation effect of EG by apoptosis pathways on leukemia, gastric tumor, prostate tumor, mast cell adenoma, osteosarcoma have been approved.¹⁸

Molaei *et al.* obtained the same results as the results of the present study using essential clove oil (0.20 mL) for disbudding of goat kids.¹⁰ They showed that EG is one of the components of essential clove oil (72.00 – 95.00%), so this study confirms the effect of EG alone on inhibition of horn growth. In the present study, only 0.10 mL synthetic EG was used for stopping horn growth, so it should be mentioned that EG administration could be cost-effective.

Koger used calcium chloride as a chemical method for disbudding. Calcium chloride 50.00% was injected (0.75 to 2.00 mL) under the calves horn buds for stopping horn growth but it requires the administration of a local analgesia or general sedation and it makes the tissue swelling at the injection site.⁵ There are a number of hypotheses regarding to EG analgesic mechanism such as inhabitation of the peripheral pain, suppression of prostaglandin or other inflammatory intermediates like leukotrienes and blocking the pain receptors.²²⁻²⁵ Due to the anti-inflammatory and analgesic effects of EG, no analgesia or sedation was needed before injection.

Thompson *et al.* reported the death of 150 dairy goat kids (4 to 10-day-old), three days after dehorning by hot iron.²⁶ There were some gross lesions such as necrotic tissue and scar on the skin of disbudding site. The frontal lobe of brain was reddened and necrotic area was seen in cerebral tissue. In the previous studies, several goat kid deaths were also reported as a result of thermal dehorning.^{27,28} In the histopathology, the gross lesions such as hemorrhage, fibrin thrombi in blood vessel, and inflammatory cells were identified. In the present study, there was no sign of swelling in the disbudding and adjacent areas three, eight, and 60 days after EG injection. In the X-ray examination, there was also no diagnostic sign of cerebral injury or osteomyelitis.

Since there are severe reported complications following dehorning adult goats such as severe bleeding and the rapid horn bud growth, disbudding goats at their early age has been recommended.^{29,30} Dehorning adult goats makes an opening to the frontal sinus that due to the infectious sinusitis necessitates the medical and supportive management. One of the complications in kids disbudding is horn regrowth with abnormal shapes and scars tissue formation, which needs dehorning to be repeated.³¹

The most common method for disbudding goat kids is using the hot iron in their early age. Thermal disbudding in goat kids causes acute pain and stress which releases a high amount of cortisol, so it is necessary to use an anesthetic or analgesic agent in this method.^{31,32} The anatomical variations in the goat frontal bone, can result in damage to the skull bone and its underlying tissue, following thermal disbudding.^{26,27} The extensive proliferation of the goat horn base is due to the vast area must destroy with physical method such as hot iron for successful disbudding.^{29,30,33}

According to the results of the present study, subcutaneous administration of EG could stop horn growth completely with no side effects, in five-day-old goat kids. Therefore, this procedure can be considered as an effective alternative method for disbudding goat kids.

Acknowledgments

We would like to thank Dr. Hamid Sharifi, Dr. Omid Azari and Dr. Mohammad Mehdi Oloumi for their help in the methods, data analysis and valuable comments which greatly improved the manuscript.

Conflict of interest

The authors declare that they have no conflict of interest regarding the publication of this article.

References

1. Dyce KM, Sack WO, Wensing CJG. Textbook of Veterinary Anatomy-E-Book. Edinburgh, UK: Elsevier Health Sciences 2009;355-360.
2. Al-Sobayil FA. A new simple device for dehorning in small ruminants. *Small Rumin Res* 2007; 67(2-3): 232-234.
3. Oehme FW. Textbook of large animal surgery. Baltimore, USA: Williams and Wilkins 1988;180-185.
4. Fubini SL, Ducharme NG. Textbook of farm animal surgery: St. Louis, USA: Saunders; 2004;511-515.
5. Koger LM. Dehorning by injection of calcium chloride. *Vet Med Small Anim Clin* 1976; 71(6):824-825.
6. Guidotti TL. Critique of available studies on the toxicology of kretek smoke and its constituents by routes of entry involving the respiratory tract. *Arch Toxicol* 1989; 63(1):7-12.
7. Kihurani D, Mbiuki S, Ngatia T. Healing of dehorning wounds. *Brit Vet J* 1989; 145(6):580-585.
8. Petrie N, Mellor D, Stafford K, et al. Cortisol responses of calves to two methods of disbudding used with or without local anesthetic. *New Zeal Vet J* 1996; 44(1):9-14.
9. Bengtsson B, Menzel A, Holtenius P, et al. Cryosurgical dehorning of calves: a preliminary study. *Vet Rec* 1996; 138(10):234-237.
10. Molaei MM, Mostafavi A, Kheirandish R, et al. Study of disbudding goat kids following injection of clove oil essence in horn bud region. *Vet Res Forum* 2015; 6(1):17-22.
11. Pavithra B. Eugenol-A Review. *Indian J Med Res*. 1981; 73:443-451.
12. Carrasco A, Espinoza C, Cardile V, et al. Eugenol and its synthetic analogues inhibit cell growth of human cancer cells (Part I). *J Brazil Chem Soc* 2008;19(3):543-548.
13. Alma MH, Ertas M, Nitz S, et al. Chemical composition and content of essential oil from the bud of cultivated Turkish clove (*Syzygium aromaticum* L.). *Bioresources* 2007;2(2):265-269.
14. Myint S, Wan Daud WR, Mohamad AB. Determination of optimal conditions for extraction of alcohol-soluble eugenol containing material from cloves. *Pertanika J Sci Technol* 1995; 3(1):99-106.
15. Guan W, Li S, Yan R, et al. Comparison of essential oils of clove buds extracted with supercritical carbon dioxide and other three traditional extraction methods. *Food Chem* 2007; 101(4):1558-1564.
16. Hernández-Sánchez P, López-Miranda S, Lucas-Abellán C, et al. Complexation of eugenol (EG), as main component of clove oil and as pure compound, with β - and HP- β -CDs. *Food Nut Sci* 2012; 3(6):716-723.
17. Ohkubo T, Shibata M. The selective capsaicin antagonist capsazepine abolishes the antinociceptive action of eugenol and guaiacol. *J Dent Res* 1997; 76(4):848-851.
18. Jaganathan SK, Supriyanto E. Antiproliferative and molecular mechanism of eugenol-induced apoptosis in cancer cells. *Molecules* 2012; 17(6):6290-6304.
19. Pisano M, Pagnan G, Loi M, et al. Antiproliferative and pro-apoptotic activity of eugenol-related biphenyls on malignant melanoma cells. *Mol Cancer* 2007; 6(1):8. doi:10.1186/1476-4598-6-8.
20. Kim GC, Choi DS, Lim JS, et al. Caspases-dependent apoptosis in human melanoma cell by eugenol. *Korean J Anat* 2006; 39(3):245-253.
21. Pal D, Banerjee S, Mukherjee S, et al. Eugenol restricts DMBA croton oil induced skin carcinogenesis in mice: Downregulation of c-Myc and H-ras, and activation of p53 dependent apoptotic pathway. *J Dermatol Sci* 2010; 59(1):31-39.

22. Kurian R, Arulmozhi DK, Veeranjanyulu A, et al. Effect of eugenol on animal models of nociception. *Indian J Pharmacol* 2006; 38(5):341-345.
23. Daniel AN, Sartoretto SM, Schmidt G, et al. Anti-inflammatory and antinociceptive activities A of eugenol essential oil in experimental animal models. *Rev Bras Farmacogn* 2009; 19(1B):212-217.
24. Raghavenra H, Diwakr B, Lokesh B, et al. Eugenol: The active principle from cloves inhibits 5-lipoxygenase activity and leukotriene-C4 in human PMNL cells. *Prostaglandins Leukot Essent Fatty Acids* 2006; 74(1):23-27.
25. Robbers JE, Tyler VE. *Tyler's herbs of choice: The therapeutic use of phytomedicinals*. Binghampton, USA: Haworth Press Inc 199;92-98.
26. Thompson K, Bateman R, Morris P. Cerebral infarction and meningoencephalitis following hot-iron disbudding of goat kids. *New Zeal Vet J* 2005; 53(5):368-370.
27. Wright H, Adams D, Trigo F. Meningoencephalitis after hot-iron disbudding of goat kids. *Vet Med Small Anim Clin*. 1983; 78:599-601.
28. Sanford SE. Meningoencephalitis caused by thermal disbudding in goat kids. *Can Vet J* 1989; 30(10):832.
29. Hull BL. Dehorning the adult goat. *Vet Clin N Am Food A* 1995; 11(1):183-185.
30. Buttle H, Mowlem A, Mews A. Disbudding and dehorning of goats. *In Pract* 1986; 8(2):63-65.
31. Hague Ba, Hooper R. Cosmetic dehorning in goats. *Vet Surg* 1997; 26(4):332-334.
32. Alvarez L, Gutierrez J. A first description of the physiological and behavioural responses to disbudding in goat kids. *Anim Welfare* 2010; 19(1):55-59.
33. Hendrickson DA, Baird AN. *Text book of Turner and McIlwraith's techniques in large animal surgery*. Baltimore, USA: John Wiley & Sons; 2013;293-296.