

# Improved Techniques for Endoscopic Mucosal Resection (EMR) in Colorectal Adenoma

Moritz Sold · Georg Kähler

Zentrale Interdisziplinäre Endoskopie ZIE, Universitätsmedizin Mannheim, Germany

## Keywords

Endoscopic mucosal resection · EMR · Adenoma · Colonic polyps

## Summary

**Background:** Endoscopic therapy of colorectal adenomas and early cancers is a standard method. Besides oncological criteria, the method is limited by polyp location, size, and texture. **Method:** Based on the current literature, technical modifications and developments in endoscopic mucosal resection are described. **Results:** Numerous approaches exist to improve the conditions of resection, including optimisation of mucosal elevation and modification of techniques, tools, and devices. **Conclusion:** Endoscopic therapy of sessile and flat colorectal polyps remains a challenge. Some of the presented modifications can help to address this challenge.

## Schlüsselwörter

Endoskopische Mukosaresektion · EMR · Adenom · Kolonpolypen

## Zusammenfassung

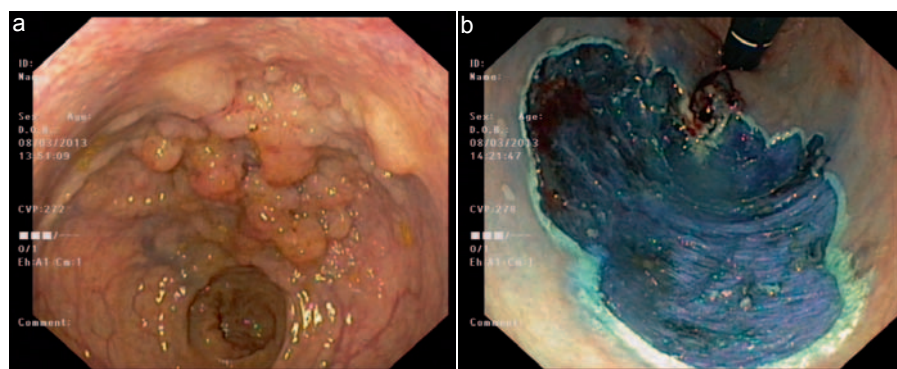
**Hintergrund:** Die endoskopische Therapie von kolorektalen Adenomen und Frühkarzinomen stellt eine Standardmethode dar. Neben onkologischen Kriterien ist diese Methode limitiert durch Größe, Lokalisation und Beschaffenheit der Polypen. **Methode:** Publierte Neuerungen zur Optimierung der endoskopischen Therapie werden vorgestellt und diskutiert. **Ergebnisse:** Ansätze zur Verbesserung der Resektionsbedingungen existieren zahlreich. Zum einen wird versucht, die der Resektion vorausgehende Mukosaelevation zu optimieren, zum anderen werden Instrumente und Resektionstechniken modifiziert. **Schlussfolgerung:** Die endoskopische Therapie flächiger und großer Adenome im Kolorektum bleibt eine Herausforderung. Durch hier vorgestellte Modifikationen kann eine Verbesserung der Resektionsbedingungen und damit auch der Ergebnisse erreicht werden.

## Introduction

Endoscopic polypectomy was first described over 40 years ago [1, 2]. Even at this first snare resection, a submucosal injection with saline was performed for better handling of the snare and prevention of perforation and thermal damage to the deeper tissue layers [1, 3]. This combination of endoscopic snare resection with preceding mucosal injection quickly became the standard method for the treatment of polyps and adenomas, and Inoue et al. [4] and Soehendra et al. [5] coined the term ‘endoscopic mucosal resection’ (EMR) for flat lesions. While snare resection of pedunculated polyps is performed safely in most cases, the risks increase especially with flat and sessile lesions and with increasing polyp size. In addition

to technical complications such as perforation and bleeding, the risk of incomplete ablation and recurrence grows [6]. From a size of 20 mm, the lesion usually cannot be resected in one piece (‘en bloc’) but must be removed in several fragments (‘piecemeal’) (fig. 1). This fractional technique not only makes the histopathological assessment of the completeness of resection almost impossible but also increases the risk of recurrence [7, 8]. The goal is to improve endoscopic resection in such a way that wide and flat lesions can be accessed and removed safely. One approach is the use of different fluids for the generation of a submucosal fluid cushion. In addition, different resection devices and modified ablation techniques including adoption of some principles of endoscopic submucosal dissection (ESD) have been described.

**Fig. 1.** Flat adenoma of the rectum before (a) and after (b) piecemeal EMR.



### Mucosal Elevation

In the first polypectomy described, mucosal elevation was created by injections in order to avoid thermal injury to the deeper tissue layers [1, 3]. In larger and flat lesions, the problem is that the applied liquid quickly spreads to the surrounding tissue and the raised mucosa flattens before complete resection can be performed [9]. To avoid this problem, numerous substances have been tested and described in the literature, through which the authors expected to obtain a longer-lasting fluid cushion in the submucosa. Especially in the colorectum, it is important to generate a fluid cushion before the use of cutting tools, because the wall layers are only a few millimetres thick. Therefore, perforations through penetration of the instrument or grasping deeper layers with the snare can happen more easily than in the stomach [10]. In addition, a longer-lasting fluid cushion facilitates en bloc resection with resulting benefits.

### Substances Used for Injection

First modifications were made by changing the saline concentration and other additives such as epinephrine. In 1999, Yamamoto et al. [11] described for the first time the use of sodium hyaluronate (SH) for mucosal elevation. Since then, several studies have been published that confirm that SH is very well suited to this purpose [12, 13]. The authors emphasise that with SH a much more inert fluid cushion can be created. SH has a high viscosity and is clinically used, for example, for intra-articular injection in osteoarthritis. It is an endogenous substance and therefore not antigenic. Due to the high viscosity, it is difficult to inject; also, special storage conditions have to be considered. The most serious disadvantage of SH is the high price of the substance, which hinders a wide range of applications [14]. Therefore, several study groups have investigated the possibility of diluting highly concentrated hyaluronic acid (HA) and using it in a mixture with other substances for injection to reduce the high cost and at the same time not abandon the convenience of this substance for EMR [15, 16]. An inexpensive, over-the-counter 0.15%

HA preparation was successfully used for safe and effective EMR for 33 lesions [16]. Conio et al. [17] compared normal saline solution, normal saline solution plus epinephrine, 50% dextrose, 10% glycerine/5% fructose in normal saline solution, and 1% HA. The experiments were performed in vivo, and flattening of the elevated areas was observed endoscopically and measured. HA showed the most consistent effect of elevation and saline solutions the shortest. The potential of sugar solutions was higher than that of the saline solutions. The authors recommend 50% dextrose solution as an alternative medium for injection, if a longer duration of the fluid cushion is desired and HA cannot be used because of the high cost. Hurlstone et al. [18] compared 174 patients randomised to dextrose solution or SH for en bloc resection of flat lesions of the colorectum. They concluded that EMR using dextrose solution was as effective as SH in terms of resection completion, recurrence rates, and complications.

Plasma surrogates have also been investigated in other studies: Moss et al. [19] compared, in ex vivo conditions, the use of succinylated gelatine and normal saline solution in the colon and could achieve a 42% increase in surface area for en bloc EMR with gelatine. Katsinelos et al. [20] conducted a prospective, double-blind, randomised study that compared EMR after use of either 50% dextrose plus epinephrine or normal saline solution plus epinephrine to create the submucosal fluid cushion. 92 sessile rectosigmoid polyps were removed. Injected solution volumes and the number of injections needed to maintain submucosal elevation were lower in the dextrose group, and the submucosal elevations were of longer duration. The same group published 49 cases of laterally spreading tumours which were resected after randomised injection with either normal saline solution plus epinephrine or hydroxyethyl starch plus epinephrine. Starch injection resulted in a more prolonged submucosal elevation and lower total procedure time than saline solution [21], according to results from our group [22].

Feitoza et al. [14] recommended hydroxypropyl methylcellulose (HPMC) for submucosal injection. HPMC is a cellulose derivative and has similar viscoelastic properties as HA. The advantages of HPMC compared with HA according to the authors are easy availability and significantly lower costs. A

study carried out on pigs showed that with a 0.83% HPMC solution, long-lasting fluid cushions (up to 45 min) could be generated [14]. Meanwhile, the feasibility of its use was also described in clinical use: Arantes et al. [23] used HPMC for resection of 36 lesions in both the upper and lower gastrointestinal (GI) tract. Complete resection was successfully completed in 89%. HPMC solution (0.4%) provided an effective submucosal fluid cushion and was safe for endoscopic resection of early neoplastic GI lesions. Arezzo et al. [24] conducted EMR after injection with 0.8% HPMC on 27 flat, sessile, or laterally spreading colorectal lesions of up to 60 mm. Injection of HPMC for EMR was performed safely and effectively, allowing en bloc resection in the majority of cases (n = 21 (78%)) and with a limited number of complications. However, other authors reject HPMC for injection as it is a synthetic product and may have antigenic potential [15].

There are other proposals for synthetic substances for injection: Tran et al. [25] presented an injectable drug-eluting elastomeric polymer (iDEEP), and Chandrasekhara et al. [26] described a submucosal lifting gel consisting of a combination of biocompatible components. Detailed experience with these materials is missing.

In contrast to these synthetic substances, Giday et al. [27] investigated the possibility of using the patient's own whole blood as an injection medium. Six different substances were compared for their elevation potential in vivo. Blood produced the most durable cushion compared with standard agents. It also had the advantages of being readily available and without cost. In the same year, Sato [28] published 35 polypectomies performed as blood patch EMR in 28 patients. Also, Al-Taie et al. [29], after ex vivo comparison of several substances, came to the conclusion that whole blood was more effective in generating long-lasting mucosa elevation than any other commonly used solution. Here, however, there is at least theoretically the disadvantage that the applied blood can restrict the endoscopic view or bleeding can be easily overlooked.

### Application Methods

Another approach to generating longer-lasting fluid cushions is the use of a water jet dissector instead of needle injection, which was investigated by our study group [30]. We showed that a water jet dissector placed directly on the mucosa resulted in selective deposition of liquid in the submucosa followed by mucosal elevation (lift-off). After animal studies and comparison of different injecting solutions [22, 31], we presented the first data from clinical application [32]. A total of 59 patients underwent resection of 70 lesions with a maximum diameter of 80 mm (mean 27 mm). Submucosal elevation with the water jet dissector was possible in all cases. Of the 70 lesions, 64 (91%) were resected completely in one session.

A study group from Italy followed the same principle by developing a self-assembled hydro-jet system connecting a

standard long-tapered tip ERCP (endoscopic retrograde cholangiopancreatography) cannula and a flushing pump [33]. In a first publication, the authors could reproduce the selective accumulation of the applied fluid in the submucosa in 34 lesions of the colon. An adequate submucosal fluid cushion was achieved in all but one case. In a second publication, the authors compared the self-assembled hydro-jet system to standard needle injection [34]. The hydro-jet system was as effective and safe as standard needle injection for tissue elevation prior to endoscopic resection, but it was significantly faster.

### Resection Techniques

Snare resection represented the beginning of therapeutic endoscopy, developed for the removal of small pedunculated polyps. This technique represented a completely new method of endoscopic therapy, and after its introduction in 1971 it became widespread. Further advances were made along the way. In 1976, Martin et al. [35] described a 'lift-and-cut biopsy technique' using a two-channel endoscope. In 1992, Inoue et al. [4] published their 'cap-EMR'. For targeted stepwise endoscopic dissection, a new instrument was developed from the papillotome used in ERCP. Cipolletta et al. [36] used the needle knife for cutting stronger pedunculated polyps in the colon. An advancement of the needle knife is the insulated-tip (IT) knife; the tip of the instrument is insulated with a ceramic ball to prevent penetration into deeper layers. Already in 1999, Gotoda et al. [37] had described the use of the IT knife in 2 patients with flat tumours of the rectum. After saline injection, incision of the mucosa was performed with a needle knife, and then the tumour-bearing mucosa was successfully resected en bloc using the IT knife. From this technique, in which the stepwise preparation within the submucosa is essential, the concept of ESD was developed [7, 11]. As with EMR, stable fluid cushions in the submucosa are crucial. The details of ESD and innovations in this field will not be further discussed in this article.

For successful EMR, it is important to reduce wall tension by suction of air prior to closing the snare, in order to achieve a better grasp of the lesion. After this manoeuvre, the intestinal lumen is re-insufflated and the grasped tissue has to be checked. Then, the actual cut can be done by diathermy, while the examiner must press the catheter of the snare deep into the wall so that the lesion remains completely enclosed.

The transition from EMR to ESD is variable and there are combinations of different methods described. Yahagi et al. [38] treated 59 gastric lesions after injection initially with circular incision around the tumour-bearing mucosa with the tip of a high-frequency (HF) loop; then the mucosa connected to the underlying surface was resected with the fully extended snare. The mean specimen size was 29 mm, and the rate of en bloc resected tumours was 95%. Sakamoto et al. [39] de-

scribed a similar technique of EMR with circumferential incision (CEMR): 24 colorectal neoplasms of >20 mm were first incised with an IT knife, then the snare resection was accomplished. The proportions of en bloc and two-piece resections by CEMR were 67 and 17%, respectively. Moss et al. [40] described the technique of circumferential submucosal incision (CSI-EMR) with an IT knife prior to EMR. The efficacy and safety of CSI-EMR was compared with conventional EMR for en bloc resection in a porcine model. CSI-EMR was safe and superior to conventional EMR, consistently resulting in en bloc resections larger than 50 × 40 mm. Lee et al. [41] named these techniques endoscopic mucosal resection precutting (EMR-P) and evaluated it compared with EMR and ESD: 523 non-pedunculated colorectal tumours of 20 mm or larger were removed with EMR, EMR-P, or ESD. The en bloc resection rates were 42.9% (EMR), 65.2% (EMR-P), and 92.7% (ESD), and the complete resection rates were 32.9% (EMR), 59.4% (EMR-P), and 87.6% (ESD).

Recently, the use of a double-channel endoscope was tested again to reduce the gap between EMR and ESD with a different approach: with a tissue anchor device the mucosa is specifically drawn to the resection snare. First, in an ex vivo study, the authors achieved 90% (9/10) complete en bloc resections with the grasp-and-snare technique [42]. They demonstrated an improved time efficiency of this method compared with ESD. In another publication, this tissue-anchoring EMR (TA-EMR) was compared with ESD and forceps precut EMR (FP-EMR) in a randomised ex vivo study [43]. The overall mean dissection time of both TA-EMR and FP-EMR was significantly shorter than that of ESD. The en bloc resection rate of ESD was 100% and the en bloc resection rate of TA-EMR (84.0%) was higher than that of FP-EMR (60.0%), but this was not statistically significant.

Dauser et al. [44] described traction-assisted EMR with a single-channel endoscope: a haemostatic clip tied to a silk suture was applied to the base of the lesion to allow traction through the working channel of the colonoscope. Then, a conventional polypectomy snare was mounted over the suture, and the lesion was pulled into the snare and resected in one piece. With this technique, 12 colorectal lesions were resected en bloc. The visualisation of colorectal lesions in less accessible locations could be improved as well.

In order to allow a better grasp of the snare, Prosst et al. [45] evaluated a modified snare with special barbs: in an ex vivo study, this snare with special teeth attached to the distal part of the wire loop was evaluated and compared with a conventional snare. 70 artificial sessile tumours were created in a porcine colon. It was shown that the modified snare could remove 31% more tissue with a single snare resection in comparison with the conventional snare without teeth. The teeth obviously increased the effectiveness of snare resection by avoiding the accidental loss of entrapped tissue from the loop.

Choi et al. [46] reported a complete resection rate comparable to that of ESD and a shorter procedure time with small

rectal carcinoid tumours of <10 mm using an EMR technique with band ligation of the tumour (EMR-B) prior to snare resection.

Another approach to improve the results of resection was presented by Binmoeller et al. [47]: the authors described a novel method of water immersion ('underwater') EMR (UEMR) that dispenses with submucosal injection. UEMR was performed in 60 patients with 62 large sessile colorectal polyps. Before EMR, air was evacuated and up to 1 l of water infused until complete filling of the lumen was achieved. Afterwards, marking and resection were performed. Complete resection was successful in all patients without early complications. The mean polyp size was 34 mm, and the mean resection time was 21 min.

Conio et al. [48] reported their experience with cap-assisted EMR (EMR-C) for colorectal polyps. This is rarely performed because of the risk of entrapping the muscularis propria in the snare. In a prospective study of consecutive patients, a total of 146 sessile polyps and 136 laterally spreading tumours were treated with EMR-C. No perforation occurred, but a disadvantage of the technique is that the resection is piecemeal.

## Miscellaneous

Recently, some other improvements for EMR have been described. Park et al. [49] investigated in a prospective, randomised, controlled trial the use of cap-assisted colonoscopy (CAC). In 329 patients, the authors compared total procedure time, time required for EMR of each polyp, and missing polyp rate for CAC and regular colonoscopy. Their conclusion was that CAC is a safe, simple, and inexpensive technology that could reduce the time required for EMR of a polyp and may improve polyp detection, especially when multiple colorectal polyps have been seen on previous colonoscopy.

To improve the colonoscopic access for mucosal resection in the sigmoid colon, a special cuff was developed. Tsiamoulos et al. [50] published their experience with this device which helps to anchor the tip of the colonoscope against the bowel wall to provide a stable platform of access. Endocuff™ (Diagmed Healthcare Ltd., Northallerton, North Yorkshire, UK) appears to improve access in the sigmoid colon by flattening colon folds and manipulating them away from the field of forward view.

Several techniques like coagulation, argon plasma, and endoclips exist for haemostasis during and after EMR. As an alternative, a new polysaccharide haemostatic system (EndoClot™; EndoClot Plus Inc., Santa Clara, CA, USA) was recently developed for control of bleeding in GI tract endoscopy. Huang et al. [51] presented their findings on the effect of bleeding control after EMR in the colorectum. EndoClot™ showed rapid bleeding control even in relatively large lesions and severe bleeding, and might be a useful alternative in treating bleeding endoscopically.

## Conclusion for Clinical Practice

In summary, a variety of substances have been proposed as an alternative to saline solution for mucosal injection before resection, but there is still no clear favourite among the methods in wide clinical use. While HA yields better elevation than other substances, routine use, especially in Europe, is inconceivable at the moment, solely because of the high cost. Basically, higher molecular weight substances appear to be suitable to produce long-lasting fluid cushions. Whether plasma surrogates such as starch or gelatine or synthetic substances such as HPMC are going to be used, is left to the investigator. The water jet seems to be a promising tool for effective and fast EMR. Even with the technical developments and modified resection techniques, there are numerous interesting approaches. With technical advancement in recent years, the

size of the lesions that can be endoscopically treated has increased. The potential value of ESD for colorectal lesions compared with high-quality EMR is under debate. For daily routine, it can be assumed that unnecessary colonic surgery can be avoided if available endoscopic techniques for the complete removal of colorectal adenoma are fully exploited. Known risks, such as incomplete removal, bleeding, and perforation, may be reduced due to the new instruments. However, like most surgical procedures, EMR and ESD also require an experienced physician for the procedures to be safe.

## Disclosure Statement

GK and MS received research support from Erbe Elektromedizin Tübingen, Germany, and Karl Storz Endoskope Tuttlingen, Germany.

## References

- 1 Classen M, Demling L: Operative Gastroskopie: Fiberoskopische Polypenabtragung im Magen. *Dtsch Med Wochenschr* 1971;96:1466–1467.
- 2 Deyhle P, Largiadèr F, Jenny S, Fumagalli I: A method for endoscopic electroresection of sessile colonic polyps. *Endoscopy* 1973;5:38–40.
- 3 DePalma GD, Caiazzo C, DiMatteo E, Capalbo G, Catanzano C: Endoscopic treatment of sessile rectal adenomas: comparison of Nd:YAG laser and injection-assisted piecemeal polypectomy. *Gastrointest Endosc* 1995;41:553–556.
- 4 Inoue H, Takeshita K, Hori H, Muraoka Y, Yoneshima H, Endo M: Endoscopic mucosal resection with a cap-fitted panendoscope for esophagus, stomach, and colon mucosal lesions. *Gastrointest Endosc* 1993;39:58–62.
- 5 Soehendra N, Binmoeller KF, Bohnacker S, Seitz U, Brand B, Thonke F, Gurakuqi G: Endoscopic snare mucosectomy in the esophagus without any additional equipment: a simple technique for resection of flat early cancer. *Endoscopy* 1997;29:380–383.
- 6 Church JM: Experience in the endoscopic management of large colonic polyps. *ANZ J Surg* 2003;73:988–995.
- 7 Ono H, Kondo H, Gotoda T, Shirao K, Yamaguchi H, Saito D, Hosokawa K, Shimoda T, Yoshida S: Endoscopic mucosal resection for treatment of early gastric cancer. *Gut* 2001;48:225–229.
- 8 Walsh RM, Ackroyd FW, Shellito PC: Endoscopic resection of large sessile colorectal polyps. *Gastrointest Endosc* 1992;38:303–309.
- 9 Sakai P, Filho FM, Iryia K, Moura EGH, Tomishige T, Scabbia A, Ishioka S: An endoscopic technique for resection of small gastrointestinal carcinomas. *Gastrointest Endosc* 1996;44:65–67.
- 10 Yamamoto H, Yahagi N, Oyama T: Mucosectomy in the colon with endoscopic submucosal dissection. *Endoscopy* 2005;37:764–768.
- 11 Yamamoto H, Yube T, Isoda N, Sato Y, Sekine Y, Higashizawa T, Ido K, Kimura K, Kanai N: A novel method of endoscopic mucosal resection using sodium hyaluronate. *Gastrointest Endosc* 1999;50:251–256.
- 12 Yamamoto H, Kawata H, Sunada K, Sasaki A, Nakazawa A, Miyata T, Sekine Y, Yano T, Satoh K, Ido K, Sugano K: Successful en bloc resection of large superficial tumors in stomach and colon using sodium hyaluronate and small-caliber-tip transparent hood. *Endoscopy* 2003;35:690–694.
- 13 Yamamoto H, Kawata H, Sunada K, Satoh K, Kaneko Y, Ido K, Sugano K: Success rate of curative endoscopic mucosal resection with circumferential mucosa incision assisted by submucosal injection of sodium hyaluronate. *Gastrointest Endosc* 2002;56:507–512.
- 14 Feitoza AB, Gostout CJ, Burgart LW, Burkert A, Herman LJ, Rajan E: Hydroxypropyl methylcellulose: a better submucosal fluid cushion for endoscopic mucosal resection. *Gastrointest Endosc* 2003;57:41–47.
- 15 Fujishiro M, Yahagi N, Kashimura K, Mizushima Y, Oka M, Matsuura T, Enomoto S, Kakushima N, Imagawa A, Kobayashi K, Hashimoto T, Iguchi M, Shimizu Y, Ichinose M, Omata M: Different mixtures of sodium hyaluronate and their ability to create submucosal fluid cushions for endoscopic mucosal resection. *Endoscopy* 2004;36:584–589.
- 16 Friedland S, Kothari S, Chen A, Park W, Banerjee S: Endoscopic mucosal resection with an over-the-counter hyaluronate preparation. *Gastrointest Endosc* 2012;75:1040–1044.
- 17 Conio M, Rajan E, Sorbi D, Norton I, Herman L, Filiberti R, Gostout CJ: Comparative performance in the porcine esophagus of different solutions used for submucosal injection. *Gastrointest Endosc* 2002;56:513–516.
- 18 Hurlstone DP, Fu KI, Brown SR, Thomson M, Atkinson R, Tiffin N, Cross SS: EMR using dextrose solution versus sodium hyaluronate for colorectal Paris type I and 0-II lesions: a randomized endoscopist-blinded study. *Endoscopy* 2008;40:110–114.
- 19 Moss A, Bourke MJ, Kwan V, Tran K, Godfrey C, McKay G, Hopper AD: Succinylated gelatin substantially increases en bloc resection size in colonic EMR: a randomized, blinded trial in a porcine model. *Gastrointest Endosc* 2010;71:589–595.
- 20 Katsinelos P, Kountouras J, Paroutoglou G, Chatzimavroudis G, Zavos C, Pilpilidis I, Gelas G, Paikos D, Karakousis K: A comparative study of 50% dextrose and normal saline solution on their ability to create submucosal fluid cushions for endoscopic resection of sessile rectosigmoid polyps. *Gastrointest Endosc* 2008;68:692–698.
- 21 Fasoulas K, Lazaraki G, Chatzimavroudis G, Paroutoglou G, Katsinelos T, Dimou E, Geros C, Zavos C, Kountouras J, Katsinelos P: Endoscopic mucosal resection of giant laterally spreading tumors with submucosal injection of hydroxyethyl starch: comparative study with normal saline solution. *Surg Laparosc Endosc Percutan Tech* 2012;22:272–278.
- 22 Sold MG, Grobholz R, Post S, Enderle MD, Kaehler GF: Submucosal cushioning with water jet before endoscopic mucosal resection: which fluids are effective? *Surg Endosc* 2008;22:443–447.
- 23 Arantes V, Albuquerque W, Benfica E, Duarte DL, Lima D, Vilela S, Lima G, Sakai P, Filho FM, Artifon E, Halwan B, Kumar A: Submucosal injection of 0.4% hydroxypropyl methylcellulose facilitates endoscopic mucosal resection of early gastrointestinal tumors. *J Clin Gastroenterol* 2010;44:615–619.
- 24 Arezzo A, Pagano N, Romeo F, Delconte G, Hervoso C, Morino M, Repici A: Hydroxy-propyl-methyl-cellulose is a safe and effective lifting agent for endoscopic mucosal resection of large colorectal polyps. *Surg Endosc* 2009;23:1065–1069.
- 25 Tran RT, Palmer M, Tang SJ, Abell TL, Yang J: Injectable drug-eluting elastomeric polymer: a novel submucosal injection material. *Gastrointest Endosc* 2012;75:1092–1097.
- 26 Chandrasekhara V, Sigmon JC Jr, Surti VC, Kochman ML: A novel gel provides durable submucosal cushion for endoscopic mucosal resection and endoscopic submucosal dissection. *Surg Endosc* 2013;27:3039–3042.
- 27 Giday SA, Magno P, Buscaglia JM, Canto MI, Ko CW, Shin EJ, Xia L, Wroblewski LM, Clarke JO, Kalloo AN, Jagannath SB, Kantsevov SV: Is blood the ideal submucosal cushioning agent? A comparative study in a porcine model. *Endoscopy* 2006;38:1230–1234.
- 28 Sato T: A novel method of endoscopic mucosal resection assisted by submucosal injection of autologous blood (blood patch EMR). *Dis Colon Rectum* 2006;49:1636–1641.
- 29 Al-Taie OH, Bauer Y, Dietrich CG, Fischbach W: Efficacy of submucosal injection of different solutions inclusive blood components on mucosa elevation for endoscopic resection. *Clin Exp Gastroenterol* 2012;5:43–48.

- 30 Kaehler GF, Sold MG, Fischer K, Post S, Enderle M: Selective fluid cushion in the submucosal layer by water jet: advantage for endoscopic mucosal resection. *Eur Surg Res* 2007;39:93–97.
- 31 Kaehler GF, Sold MG, Post S, Fischer K, Enderle MD: Selective tissue elevation by pressure injection (STEP) facilitates endoscopic mucosal resection (EMR). *Surg Technol Int* 2007;16:107–112.
- 32 Belle S, Collet PH, Szyrach M, Ströbel P, Post S, Enderle MD, Kaehler G: Selective tissue elevation by pressure for endoscopic mucosal resection of colorectal adenoma: first clinical trial. *Surg Endosc* 2012;26:343–349.
- 33 Cipolletta L, Rotondano G, Bianco MA, Garofano ML, Meucci C, Prisco A, Cipolletta F, Piscopo R: Self-assembled hydro-jet system for submucosal elevation before endoscopic resection of nonpolypoid colorectal lesions (with video). *Gastrointest Endosc* 2009;70:1018–1022.
- 34 Cipolletta L, Bianco MA, Garofano ML, Meucci C, Piscopo R, Cipolletta F, Salerno R, Sansone S, Rotondano G: A randomised study of hydro-jet vs. needle injection for lifting colorectal lesions prior to endoscopic resection. *Dig Liver Dis* 2010;42:127–130.
- 35 Martin TR, Onstad GR, Silvis SE, Vennes JA: Lift and cut biopsy technique for submucosal sampling. *Gastrointest Endosc* 1976;23:29–30.
- 36 Cipolletta L, Bianco MA, Rotondano G, Catalano M, Prisco A, De Simone T: Endoclip-assisted resection of large pedunculated colon polyps. *Gastrointest Endosc* 1999;50:405–406.
- 37 Gotoda T, Kondo H, Ono H, Saito Y, Yamaguchi H, Saito D, Yokota T: A new endoscopic mucosal resection procedure using an insulation-tipped diathermic knife for rectal flat lesions: report of two cases. *Gastrointest Endosc* 1999;50:560–563.
- 38 Yahagi N, Fujishiro M, Kakushima N, Kobayashi K, Hashimoto T, Oka M, Iguchi M, Enomoto S, Ichinose M, Niwa H, Omata M: Endoscopic submucosal dissection for early gastric cancer using the tip of an electrosurgical snare (thin type). *Dig Endoscopy* 2004;16:34–38.
- 39 Sakamoto T, Matsuda T, Nakajima T, Saito Y: Efficacy of endoscopic mucosal resection with circumferential incision for patients with large colorectal tumors. *Clin Gastroenterol Hepatol* 2012;10: 22–26.
- 40 Moss A, Bourke MJ, Tran K, Godfrey C, McKay G, Chandra AP, Sharma S: Lesion isolation by circumferential submucosal incision prior to endoscopic mucosal resection (CSI-EMR) substantially improves en bloc resection rates for 40 mm colonic lesions. *Endoscopy* 2010;42:400–404.
- 41 Lee EJ, Lee JB, Lee SH, Youk EG: Endoscopic treatment of large colorectal tumors: comparison of endoscopic mucosal resection, endoscopic mucosal resection-precutting, and endoscopic submucosal dissection. *Surg Endosc* 2012;26:2220–2230.
- 42 Von Renteln D, Schmidt A, Vassiliou MC, Rudolph HU, Caca K: Endoscopic mucosal resection using a grasp-and-snare technique. *Endoscopy* 2010; 42:475–480.
- 43 Jung Y, Kato M, Lee J, Gromski MA, Chuttani R, Matthes K: Effectiveness of circumferential endoscopic mucosal resection with a novel tissue-anchoring device. *World J Gastrointest Endosc* 2013; 5:275–280.
- 44 Dauser B, Winkler T, Salehi B, Riss S, Beer F, Herbst F: Traction-assisted endoscopic mucosal resection for polypectomy in the large intestine. *World J Gastroenterol* 2010;16:5462–5466.
- 45 Probst RL, Baur FE: A new serrated snare for improved tissue capture during endoscopic snare resection. *Minim Invasive Ther Allied Technol* 2010; 19:100–104.
- 46 Choi CW, Kang DH, Kim HW, Park SB, Jo WS, Song GA, Cho M: Comparison of endoscopic resection therapies for rectal carcinoid tumor: endoscopic submucosal dissection versus endoscopic mucosal resection using band ligation. *J Clin Gastroenterol* 2013;47:432–436.
- 47 Binmoeller KF, Weilert F, Shah J, Bhat Y, Kane S: ‘Underwater’ EMR without submucosal injection for large sessile colorectal polyps (with video). *Gastrointest Endosc* 2012;75:1086–1091.
- 48 Conio M, Bianchi S, Repici A, Ruggeri C, Fisher DA, Filiberti R: Cap-assisted endoscopic mucosal resection for colorectal polyps. *Dis Colon Rectum* 2010;53:919–927.
- 49 Park SY, Kim HS, Yoon KW, Cho SB, Lee WS, Park CH, Joo YE, Choi SK, Rew JS: Usefulness of cap-assisted colonoscopy during colonoscopic EMR: a randomized, controlled trial. *Gastrointest Endosc* 2011;74:869–875.
- 50 Tsiamoulos ZP, Saunders BP: A new accessory, endoscopic cuff, improves colonoscopic access for complex polyp resection and scar assessment in the sigmoid colon (with video). *Gastrointest Endosc* 2012;76:1242–1245.
- 51 Huang R, Pan Y, Hui N, Guo X, Zhang L, Wang X, Zhang R, Luo H, Zhou X, Tao Q, Liu Z, Wu K: Polysaccharide hemostatic system for hemostasis management in colorectal endoscopic mucosal resection. *Dig Endosc* 2014;26:63–68.