



Systematic Review / Meta-analysis

## Efficacy of laparoscopic surgery in the treatment of hepatic abscess: A systematic review and meta-analysis

Abdourahmane Ndong<sup>a,\*</sup>, Jacques Noel Tendeng<sup>a</sup>, Adja Coumba Diallo<sup>a</sup>, Alassane Dieye<sup>b</sup>, Mohamed Lamine Diao<sup>a</sup>, Sidy Diallo<sup>c</sup>, Saer Diop<sup>a</sup>, Mamadou Ka Diallo<sup>a</sup>, Moustapha Diedhiou<sup>d</sup>, Mohamed Lamine Fall<sup>d</sup>, Philippe Manyacka Ma Nyemb<sup>a</sup>, Ibrahima Konaté<sup>a</sup>

<sup>a</sup> Department of Surgery, Gaston Berger University, Saint-Louis, Senegal

<sup>b</sup> Department of Infectious Diseases, Gaston Berger University, Saint-Louis, Senegal

<sup>c</sup> Department of Hepato-Gastro-Enterology, Gaston Berger University, Saint-Louis, Senegal

<sup>d</sup> Department of Anaesthesiology, Gaston Berger University, Saint-Louis, Senegal

### ARTICLE INFO

#### Keywords:

Hepatic abscess  
Amoebic  
Pyogenic  
Surgery  
Laparoscopy  
Infection

### ABSTRACT

**Background:** Liver abscess is a common cause of intra-abdominal infection and its treatment depends on the presentation. Laparoscopy, in addition to its classic benefits, has particular advantages in the management of liver abscess but its role is not well defined and studies done in that field are heterogenous. The objective of this systematic review is to evaluate the efficacy of laparoscopic surgery in the management of liver abscess.

**Methods:** We realized a systematic review and meta-analysis including studies published in the 20 last years. The primary outcome was the pooled prevalence of recurrent or residual liver abscess after laparoscopic treatment.

**Results:** We retrieved 190 studies regarding laparoscopic surgery in liver abscess and 17 studies were included in the quantitative and qualitative synthesis. A total of 608 patients was included and 299 of them (49.1%) were treated by laparoscopic surgery. The indications were mainly failure of first line treatment (antibiotic treatment and/or percutaneous drainage and/or needle aspiration) and ruptured multiloculated, or caudate lobe liver abscess. The surgical gesture performed was laparoscopic drainage in all studies. The post-operative rate of recurrent or residual liver abscess after treatment by laparoscopy was 4.22% (95% CI: 2.29–7.07).

**Conclusions:** This systematic review showed that laparoscopic drainage had a considerable place in the management. The post-operative rate of recurrence was low with no mortality suggesting that laparoscopy is safe and feasible for liver abscess management.

### 1. Introduction

Liver abscess is a common cause of intra-abdominal infection characterised by an encapsulated suppurative collection inside the hepatic parenchyma [1]. Pyogenic liver abscesses are more found in developed countries while amoebic abscess are endemic in tropical areas where it is considered by some authors as a neglected disease [2,3]. The occurrence of rupture is the main complication with a prevalence of up to 26% [4].

The treatment depends on the presentation and different options exist. Antibiotics are the first line treatment and should always be used whatever the evolution stage. However, anti-biotherapy can be used alone for abscesses with small diameter [5]. In case of no improvement with medical treatment alone, percutaneous needle aspiration or catheter drainage are acceptable options with good success rate [6].

Surgery has its indications limited to ruptured liver abscess, particularly in the peritoneal cavity [7]. One major issue about open surgery concerned its higher associated mortality rate [8,9].

Laparoscopy, in addition to its classic benefits, has particular advantages in the management of liver abscess [5]. Laparoscopic surgical drainage can be used both for unruptured and ruptured liver abscess [10,11] It can also allow to realize a surgical drainage and at the same time can also treat associated diseases (e.g. cholecystectomy or common bile duct exploration for biliary lithiasis) [12].

Nevertheless, the place of laparoscopic surgery is not well defined and studies done in that field are heterogenous. With these potential advantages, the objective of this systematic review and meta-analysis is to evaluate the efficacy of laparoscopic surgery in the management of liver abscess.

\* Corresponding author.

E-mail address: [abdourahmane.ndong@ugb.edu.sn](mailto:abdourahmane.ndong@ugb.edu.sn) (A. Ndong).

<https://doi.org/10.1016/j.amsu.2022.103308>

Received 6 December 2021; Received in revised form 19 January 2022; Accepted 23 January 2022

Available online 31 January 2022

2049-0801/© 2022 The Authors. Published by Elsevier Ltd on behalf of IJS Publishing Group Ltd. This is an open access article under the CC BY-NC-ND license

(<http://creativecommons.org/licenses/by-nc-nd/4.0/>).

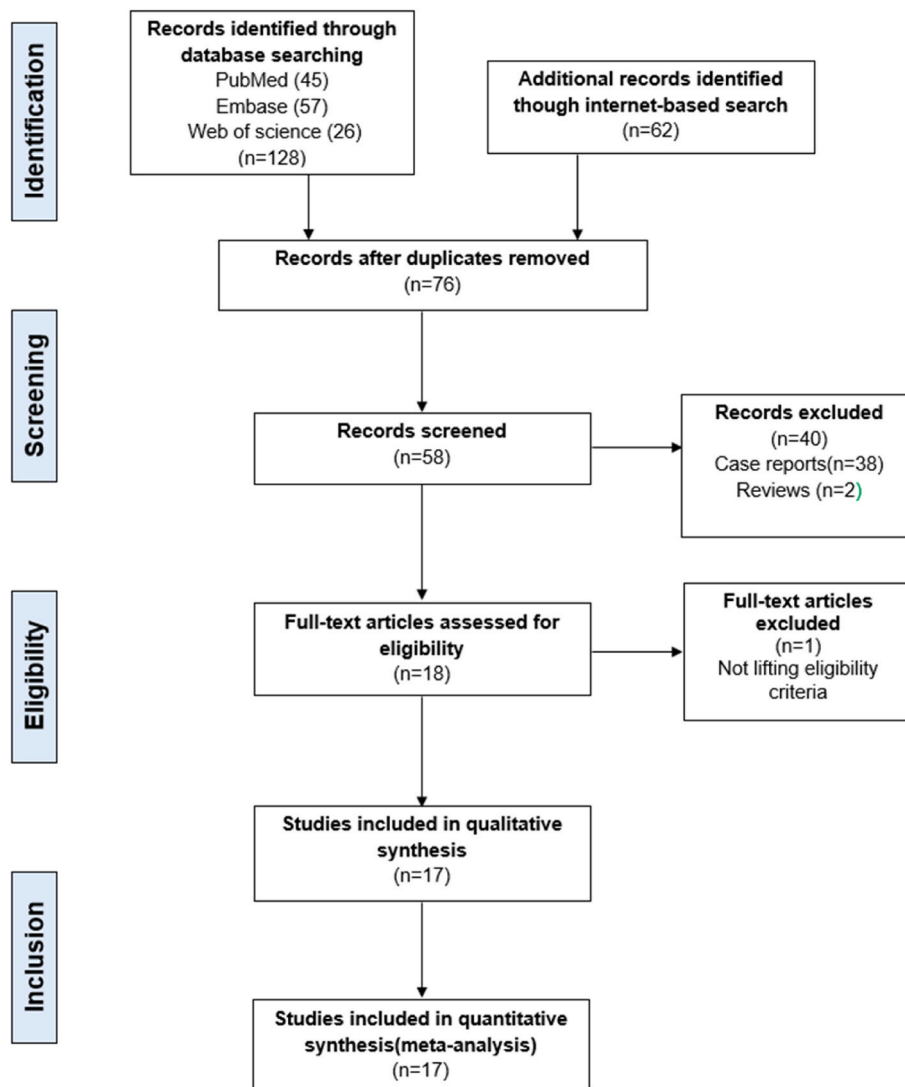


Fig. 1. PRISMA flow diagram illustrating the search process and study selection.

## 2. Methods

We realized a systematic review and meta-analysis to determine the efficacy of laparoscopic surgery for liver abscess. The work has been reported in line with the PRISMA criteria [13]. The systematic review was registered in the Research Registry database for systematic reviews (<https://www.researchregistry.com/>) with unique number: reviewregistry1183.

### 2.1. Search strategy

A search of the following online databases and search engines were performed (PubMed/Medline, Web of Science and Embase) completed by an internet-based search. The keywords used were “liver OR hepatic” AND “abscess\*” AND “laparoscop\*”. All references of included articles were manually screened to find relevant articles.

The PRISMA flow chart of search is shown in Fig. 1 [13].

### 2.2. Study selection

The inclusions criteria were:

- Patients: aged more than 15 years with liver abscess whatever the presentation (ruptured or unruptured);

-Interventions: laparoscopy;

-Comparison: none;

-Outcomes: post-operative rate of recurrent or residual abscess during the follow-up;

-Study type: randomized clinical trial or non-randomized clinical series or prospective or retrospective cohort series with more than 5 patients, published in the 20 last years (between 2000 and 2020) in English language.

Conference abstracts were screened and included if data needed were available. Letters, reviews, case reports and duplicated studies were excluded. Where studies reported other method of treatment (open surgery, percutaneous drainage, needle aspiration, antibiotic treatment), only data pertaining to laparoscopic surgery was extracted. We excluded studies where the outcomes were unclear between patients managed with laparoscopy and others modalities. Last search was made the September 30<sup>th</sup> 2020.

### 2.3. Quality assessment

Newcastle-Ottawa-Scale (NOS) (selection and outcome criteria) was used for quality assessment of included studies [14]. A NOS score of 6 was considered as good quality, while 5 or less score as poor quality.

Study	Risk of bias domains							Overall
	D1	D2	D3	D4	D5	D6	D7	
Iqbal 2001 [15]	⊖	⊗	⊕	⊕	⊕	⊕	⊕	⊖
Wang 2004 [16]	⊖	⊗	⊕	⊕	⊕	⊕	⊕	⊖
Channa 2005 [23]	⊖	⊗	⊕	⊕	⊗	⊕	⊗	⊗
Rajasekar 2006 [24]	⊖	⊗	⊕	⊕	⊕	⊗	⊕	⊗
Yeh 2007 [27]	⊖	⊗	⊕	⊕	⊕	⊗	⊕	⊗
Tu 2011 [12]	⊖	⊗	⊕	⊕	⊕	⊕	⊕	⊖
Tan 2013 [17]	⊖	⊗	⊕	⊕	⊗	⊕	⊗	⊗
Krishnan 2013 [25]	⊕	⊕	⊕	⊕	⊕	⊗	⊕	⊕
Cioffi 2014 [28]	⊖	⊗	⊕	⊕	⊕	⊖	⊕	⊗
Ekwunife 2015 [18]	⊖	⊗	⊕	⊕	⊗	⊖	⊗	⊗
Groeschl 2016 [19]	⊕	⊕	⊕	⊕	⊕	⊗	⊕	⊕
Saha 2016 [10]	⊖	⊗	⊕	⊕	⊕	⊕	⊕	⊖
Dhamodharan 2018 [20]	⊕	⊕	⊕	⊕	⊕	⊕	⊕	⊕
Dhir 2019 [21]	⊖	⊗	⊕	⊕	⊕	⊗	⊕	⊗
Chitrambalam 2019 [26]	⊕	⊕	⊕	⊕	⊕	⊕	⊕	⊕
Minh 2019 [11]	⊕	⊕	⊕	⊕	⊗	⊖	⊗	⊗
Mogahed 2020 [22]	⊕	⊕	⊕	⊕	⊕	⊖	⊕	⊕

Domains:  
 D1: Bias due to confounding.  
 D2: Bias due to selection of participants.  
 D3: Bias in classification of interventions.  
 D4: Bias due to deviations from intended interventions.  
 D5: Bias due to missing data.  
 D6: Bias in measurement of outcomes.  
 D7: Bias in selection of the reported result.

Judgement  
 ⊗ Serious  
 ⊖ Moderate  
 ⊕ Low

Fig. 2. Bias assessment for included studies using ROBINS-I tool.

2.4. Bias assessment

The Cochrane tool for Risk Of Bias In Non-randomized Studies of Interventions (ROBINS-I) assessed the risk of bias [15,16]. The ROBVIS tool was used to create risk-of-bias plots [17]. Each publication was classified as:

- Low risk of bias (the study is comparable to a well-performed randomized trial with regard to this domain);
- Moderate risk of bias (the study is sound for a non-randomized study with regard to this domain but cannot be considered comparable to a well-performed randomized trial);
- Serious risk of bias (the study has some important problems in this domain);
- Critical risk of bias (the study is too problematic in this domain to provide any useful evidence on the effects of intervention); and
- No information on which to base a judgement about risk of bias for this domain [16].

2.5. Data extraction

The extracted parameters were: type and year of studies, number of

patients, age and gender of patients, indications and results (mortality, complications, failure or success of treatment) of laparoscopic surgery. The primary outcome was the rate of recurrent or residual abscess during the follow-up.

2.6. Data analysis

Statistical analysis was done with Medcalc 14.8.1 software. A meta-analysis was performed to determine the pooled prevalence with the 95% confidence interval (CI) of recurrent or residual liver abscess after treatment by laparoscopic surgery. Heterogeneity between studies was tested by I<sup>2</sup> test. A random-effects model was used when I<sup>2</sup> > 50%; and a fixed-effects model when I<sup>2</sup> ≤ 50%.

The quality of this systematic review was assessed using AMSTAR 2 criteria [18]. The mean AMSTAR 2 score was estimated to 45%.

3. Results

We retrieved 190 studies regarding laparoscopic surgery in liver abscess at PubMed/Medline, Web of Science, Embase and internet-based search. After removing duplicates, 76 studies remained. Out of 76 remained articles, 18 were excluded after review of their titles and

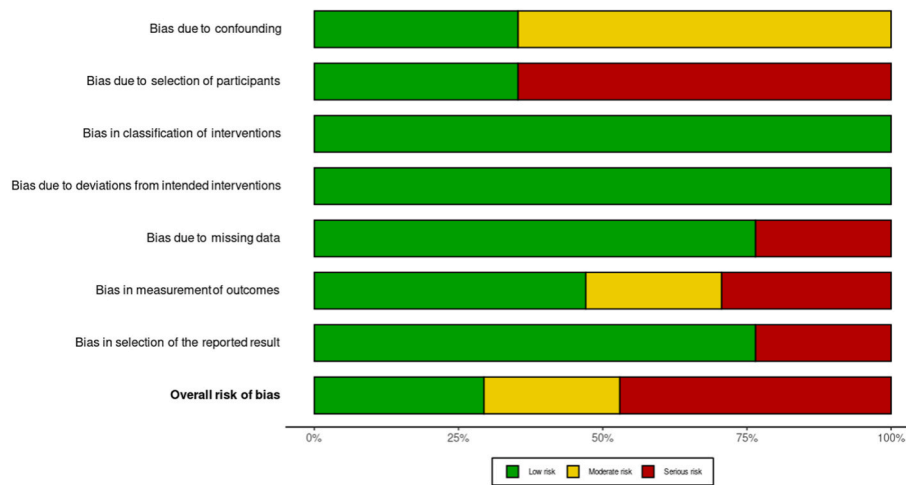


Fig. 3. Summary plot of Bias assessment for included studies using ROBINS-I tool.

Table 1

Characteristics of the different included studies.

Study	Country	Study type	Mean age	Gender M/F	Number of patients	Number of patients with laparoscopy
Iqbal 2001 [22]	Pakistan	Prospective cohort	34.4	25/1	58	11
Wang 2004 [23]	Taiwan	Retrospective comparative	57	10/8	23	18
Channa 2005 [28]	Pakistan	Cohort	34.8 ± 15.81	10/2	12	12
Rajasekar 2006 [29]	India	Cohort	36	9/1	10	10
Yeh 2007 [31]	Taiwan	Retrospective cohort	Not available (NA)	NA	18	8
Tu 2011 [12]	China	Retrospective comparative	57.5 (37–69)	5/8	31	13
Tan 2013 [19]	Singapore	Retrospective Comparative	59.2 ± 17.7	11/7	85	18
Krishnan 2013 [30]	Singapore	Retrospective comparative	NA	NA	99	21
Cioffi 2014 [32]	Italy	Cohort	51.5(41–75)	7/3	10	10
Ekunife 2015 [24]	Nigeria	Retrospective cohort	(31–54)	3/5	8	8
Groeschl 2016 [25]	USA	Retrospective comparative	58.5	NA	54	26
Saha 2016 [10]	India	Prospective cohort	39.5(31–50)	10/2	12	12
Dhamodharan 2018 [20]	India	Prospective cohort	47.7 ± 9.3	39/1	40	40
Dhir 2019 [26]	India	Cohort	NA	7/1	8	8
Chitrabalam 2019 [21]	India	Randomized controlled trial	55.23	22/8	60	30
Minh 2019 [11]	Vietnam	Retrospective cohort	53.3 ± 15.3	21/11	32	32
Mogahed 2020 [27]	Egypt	Retro-prospective Comparative	54.5(34–65)	20/28	48	22

Table 2

Quality assessment of the different included studies according to the Newcastle-Ottawa Scale [14].

Study	Selection <sup>a</sup>	Outcome <sup>b</sup>	Score
Iqbal 2001 [22]	**	***	5/6
Wang 2004 [23]	**	***	5/6
Channa 2005 [28]	**	***	5/6
Rajasekar 2006 [29]	**	*	3/6
Yeh 2007 [31]	**	*	3/6
Tu 2011 [12]	**	***	5/6
Tan 2013 [19]	***	***	6/6
Krishnan 2013 [30]	**	*	3/6
Cioffi 2014 [32]	**	**	4/6
Ekunife 2015 [24]	**	**	4/6
Groeschl 2016 [25]	**	*	3/6
Saha 2016 [10]	**	***	5/6
Dhamodharan 2018 [20]	***	***	6/6
Dhir 2019 [26]	**	*	3/6
Chitrabalam 2019 [21]	***	***	6/6
Minh 2019 [11]	**	**	4/6
Mogahed 2020 [27]	**	**	4/6

<sup>a</sup> The maximum score possible was 3 stars.

<sup>b</sup> Criteria used to assess outcome were evaluation of recurrent or residual liver abscess in the follow-up. The maximum score possible was 3 stars.

abstracts. Finally, 58 studies were screened and 17 studies were included in the systematic review and meta-analysis. The PRISMA flow chart is represented at Fig. 1. There was 13 published articles and 4 conference abstracts. We identified 10 cohort studies, 6 comparative studies and 1 randomized controlled trial.

Using the ROBINS tool for bias assessment, 5 studies were considered as low risk [22,23,25,28,29], 4 studies with moderate risk [10,12,18,19] and 8 studies with serious risk [11,20,21,24,26,27,30,31]. The summary plot of bias assessment is represented at Figs. 2 and 3.

The quality assessment of the different included studies according to the Newcastle-Ottawa Scale is reported at Table 2. Only 3 studies have been considered as good quality following NOS score [19–21].

The studies and patients' characteristics are detailed in Table 1. A total of 608 patients was included in these studies. The mean age was 46.5 years. Out of these patients, 299 (49.1%) were treated by laparoscopic surgery.

The indications of laparoscopic surgery for liver abscess in the different studies were unique or multiple. These indications were:

- Failure of first line treatment (antibiotic treatment and/or percutaneous drainage and/or needle aspiration) in 8 studies [19,20,22–27];
- Ruptured liver abscess in 5 studies [11,19,22,28,29];
- First line treatment of unruptured liver abscess in 3 studies [10,21,30];
- Contraindications of percutaneous drainage in 1 studies [23].
- Large multiloculated liver abscess in 3 studies [27,31,32];

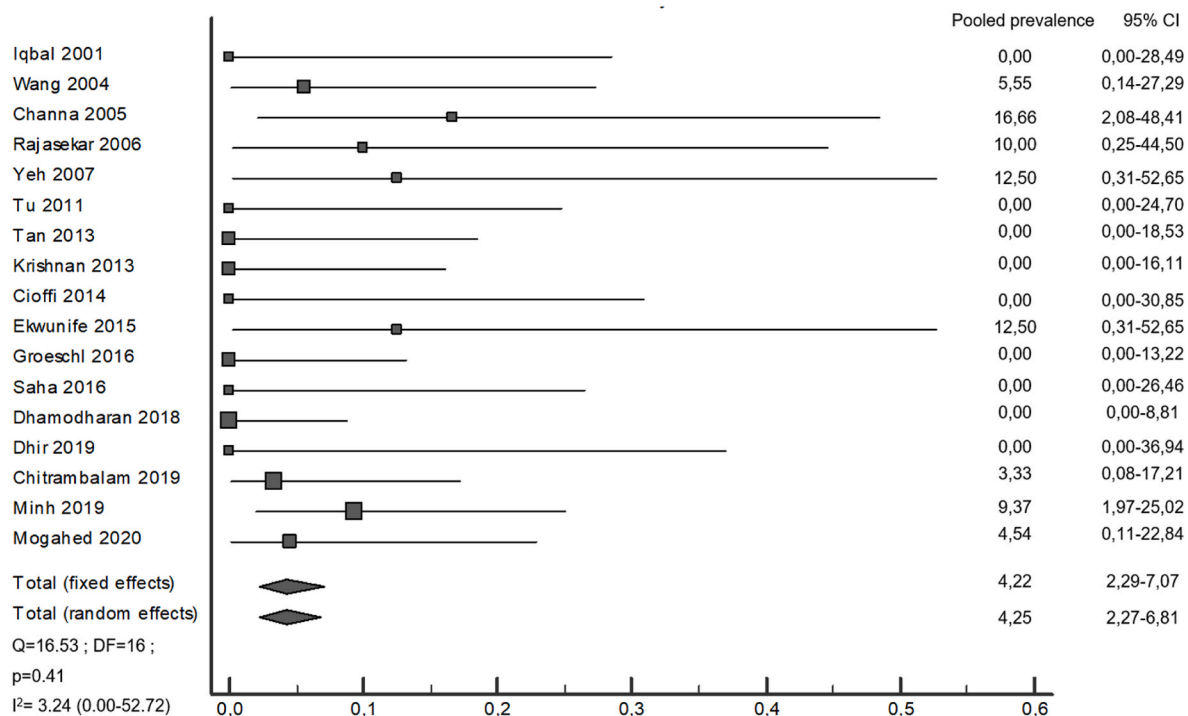


Fig. 4. Meta-analysis estimating post-operative rate of recurrent or residual liver abscess after treatment by laparoscopy.

- Liver abscess located at caudate lobe in 1 study [26];
- Associated biliary disease (lithiasis or stricture) in 2 studies [12,32];

The surgical gesture performed was laparoscopic drainage in all studies. In addition, cholecystectomy was associated in 3 studies, common bile duct exploration and hepatectomy in 1 study each.

The post-operative rate of recurrent or residual liver abscess after treatment by laparoscopy was 4.22% (95% CI: 2.29–7.07) with a fixed effect model ( $I^2 = 3.24$ ; 95% CI: 0.00–52.72). The meta-analysis is represented at the forest plot at Fig. 4. There was no reported death in all studies. The indications, surgical gestures and complications are detailed at Table 3.

#### 4. Discussion

Laparoscopy has seen many technological advances since its advent, allowing its indications to be extended [33]. Its advantages in reduction of morbidity, suggest its application in the treatment of liver abscess.

The first-line treatment of liver abscesses remains antibiotic therapy associated or not with ultrasound or CT guided drainage depending on the size. However, in some situations, drainage may be difficult to realize. In these cases, laparoscopic approach has a particular value by achieving efficient minimally invasive treatment.

Our systematic review showed that, out of 17 studies including patients with liver abscess, 299 patients were treated with laparoscopy. It found that the main indication for laparoscopy was failure of first-line treatment (antibiotic treatment and/or percutaneous drainage and/or needle aspiration) [19,20,22–27]. In fact, laparoscopy is an effective alternative to open surgery by allowing evacuation of the pus without laparotomy.

Another indication of laparoscopy found in our review was multiloculated or caudate lobe liver abscess [26,27,31,32]. The caudate lobe represents an infrequent localization but is associated with a greater risk of rupture [26]. Its particular location is more difficult to access by external drainage. Hence, laparoscopy allows safer control of the gesture and minimizes the risk of recurrence or incomplete evacuation.

In several studies of ruptured liver abscesses with peritonitis, open

surgery was the unique approach used. However, our review has shown that for ruptured liver abscesses, laparoscopy is a good indication [11, 19,22,28,29]. It realizes good control of infection in a minimally invasive manner [30]. It allows to evacuate the pus and treat etiologic conditions if it is biliary lithiasis by realizing cholecystectomy in the same intervention [12,32]. However, performing the procedure requires a good mastery of the laparoscopic hepato-biliary surgical technique. As liver abscesses are more common in low-middle income countries, it would be important to develop these minimally invasive techniques that have shown their potential opportunities in resource-limited settings [34].

In all studies, the procedure performed by laparoscopy was surgical drainage associated in some cases with cholecystectomy, common bile duct exploration, or hepatectomy. The meta-analysis showed a pooled postoperative rate of recurrent or residual liver abscess after treatment by laparoscopy of 4.22% (95% CI: 2.29–7.07). Besides, there was no reported death. This rate of post operative complications is lower or comparable to other studies evaluating others approach as catheter drainage or open surgery [6,12,19]. This suggest the efficacy and safety of laparoscopy in the management of liver abscesses.

#### 5. Strengths and limitations

This systematic review appraised the literature in 20 years with 299 patients. It estimated the post-operative rate of liver abscess recurrence after laparoscopic treatment suggesting that it is a safe and effective approach.

However, there were some limits. It included 17 studies but only one was a randomized controlled trial. The risk of bias was significant and the meta-analysis comparing external drainage or open surgery to laparoscopic surgery was not possible.

#### 6. Conclusion

This systematic review showed that laparoscopic drainage had a considerable place in the management. The mains indications are failure of the first-line treatment and ruptured, multiloculated, or caudate lobe

**Table 3**  
Indications, surgical gestures and complications of laparoscopic surgery for liver abscess (LA).

Study	Indications	Gestures	Complications
Iqbal 2001 [22]	Failure of percutaneous drainage (PD) Ruptured LA	Laparoscopic drainage	0
Wang 2004 [23]	Failure of PD and antibiotic treatment Contraindications to PD	Laparoscopic drainage	Residual/ recurrent abscess: 1
Channa 2005 [28]	Ruptured LA (peritonitis)	Laparoscopic drainage	Residual/ recurrent abscess: 2
Rajasekar 2006 [29]	Ruptured LA with organ failure	Laparoscopic drainage	Wound infection: 2 Residual/ recurrent abscess: 1 Conversion: 1
Yeh 2007 [31]	Multilobulated LA	Laparoscopic drainage + cholecystectomy	Residual/ recurrent abscess: 1
Tu 2011 [12]	Associated biliary lithiasis Biliary stricture	Laparoscopic drainage + cholecystectomy and/or CBD exploration Hepatectomy	Biliary leakage: 1 Hydrothorax: 1
Tan 2013 [19]	Ruptured LA Failure of antibiotic treatment	Laparoscopic drainage	Biliary leakage: 1
Krishnan 2013 [30]	Unruptured LA	Laparoscopic drainage	0
Cioffi 2014 [32]	Large multilobulated LA Associated biliary lithiasis	Laparoscopic drainage + cholecystectomy	0
Ekwunife 2015 [24]	Failure of antibiotic treatment	Laparoscopic drainage	Residual/ recurrent abscess: 1
Groeschl 2016 [25]	Failure of PD and antibiotic treatment	Laparoscopic drainage	Conversion: 1
Saha 2016 [10]	Unruptured LA	Laparoscopic drainage	0
Dhamodharan 2018 [20]	Failure of PD	Laparoscopic drainage	Wound infection: 4
Dhir 2019 [26]	Caudate lobe LA Failure of PD	Laparoscopic drainage	0
Chitrabalam 2019 [21]	Unruptured	Laparoscopic drainage	Residual/ recurrent abscess: 1
Minh 2019 [11]	Ruptured LA (peritonitis)	Laparoscopic drainage	Residual/ recurrent abscess: 3 Pneumoniae: 2/ Bleeding: 1 Wound infection: 1/Bile duct leak: 1
Mogahed 2020 [27]	Failure of antibiotic treatment and PD Complex LA (diameter $\geq$ 5 cm, multilobular)	Laparoscopic drainage	Residual/ recurrent abscess: 1

liver abscess. Besides the evacuation of the pus, laparoscopy also allows to realize a cholecystectomy and/or common bile duct exploration when biliary lithiasis is the aetiology. The post-operative rate of recurrence was low with no mortality suggesting that laparoscopy is safe and feasible for liver abscess management. To improve the level of evidence, further randomized controlled studies should be carried out with a suitable number of patients.

## Provenance and peer review

Not commissioned, externally peer-reviewed.

## Sources of funding

None.

## Ethical approval

Not needed (systematic review).

## Research registration Unique Identifying number (UIN)

- Name of the registry: the Research Registry database for systematic reviews(<https://www.researchregistry.com/>)
- Unique Identifying number or registration ID: reviewregistry1183
- Hyperlink to your specific registration (must be publicly accessible and will be checked):

## Author contribution

A Ndong, AC Diallo, JN Tendeng, A Dieye, conceived the study, collected, analysed data, A Ndong, AC Diallo, JN Tendeng, A Dieye, M L Diao, S Diallo, S Diop, MK Diallo and M Diedhiou drafted the manuscript. M L Fall, P M Ma Nyemb and I Konaté edited and reviewed the manuscript.

## Guarantor

A Ndong.

## Declaration of competing interest

None.

## Appendix A. Supplementary data

Supplementary data to this article can be found online at <https://doi.org/10.1016/j.amsu.2022.103308>.

## References

- [1] M.G. Mavilia, M. Molina, G.Y. Wu, The evolving nature of hepatic abscess: a review, *J. Clin. Translat. Hepatol.* 4 (2) (2016 Jun 28) 158–168.
- [2] J.E. Kurland, O.S. Brann, Pyogenic and amebic liver abscesses, *Curr. Gastroenterol. Rep.* 6 (4) (2004 Aug 1) 273.
- [3] T. Kumanan, V. Sujaritha, N. Sreeharan, Amoebic liver abscess: a neglected tropical disease, *Lancet Infect. Dis.* 20 (2) (2020 Feb 1) 160–162.
- [4] A. Ndong, J.N. Tendeng, N.A. Ndoye, M.L. Diao, A. Dieye, A.C. Diallo, et al., Predictive risk factors for liver abscess rupture: a prospective study of 138 cases, *Arch. Clin. Gastroenterol.* 6 (1) (2020 Jan 25) 1–5.
- [5] M.C. Trillos-Almanza, J.C. Restrepo Gutierrez, How to manage: liver abscess, *Frontline Gastroenterol.* 12 (2020 Jun 26) 225–231, [flgastro-2019-101240](https://doi.org/10.1136/flgastro-2019-101240).
- [6] Y.-L. Cai, X.-Z. Xiong, J. Lu, Y. Cheng, C. Yang, Y.-X. Lin, et al., Percutaneous needle aspiration versus catheter drainage in the management of liver abscess: a systematic review and meta-analysis, *HPB* 17 (3) (2015 Mar) 195–201.
- [7] M. Bhatia, M. Ali, Ruptured liver abscess: analysis of 50 cases, *Med. J. Dr DY Patil Univ.* 10 (6) (2017 Jan 11) 532.
- [8] A.S. Memon, F.G. Siddiqui, H.A. Memon, S.A. Ali, Management of ruptured amoebic liver abscess: 22-years experience, *J. Ayub Med. Coll. Abbottabad* 22 (2) (2010 Jun) 96–99.
- [9] R.N. Priyadarshi, V. Prakash, U. Anand, P. Kumar, A.K. Jha, R. Kumar, Ultrasound-guided percutaneous catheter drainage of various types of ruptured amebic liver abscess: a report of 117 cases from a highly endemic zone of India, *Abdom Radiol. (NY)* 44 (3) (2019) 877–885.
- [10] S. Saha, K. Gedam, Role of Laparoscopic Drainage of Liver Abscess—A Recent Trend, 2016.
- [11] L.Q. Minh, L.C. Tri, V.T. Minh Thuc, H.Q. Huy, H.H. Phuong, N.Q. Vinh, Laparoscopic surgery for intra-abdominal ruptured liver abscess: a study of 32 cases, 2019, *World J. Surg. Surgical Res.* 2 (2019) 1144.

- [12] J.-F. Tu, X.-F. Huang, R.-Y. Hu, H.-Y. You, X.-F. Zheng, F.-Z. Jiang, Comparison of laparoscopic and open surgery for pyogenic liver abscess with biliary pathology, *World J. Gastroenterol.* 17 (38) (2011 Oct 14) 4339–4343.
- [13] M.J. Page, J.E. McKenzie, P.M. Bossuyt, I. Boutron, T.C. Hoffmann, C.D. Mulrow, et al., The PRISMA 2020 statement: an updated guideline for reporting systematic reviews, *Int. J. Surg.* 88 (2021 Apr 1) 105906.
- [14] G.A. Wells, B. Shea, D. O'Connell, J. Peterson, V. Welch, M. Losos, et al., *The Newcastle-Ottawa Scale (NOS) for Assessing the Quality of Nonrandomised Studies in Meta-Analyses*, 2000. Oxford.
- [15] P. Jüni, Y. Loke, T. Pigott, C. Ramsay, D. Regidor, H. Rothstein, et al., Risk of bias in non-randomized studies of interventions (ROBINS-I): detailed guidance, *Br. Med. J.* (2016).
- [16] J.A. Sterne, M.A. Hernán, A. McAleenan, B.C. Reeves, J.P. Higgins, Assessing risk of bias in a non-randomized study, *Cochrane Handbk. Syst. Rev. Interv.* (2019) 621–641.
- [17] L.A. McGuinness, J.P. Higgins, Risk-of-bias VISualization (robvis): an R package and Shiny web app for visualizing risk-of-bias assessments, *Res. Synth. Methods* 12 (1) (2021) 55–61.
- [18] B.J. Shea, B.C. Reeves, G. Wells, M. Thuku, C. Hamel, J. Moran, et al., AMSTAR 2: a critical appraisal tool for systematic reviews that include randomised or non-randomised studies of healthcare interventions, or both, *BMJ* 358 (2017).
- [19] L. Tan, H.J. Zhou, M. Hartman, I.S. Ganpathi, K. Madhavan, S. Chang, Laparoscopic drainage of cryptogenic liver abscess, *Surg. Endosc.* 27 (9) (2013 Sep) 3308–3314.
- [20] S.R. Dhamodharan, J. Christeena Indrani, An innovative technique of laparoscopic drainage of liver abscess, *Int. J. Dent. Med. Sci. Res.* 2 (9) (2018) 1–11.
- [21] S J T.G. Chitrambalam, M. Pethuraj, P. Anguraj, Study on therapeutic effectiveness of laparoscopic drainage and image guided pigtail catheter drainage in the treatment of liver abscess: a randomised controlled trial, *Int. Surg. J.* 6 (7) (2019 Jun 29) 2417–2422.
- [22] J. Iqbal, S.A. Yamin, Laparoscopic drainage of liver abscess, *J. Coll. Phys. Surg. Pak.* 11 (10) (2001) 636–638.
- [23] W. Wang, W.-J. Lee, P.-L. Wei, T.-C. Chen, M.-T. Huang, Laparoscopic drainage of pyogenic liver abscesses, *Surg. Today* 34 (4) (2004 Apr 1) 323–325.
- [24] C.N. Ekwunife, O. Okorie, O. Nwobe, Laparoscopy may have a role in the drainage of liver abscess: early experience at Owerri, Nigeria, *Niger. J. Surg.* 21 (1) (2015 Jun) 35–37.
- [25] Groeschl R, Baker E, Bertens K, Siddiqui I, Tee M, Helton WS, et al. Both laparoscopic and open surgical drainage are highly effective in the treatment of refractory pyogenic liver abscess: a multi-institutional analysis. *HPB.* 2016;18. ((Groeschl R.; Tee M.) Mayo Clinic, United States);e244.
- [26] Dhir U, Ghuman S, Singhvi S, Rawat S. Caudate lobe liver abscess: laparoscopic drainage the best approach. *HPB.* 2019;21. ((Dhir U.; Singhvi S.; Rawat S.) Department of Surgical Gastroenterology and Liver Transplantation, Sir Ganga Ram Hospital, India);S385.
- [27] M.M. Mogahed, A.A. Zytoon, B. Eysa, M. Manaa, W. Abdellatif, Laparoscopic vs open drainage of complex pyogenic liver abscess, *World J. Laparosc. Surg.* 13 (1) (2020) 11–15.
- [28] A. Channa, A. Siddiqui, Laparoscopic drainage of ruptured liver abscess, *J. Surg. Pak.* 10 (1) (2005) 36–38.
- [29] A. Rajasekar, Laparoscopic drainage OF RUPUTRED liver abscess: P21. 05, *Off. J. Int. HPB* 8 (2006).
- [30] Krishnan SG. Laparoscopic drainage of cryptogenic liver abscess as the first line option. *HPB.* 2013;15. ((Krishnan S.G.) National University Hospital, Singapore, Singapore);33.
- [31] T.-S. Yeh, Y.-P. Ho, Y.-Y. Jan, M.-F. Chen, Efficacy of color sonography and harmonic scalpel in laparoscopic management of multiple/lobulated liver cysts and abscesses, *Hepato-Gastroenterology* 54 (74) (2007 Mar) 485–488.
- [32] L. Cioffi, A. Belli, P. Limongelli, G. Russo, M. Arnold, A. D'Agostino, et al., Laparoscopic drainage as first line treatment for complex pyogenic liver abscesses, *Hepato-Gastroenterology* 61 (131) (2014 May) 771–775.
- [33] M.L. Cissé, A.O. Touré, J.N. Tendeng, M. Seck, M. Thiam, M.L. Guèye, et al., Apport de la laparoscopie devant les urgences abdominales au CHU A Le Dantec de Dakar, à propos de 144 cas, *Le J. de Coelio-chirurgie* 95 (2015) 1–4.
- [34] A. Ndong, M. Dia, J. Tendeng, O. Thiam, A. Diallo, A. Diouf, et al., Limitations and challenges of laparoscopic surgery in a low-income country: example of the Gaston Berger Teaching Hospital of Saint-Louis (Senegal), *J. Surg. Simulat.* 8 (2021 Jun 11) 14–17.