

Case Report

Huge Primary Parasitic Leiomyoma in a Postmenopausal Lady: A Rare Presentation

Nkencho Osegi,¹ E. Yilaiba Oku,² C. Stanley Uwaezuoke,²
K. Timothy Alawode,³ and S. Adeniyi Afolabi ¹

¹Department of Obstetrics and Gynaecology, Federal Medical Centre, Yenagoa, Bayelsa State, Nigeria

²Department of Surgery, Federal Medical Centre, Yenagoa, Bayelsa State, Nigeria

³Department of Pathology, Federal Medical Centre, Yenagoa, Bayelsa State, Nigeria

Correspondence should be addressed to S. Adeniyi Afolabi; niyiafolabi2014@gmail.com

Received 25 December 2018; Accepted 3 March 2019; Published 1 April 2019

Academic Editor: Julio Rosa e Silva

Copyright © 2019 Nkencho Osegi et al. This is an open access article distributed under the Creative Commons Attribution License, which permits unrestricted use, distribution, and reproduction in any medium, provided the original work is properly cited.

Although uterine myomas are the most common benign tumours of the female pelvis in the reproductive age group, they rarely grow in menopausal women. Parasitic fibroids without prior history of laparoscopic myomectomy are even a rarer presentation particularly in menopausal women. The case presented is a 58-year-old grand-multiparous, menopausal lady with progressive abdominal swelling of three-year duration. She had excision of a huge parasitic fibroid attached to omentum. She had partial omentectomy, total abdominal hysterectomy, and bilateral salpingo-oophorectomy. The parasitic fibroid mass weighed 5.2kg and histopathology confirmed leiomyoma uteri with cystic degeneration and lymph nodes with reactive lymphoid hyperplasia. She had uneventful postoperative recovery and follow-up has so far been uneventful.

1. Introduction

Uterine fibroids are the most common tumours of the female genital tract in women within the reproductive age and it has been documented that they occur in over 70% of women by the onset of menopause [1]. Chief among the risk factors is race and it is more common in women of African ancestry. They are benign monoclonal tumours that arise from the uterine smooth muscle tissue. The initiating events for fibroid genesis remain speculative. The cells proliferate at a modest rate and their growth is dependent on the ovarian steroids oestrogen and progesterone and therefore most fibroids shrink after menopause [2].

Spontaneous parasitic fibroids are a rare subset of subserous fibroids that become adherent to other structures, obtain their blood supply from such structures, and usually do not retain vascular connection with the uterus [3]. Most reported cases are iatrogenic and are linked to unintentional seeding of the fragments during previous laparoscopic myomectomy using the morcellator [4–7]. The true incidence of parasitic fibroid is unknown, but some authors have

reported an incidence of 0.9% in women with previous laparoscopic myomectomy [8]. We report a rare case of spontaneous parasitic leiomyoma occurring in a menopausal lady without history of previous operation.

2. Case Presentation

A 58-year-old menopausal woman, para 6+⁰, presented to the gynecology clinic with progressive abdominal swelling of three-year duration. There was no associated pain, vaginal bleeding/discharge, weight loss, gastrointestinal symptoms, or respiratory difficulties. She was eight years post-menopause. She was a known diabetic on oral medication and had been previously managed medically for uterine fibroids prior to menopause. She had no history of previous surgery. She had no family history of malignancy: breast, ovarian, or endometrial.

Examination revealed a markedly distended abdomen that moved with respiration. An abdominopelvic mass that extended to the xiphisternum was palpated. It was firm, nontender, and slightly mobile in the transverse plane. Other

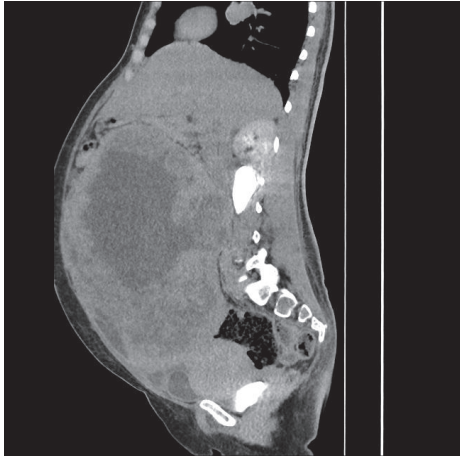


FIGURE 1: Presurgical evaluation showing the sagittal slice of the abdominopelvic CT scan.

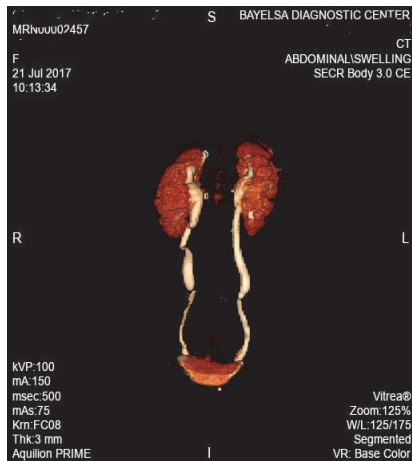


FIGURE 2: Presurgical evaluation outlining the kidneys, ureters, and bladder on contrast CT scan.

organs were not palpable and there was no demonstrable ascites.

Haemogram, electrolytes, urea, creatinine, and liver function tests were all normal. Serum Ca-125 was 21.3u/ml. Urinalysis showed no abnormality. Chest X-ray and ECG were normal. Abdominopelvic ultrasound scan showed a bulky nongravid anteverted uterus with multiple uterine fibroids with degenerative changes and a mid-line echo. A huge mass extending up to the epigastrium with mixed echogenicity and areas of cystic changes was seen. The liver, gall bladder, spleen, pancreas, and kidneys were grossly normal without focal mass lesion. No ascites was seen. The ovaries were not visualized.

Abdominopelvic computerized tomographic scan with intravenous contrast (Figures 1 and 2) showed a large heterogeneous predominantly necrotic mass measuring about 22.4 x 16 x 25cm extending from the mid-pelvis to the level of the epigastric region, mild bilateral hydronephrosis

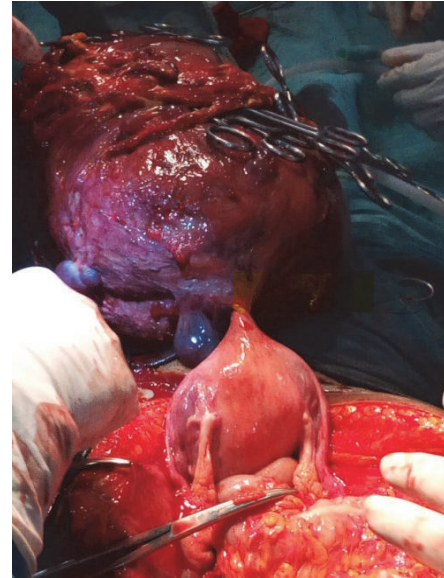

FIGURE 3: Intraoperative finding of a huge parasitic fibroid wrapped around and deriving its blood supply from the omentum.

due to compression of the mid-ureters by the abdominopelvic mass and mild ascites were noted.

She had exploratory laparotomy and findings at surgery were a huge mass with cystic and solid areas filling up the entire abdominal cavity up to the epigastrium pushing the bowels loops up and to the left (Figure 3). It derived its blood supply from the greater omentum to which it was attached with huge visible arteries and veins. Enlarged lymph nodes were noted in the gastrocolic ligament. The uterus had multiple myomas, but other structures (ovaries, fallopian tubes, liver, spleen, and intestines) were normal.

She had excision of the huge parasitic fibroid, partial omentectomy, total abdominal hysterectomy and bilateral salpingo-oophorectomy. The histology report (Figure 4) confirmed leiomyoma with cystic degeneration and lymph nodes with reactive lymphoid hyperplasia.

3. Discussion

Very rarely, a subserous fibroid may detach from the uterus to attach and receive its blood supply from other structures in the abdomen. When this occurs in a woman without previous history of surgery as in the case presented, it is the considered opinion of the authors that this should be regarded as a primary or spontaneous parasitic fibroid. Primary parasitic fibroids are a rare variant of subserous fibroids that often pose diagnostic dilemma with diagnosis made mostly during surgery and/or following histopathology assessment of the tumour [9].

Secondary or iatrogenic parasitic fibroids are the more common form of parasitic fibroids and are seen as a complication of previous myomectomy particularly following laparoscopy using morcellator. The literature on parasitic

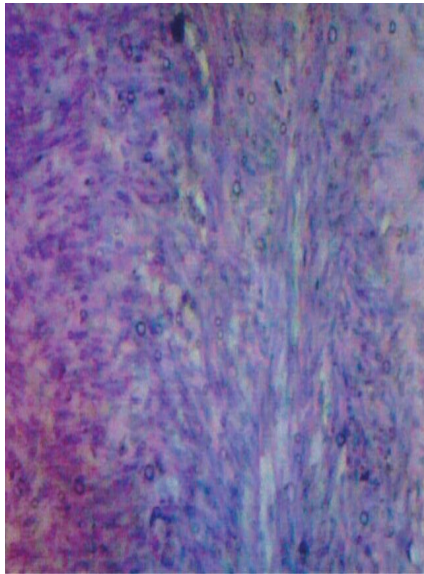


FIGURE 4: The microscopic slide of the histology.

fibroids is sparse and most reported cases have been linked to previous laparoscopic surgeries.

This case report of parasitic myoma occurred without history of prior abdominal procedure. Although this is not common, but few similar cases have been reported by others. Abdulwahid and associates reported parasitic fibroids in a 46-year-old lady without previous history of surgery [10]. This is similar to cases reported by Mushtaq [11] and Abdel-Gadir et al. [12]. Previous surgery (laparoscopy) may not be the most significant risk factor for development of parasitic fibroids as stated by many authors. Nehzat and colleagues [5] reported a series of parasitic fibroids and posited in their work that the greatest risk factor for development of parasitic myoma is the presence of uterine leiomyoma as found in the case presented.

Parasitic fibroids have been reported in premenopausal women without primary uterine fibroids; this however appears to be extremely rare in menopausal women as uterine fibroids seem to be a prerequisite for presence of parasitic fibroids in this group of women. The reason for this is unknown. This hypothesis is strengthened by Nappi and colleagues who reported parasitic leiomyoma coexisting with uterine leiomyoma in a 58-year-old postmenopausal woman similar to the case presented [13].

Although most parasitic myomas occur in the pelvis, index case was located on the greater omentum in the abdominal cavity which appears to be the most common source of blood supply. This finding is similar to what has been reported by other authors. More rare locations like the urethra and sigmoid colon have also been reported [14].

Clinical features of parasitic fibroids are usually nonspecific. Although they may be asymptomatic, symptoms when present depend on the size and location of the fibroids and are mostly due to pressure. Our patient presented with abdominal swelling. Management is usually surgical resection either via laparotomy or laparoscopy.

4. Conclusion

A high index of suspicion for parasitic fibroids should be entertained in women presenting with intraabdominal swelling with benign clinical features especially for those with previous history of uterine fibroids. This report also raises questions for further discourse and research on the growth and persistence of uterine fibroids after menopause.

Conflicts of Interest

The authors declare that they have no conflicts of interest.

Authors' Contributions

Osegi Nkencho carried out follow-up of patient, final review, and approval of the manuscript. E. Oku Yilaiba did follow-up of patient and review of the manuscript. C. Uwazuoke Stanley did follow-up of patient and review of the manuscript. K. Alawode Timothy analysed and reported histopathology sample. S. Afolabi Adeniyi did manuscript writing and literature review.

Supplementary Materials

Figure 5 shows the huge parasitic leiomyoma occupying the entire abdominal cavity. Figure 6 shows a huge parasitic leiomyoma. (*Supplementary Materials*)

References

- [1] D. D. Baird, D. B. Dunson, M. C. Hill, D. Cousins, and J. M. Schectman, "High cumulative incidence of uterine leiomyoma in black and white women: ultrasound evidence," *American Journal of Obstetrics & Gynecology*, vol. 188, no. 1, pp. 100–107, 2003.
- [2] G. A. Vilos, C. Allaire, P. Y. Laberge et al., "The management of uterine leiomyomas," *Journal of Obstetrics and Gynaecology Canada*, vol. 37, no. 2, pp. 157–178, 2015.
- [3] A. S. Elagwany, H. A. Rady, and T. M. Abdeldayem, "A case of parasitic leiomyoma with serpentine omental blood vessels: an unusual variant of uterine leiomyoma," *Journal of Taibah University Medical Sciences*, vol. 9, no. 4, pp. 338–340, 2014.
- [4] S. Sukainah, T. K. Nasir, K. Zulkifli et al., "Parasitic fibroid: case report and novel approach in reducing incidence of future cases," *International Journal of Reproduction, Contraception, Obstetrics and Gynecology*, vol. 5, pp. 2836–2839, 2016.
- [5] K. A. Kho and C. Nezhat, "Parasitic myomas," *Obstetrics & Gynecology*, vol. 114, no. 3, pp. 611–615, 2009.
- [6] M. Sarmalkar, A. Nayak, N. Singh, M. Mehendale, and P. Dixit, "A rare case of primary parasitic leiomyoma mimicking as ovarian mass: a clinical dilemma," *International Journal of Reproduction, Contraception, Obstetrics and Gynecology*, vol. 5, no. 2, pp. 545–548, 2016.
- [7] B. Lu, J. Xu, and Z. Pan, "Iatrogenic parasitic leiomyoma and leiomyomatosis peritonealis disseminata following uterine morcellation," *Journal of Obstetrics and Gynaecology Research*, vol. 42, no. 8, pp. 990–999, 2016.
- [8] G. Cucinella, R. Granese, G. Calagna, E. Somigliana, and A. Perino, "Parasitic myomas after laparoscopic surgery: an

- emerging complication in the use of morcellator? Description of four cases,” *Fertility and Sterility*, vol. 96, no. 2, pp. 90–96, 2011.
- [9] I. Okoro, N. Ododo, and R. Egejuru, “Parasitic leiomyoma: a diagnostic dilemma. A case report,” *Nigerian Journal of Clinical Practice*, vol. 10, no. 4, pp. 349–351, 2007.
- [10] A. M. Salih, F. H. Kakamad, D. A. H., I. J. Habibullah, and G. M. Rauf, “Parasitic leiomyoma: a case report with literature review,” *International Journal of Surgery Case Reports*, vol. 41, pp. 33–35, 2017.
- [11] R. Mushtaq, K. Parveen, and S. Ambreen, “Conjoint presentation of large parasitic leiomyoma and serpentine omental blood vessels: a distinctive case,” *Journal of the Society of Obstetrics and Gynaecologists of Pakistan*, vol. 7, no. 2, pp. 106–109, 2017.
- [12] A. Abdel-Gadir, N. D. Francis, O. O. Oyawoye, and B. P. Chander, “Secondary amenorrhoea with high inhibin B level caused by parasitic ovarian leiomyoma,” *Gynecological Endocrinology*, vol. 26, no. 2, pp. 93–95, 2009.
- [13] L. Nappi, S. Bettocchi, C. Carriero, O. Ceci, A. Vimercati, and L. Resta, “Large parasitic leiomyoma of the broad ligament,” *Journal of Gynecologic Surgery*, vol. 20, no. 3, pp. 97–102, 2004.
- [14] J. Putran and K. Khaled, “Parasitic leiomyomas: two case reports and review of literature,” *Journal of Gynecologic Surgery*, vol. 7, no. 4, pp. 383–384, 2010.