

CASE REPORT

Intracranial subdural empyema mimicking a recurrent chronic subdural hematoma

Ninh Doan*, Mohit Patel, Ha Son Nguyen, Andrew Mountoure,
Saman Shabani, Michael Gelsomino, Karl Janich, and Shekar Kurpad

Department of Neurosurgery, Medical College of Wisconsin, Milwaukee, WI 53226, USA

*Correspondence address. Department of Neurosurgery, Medical College of Wisconsin, 9200 W Wisconsin, Milwaukee, WI 53226, USA.
E-mail: ndoan@mcw.edu

Abstract

Intracranial subdural empyema (ISDE) is a life-threatening condition. The risk for ISDE increases in patients that have undergone prior intracranial procedures. The non-specificity in its clinical presentation often makes ISDE difficult to diagnose. Here, we present a rare case of ISDE mimicking a recurrent chronic subdural hematoma, emphasizing the significance of obtaining early magnetic resonance images of the brain for early diagnosis and treatment to achieve the optimal outcome.

INTRODUCTION

Intracranial subdural empyema (ISDE) is a life-threatening condition that is localized between the dura and arachnoid mater. It can stem from multiple etiologies, including sinusitis, mastoiditis, infected cranial procedures, or dental complications [1–3]. ISDE is reported to account for 5 to 25% of intracranial infections [2]. Published data varies in mortality rates from 4.4 to 24% from ISDE [3]. Repeated studies have supported that prompt neurosurgical intervention is of utmost importance in patients with ISDE as a lack of treatment can progress to septic shock and death [1, 4]. Clinical manifestations of patients with ISDE can be subtle; however, patients can also present with neurological symptoms such as headaches, seizures, vomiting and mass effect [1]. This non-specificity in its clinical presentation often makes ISDH difficult to diagnose. Here, we present a rare case of ISDE mimicking a recurrent chronic subdural hematoma (CSDH) emphasizing the significance of obtaining early magnetic resonance images (MR) of the brain for early diagnosis and treatment to achieve the optimal outcome.

CASE PRESENTATION

Patient is a 59-year-old male without a significant medical history presenting with a worsening headache and the right lower extremity paresis for the past three weeks. Computed tomography (CT) scans of the brain on admission showed bilateral subdural hematomas (Fig. 1A). A left subdural drain was placed, which led to the marked improvement of symptoms and the CSDH (Fig. 1B). A day later, the drain was removed, and the patient was discharged with the resolution of his symptoms; however, a week following the initial procedure, the patient was re-admitted to the hospital with concerns for increased drowsiness and word finding difficulty. The repeated CT of the head demonstrated what was thought to be a stable left CSDH (Fig. 1C). The patient was discharged home the next day as the work-up at that time was insignificant and symptoms were considered secondary to the opioid use.

After 4 weeks of his initial procedure, patient again returned to the hospital with the right-sided hemiparesis and aphasia. Repeated CT of the head was consistent with an enlarged recurrent CSDH (Fig. 1D). Patient underwent a left craniectomy

Received: May 16, 2016. Accepted: August 25, 2016

Published by Oxford University Press and JSCR Publishing Ltd. All rights reserved. © The Author 2016.

This is an Open Access article distributed under the terms of the Creative Commons Attribution Non-Commercial License (<http://creativecommons.org/licenses/by-nc/4.0/>), which permits non-commercial re-use, distribution, and reproduction in any medium, provided the original work is properly cited. For commercial re-use, please contact journals.permissions@oup.com

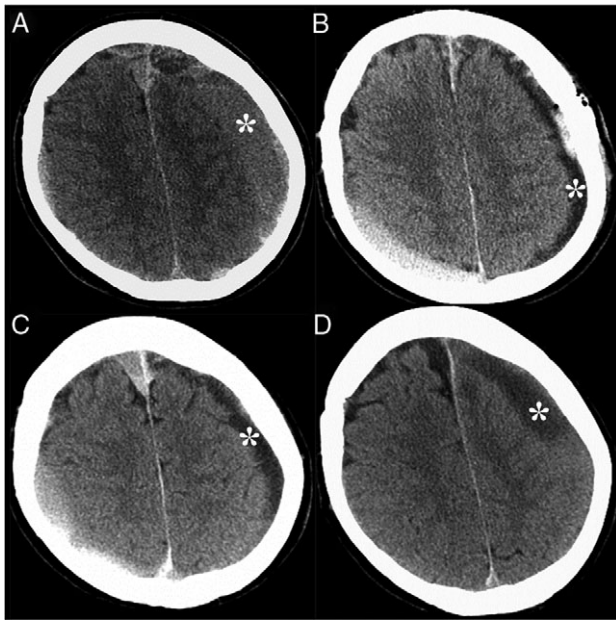


Figure 1: CT of the head without contrast demonstrated CSDH, denoted by the asterisks, at the initial presentation (A), after the procedure (B), 7 days later (C) and 4 weeks later, when the CSDH has enlarged (D). Acute subdural hematoma was also noted in the right posterior frontoparietal region.

for evacuation of what was thought to be a hematoma. Unexpectedly, after opening of the dura, a large amount of purulent materials was encountered and the diagnosis of subdural empyema was made. Patient was immediately started on broad-spectrum antibiotics for ISDE. He was later switched to intravenous Nafcillin for the duration of 6 weeks, as operative cultures were positive for methicillin-sensitive staph aureus (MSSA). After the 4 months of empyema evacuation, patient underwent a left cranioplasty with an artificial implant to cover the craniectomy defect. Patient was discharged home with an intact neurological exam.

DISCUSSION

ISDE is a deadly infection that accounts for up to 25% of all intracranial infections [3]. The mortality rate from ISDE has decreased significantly from 40 to 10% in the last 60 years due to neurosurgical advances in treatment modalities, imaging and in improved antimicrobial treatment regimens [5]. The treatment of the ISDE includes an evacuation of the empyema and antibiotics based on the sensitivity result from the culture [2]. The most common organism isolated from ISDE has been *Streptococcus* and *Staphylococcus* species [1, 5].

The most important aspect of managing an ISDE is the early diagnosis and treatment to prevent severe sequelae. One of the challenges that clinicians face in treating an ISDE is that patients, such as the patient in this report, can present with

subtle clinical manifestations and without classical signs of infection such as fever. In reported studies, the so-called 'classic triad' of fever, headache and vomiting, only accounts for less than 20% of patients with ISDE [1, 5]. However, there are also reports of having a prior neurosurgical procedure as a risk of developing an ISDE [1, 2]. The probability of developing an ISDE after multiple intracranial procedures was upwards of 50% in some studies, while it was only 0.44–1.8% after one neurosurgical procedure [2, 6]. Our patient had undergone a prior subdural hematoma evacuation four weeks prior to developing the ISDE. The patient re-presented without a fever or elevated white blood cell counts. In fact, Ryu et al. reported that patients developing ISDEs after a neurosurgical procedure often have subtle signs and symptoms with less than 35% of patients having a fever and only 15% having headaches from ISDEs [2]. While the cranial CT is widely used in the initial evaluation, it has a false negative result of 6% for diagnosing an ISDE, which can be readily identified by the MR of the brain with a much higher sensitivity and specificity [2, 4, 5]. It is highly important to make an early diagnosis of ISDE as an undiagnosed and untreated ISDE can lead to severe complications such as seizures, septic sinus thrombosis, infarctions, septic shock and even death [2]. Given the lack of sensitive and specific clinical signs of ISDE, a low threshold to obtain an early MR of the brain is highly important to facilitate a prompt diagnosis for early treatments especially in patients who have undergone prior procedures and presented with findings on the CT of the brain suggesting of a recurrent chronic subdural hematoma.

CONFLICT OF INTEREST STATEMENT

None declared.

REFERENCES

- French H, Schaefer N, Keijzers G, Barison D, Olson S. Intracranial subdural empyema: a 10-year case series. *Ochsner J* 2014;14:188–94.
- Ryu S, Lim M, Harsh GI. Management of epidural abscesses and subdural empyemas. *Oper Tech Neurosurg* 2004;7:182–7.
- Nguyen HS, Doan N, Shabani S, Gelsomino M, Mueller W. Co-presentation of a subdural empyema and an infected ventriculoperitoneal shunt in an adult patient: a rare complication with review of literature. *Surg Neurol Int* 2015;6:S455–8.
- Yuan X, Shi X, Xiao H, Sun G, Bai Y, Zhao H, et al. Intracranial subdural empyema mimicking chronic subdural hematoma. *J Craniofac Surg* 2016;27:529–30.
- Brouwer MC, Coutinho JM, van de Beek D. Clinical characteristics and outcome of brain abscess: systematic review and meta-analysis. *Neurology* 2014;82:806–13.
- Hlavin ML, Kaminski HJ, Fenstermaker RA, White RJ. Intracranial suppuration: a modern decade of postoperative subdural empyema and epidural abscess. *Neurosurgery* 1994; 34:974–80; discussion 80–1.