

Received: 2018.07.02
Accepted: 2018.11.01
Published: 2018.12.14

Time Intervals Between Prior Cervical Conization and Posterior Hysterectomy Influence Postoperative Infection in Patients with Cervical Intraepithelial Neoplasia or Cancer

Authors' Contribution:
Study Design A
Data Collection B
Statistical Analysis C
Data Interpretation D
Manuscript Preparation E
Literature Search F
Funds Collection G

ADE **Xinming Yin**
BC **Li Zhu**
DF **Weiwei Tan**
EF **Xiaolan Zhu**
CG **Songping Liu**
EF **Wenlin Xu**

Department of Gynecology, Maternal and Child Care Service Center, Zhenjiang 4th Hospital, Zhenjiang, Jiangsu, P.R. China

Corresponding Authors:

Xiaolan Zhu, e-mail: yinxmtg@163.com, Wenlin Xu, e-mail: xwl0806@163.com

Source of support:

This study was supported by the Science and Technology Support Program of Zhenjiang, JiangSu Province - Social Development Fund (grant number SH2013088); the Natural Science Foundation of China (grant number 81402165/81672913); the Six talent peaks project in Jiangsu Province (grant number 2016-WSW-125); "333 Project" research projects in Jiangsu Province (grant number BRA2016141); the Natural Science Foundation of Jiangsu Province (grant number BK20141288/BK20171311); Jiangsu Provincial Medical Youth Talent (grant number QNRC2016460); Zhenjiang health project science and technology project (grant number SHW2017011); The Zhenjiang health project science and technology project (grant number SHW2017011)

Background:

This study was conducted to observe the influence of different time intervals between prior cervical conization and posterior hysterectomy on postoperative infection in female patients with cervical intraepithelial neoplasia or cancer.

Material/Methods:

Medical records of 170 patients who underwent hysterectomy following cervical conization between November 2010 and September 2016 at the Zhenjiang 4th Hospital were reviewed. According to the interval between hysterectomy and cervical conization, patients were classified into 1–2-week, 4–5-week, and 6-week groups. The outcomes of 46 patients who underwent conization with iodoform gauze inside the vagina were observed.

Results:

The total postoperative infection rate after hysterectomy was 25.3% (43/170). The expression levels of tumor necrosis factor- α (TNF- α), interleukin-6 (IL-6), and high mobility group box 1 (HMGB1) in the cervical secretions and tissues were found to gradually increase, peaking at 2 weeks after conization, then significantly decreasing 3–6 weeks onwards. Compared with the 1–2-week group, the 4–5-week and 6-week groups exhibited significantly lower infection rates (2/42, 4.8%, 4–5-week group; 0%, 0/33, 6-week group; vs. 41/95, 43.2%, 1–2-week group; $p < 0.001$). In the 1–2-week group in particular, the postoperative infection rate after laparoscopic hysterectomy was significantly higher than the rate after abdominal hysterectomy (21/35, 60% vs. 20/60, 33%, $p = 0.0177$). In addition, the vaginal and cervical wound infection rates after conization in patients treated with iodoform were significantly lower than the rates in those without iodoform treatment ($p < 0.05$).

Conclusions:


Hysterectomy should be performed at least 4 weeks after conization. Treatment with iodoform would be beneficial.

MeSH Keywords:

Conization • Hysterectomy • Postoperative Care

Full-text PDF:

<https://www.medscimonit.com/abstract/index/idArt/911892>

 3213

 3

 4

 25



Background

Cervical cancer currently ranks as the second leading cause of cancer death among women in developing countries [1]. In China, cervical cancer exhibits an increasing prevalence among young patients [2]. Cervical intraepithelial neoplasia (CIN) is a preinvasive condition that precedes cervical cancer. To obtain better therapeutic outcomes for cervical cancer, it is vital to diagnose and treat CIN and early cervical cancer. The keys to the management of CIN and early stage cervical cancer (Stage IA1) are early diagnosis and appropriate treatment [3], which involves the central step of cervical conization, either by cold knife or loop electrosurgical excision [4,5]. In addition, posterior hysterectomy via an abdominal, transvaginal, or laparoscopic approach is an important therapeutic measure following cervical conization for CIN III and Stage IA1 invasive cervical cancer. For patients with Stage IA1 cervical cancer, hysterectomy should be performed. Although hysterectomy is not the preferred treatment for CIN III, some patients still require the procedure [6].

However, owing to the lack of systematic and unified information, the safety and effectiveness of posterior hysterectomy after cervical conization remains controversial. In the present study, we analyzed the cases of patients with CIN III or early cancer (Stage IA1) who underwent cervical conization and posterior hysterectomy in the Maternal and Child Care Service Center of Zhenjiang, Zhenjiang 4th Hospital (Zhenjiang, China) to observe the influence of the time interval between prior cervical conization and posterior hysterectomy on postoperative infection. Furthermore, the current study also evaluated the feasibility and safety of hysterectomy following cervical conization.

Material and Methods

Patients

This study was approved by the Ethics Committee of Zhenjiang 4th Hospital (Zhenjiang, China). Written consent was obtained from each patient. Medical records of 170 female patients with CIN III or Stage IA1 cervical cancer who underwent hysterectomy through the abdominal or laparoscopic approach following prior cervical conization between November 2010 and September 2016 at the Zhenjiang 4th Hospital were retrospectively analyzed. All patients were diagnosed with Grade III CIN or invasive cervical cancer through biopsy, and diagnoses were further pathologically confirmed within 2 days of cervical conization and subsequent hysterectomy. Patients who reported abdominal pain or fever, or had a history of diabetes, hypohemia, or thyroid diseases before cervical conization, as well as those with a history of pelvic surgeries, were excluded.

Patients with severe pelvic adhesions after operation, with inflammation, or with tumors discovered during hysterectomy were also excluded.

After biopsy, patients with Grade III CIN or invasive cervical cancer underwent cervical conization and posterior hysterectomy according to routine protocols. Postoperative prophylactic anti-infective treatments were implemented after 48 hours. Indications for hysterectomy included age over 45–50 years with no desire to preserve fertility, lesions located deep in the cervical tube, positive tissue margins after cervical conization, and lack of follow-up conditions.

According to the time interval between cervical conization and posterior hysterectomy, the patients were divided into 3 groups, as follows: 1–2-week group (patients who underwent hysterectomy 48 hours to 2 weeks after cervical conization, comprising 60 cases of abdominal and 35 of laparoscopic hysterectomy), 4–5-week group (comprising 20 cases of abdominal and 22 of laparoscopic hysterectomy), and 6-week group (comprising 9 cases of abdominal and 24 of laparoscopic hysterectomy). The influence of the time interval on post-hysterectomy infection was evaluated.

Measurement of inflammatory factors of cervical tissues and secretions

Cervical tissues and secretion samples from a total of 60 patients were collected at 0 hours, 48 hours, 1 week, 2 weeks, 3 weeks, 4 weeks, 5 weeks, and 6 weeks after conization. The mRNA and protein levels of tumor necrosis factor- α (TNF- α), interleukin-6 (IL-6), and high mobility group box 1 (HMGB1) of these cervical tissues and secretion samples were examined by quantitative real-time polymerase chain reaction (qRT-PCR) and immunohistochemical staining, respectively. Infiltration by inflammatory cells was observed by hematoxylin staining.

Treatment vs. non-treatment with iodoform

In total, 33 patients who underwent conization of the cervix without hysterectomy from January 2014 to September 2015 at our hospital were reviewed. Every week after the operation, a 4% iodoform gauze was placed inside the vaginas of these patients. Tissue around the wound surface was collected at 1, 2, or 3 weeks after conization to measure the expression levels of TNF- α , IL-6, and HMGB1. Clinical data regarding cervical wound inflammation were also reviewed. In addition, a group of approximately the same number of patients who did not receive iodoform treatment after conization of the cervix during the same period were also examined.

Table 1. Clinical data of the patients.

	1–2-week group (n=95)	4–5-week group (n=42)	6-week group (n=33)	p Value
Age (year)	49.6±6.6	50.0±5.7	51.2±5.5	0.259
Uterine size				
Length (mm)	8.2±1.3	8.7±1.0	8.6±1.8	0.457
Width (mm)	5.8±1.4	5.7±0.9	6.0±1.6	0.821
Thickness (mm)	3.9±1.2	4.2±0.9	3.9±1.2	0.264
Intraoperative blood loss (mL)	169.5±81.3	125.5±57.1*	106.1±51.2#	<0.0001
Operating time (min)	115.3±26.2	99.1±18.4*	102.2±12.1#	<0.0001
Days of hospital stay (days)	7.46±2.19	6.12±1.63*	5.55±1.70#	<0.0001
Antibiotic use (h)	96.3±67.1	54.3±22.5*	36.0±13.9#	<0.0001
Prolonged antibiotic prophylaxis (n)	49	4*	3#	
The highest postoperative temperature (°C)	38.1±0.5	37.9±0.5*	37.8±0.3#	0.0012
Days of postoperative temperature more than 38°C (day)	1.24±1.54	0.45±1.06*	0.36±0.74#	<0.0001
Infection rate (n/%)	41 (43.2)	2 (4.8)*	0 (0)*	

* 4–5-week group compared with 1–2-week group; # 6-week group compared with 1–2-week group.

Reverse transcription qRT-PCR analysis

Total RNA was extracted from cervical tissues or secretions using TRIzol (Invitrogen, Carlsbad, CA, USA), and cDNA was generated using the PrimeScript® RT Reagent Kit (Takara, Dalian, China). mRNA was detected by qRT-PCR using the SYBR Premix Ex Taq™ II kit (Takara). The expression levels in each sample were calculated using the $2^{-\Delta\Delta CT}$ method and were normalized using β -actin expression. The primers were designed as follows: TNF- α -F: CCGAGTGACAAGCCTGTAGC, TNF- α -R: AGGAGGTTGACCTTGGTCTG, 493 bp; IL-6-F: TACATCCTCGACGGCATCTC, IL-6-R: AGCTCTGGCTTGTCTCAC, 252 bp; HMGB1-F: GAGGTGAAGACCATGTCTG, HMGB1-R: TCATAAGGCTGCTTGTCATC, 294 bp; and β -actin-F: CACGA AACTACCTCAACTCC, β -actin-R: CATACTCTGCTTGCTGATC, 265 bp.

Histological observation of tumor tissues

The tumor tissues were fixed in formalin, embedded in paraffin, sectioned, and then heat-immobilized or pepsin-immobilized according to the manufacturer's instructions. The slides were stained with hematoxylin and then observed under a microscope.

Statistical analysis

All data were statistically analyzed using the GraphPad Prism 5 software package. Data were expressed as means \pm standard deviations. Measurement data were compared between groups with Student's t test, whereas enumerative data were compared using Fisher's exact test. A value of $p < 0.05$ represented a statistically significant difference.

Results

Basic clinical characteristics

A total of 170 patients underwent cervical conization and posterior hysterectomy, comprising 95 in the 1–2-week group, 42 in the 4–5-week group, and 33 in the 6-week group, with mean ages of 49.6±6.6, 50.0±5.7, and 51.2±5.5 years, respectively. There were no significant differences in age or uterine volume, length, width, and thickness among the 3 groups ($p > 0.05$, Table 1).

Treatment outcomes and postoperative infections

Compared with the 1–2-week group, the 4–5-week and 6-week groups had significantly less intraoperative blood loss, shorter operating times, shorter hospital stays, lower antibiotic use,

Table 2. Postoperative infection after posterior hysterectomy in laparoscopic versus abdominal hysterectomy in the 1–2-week group.

Infection rate	Laparoscopic hysterectomy (n=35)		Abdominal hysterectomy (n=60)		p Value
	Infection number (n)	Infection rate (%)	Infection number (n)	Infection rate (%)	
Urinary tract infection	2	5.71	0	0	
Intestinal infection	3	8.57	0	0	
Vaginal cuff bleeding	5	14.29	0	0	
Pelvic infection	16	45.71	0	33.33	
Total	21	60.00	20	33.33	0.018

higher postoperative temperatures, and fewer days of postoperative temperatures greater than 38°C (all $p < 0.01$, Table 1). These results are likely due to the different time intervals between cervical conization and hysterectomy rather than other factors.

Among the 170 patients who received postoperative prophylactic anti-infective treatments after 48 hours, the total postoperative infection rate after hysterectomy was 25.3% (43/170). The 4–5-week and 6-week groups exhibited both significantly lower infection rates (2/42, 4.8%, for the 4–5-week group; and 0/33, 0%, for the 6-week group vs. 41/95, 43.2%, for the 1–2-week group; both $p < 0.001$) and lower prolonged antibiotic prophylaxis rates (4/42, 9.5%, for the 4–5-week group; and 3/33, 9.1%, for the 6-week group vs. 49/95, 51.6%, for the 1–2-week group; both $p < 0.001$) than the 1–2-week group (Table 1).

In addition, the infections observed in the 1–2-week group included complex urinary tract, severe intestinal, vaginal cuff, and pelvic infections. In contrast, only 2 cases of pelvic infection were observed in the 4–5-week group, and no infections were found in the 6-week group (Table 1). Refractory diarrhea, vaginal bleeding, and severe postoperative infection were observed in the 1–2-week group, in contrast to the other 2 groups. Furthermore, in the 1–2-week group, with 60 cases of abdominal hysterectomy and 35 of laparoscopic hysterectomy, patients receiving laparoscopic hysterectomy had a significantly higher infection rate than those undergoing abdominal hysterectomy (21/35, 60% vs. 20/60, 33%, respectively, $p = 0.0177$, Table 2). In particular, there were 2, 3, and 5 cases of complex urinary tract, severe intestinal, and vaginal cuff infection, respectively, in patients in the 1–2-week group receiving laparoscopic hysterectomy.

Histological observation

Hematoxylin staining for tumor tissues showed progressive inflammatory cell infiltration after hysterectomy following prior cervical conization. Compared with the specimens without obvious inflammation immediately after cervical conization (0 h, Figure 1A), some mild inflammation and expansion

of the mesenchymal vessels in the cervical tissue were visible about 48 hours later (48 h, Figure 1B); after 1 week, significant inflammation, high inflammatory exudation on the surface, plasma cell infiltration, and a large number of neutrophils and lymphatics were observed (1 w, Figure 1C). After 2 weeks, there was a slight decrease in the number of inflammatory cells and inflammatory exudation on the surface, along with mild interstitial edema (2 w, Figure 1D), and about 3 weeks after the procedure, the number of inflammatory cells was further reduced, accompanied by the appearance of interstitial fibrosis (3 w, Figure 1E). Approximately 4 weeks after conization, the squamous epithelium showed recovery, with infiltration by a few inflammatory cells (4 w, Figure 1F). Infiltration by inflammatory cells reduced significantly at 5 weeks after the procedure (5 w, Figure 1G). About 6 weeks after cervical conization, scattered inflammatory cells in the stroma and matured reparative squamous epithelium were visible (6 w, Figure 1H). Therefore, different levels of inflammatory cell infiltration and inflammatory reactions were observed at different time intervals between cervical conization and posterior hysterectomy.

Expression of inflammatory factors post-conization

TNF- α , IL-6, and HMGB1 were detected by qRT-PCR in the cervical secretions (Figure 2A) and surrounding tissues (Figure 2B) after cervical conization. The mRNA expression levels of TNF- α , IL-6, and HMGB1 in the cervical secretions or tissues peaked at 1 or 2 weeks after conization and then significantly decreased 3–6 weeks onwards (Figure 2). These findings indicate that the expression levels of TNF- α , IL-6, and HMGB1 in cervical secretions or tissues were significantly affected by the time interval between conization and posterior hysterectomy.

Effect of iodoform on treatment

Clinical data showed that the existence of vaginal odor and cervical pus, as well as indicators of lack of cleanliness of vaginal discharge, were significantly lower in patients who were treated with iodoform at 1, 2 or 3 weeks after conization than in those without iodoform treatment (all $p < 0.001$, Table 3).

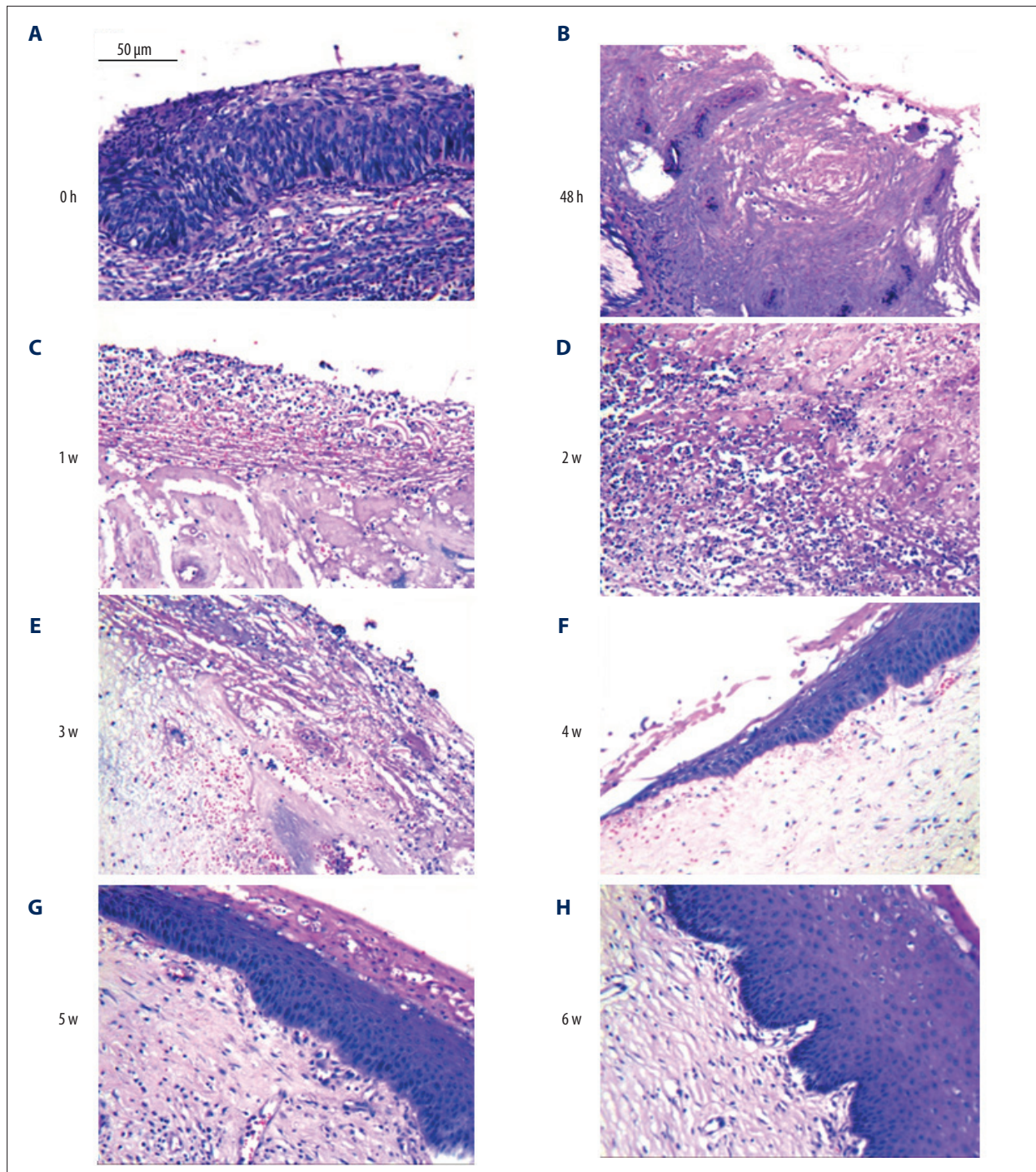


Figure 1. Histological characteristics of cervical tissues at (A) 0 h, (B) 48 h, (C) 1 week (1 w), (D) 2 weeks (2 w), (E) 3 weeks (3 w), (F) 4 weeks (4 w), (G) 5 weeks (5 w), and (H) 6 weeks (6 w), respectively, after posterior hysterectomy following conization of CIN (Grade III). (200× magnification). Ten cervical tissue samples were analyzed at each time point.

The mRNA expression levels of TNF- α , IL-6, and HMGB1 in cervical secretions and surrounding tissues after conization in patients treated with iodoform were significantly lower than the levels in those without iodoform treatment ($p < 0.05$, Figure 3). In addition, the vaginal and cervical wound infection

rates after conization in patients treated with iodoform were significantly lower than the rates in those without iodoform treatment ($p < 0.005$).

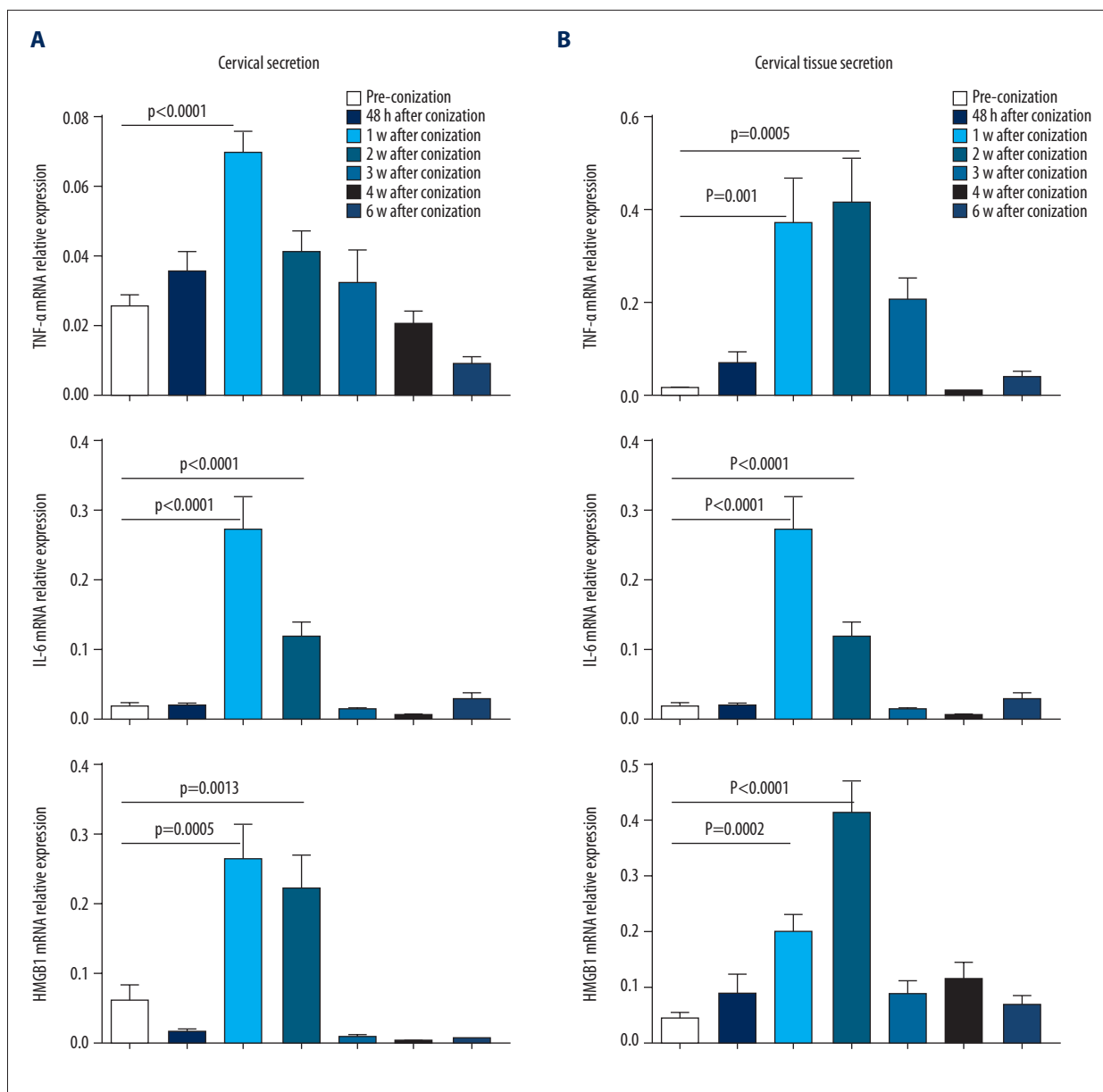


Figure 2. mRNA expression of TNF-α, IL-6, and HMGB1 in cervical tissues (A) and secretions (B) at 0 h, 48 h, 1 w, 2 w, 3 w, 4 w, 5 w, and 6 w, respectively, after posterior hysterectomy following conization, examined using qRT-PCR. N=10.

Table 3. Clinical symptoms after conization and cleanliness of vaginal discharge.

	Existence of vaginal odor	Existence of cervical pus	Cleanliness of vaginal discharge ≥III
Iodoform gauze group (n=46)	5	2	7
Non-iodoform gauze group (n=46)	26	16	29
p value	<0.0001	0.0004	<0.0001

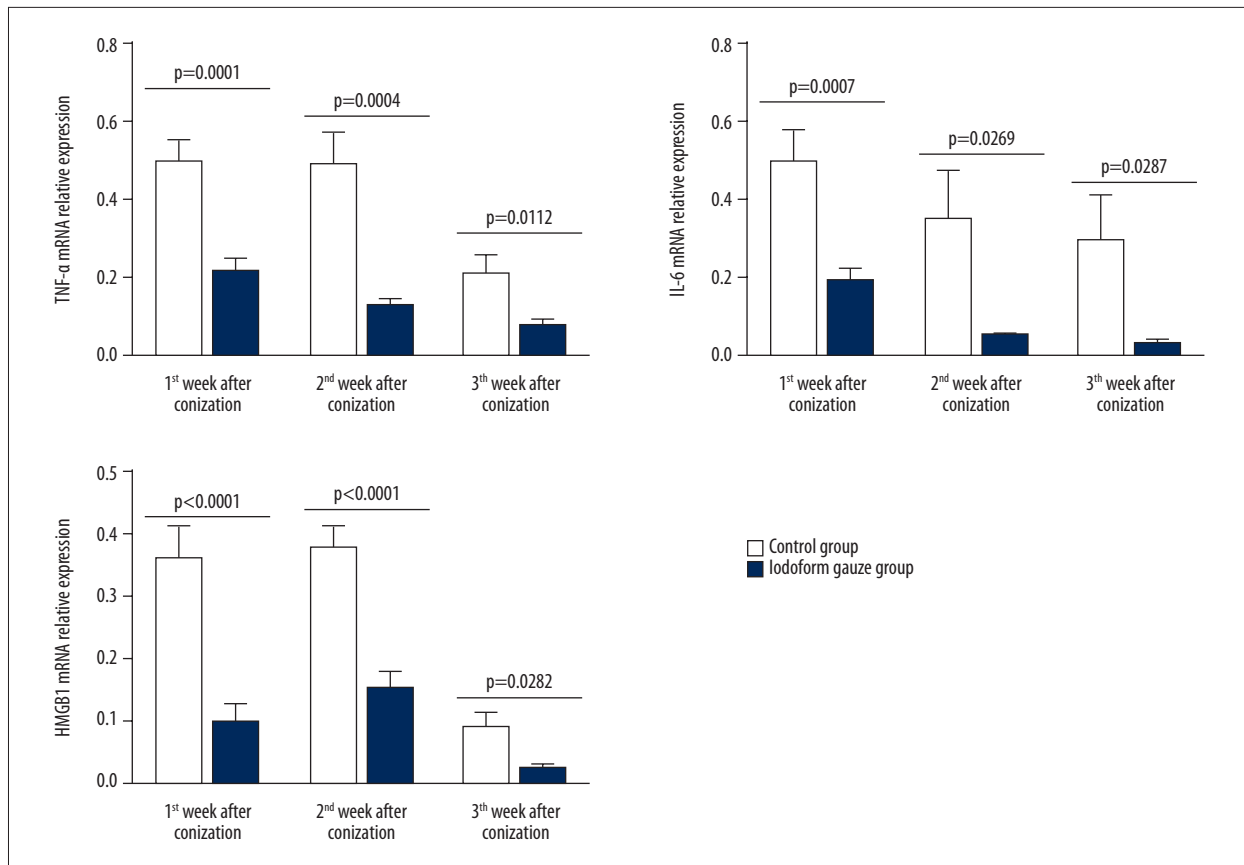


Figure 3. Effect of iodoform on the expression of TNF- α , IL-6, and HMGB1 detected by qRT-PCR in cervical tissue after conization.

Histological observation showed that the cervical wound in patients hysterectomized at 1–3 weeks after cervical conization was cleaner and had less visible edema and exudation among those treated with iodoform gauze, allowing the development of granulation tissue and improving wound healing and regeneration (Figure 4).

Discussion

Cervical conization is part of the diagnosis and treatment of CIN and is performed mainly for the treatment of high-grade CIN (e.g., Grade III) [7]. Hysterectomy, one of the most common gynecologic surgical procedures, can be performed via vaginal, abdominal, or laparoscopic approaches [5]. The well-known risk factors for the persistence/recurrence of CIN after cervical conization include older age, high cytological grade, and positive margins [8]. We therefore performed hysterectomy after prior cervical conization for older patients with high-grade CIN (grade III) or early cervical cancer (IA1). In the present study, we observed the influence of the time interval between prior cervical conization and posterior hysterectomy on postoperative infection. The patients were classified into 1–2-week, 4–5-week, and 6-week interval groups. Since the

third week after conization was probably the patients' menstruation period, fewer hysterectomies were performed during that time. As a result, cervical specimens at 3 weeks were not analyzed. We demonstrated that prior cervical conization with posterior hysterectomy was safe and effective, with postoperative inflammation and infection controlled at low levels, when hysterectomy was performed 4–5 weeks or more after cervical conization.

Proinflammatory cytokines, such as TNF- α , IL-6, and HMGB1, play important roles in the occurrence and development of biological injury and pathological inflammation processes. TNF- α is involved in the systemic inflammatory response in acute disease phases [9] and plays an important role in reproductive tract infections [10]. IL-6, a multifunctional inflammatory cytokine and a key component of the inflammatory mediator network, is associated with inflammation; its rapid increase after exposure to bacterial components can be used as an early marker for bacterial infection with efficacy superior to that of procalcitonin [11]. HMGB1 and IL-6 are involved in the pathogenesis of pandemic H1N1 influenza-associated encephalopathy, and the levels of these inflammatory cytokines in serum can be used as biomarkers for inflammation severity [12]. In the present study, we showed that the expression levels of TNF- α , IL-6, and

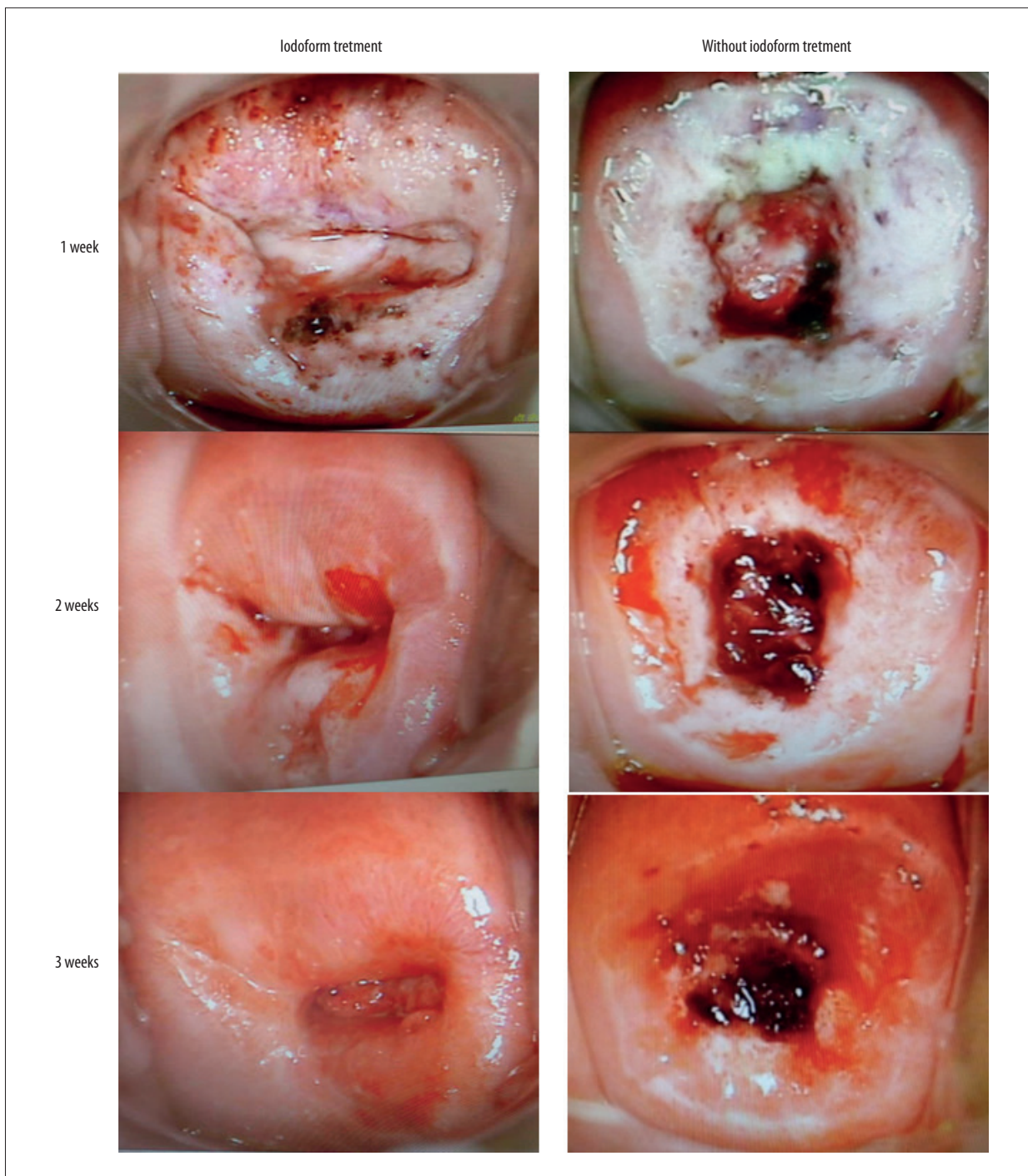


Figure 4. Colposcopic examination of cervical tissues at 1, 2, and 3 weeks, respectively, after posterior hysterectomy following conization with or without iodoform treatment.

HMGB1 in cervical tissue and secretions gradually increased after conization, peaked after approximately 1–2 weeks, and then 3–6 weeks onwards following surgery, significantly decreased to the preoperative levels. Given that there were no significant differences in age or uterine volume, length, width, and thickness among the 3 groups, and that certain other factors,

such as a history of pelvic surgeries, severe pelvic adhesions, inflammation, and other combined diseases (such as diabetes and thyroid diseases) related to induction of infection that could affect the occurrence of complications after hysterectomy were excluded, these results indicate that the time interval between cervical conization and posterior hysterectomy,

rather than other factors, influenced the expression levels of inflammatory factors (TNF- α , IL-6, and HMGB1). Histological observation showed that inflammation (e.g., inflammatory cell infiltration) was most severe within approximately 1–2 weeks after conization. Together, these results imply that to avoid serious postoperative inflammation and subsequent related infection, it is not advisable to perform hysterectomy within 1–2 weeks following conization.

The time during which hysterectomy could feasibly be performed after prior cervical conization has not yet been determined. Li et al. [13] showed that surgery time, blood loss, conversion to laparotomy, and preoperative morbidity after posterior radical hysterectomy performed following conization varied with the time interval, and indicated that the appropriate time interval was 6 weeks after conization. Furthermore, a careful separation of the bladder and ureter from the cervix was recommended to minimize morbidity. In contrast, some studies have reported that hysterectomy could be conducted at any time after cervical conization as long as patients were in the appropriate condition, rather than precisely within a period of 48 hours or >6 weeks [14,15]. Postoperative infection is one of the most common complications following hysterectomy, not only threatening the health and life of patients but also affecting the quality of medical care. Risk factors for the development of postoperative infection include an immunocompromised state, obesity, poor nutrition, diabetes mellitus, prolonged preoperative hospitalization, and infected or devitalized tissues [5].

In the present study, we demonstrated that postoperative infections following hysterectomy performed within 2 weeks after conization were more common and severe than those occurring following procedures conducted 3–6 weeks after conization. The rate of postoperative infection following hysterectomy conducted 4–6 weeks after conization was 2.67%, similar to the findings of other reports, whereas the rate following hysterectomy conducted within 2 weeks after conization showed a dramatic increase to 43.2%, higher than the rate previously reported (6.1%) [16].

Moreover, the present study further indicated that compared with other time intervals, hysterectomy within 2 weeks after conization led to higher post-hysterectomy infection rates, increased severity of infection, higher grade and prolonged use of antibiotics, increased inflammatory cell infiltration, delayed postoperative recovery, and extended hospitalization time. In contrast, when hysterectomy was performed 4–6 weeks after conization, the postoperative infection rates, severity of infection, grade and days of using antibiotics, and inflammatory cell infiltration decreased significantly, with no postoperative bleeding and fewer complications. The current study showed that hysterectomy was safe and feasible 4 weeks after

conization, with both decreased postoperative infection and lower use of antibiotics, which may be because the tissues damaged by cervical conization had already been repaired by this period. Although inflammation existed around the cervix after conization, it has been reported that radical hysterectomy could be performed at any time after conization [15], which might be due to the excision of inflammatory organization around the cervix in radical hysterectomy, indicating that greater post-hysterectomy infection was affected by the inflammatory organization around the cervix.

Laparoscopic hysterectomy is one of the most common surgeries for female patients [17,18]. This procedure has the advantages of reducing trauma and accelerating postoperative recovery [19], and it is becoming increasingly popular [20]. Nogueira-Silva et al. [21] reported a postoperative infection rate of 5.72% in 262 laparoscopic hysterectomy cases. In the present study, the postoperative infection rates of laparoscopic hysterectomy in the 1–2-week, 4–6-week, and 6-week groups were 60.0%, 9.1%, and 0%, respectively. The great variations in the postoperative infection rates revealed in this study are likely related to the time interval between cervical conization and posterior hysterectomy. Furthermore, for hysterectomy within 1–2 weeks after conization, the postoperative infection rate associated with laparoscopic hysterectomy (60.0%) was higher than that associated with abdominal hysterectomy (33.3%). The explanation might be the following: as uterine arteries and ligaments close to the cervix were mainly managed by electrosurgery in laparoscopic hysterectomy, inflammatory hyperemia around the cervix would reach its peak approximately 1–2 weeks after conization, resulting in more coagulation and hemostasis from hysterectomy using bipolar electrosurgery during this period, with thermal radiation burns affecting the function of surrounding tissues [22–25]. As a result, operation time was prolonged, and errhysis, recovery retardation, infection, and dysfunction of the rectum and bladder occurred after the operation, which further decreased the superiority of laparoscopy. In contrast, abdominal hysterectomy performed with the cold knife procedure causes relatively little damage to the surrounding tissues. However, when hysterectomy is performed 4 weeks after conization, laparoscopy is preferred, with lower rates of postoperative infection and complications.

We showed that treatment with iodoforn after conization decreased postoperative infection, indicating that if hysterectomy must be performed within 1–2 weeks after conization, additional iodoforn instead of laparoscopic treatment is recommended.

Only when the optimal operation window of opportunity between prior conization and posterior hysterectomy is appropriately chosen can the risk of surgery-related infections and complications be reduced. Subsequent hysterectomy within 1–2

weeks after conization should be avoided, except under special circumstances. Instead, posterior hysterectomy is best performed when inflammation has subsided, more than 4 weeks after conization. If hysterectomy must be carried out within 1–2 weeks following conization, abdominal hysterectomy including the suturing of uterine arteries and cold knife cutting procedures instead of electrical coagulation is recommended, and treatment with iodoform gauze after conization, an economic, convenient, and effective procedure, is also suggested, whether or not hysterectomy is to be performed.

There are some limitations to the present study. This was a retrospective study analyzing medical records from a single center, which might result in some bias in case selection as well as incomplete clinical and biochemical patient information

in some key areas. In addition, for several reasons, follow-up information was not available in this study. In the future, a prospectively designed study involving a larger sample size in multiple centers, with an appropriate follow-up period, is warranted to verify these results.

Conclusions

Hysterectomy performed 3–6 weeks rather than 1–2 weeks after conization decreases inflammatory cell infiltration and postoperative complications and infection after the procedure. Hysterectomy should be performed at least 4 weeks after conization, and treatment with iodoform gauze after conization can be beneficial.

References:

- Torre LA, Bray F, Siegel RL et al: Global cancer statistics, 2012. *Cancer J Clin*, 2015; 65(2): 87–108
- Li S, Hu T, Lv W et al: Changes in prevalence and clinical characteristics of cervical cancer in the People's Republic of China: A study of 10,012 cases from a nationwide working group. *Oncologist*, 2013; 18(10): 1101–7
- Wright TC Jr, Massad LS, Dunton CJ et al: 2006 consensus guidelines for the management of women with cervical intraepithelial neoplasia or adenocarcinoma *in situ*. *J Low Genit Tract Dis*, 2007; 11(4): 223–39
- Zeng SY, Liang MR, Li LY, Wu YY: Comparison of the efficacy and complications of different surgical methods for cervical intraepithelial neoplasia. *Eur J Gynaecol Oncol*, 2012; 33(3): 257–60
- Hodges KR, Davis BR, Swaim LS: Prevention and management of hysterectomy complications. *Clin Obstet Gynecol*, 2014; 57(1): 43–57
- Massad LS, Einstein MH, Huh WK et al: 2012 updated consensus guidelines for the management of abnormal cervical cancer screening tests and cancer precursors. *Obstet Gynecol*, 2013; 121(4): 829–46
- Baser E, Ozgu E, Erkilinc S et al: Clinical outcomes of cases with cervical dysplasia absent in cold knife conization specimens. *Asian Pac J Cancer Prev*, 2014; 14(11): 6693–96
- Nam K, Chung S, Kim J et al: Factors associated with HPV persistence after conization in patients with negative margins. *J Gynecol Oncol*, 2009; 20(2): 91–95
- Lukaszewski T, Drews K, Seremak-Mrozikiewicz A et al: The evaluation of the predictive value of TNF-alpha concentration in maternal serum in the prediction of neonatal and maternal infection. *Ginekol Pol*, 2015; 86(1): 26–32
- Zhao X, Zhu D, Ye J et al: The potential protective role of the combination of IL-22 and TNF-alpha against genital tract *Chlamydia trachomatis* infection. *Cytokine*, 2015; 73(1): 66–73
- Lin S, Huang Z, Wang M et al: Interleukin-6 as an early diagnostic marker for bacterial sepsis in patients with liver cirrhosis. *J Crit Care*, 2015; 30(4): 732–38
- Momonaka H, Hasegawa S, Matsushige T et al: High mobility group box 1 in patients with 2009 pandemic H1N1 influenza-associated encephalopathy. *Brain Dev*, 2014; 36(6): 484–88
- Li H, Jang JY, Li H et al: The influence of interval between conization and laparoscopic radical hysterectomy on the morbidity of patients with cervical cancer. *Eur J Gynaecol Oncol*, 2012; 33(6): 601–4
- Tae Kim Y, Sung Yoon B et al: The influence of time intervals between loop electrosurgical excision and subsequent hysterectomy on the morbidity of patients with cervical neoplasia. *Gynecol Oncol*, 2005; 96(2): 500–3
- Qu H, Zhang Y, Zhang J et al: Influences of different time intervals between loop electrosurgical excision and abdominal hysterectomy or radical hysterectomy on postoperative complications: A retrospective analysis. *J Med Coll PLA*, 2010; 25: 38–43
- Petrosillo N, Drapeau CM, Nicastrì E et al: Surgical site infections in Italian Hospitals: A prospective multicenter study. *BMC Infect Dis*, 2008; 8: 34
- Wright KN, Jonsdottir GM, Jorgensen S et al: Costs and outcomes of abdominal, vaginal, laparoscopic and robotic hysterectomies. *JSL*, 2012; 16(4): 519–24
- Rosero EB, Kho KA, Joshi GP et al: Comparison of robotic and laparoscopic hysterectomy for benign gynecologic disease. *Obstet Gynecol*, 2013; 122(4): 778–86
- Lee EJ, Park HM: Trends in laparoscopic surgery for hysterectomy in Korea between 2007 and 2009. *J Obstet Gynaecol Res*, 2014; 40(6): 1695–99
- Loring M, Morris SN, Isaacson KB: Minimally invasive specialists and rates of laparoscopic hysterectomy. *JSL*, 2015; 19(1): e2014.00221
- Nogueira-Silva C, Santos-Ribeiro S, Barata S et al: [Total laparoscopic hysterectomy: retrospective analysis of 262 cases]. *Acta Med Port*, 2014; 27(1): 73–81 [in Portuguese]
- Pantelic M, Ljekar J, Deveckerski G, Karadzic J: Energy systems in surgery. *Med Pregl*, 2015; 68(11–12): 394–99
- Teerapong S, Rungaramsin P, Tanprasertkul C et al: Major complication of gynaecological laparoscopy in Police General Hospital: A 4-year experience. *J Med Assoc Thai*, 2012; 95(11): 1378–83
- Soderstrom RM: Electrosurgical injuries during laparoscopy: Prevention and management. *Curr Opin Obstet Gynecol*, 1994; 6(3): 248–50
- Janssen PF, Brolmann HA, Huirne JA: Causes and prevention of laparoscopic ureter injuries: An analysis of 31 cases during laparoscopic hysterectomy in the Netherlands. *Surg Endosc*, 2013; 27(3): 946–56