

CASE REPORT

Effectiveness of continuous low-dose fasudil on refractory coronary vasospasm subsequent to cardiopulmonary arrest

Daisuke Ooshiro , Satoshi Yamaguchi, Masanori Kakazu & Osamu Arasaki

Department of Cardiology, Tomishiro Central Hospital, Okinawa, Japan

Correspondence

Satoshi Yamaguchi, Department of Cardiology, Tomishiro Central Hospital, 25 Ueta, Tomishiro-shi, Okinawa 901-0243, Japan.
Tel: +81-(0) 98-850-3811;
Fax: +81-(0)-98-850-3810;
E-mail: gajyakichi@gmail.com

Funding Information

No sources of funding were declared for this study.

Received: 16 September 2015; Revised: 9 November 2016; Accepted: 27 November 2016

Clinical Case Reports 2017; 5(8): 1207–1209

doi: 10.1002/ccr3.830

Introduction

Calcium blockers, nicorandil, and nitrates are used to treat coronary vasospastic angina (VSA). In almost all cases, chest pain and ST-T changes on electrocardiography can be resolved rapidly. However, some cases are refractory to these medications, which can be dangerous considering the risk of myocardial infarction or life-threatening arrhythmia. It is suggested that Rho-kinase may evoke severe vasospasm [1]. There are few available reports on clinical use of fasudil as a Rho-kinase blocker for refractory VSA [2–4]. In addition, the effective dose of fasudil is unclear. Here, we describe how refractory VSA unresponsive to a first-line drug, such as calcium blockers or nicorandil, in a patient with postcardiac arrest, can be treated with continuous low-dose fasudil (CLDF) administration.

Case Description

A 62-year-old man had been treated with stent implantation in the right coronary artery (RCA) for effort angina. He did not achieve smoking cessation. He complained of

Key Clinical Message

Refractory coronary vasospasm subsequent to reperfusion, such as cardiopulmonary resuscitation or revascularization, for myocardial infarction may respond to fasudil in the superacute phase. Continuous low-dose fasudil administration should be an option for refractory coronary vasospastic angina (VSA).

Keywords

Fasudil, Rho-kinase, vasospastic angina.

chest pain 34 months after the percutaneous coronary intervention, and bisoprolol 2.5 mg was prescribed. He went into cardiopulmonary arrest after complaining of nausea 2 weeks after bisoprolol was started. Bystander cardiopulmonary resuscitation was started immediately. Biphasic direct-current shock after intravenous administration of nifekalant 30 mg and amiodarone 300 mg returned his ventricular fibrillation to spontaneous circulation. His ST-T segment at the inferior wall leads was elevated. After spontaneous circulation returned, ventricular fibrillation reoccurred frequently, and his hemodynamics was unstable due to electrical storm. Thus, percutaneous cardiopulmonary support with intra-aortic balloon pumping was performed. Coronary angiography showed vasospasm at three coronary vessels, including total occlusion of the RCA. However, no in-stent restenosis was observed on angiography. Intravascular ultrasonography did not show a significant organic stenosis along the occluded site of the RCA. Vasodilators, including nitroglycerin and nicorandil, were administered, and total occlusion of the RCA was released. Coronary perfusion restarted after this.

After admission to the intensive care unit, under continuous administration of nicorandil, isosorbide dinitrate, and diltiazem, a series of ventricular fibrillations was recreated subsequent to ST-T segment elevation at the inferior wall. CLDF (60 mg/day; 30 mg fasudil dissolved in 5% glucose solution, administered at a rate of 11 mL/h [72.9 mg/day]) was administered between the second and sixth hospital days. Target temperature therapy was initiated and maintained for 12 h, with a management objective of 34°C for bladder temperature. Intra-aortic balloon pumping was discontinued on the second hospital day, and noradrenaline 0.1 µg/kg/min was administered between the first and seventh hospital days. ST-T change and ventricular fibrillation did not recur after fasudil administration, even after it was discontinued.

The patient underwent intracardiac defibrillator implantation to prevent sudden death, and verapamil hydrochloride, nicorandil, benidipine hydrochloride, and

isosorbide dinitrate continued to be prescribed (Figs 1 and 2).

Discussion

Severe coronary vasospasm can cause life-threatening ventricular arrhythmia or myocardial infarction. However, this condition remains challenging to cardiologists and intensivists because of the lack of specific treatment. Some researchers have suggested the effectiveness of fasudil in animal models and clinical reports [2–5]. In fact, fasudil has been widely used in patients with subarachnoid hemorrhage to prevent intracerebral vasospasm [6]. We made two discoveries in this case. First, CLDF administration was effective for refractory VSA. Second, even after its discontinuation, VSA did not recur, and myocardial infarction and ventricular arrhythmia did not occur for more than 21 months after this event with a combination

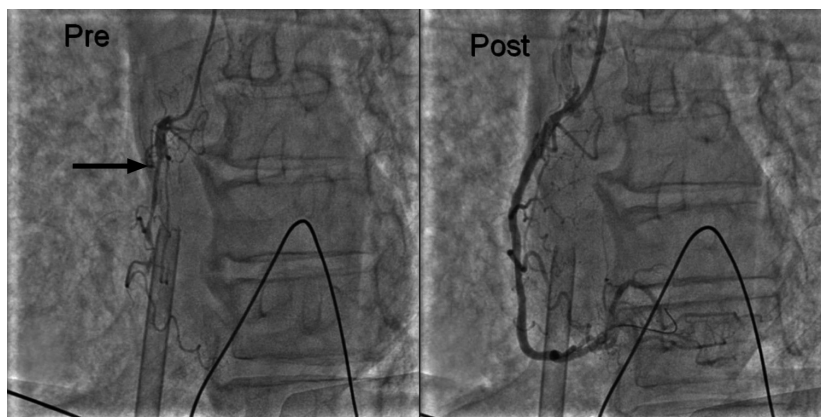


Figure 1. Coronary angiogram (left), revealing occlusion of the right coronary artery (black arrow). Coronary spasm is relieved (right).

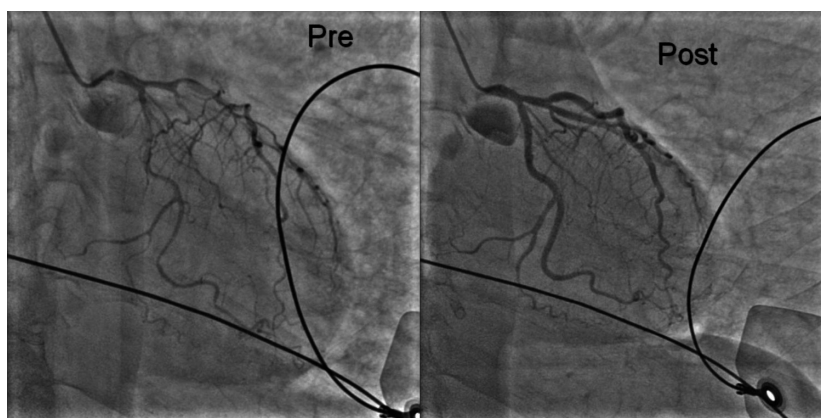


Figure 2. Coronary angiogram (left), showing diffuse spasm of the left coronary artery. Coronary flow is delayed. Coronary spasm is relieved (right).

of verapamil hydrochloride, nicorandil, benidipine hydrochloride, and isosorbide dinitrate.

First, CLDF was effective for refractory VSA. One previous study using a canine model of coronary artery reperfusion demonstrated that reperfusion activated Rho-kinase, which suppressed eNOS expression [5]. Conversely, fasudil administration induced eNOS expression. In this case, reperfusion activated Rho-kinase and suppressed eNOS expression, resulting in refractory coronary spasm. Fasudil, even with a low dose, might influence eNOS expression and suppress Rho-kinase by blocking the upstream of its cascade.

Second, there is no firm evidence available regarding the legacy effect of CLDF. In fact, to reiterate, VSA subsequent to reperfusion should be derived from the cascade of Rho-kinase. This might be the reason why severe VSA was resolved so rapidly after fasudil administration. We believe that once fasudil had relieved the cascade activation, the other drugs, such as verapamil hydrochloride, nicorandil, benidipine hydrochloride, and isosorbide dinitrate, became sufficiently effective.

Refractory VSA subsequent to reperfusion, such as cardiopulmonary resuscitation or revascularization, for myocardial infarction may respond to fasudil in the superacute phase.

Conclusion

CLDF administration should be an option for refractory coronary VSA.

Consent

Informed consent was obtained from the patient and his family for publication of this case report.

Acknowledgment

We are particularly grateful for the assistance provided by Satoshi Yamaguchi.

Conflict of Interest

All authors did not receive any financial support and declare no competing interests.

Authorship

DO: is the first author and wrote this manuscript. SY: provided the concept and insights from this case. MK: treated the patient's acute myocardial infarction. OA: approved publication of this manuscript.

References

1. Mohri, M., H. Shimokawa, Y. Hirakawa, A. Masumoto, and A. Takeshita. 2003. Rho-kinase inhibition with intracoronary fasudil prevents myocardial ischemia in patients with coronary microvascular spasm. *J. Am. Coll. Cardiol.* 41:15–19.
2. Hiroki, J., Y. Fukumoto, H. Shimokawa, Y. Hirooka, and A. Takeshita. 2004. Inhibition of Rho-kinase by fasudil prevents anginal attacks associated with spastic angina: a case report [in Japanese]. *J. Cardiol.* 44:161–164.
3. Taniguchi, Y., H. Funayama, J. Matsuda, K. Fujita, T. Nakagawa, T. Nakamura, et al. 2014. Super-selective intracoronary injection of Rho-kinase inhibitor relieves refractory coronary vasospasms: a case report. *Int. J. Cardiol.* 176:270–271.
4. Masumoto, A., M. Mohri, H. Shimokawa, L. Urakami, M. Usui, and A. Takeshita. 2002. Suppression of coronary artery spasm by the Rho-kinase inhibitor fasudil in patients with vasospastic angina. *Circulation* 105:1545–1547.
5. Yada, T., H. Shimokawa, O. Hiramatsu, T. Kajita, F. Shigeto, E. Tanaka, et al. 2005. Beneficial effect of hydroxyfasudil, a specific Rho-kinase Inhibitor, on ischemia/reperfusion injury in canine coronary microcirculation in vivo. *J. Am. Coll. Cardiol.* 45:599–607.
6. Shibuya, M., Y. Suzuki, K. Sugita, I. Saito, T. Sasaki, K. Takakura, et al. 1992. Effect of AT877 on cerebral vasospasm after aneurysmal subarachnoid hemorrhage. Results of a prospective placebo-controlled double-blind trial. *J. Neurosurg.* 76:571–577.