

**Case Report**

# Distal Bypass to the Palmar Arch to Rescue Digital Ischemia Due to Peripheral Artery Disease

Tsukasa Nakamura, MD, PhD,<sup>1</sup> Shuji Nobori, MD, PhD,<sup>1</sup> Kiyokazu Akioka, MD, PhD,<sup>2</sup>  
Koji Masuda, MD,<sup>1</sup> Shumpei Harada, MD,<sup>1</sup> Masafumi Osaka, MD,<sup>1</sup> Takehisa Matsuyama, MD,<sup>1</sup>  
Norio Yoshimura, MD, PhD,<sup>1</sup> and Hidetaka Ushigome, MD, PhD<sup>1</sup>

Digital ischemia is a serious problem in peripheral artery diseases (PAD) patients. Case 1: A 60-year-old woman with large arteriovenous fistula (AVF) complained of digital ischemia symptoms. The patient underwent dissection of AVF and distal bypass to the palmar arch with successful repair. Case 2: A 47-year-old female, diagnosed with renal failure, and scleroderma, complained of a digital gangrene. A bypass was performed from the left brachial artery to the superficial palmar arch. The digital gangrene showed a complete recovery within 2 months after surgery. Distal bypass to the palmar arch thus appears to be a useful procedure to re-establish digital circulation in PAD patients.

**Keywords:** distal bypass, palmar arch, upper extremity

## Introduction

Peripheral artery disease (PAD) in an upper extremity (UE) is a serious problem, especially among chronic kidney disease patients,<sup>1</sup> while lower extremity (LE) PAD often receives attention due to the high morbidity rate and crucial outcomes.<sup>2</sup> Generally, the prevalence of UE PAD seems to be lower than that of LE PAD because there is relatively enough collateral circulation in UE compared

with LE.

However, UE critical digital ischemia can also develop into tissue necrosis and unavoidable amputation. In order to prevent amputation, procedures, similar to those performed for LE PAD<sup>3–5</sup> are available for UE PAD: surgical distal bypass/sympathectomy, endovascular recanalization, and regenerative therapy. Besides LE distal bypass surgery, UE distal bypass still has not gained popularity. Nevertheless, it is true that surgical distal bypass promises to define revascularization to digits in terms of reliability, efficacy, and patency,<sup>3</sup> especially in cases with complete obstruction of forearm arteries and spared palmar arteries. For example, as an arteriovenous fistula (AVF) complication, longitudinal artery occlusion below the AVF can be seen. These patients tend to exhibit PAD symptoms and might require surgical reconstruction. In terms of bypass surgery, outflow target, in this situation, would be the palmar arch, because there is a possibility that at least one of the superficial or deep palmar arches is spared. Although below wrist distal bypass is technically difficult, a certain microsurgical procedure enables to retrieve digital circulation and avoid amputation. Enough palmar arch circulation enables to improve PAD. Furthermore, following establishment of digital circulation, it is possible to re-construct the AVF again in the forearm, as required. Because AVF obstruction usually compels the reconstruction of the AVF at the upstream or the other side: dominant side. Therefore, this procedure might bring significant benefits to renal failure patients. Thus, it is reasonable to believe that distal bypass to the palmar arch is the most promising procedure to rescue severe ischemic digits and maintain the AVF in well condition.

The aim of this report is to broaden the effectiveness of UE distal bypass to the palmar arch.

## Case Report


### Case 1

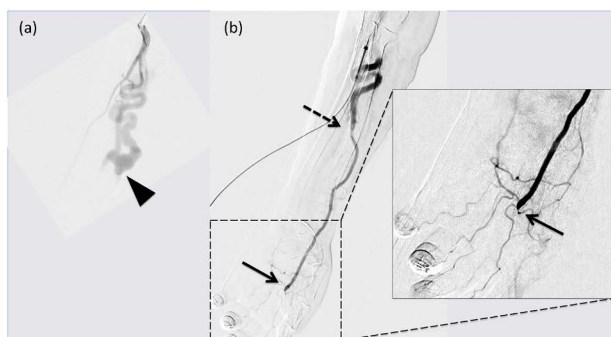
A 60-year old female patient, body weight 35 kg, had a 37-year-history of hemodialysis and had received a deceased donor renal transplantation. Her left forearm AVF

<sup>1</sup>Department of Organ Transplantation and General Surgery, Kyoto Prefectural University of Medicine, Kyoto, Japan

<sup>2</sup>Department of Surgery, Omihachiman Community Medical Center, Shiga, Japan

Received: January 15, 2018; Accepted: April 12, 2018  
Corresponding author: Tsukasa Nakamura, MD, PhD. Department of Organ Transplantation and General Surgery, Kyoto Prefectural University of Medicine, 465 Kajii-cho, Kamigyō-ku, Kyoto 602-8566, Japan  
Tel: +81-75-251-5532, Fax: +81-75-223-6189  
E-mail: tsukasa@koto.kpu-m.ac.jp

 ©2018 The Editorial Committee of Annals of Vascular Diseases. This article is distributed under the terms of the Creative Commons Attribution License, which permits use, distribution, and reproduction in any medium, provided the credit of the original work, a link to the license, and indication of any change are properly given, and the original work is not used for commercial purposes. Remixed or transformed contributions must be distributed under the same license as the original.



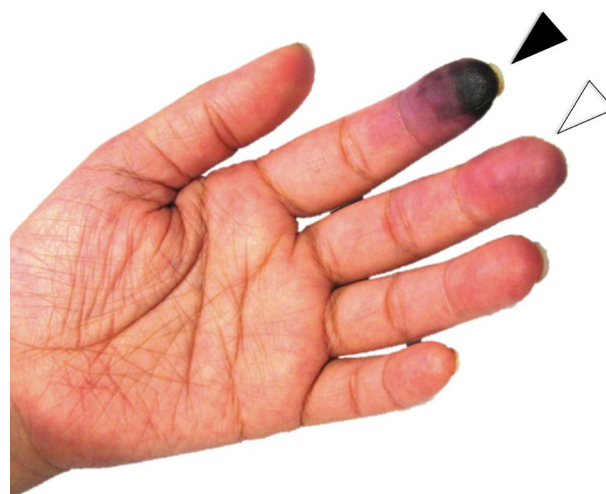**Fig. 1** (a) Pre-operative angiography shows a large AVF and occlusion of the radial artery (black arrowhead). (b) Left arm angiography demonstrates distal bypass from the radial artery to the superficial palmar arch. Black arrowhead: large AVF; black arrow: the distal end anastomosis; black dashed arrow: the proximal anastomosis. The image, surrounded by solid line, indicates a magnified peripheral arteriogram.

appeared a large shunt: 1,200 ml/min associated with complete obliteration of the radial artery (Fig. 1a). Exertional symptoms, tingling, and frigid digits were noted mainly due to decreased blood flow to the hand. Her skin perfusion pressure (SPP) at the left second digit was 23 mmHg. This perfusion pressure was not significantly changed following complete AVF compression. Her stable renal allograft function did not require hemodialysis and AVF. Pre-operative assessment of the main organs revealed no prominent vascular lesions: contralateral UE PAD, cerebrovascular diseases, and cardiovascular diseases. After removal of the AVF, a distal bypass was performed, because intra-operative palmar arch arterial pulse doppler was still weak following AVF closure. The patient was given 5,000 units of intravenous heparin totally and monitored by activated clotting time (ACT) testing: 150–200. Regarding proximal anastomosis, the left radial artery and reversed greater saphenous vein (GSV) graft were anastomosed with interrupted 8-0 prolene suture. In terms of the distal side, the posterior wall was sutured by parachute anastomosis technique, and the anterior wall anastomosis with interrupted 9-0 nylon was performed under the operating microscope OPMI Pentero 900 (Carl Zeiss, Feldbach Schweiz, Switzerland). The graft blood flow was 36 ml/min, measured by VeriQ (Medistim, Oslo, Norway).

Following distal bypass, angiography demonstrated satisfied palmar arch blood circulation (Fig. 1b), and her symptoms disappeared immediately. The SPP at the same digit improved to 98 mmHg following reflow.

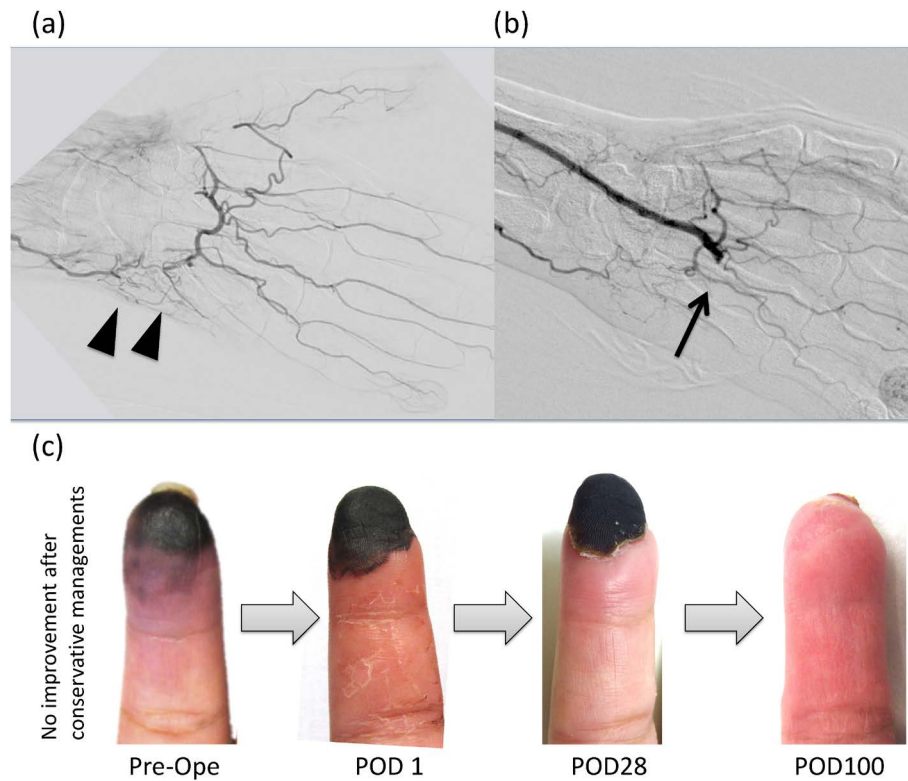
## Case 2

A 47-year-old female patient with renal failure, scleroderma, and diabetes mellitus complained of left hand digital gangrene with rest pain. The patient demonstrated



**Fig. 2** Pre-operative ischemic left hand. Black arrowhead indicates gangrene and white arrowhead shows an ischemic color change.

gangrene in the second digit of the left hand, and severe PAD in the both UE primarily due to her primary diseases (Fig. 2). An angiogram demonstrated occlusion of the left radial artery and severe stenosis of the ulnar artery (Fig. 3a). Even with a maximum dosage of prostaglandin E, vasodilators, and anti-platelet drugs for about 1 year, the lesion was progressively deteriorated. Long-term hemodialysis catheter utilization was not feasible due to a repeated severe blood stream infection. Furthermore, other three limbs also noted mild PAD, which prevented AVF construction in the other limb. However, no cerebrovascular diseases and cardiovascular diseases were demonstrated. Thus, in order to rescue digital circulation and obtain simultaneous blood access, distal bypass from the brachial artery to the palmar arch and AVF construction by using the downstream ulnar artery was performed. With monitoring ACT testing, the patient was given 5,000 units of intravenous heparin in total. The left brachial artery and reversed greater saphenous vein (GSV) graft were anastomosed with interrupted 8-0 prolene suture. Regarding the distal end side, the posterior wall was sutured by the parachute anastomosis technique, and the anterior wall anastomosis with interrupted 9-0 nylon by using the OPMI Pentero 900. VeriQ system confirmed appropriate graft blood flow: 40 ml/min. An angiography after distal bypass showed enough palmar arch and digital circulation (Fig. 3b), and the gangrene improved completely within 2-month (SPP improved <25 to 99 mmHg) (Fig. 3c). Currently, stable hemodialysis was performed regularly by using AVF in the left forearm. The graft patency was confirmed at 6-month following distal bypass in both cases.



**Fig. 3** (a) Pre-operative angiography shows a lack of the radial artery and multiple stenosis of the ulnar artery (black arrowheads). (b) Post-operative left forearm angiography shows distal bypass to the superficial palmar arch by using a reversed GSV. Black arrow: the distal end anastomosis. (c) Stepwise improvements of the gangrene following distal bypass to the palmar arch.

## Discussion

Distal bypass to the palmar arch is still rarely seen given that it is technically difficult and UE PAD relatively rare.<sup>6)</sup> Conversely, population who requires palmar arch re-vascularization certainly exists, for example, patients on hemodialysis with an inappropriate AVF condition. It is true that AVF iatrogenically causes decreased digital blood circulation. With inappropriate collateral vessels or additional arterial disease might cause the onset of symptomatic PAD. As a surgical treatment for digital ischemia due to AVF, it has been reported that distal revascularization with interval ligation (DRIL)<sup>7)</sup> was effective to rescue digital perfusion. The original DRIL procedure indicates a bypass from the native brachial artery to just distal to the ligated artery, provided that AVF and downstream arteries are patent. In terms of affected arteries, radial and ulnar arteries: between above wrist and below elbow, seem to have a responsibility to develop PAD. However, a long distal bypass would be required where there is a complete occlusion of the downstream artery. In fact, case 2 showed a lack of radial artery and severe ulnar arterial calcification. Even in these cases, below the wrist, both superficial and deep palmar arch complete obstruction is still rare.<sup>1)</sup> Thus,

for such cases, it is reasonable to believe that the upstream artery to the palmar artery bypass is ideal: direct palmar arch revascularization to re-establish digital arterial circulation. Regarding bypass surgery to the palmar arch, only a few series of cases has been reported,<sup>8,9)</sup> that might be owing to the requirement of extremely delicate surgical procedures. In terms of surgical technique, generally, that of LE distal bypass appears to be applied in the field of UE distal bypass.<sup>6)</sup> Especially in the context of the palmar arch reconstruction, microscopic vascular anastomosis technique seems to be claimed in order to accomplish an accurate anastomosis. Generally, an external diameter of the palmar arch is around 1.5 mm.<sup>10)</sup> Moreover, an internal diameter is inevitably less than that. Therefore, 9-0 to 11-0 monofilament sutures are usually required for the distal end anastomosis. Where an intraluminal anastomosis is applied, the parachute technique appears to be useful due to the limited surgical space. The total skin incision along with the graft placement would not be required. It can be argued that only a skin incision of the proximal and distal end sites is necessary in addition to the relay point of the graft as needed. As a bypass graft, reversed GSV or lesser saphenous vein, cephalic vein (CV), and in-situ de-valved CV are usually employed in UE distal by-

pass. Especially, de-valved non-reversed GSV grafts seem to be ideal, because of minimum diameter discrepancy and enough length. Given a diameter of prosthetic grafts (5–6 mm), application of these grafts seems to be limited in the context of distal bypass to the palmar arch.

In cases with AVF trouble: obstruction or stenosis, it is true that AVF reconstruction in the upper side is often performed without AVF restoration. Furthermore, there are several other options for patients with difficult vascular access by using prosthetic grafts: prosthetic axillary–axillary bypass, axillary loops, and axillary or femoral to right atrium bypass, among others. However, the former procedure usually gives impetus to deterioration in digital circulation and the latter procedures do not improve PAD. Therefore, in AVF trouble cases, it is reasonable to believe that repairing AVF with distal bypass to ensure digital blood flow is important and useful. It is also true that repairing an AVF with an autologous vein graft distal bypass has an advantage, because this method does not require a prosthetic graft. Conversely, a distal bypass with an autologous vein graft also has limitations, including vein graft atherosclerosis, aneurysm, and a lack of available vein grafts. Generally, LE PAD patients have high morbidity rate of other arterial diseases: PAD in remnant limbs, cerebrovascular diseases, or cardiovascular diseases,<sup>4)</sup> although this shall not apply to patients with multiple AVF surgeries: non-systemic PAD. Thus, pre-operative appropriate screening for other vascular diseases seems to be essential. It is also true to preserve veins for the purpose of future surgical procedures, which require autologous vein grafts. In terms of no availability of vein grafts, transplantation of tissue-engineered vascular grafts would have a potential to address this problem.

## Conclusion

It can be argued that distal bypass to the palmar arch is a useful procedure to re-establish digital blood circulation in PAD patients. UE distal bypass, when indicated and performed by trained surgeons, can be the only digital-saving procedure available.

## Acknowledgments

Tsukasa Nakamura thanks Lyn Child, RN, Holborn Church, Leeds, United Kingdom, for her English editing and proofreading.

## Disclosure Statement

The authors declare no conflicts of interest.

## Author Contributions

Study conception: TN

Data collection: TN, KM, MO, TM

Analysis: TN

Investigation: TN, SN, KA

Writing: TN

Supervision: HU, NY

Critical review and revision: all authors

Final approval of the article: all authors

## References

- 1) Ferraresi R, Acuna-Valerio J, Ferraris M, et al. Angiographic study of upper limb vascularization in a large cohort of hemodialysis patients with critical hand ischemia. *Minerva Cardioangiol* 2016; **64**: 642-7.
- 2) Okamoto S, Iida O, Mano T. Current perspective on hemodialysis patients with peripheral artery disease. *Ann Vasc Dis* 2017; **10**: 88-91.
- 3) Adam DJ, Beard JD, Cleveland T, et al. Bypass versus angioplasty in severe ischaemia of the leg (BASIL): multicentre, randomised controlled trial. *Lancet* 2005; **366**: 1925-34.
- 4) Ohmine T, Iwasa K, Yamaoka T. Strategy of revascularization for critical limb ischemia due to infragenicular lesions—which should be selected firstly, bypass surgery or endovascular therapy? *Ann Vasc Dis* 2015; **8**: 275-81.
- 5) Miyahara T, Suhara M, Nemoto Y, et al. Long-term results of treatment for critical limb ischemia. *Ann Vasc Dis* 2015; **8**: 192-7.
- 6) Hughes K, Hamdan A, Schermerhorn M, et al. Bypass for chronic ischemia of the upper extremity: results in 20 patients. *J Vasc Surg* 2007; **46**: 303-7.
- 7) Aimaq R, Katz SG. Using distal revascularization with interval ligation as the primary treatment of hand ischemia after dialysis access creation. *J Vasc Surg* 2013; **57**: 1073-8.
- 8) Weber R, Benacquista T, Suggs W, et al. Palmar arch revascularization for arterial occlusion of the distal upper extremity. *J Reconstr Microsurg* 2005; **21**: 303-6.
- 9) Savvidou C, Tsai TM. Long-term results of arterial sympathectomy and artery reconstruction with vein bypass technique as a salvage procedure for severe digital ischemia. *Ann Plast Surg* 2013; **70**: 168-71.
- 10) Hazani R, Elston J, Brooks D, et al. Bridging the gap in hand replantation: use of the common digital artery for completion of the superficial palmar arch. *Plast Reconstr Surg* 2010; **126**: 2037-42.