

Ocular Morbidity Among Children With Protein Energy Malnutrition in Northwest Nigeria

Abstract

Background: Protein energy malnutrition (PEM) remains a major health challenge in Nigeria, especially Northern Nigeria. Its association with ocular morbidity and irreversible blindness has been previously documented. There are however limited recent literature on these ocular manifestations, which may have evolved over the years. This study is thus relevant to establish a current baseline for the ocular manifestations associated with PEM in Northern Nigeria. **Materials and Methods:** This was a comparative, cross-sectional study. The sample size was 400 children; 200 with PEM, and 200 without PEM. Consenting parents with children between 6 – 59 months of age diagnosed with PEM, and those without PEM were recruited. Sociodemographic characteristics, general and ocular history were documented. A detailed ocular examination which included visual acuity assessment, examination of ocular adnexae, as well as the anterior and posterior segment of the eyes were done. Data was collected in a structured proforma, and analysed with the SPSS version 21, and Windows WinPepi softwares. **Results:** Abnormal ocular findings were significantly higher in the PEM group compared to the non-malnourished group [46.5% vs 24%, OR = 2.910 (1.891, 4.477), $p < 0.001$]. The predominant ocular examination findings in the PEM and non-malnourished groups were infective conjunctivitis (35.5% vs 17%), lid oedema (11% vs 0%), signs of xerophthalmia (6% vs 0%) and visual impairment (3% vs 0%) **Conclusion:** PEM is still complicated by varying severity of ocular morbidity, with the potential of progression to irreversible blindness.

Keywords: Blindness, ocular manifestations, protein energy malnutrition

Introduction

Protein energy malnutrition (PEM) still remains a major health burden in developing countries.^[1] It characteristically occurs in children under five years of age, wherever the diet is poor in protein and energy.^[2]

Severe PEM has been associated with extreme ocular changes like keratomalacia and corneal xerosis, which in some cases leads to irreversible blindness.^[2]

Some of the studies reviewed, such as those from Kolar, India,^[3] and Khartoum,^[4] Sudan, have shown a spectrum of abnormal ocular findings in children with PEM. While the former was a comparative study with a non-malnourished group to compare with, the latter was a cross-sectional study with no group for comparison. These studies were conducted in environments with a different socio-demographic background to Northwest Nigeria.

In view of the possible changes in dietary habits over the years, as well as various

efforts at food fortification and general improvement in educational levels, we may expect a difference in the range of abnormal ocular findings seen in children with PEM. Abnormal ocular findings in PEM are due to various micronutrient deficiencies most notably vitamin A, and not due to protein deficiency alone. There is however a dearth of recent local studies to assess if PEM is still a significant cause of ocular morbidity in our environment. This study is thus relevant to establish a current baseline for the abnormal ocular findings associated with PEM in Northern Nigeria.

Materials and Methods

This was a comparative, cross-sectional study which was conducted at the paediatric outpatient clinic of the Institute of Child Health. The sample size calculated for the study was 400 children; 200 with PEM, and 200 without PEM. Consenting parents with children between 6 – 59 months of age diagnosed with PEM, and controls without PEM were recruited using systematic random sampling technique. Socio-demographic characteristics, general

**Asimau Eivovo Idris
Zubairu,
Kehinde Kabir
Oladigbolu,
Elsie Samaila,
Peter Ndako Elijah**

*Department of Ophthalmology,
Ahmadu Bello University
Teaching Hospital, Zaria,
Kaduna State, Nigeria*

Received: 15-Mar-2022

Accepted: 09-May-2022

Published: 23-Aug-2022

Address for correspondence:

*Dr. Asimau Eivovo Idris Zubairu,
Department of Ophthalmology,
Ahmadu Bello University
Teaching Hospital, Zaria,
Kaduna State, Nigeria.
E-mail: info4smos@yahoo.com*

Access this article online

Website:

www.jwacs-jcoac.com

DOI: 10.4103/jwas.jwas_56_22

Quick Response Code:



How to cite this article: Zubairu AE, Oladigbolu KK, Samaila E, Elijah PN. Ocular morbidity among children with protein energy malnutrition in Northwest Nigeria. *J West Afr Coll Surg* 2022;12:83-7.

This is an open access journal, and articles are distributed under the terms of the Creative Commons Attribution-NonCommercial-ShareAlike 4.0 License, which allows others to remix, tweak, and build upon the work non-commercially, as long as appropriate credit is given and the new creations are licensed under the identical terms.

For reprints contact: reprints@medknow.com

and ocular history were documented, and a general physical examination with anthropometry were performed. A detailed ocular examination which included visual acuity assessment, examination of ocular adnexae, as well as the anterior and posterior segment of the eyes were done. Conditions requiring further evaluation and treatment were referred to the teaching hospital. Data was collected in a structured proforma, and analysed with the Statistical Package for Social Sciences version 21 and the windows WINPEPI software. Chi square testing was used to determine statistically significant differences between the study groups, which was reported to be statistically significant at a p-value of less than 0.05.

Results

The mean age of the children was 18.0 ± 9.6 months for the PEM and 17.8 ± 9.6 months for the non-malnourished group. Most of the children (82% in both study groups) were between

Table 1: Socio-demographic characteristics of both study groups

Socio-demographic characteristics	PEM group	Non-PEM group
Age (in months)		
6 – 12	70 (35%)	70 (35%)
13 – 24	94 (47%)	94 (47%)
25 – 36	28 (14%)	28 (14%)
37 – 59	8 (4%)	8 (4%)
Sex		
Male	114 (57%)	86 (43%)
Female	98 (49%)	102 (51%)
Tribe		
Hausa	190 (95%)	178 (89%)
Fulani	9 (4.5%)	10 (5%)
Yoruba	0 (0%)	6 (3%)
Others	1 (0.5%)	6 (3%)
Religion		
Islam	200 (100%)	196 (98%)
Christianity	0 (0%)	4 (2%)
Maternal educational level		
None	30 (15%)	8 (4%)
Quranic	96 (48%)	46 (23%)
Primary	35 (17.5%)	34 (17%)
Secondary	33 (16.5%)	72 (36%)
Tertiary	6 (3%)	40 (20%)

6 – 24 months. Males constituted 114 (57%) of the PEM group and 98 (49%) of the non-malnourished group. Majority of the study participants were Hausa and Muslim [Table 1].

Children with PEM had higher odds of ocular complaints compared to those without PEM. [$\chi^2 = 13.176$, OR = 2.201, 95% CI (1.432, 3.382), $P < 0.001$]. The main presenting ocular complaints in the PEM and non-PEM groups were eye discharge (34% vs 15%), redness (9.5% vs 14%), and itching (8% vs 6%) [Table 2].

Children with PEM had statistically significant higher odds of ocular manifestations in general compared to the non-malnourished children [46.5% vs 24%, OR = 2.910 (1.891, 4.477), $p = < 0.001$]. Most notable among these were visual impairment, lid oedema, infective conjunctivitis, and xerophthalmia [Table 3 and Figure 1].

Logistic regression analysis with nutritional status as the predictor variable, and the significant ocular manifestations as the outcome variables, showed that PEM was a significant predictor for infective conjunctivitis ($P = 0.000$, OR = 4.882). However, while visual impairment, lid oedema, and xerophthalmia showed higher odds of occurring in children with PEM, they were not found to be statistically significant on logistic regression. ($p = > 0.05$).

Discussion

The prevalence of ocular manifestations in under five children with PEM in this study is significantly higher than the non-PEM group. The prevalence in this study is higher than that reported from Kolar, India (16.7%),^[3] which was also a comparative cross-sectional study. However, the Kolar study demonstrated a similar trend with ocular manifestations in the malnourished children found to be significantly higher than non-malnourished children. The difference in prevalence may be likely due to the smaller sample size in the Indian study as compared to that in this study. Also, the Indian study did not document the visual status of the children. The prevalence in this study is however similar to that from Khartoum.^[4] These findings suggest a possible link between PEM and increased ocular manifestations.

This study also demonstrated that ocular complaints were significantly higher in children with PEM than those

Table 2: Distribution of ocular complaints among the study groups

Ocular complaints	PEM group	Non-PEM group	Test statistic	p-value	OR	95% CI
Discharge	68 (34%)	30 (15%)	$\chi^2 = 19.516$	< 0.001	2.919;	1.796, 4.746
Redness	19 (9.5%)	28 (14%)	$\chi^2 = 1.953$	0.162	0.645	0.347, 1.197
Itching	16 (8%)	12 (6%)	$\chi^2 = 0.614$	0.433	1.362	0.627, 2.959
Whitish lesions	3 (1.5%)	0 (0%)	FET	0.248	NA	NA
Poor vision	4 (2%)	0 (0%)	FET	0.123	NA	NA
Tearing	3 (1.5%)	8 (4%)	$\chi^2 = 2.337 (1)$	0.126	0.365	0.096, 1.398
Photophobia	3 (1.5%)	0	FET = 3.584	0.123	NA	NA
Night blindness	0 (0%)	0 (0%)	0	NA	NA	NA

NA: Not applicable, OR: Odds ratio, FET: Fisher's exact test

Table 3: Distribution of ocular manifestations between the PEM and non-PEM groups

Ocular manifestations	Study groups		Test statistic	OR (95% CI)	p-value
	PEM group	Non-PEM group			
Ocular complaints	82 (41%)	48 (24%)	$\chi^2 = 13.174$	2.201 (1.432, 3.382)	< 0.001
Visual impairment	6 (3.04%)	0 (0%)	FET	NA	< 0.001
Lid oedema	22 (11%)	0 (0%)	$\chi^2 = 23.280$	NA	< 0.001
Blepharitis	6 (3%)	2 (1%)	FET	NA	0.284
Trichiasis	4 (2%)	0 (0%)	FET	NA	0.123
Entropion	4 (2%)	0 (0%)	FET	NA	0.123
Preseptal cellulitis	1 (0.5%)	0 (0%)	FET	NA	0.499
Allergic conjunctivitis	6 (3%)	10 (5%)	$\chi^2 = 1.042$	0.588 (0.209, 1.649)	0.307
Conjunctival xerosis	6 (3%)	0 (0%)	FET	NA	0.060
Infective conjunctivitis	72 (36%)	34 (17%)	$\chi^2 = 18.534$	2.746 (1.719, 4.388)	< 0.001
Corneal xerosis	6 (3%)	0 (0%)	FET	NA	0.248
Staphyloma	2 (1%)	0 (0%)	FET	NA	0.499
Keratomalacia	1 (0.5%)	0 (0%)	FET	NA	1.000
Exposure keratitis	1 (0.5%)	0 (0%)	FET	NA	1.000
Megalocornea	1 (0.5%)	0 (0%)	FET	NA	1.000
Xerophthalmia	12 (6%)	0 (0%)	$\chi^2 = 12.371$	NA	< 0.001
Strabismus	3 (1.5%)	0 (0%)	FET	NA	0.248
Cataract	1 (0.5%)	0 (0%)	FET	NA	1.000
Optic nerve head atrophy	1 (0.5%)	0 (0%)	FET	NA	1.000
Ocular findings	93 (46.5%)	48 (24%)	$\chi^2 = 24.356$	2.910 (1.891, 4.477)	< 0.001

KEY: FET: Fisher's exact test, OR: Odds ratio, NA: Not applicable since frequency in one cell is 0

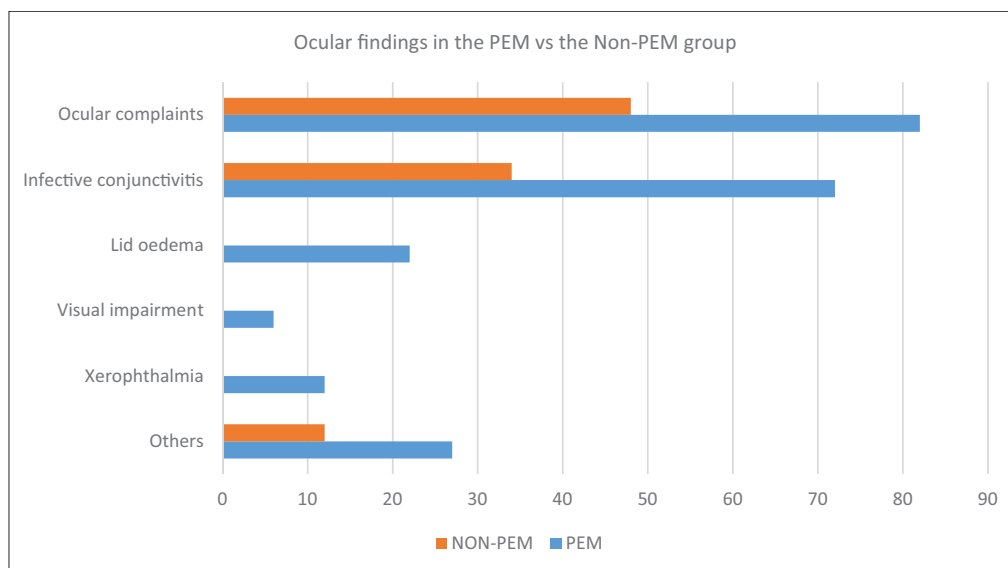


Figure 1: Distribution of ocular findings between both study groups

without PEM. The predominant ocular complaints of discharge, redness and itching in this study are comparable to the findings in Khartoum,^[4] where the major complaints were discharge (28%) and itching (25%). However, it is important to note that the Khartoum study had no control group for comparison. The Kolar study and other studies reviewed did not document ocular complaints and as such could not be used for comparison. Other additional complaints such as whitish lesions of the eyes and poor vision are documented in this study which were not reported in the study from Khartoum. These complaints occurred in

patients with severe eye changes, which may not have been noted in Khartoum due to a much smaller sample size (75 patients) as compared to this study (400 patients). They were considered to be severe because the children affected had irreversible eye changes such as keratomalacia and staphyloma, though one was a case of cataract.

The presence of purulent discharge indicates infection (conjunctivitis), which is quite common in PEM. This is because malnutrition predisposes the body, including the eyes, to a wide range of infections and diseases, such as conjunctivitis, trachoma, and blepharitis.^[5]

Visual impairment was found only in the PEM group in this study, unlike the study in Khartoum^[4] which did not report visual impairment in their study population. This difference may be due to their smaller sample size. The study from Kolar, India^[3] did not assess visual status.

Lid oedema was the commonest eyelid finding in the PEM group. There was no lid oedema in the control group. Other findings included blepharitis, trichiasis, entropion, and preseptal cellulitis, which were found not to be significantly different from the control group. This is similar to the study from Khartoum^[4] which also showed lid oedema as the commonest eyelid finding (46.67%). However, the figure from Khartoum is higher than the results from this study probably due to a higher percentage of children with Kwashiorkor. Hypoproteinaemia leading to hypo-albuminaemia, in addition to micronutrient deficiency, oxidative stress, and glutathione deficiency, all contribute to the lid oedema commonly seen in Kwashiorkor.^[6] Other reviewed studies from Kolar, India, and Ethiopia, did not report lid oedema among their abnormal ocular findings.

Another study in Ethiopia^[7] however showed blepharitis as the most notable finding (13.3%). Blepharitis (0.77%) and sty (1.15%) were the only eyelid findings in the Kolar study.^[3] Trachoma was also a notable finding from Khartoum (14.67%)^[4] and Ethiopia (12%),^[7] which was not found in any patients in this study. These differences may indicate regional variability in ocular manifestations in PEM, especially when we consider the endemicity of trachoma in some of these countries.

Infective conjunctivitis was the commonest ocular examination finding in both study groups but was more likely to occur in the children with PEM. Conjunctival xerosis was also found to be significantly associated with PEM. These reports are comparable to the findings from Khartoum^[4] where infective conjunctivitis (46.67%) was also the commonest examination finding, and conjunctival xerosis was also a notable finding. Infective conjunctivitis occurs due to predisposing factors such as structural damage to epithelial tissue, and decreased cell mediated immunity associated with PEM.^[8]

Corneal xerosis, keratomalacia, and staphyloma were notable features of xerophthalmia in the PEM group that were not seen in the control group. Xerophthalmia was found to be significantly associated with PEM as compared to the non-PEM group. The study from Khartoum^[4] also reported corneal xerosis, keratitis, and corneal opacity in their study population, while Reddy *et al*^[9] in America also reported similar occurrence of corneal lesions in malnourished children examined. Rubino^[10] in Italy and Mado^[11] in Zaria, Nigeria, also reported Bitot spots and staphyloma respectively in case reports of children primarily presenting with PEM. A study from Northwest Ethiopia^[12] however reported Bitot spots (4.5%) and night blindness (3.1%) as the commonest features of xerophthalmia, while corneal xerosis and corneal scarring were also documented.

Xerophthalmia was marginally higher in this study than the values reported from the Khartoum study^[4] which found xerophthalmia in 4% of children with PEM. The findings of this study are however slightly lower than the 7.7% and 8.3% from Kolar, India,^[3] and Northwest Ethiopia^[12] respectively.

There were limited findings noted in the anterior chamber, pupils, lens and posterior segment, (as only one child each was found to have abnormal pupillary reaction, cataract and optic atrophy) in the PEM group. None of these findings were seen in the control group. These vary from the findings reported from Khartoum where retinal haemorrhages were reported in three children which was found not to be significantly related to PEM. Another survey in Portugal^[13] found fundoscopic alterations such as pale optic nerve, increased disc cup, increased vascular tortuosity, alteration of retinal colour, and retinal pigment epithelium cell atrophy. These were however found in children between the ages of 2 – 11 years who had malnutrition in the first six years of life as a follow up study, rather than under five children presenting for the first time with PEM as was the case in this study and the Khartoum study.^[4] Most of the other studies reviewed did not report any posterior segment abnormalities.

PEM was demonstrated on regression analysis to be a significant risk factor for infective conjunctivitis and not the other abnormal ocular findings documented in this study. The other studies reviewed did not perform regression analysis to determine if PEM was a predictor of any of the ocular findings they reported.

Conclusion

PEM is still associated with a significantly higher risk of varying severities of ocular morbidity, several of which could progress to irreversible childhood blindness. Most notable were infective conjunctivitis, and potentially blinding stages of xerophthalmia.

Financial support and sponsorship

Nil.

Conflicts of interest

There are no conflicts of interest.

References

1. Müller O, Krawinkel M. Malnutrition and health in developing countries. *CMAJ* 2005;173:279-86.
2. Menon K, Vijayaraghavan K. Sequelae of severe xerophthalmia—a follow-up study. *Am J Clin Nutr* 1980;33:218-20.
3. Singh P, Kumar R, Das S. A clinical study of prevalence of ocular manifestations in malnourished children attending Anganwadi centres in urban slum areas. *Int J Med Res Rev* 2017;5:956-61. doi:10.17511/ijmrr.2017.i11.07
4. Medani Ahmed UB. Ocular manifestations of severe protein energy malnutrition in Sudanese children (master's thesis on the internet). Khartoum: University of Khartoum; 2003. Available from <https://khartoumspace.uofk.edu>. Date assessed 7th June, 2019.

5. Rabindram, Gedam DS. Ocular manifestations of childhood malnutrition – an overview. *Int J Med Res Rev* 2017;5:925-6.
6. Scully C. Dietary factors and health and disease; In Scully's Medical Problems in Dentistry. 7th ed. Amsterdam: Elsevier Inc.; 2014.
7. Moore DB, Shirefaw W, Tomkins-Netzer O, Eshete Z, Netzer-Tomkins H, Ben-Zion I. Prevalence of xerophthalmia among malnourished children in rural ethiopia. *Int Ophthalmol* 2013;33:455-9.
8. Fakhir S, Ahmad P, Faridi MA, Rattan A. Cell-mediated immune responses in malnourished host. *J Trop Pediatr* 1989;35:175-8.
9. Reddy V, Bhaskaram P, Raghuramulu N, Milton RC, Rao V, Madhusudan J, *et al.* Relationship between measles, malnutrition, and blindness: A prospective study in indian children. *Am J Clin Nutr* 1986;44:924-30.
10. Rubino P, Mora P, Ungaro N, Gandolfi SA, Orsoni JG. Anterior segment findings in vitamin A deficiency: A case series. *Case Rep Ophthalmol Med* 2015;2015:181267.
11. Mado SM, Idris HW, Abdullahi SM, Musa S. Anterior staphyloma in a 6-month old, severely malnourished child following measles. A case report. *Sub-Saharan Afr J Med* 2018;5:29-31.
12. Belete GT, Fenta AL, Hussen MS. Xerophthalmia and its associated factors among school-age children in amba giorgis town, northwest ethiopia, 2018. *J Ophthalmol* 2019;2019:5130904.
13. Brandt CT, Leal DN. Ocular manifestations in patients who had malnutrition in the first six months of life. *Arq Bras Oftalmol* 2005;68:753-6.