


## ORIGINAL ARTICLE

# Comparison of small intestinal contrast ultrasound with magnetic resonance enterography in pediatric Crohn's disease

Aishah Hakim,\* Christopher Alexakis,<sup>†</sup> James Pilcher,<sup>‡</sup> Demitrios Tzias,<sup>‡</sup> Sally Mitton,<sup>§</sup> Thankam Paul,<sup>§</sup> Sonia Saxena,<sup>¶</sup> Richard Pollok\*,<sup>†</sup> and Shankar Kumar<sup>||</sup> 

\*Medical School, St George's Hospital, Departments of <sup>†</sup>Gastroenterology, <sup>‡</sup>Radiology, <sup>§</sup>Paediatric Gastroenterology, St George's University Hospitals NHS Foundation Trust, <sup>¶</sup>Child Health Unit, School of Public Health, Imperial College London and <sup>||</sup>Centre for Medical Imaging, University College London, London, UK

### Key words

Crohn's disease, gastroenterology, imaging, pediatric Crohn's disease, small bowel, small intestine, ultrasound.

Accepted for publication 30 June 2019.

### Correspondence

Dr Shankar Kumar, Centre for Medical Imaging, University College London, 2nd Floor Charles Bell House, 43-45 Foley Street, London, W1W 7TS, UK.

Email: shankar.kumar@ucl.ac.uk

**Declaration of conflict of interest:** SK is supported by the National Institute for Health Research (NIHR) Academic Clinical Fellowship Scheme. SS is supported by a National Institute for Health Research Career Development Fellowship (NIHR CDF-2011-04-048). The views expressed in this publication are those of the author(s) and not necessarily those of the NHS, the NIHR, or the Department of Health. AH, JP, CA, DT, SM, TP, and RP have nothing to declare.

**Author contribution:** SK, RP, and AH conceived and designed the study; RP and SK led and coordinated the study. JP and DT performed the ultrasound studies in the older patient group. AH, SK, and CA collated and analyzed the data. SK drafted the manuscript which was revised by all authors.

## Introduction

Crohn's disease (CD) occurs in approximately four children per 100 000 in Europe and North America, and its incidence is rising.<sup>1–3</sup> CD affects the small bowel in as many as two thirds of pediatric cases.<sup>4</sup> Diagnosis is often difficult as children may not present with the classical triad of diarrhea, pain, and weight loss.<sup>5</sup> Delays in diagnosis and treatment can lead to growth retardation and pubertal delay, often advanced by the time a diagnosis is made.<sup>6,7</sup> There is also an increased risk of developing complications such as intestinal strictures and fistulae.<sup>8–10</sup>

## Abstract

**Aim:** To compare the diagnostic yield of small intestinal contrast ultrasonography (SICUS) with magnetic resonance enterography (MRE) in routine clinical practice in a cohort of pediatric patients investigated for Crohn's disease (CD) attending a UK tertiary center.

**Methods and Results:** Patients with suspected or established CD who underwent SICUS were identified retrospectively. SICUS was compared to conventional trans-abdominal ultrasound (TUS), ileocolonoscopy (IC), and MRE. The accuracy and agreement of SICUS in detecting small bowel lesions and CD-related complications were assessed using kappa ( $\kappa$ ) coefficient statistics. A total of 93 patients (median age 15 years, range 2–17, 49 male) underwent SICUS; 58 had suspected and 35 had established CD. In suspected CD, sensitivity and specificity of SICUS in detecting CD small bowel lesions were 81.8 and 100% and for TUS 85.7 and 87.5%, respectively. In established CD, sensitivity and specificity of SICUS were 98.7 and 100% and TUS 80 and 100%, respectively. Agreement between SICUS and IC was substantial for the presence of lesions ( $\kappa = 0.73$ ) but fair in TUS ( $\kappa = 0.31$ ). Agreement between SICUS and IC was almost perfect for detecting strictures ( $\kappa = 0.84$ ), with a sensitivity of 100% and specificity of 97.6%. When comparing SICUS and TUS with MRE, agreement for the presence of lesions was substantial ( $\kappa = 0.63$ ) and moderate ( $\kappa = 0.53$ ), respectively. Agreement between SICUS and MRE was substantial for detecting strictures ( $\kappa = 0.77$ ) and dilatation ( $\kappa = 0.68$ ).

**Conclusions:** SICUS offers a radiation-free alternative for assessing pediatric small bowel CD, with diagnostic accuracy that is comparable to MRE and IC, supporting its wider use in routine practice.

The relapsing nature of CD necessitates intermittent, but lifelong, radiological assessment, commonly undertaken in the past with small bowel follow-through (SBFT) and CT enterography.<sup>11,12</sup> However, retrospective studies have confirmed that both adults and children with CD may have high levels of cumulative exposure to diagnostic ionizing radiation, drawing attention to the need for alternative, accurate, radiation-free techniques.<sup>13–17</sup> In view of this, magnetic resonance enterography (MRE) is now more frequently used to assess pediatric CD, providing an accurate tool to assess disease extent and distribution, depicting

both intestinal and extraintestinal disease-related complications.<sup>18</sup> It is favored due to its inherent multiplanar capability and ability to provide excellent soft-tissue contrast resolution without exposure to ionizing radiation.<sup>19</sup> However, it is expensive, time-consuming, and sometimes poorly tolerated, particularly in children who may not be able to lie still during the procedure without a general anesthetic.

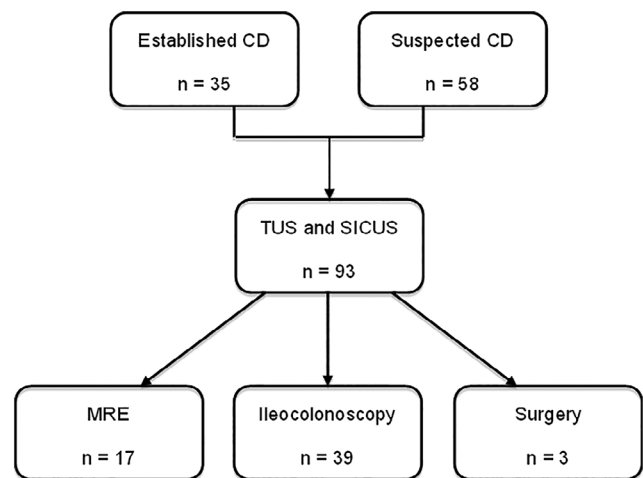
Transabdominal ultrasound (TUS) has been used to evaluate small bowel CD in both children and adults but may be hampered by the presence of endoluminal gas, which can obscure pathology.<sup>20,21</sup> Administering oral contrast before performing abdominal ultrasound distends the small bowel and improves bowel wall visualization. Studies have validated small intestinal (oral) contrast-enhanced ultrasonography (SICUS) in evaluating adults with CD,<sup>22–25</sup> but very few studies in children, for whom this imaging technique is well suited, have been published, and none have evaluated its use in routine clinical practice.<sup>26,27</sup> Here, we describe our 5-year experience of SICUS in routine clinical practice, introduced as part of service improvement at a single regional referral center, retrospectively comparing its diagnostic accuracy to conventional TUS, MRE, and ileocolonoscopy (IC) in evaluating children and adolescents with suspected or established CD.

## Methods

The study protocol was approved by the hospital's local ethics and research and development committees as part of an ongoing local audit of service development. Patient confidentiality was maintained through the anonymization of collected data. We followed the Standards for Reporting of Diagnostic Accuracy (STARD) criteria for reporting studies considering diagnostic accuracy.<sup>28</sup>

**Study design and setting.** Since January 2009, SICUS has been available for children and adolescents with signs and symptoms of small intestinal disease, in addition to conventional investigations, and has been performed at the discretion of the responsible clinician. We retrospectively identified all patients younger than 18 years of age who had been assessed by SICUS between January 2009 and December 2013 from the radiology information system database, cross-referenced with the ultrasound department's booking diary to ensure a comprehensive dataset. We also determined which of these patients with CD underwent bowel resection within 6 months of undergoing SICUS or MRE from electronic patient records. Their surgical notes were reviewed along with TUS, IC, and MRE reports, performed within 6 months of the SICUS study (Fig. 1). We collated demographic data, C-reactive protein (CRP), erythrocyte sedimentation rate (ESR), and fecal calprotectin (FC) within 2 weeks of each imaging investigation as surrogate markers of disease severity. Radiological findings were compared to assess the accuracy and agreement of SICUS in diagnosing CD and its related complications, including proximal dilatation.

**Features of CD.** A diagnosis of small bowel CD was entertained if SICUS detected one or more of the following features in the context of a consistent clinical presentation: (i) increased bowel wall thickness  $\geq 3$  mm; (ii) absence of



**Figure 1** Flow diagram showing the investigations that the study cohort underwent. CD, Crohn's disease; MRE, magnetic resonance enterography; SICUS, small intestine contrast-enhanced ultrasonography; TUS, transabdominal ultrasound.

peristalsis; (iii) stiffened bowel loop, defined as an intestinal loop that remained unchanged during transabdominal compression with the ultrasound probe; (iv) presence of a stricture, fistula, or abscess; (v) absence of wall stratification; (vi) increased mural or mesenteric power Doppler (vascular) activity; (vii) mesenteric lymph node hypertrophy; and (viii) fat creep caused by mesenteric fat hypertrophy.<sup>22</sup>

## Radiology

**Small intestinal contrast ultrasonography.** After a 6-h fast, a baseline ultrasound of the abdomen and pelvis was performed using either an Aplio XG (Toshiba Medical Systems, Tochigi, Japan) with a 1.5–6 MHz curvilinear array or a Logic 9 (GE Healthcare, Milwaukee, WI, USA) with a 2–5 MHz curvilinear array to assess for any solid visceral pathology that might explain the patient's presenting symptoms. Initial small bowel evaluation was also undertaken, looking for any areas of bowel wall thickening, loss of normal wall stratification, or mesenteric thickening, using a combination of high-frequency curvilinear and linear transducers (3–9 and 6–11 MHz on the Aplio and 4–12 MHz on the Logic 9). The patient then consumed the contrast medium: pediatric formulation polyethylene glycol (Movicol). Each sachet of contrast medium was dissolved in 250 mL tap water in preparation for SICUS. For children weighing less than 50 kg, one to three sachets, according to their weight, were used at the discretion of the radiologist; otherwise, four sachets were used. Intermittent scans were then performed over the next 30 min or until the solution had moved through to the distal ileum. Features of the small bowel were confirmed by its location, mucosal fold pattern, and its motility. Adjacent bowel loops were displaced by graded compression, and this also permitted bowel wall stiffness to be determined. Power Doppler was used to assess intramural and adjacent mesenteric vascularity when considering abnormal loops of the small bowel. For both ultrasound systems, the parameters were optimized toward low-

volume flow while trying to avoid excessive flash artifact. A pulse repetition frequency (PRF) of 800 Hz was used, with a low to medium wall filter, and the gain was adjusted to just below the noise floor. Scans were performed or supervised by two experienced radiologists with a subspecialty interest in ultrasonography (JP and RA).

**Magnetic resonance enterography.** Scans were performed using a Siemens 1.5T scanner (Siemens UK, Frimley, Surrey, UK) with an eight-channel body coil. All patients attended 90 min prior to the scan and were asked to drink an oral contrast mix comprising 1 L of water (to fill the bowel), four scoops of Vitaquick thickener, and 5 mg of metoclopramide hydrochloride. Patients were instructed to drink the first cup quickly and the remainder gradually over 45 min. A drug history was taken to verify that there were no contraindications to the antimuscarinic hyoscine butylbromide (Buscopan), given to reduce intestinal motility. Patients and/or their parents were also made aware of the potential adverse effects of mannitol and asked to empty their bladder prior to scanning.

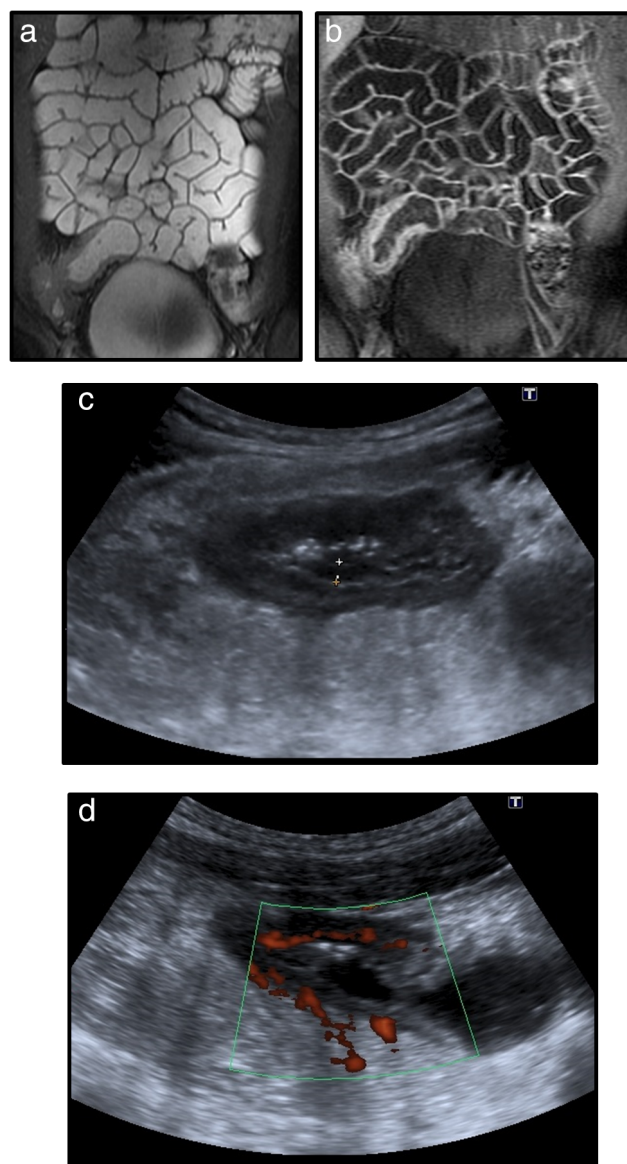
Patients were positioned prone to reduce peristalsis and the number of imaging slices required. The following three sequences were obtained to image the entire small bowel: localizers, coronal 2D FIESTA, coronal T2 Fat Sat, coronal lava, Axial T2, coronal lava postcontrast 30 s, coronal lava postcontrast 70 s, and axial lava postcontrast. Coronal T2 fat saturation and axial lava were also acquired to image the terminal ileum exclusively. MRE was reported by JV and other members of the department.

**Statistical analysis.** The sensitivity and specificity of SICUS in identifying CD were calculated according to the final clinical diagnosis (gold standard), determined by the treating gastroenterologist, taking into account clinical history, examination findings, biochemical results, and imaging findings other than those of SICUS. Consistency between investigations was tested by Cohen's kappa coefficient statistical analysis ( $\kappa$ ), with 0–0.20 indicating slight agreement, 0.21–0.40 fair, 0.41–0.60 moderate, 0.61–0.80 substantial, and 0.81–1 almost perfect agreement. CRP, ESR, and FC were compared using a paired Student's *t*-test.

## Results

A total of 93 patients underwent SICUS during the study period (median age 15 years, range 2–17, 49 male), with 58 having suspected and 35 established CD. Figure 2 illustrates small bowel complications identified by SICUS and MRE in a representative patient with CD.

**SICUS versus MRE.** Seventeen patients were assessed with both SICUS and MRE (median age 15.1 years, range 8–17, 10 male). No difference was found in markers of disease severity at the time of each radiological investigation, SICUS (CRP  $24.4 \pm 33.3$ , ESR  $21.1 \pm 22.8$ , FC  $514.8 \pm 830.5$ ), and MRE (CRP  $19.1 \pm 18.4$ , ESR  $26.9 \pm 18.5$ , FC  $1266.6 \pm 1070.6$ );  $P = 0.18$ , 0.92, and 0.18, respectively. The mean interval between SICUS and MRE was 108.9 days  $\pm$  SD 54.5. Comparative statistical data are provided in Table 1. Agreement between TUS and MRE was moderate ( $\kappa = 0.53$ ) for the presence of lesions but substantial between SICUS and MRE ( $\kappa = 0.63$ ). In



**Figure 2** A 16-year-old male with Crohn's disease. (a) Coronal magnetic resonance enterography (MRE), gradient Echo (GRE) sequence (2D FIESTA), demonstrating bowel wall thickening affecting the terminal ileum, caecum, and appendix. (b) Coronal MRE, 3D, T1-weighted sequence with fat suppression and intravenous gadolinium contrast administration (LAVA) at 70s postinjection, demonstrating avid enhancement of the thickened segment of bowel. (c) Selected small intestinal contrast ultrasonography (SICUS) images demonstrating the same loop of terminal ileum, with bowel wall thickening and edema (hypoechoic change), decreased luminal diameter, and (d) increased vascularity on Doppler imaging.

our cohort, SICUS correctly identified 3 of 4 proximal bowel lesions, and 9 of 10 distal small bowel lesions were detected by MRE. Agreement between SICUS and MRE was substantial in detecting both strictures ( $\kappa = 0.77$ ) and dilatation ( $\kappa = 0.68$ ). SICUS identified two cases of small dilatation not identified by MRE.

**Table 1** Comparing small intestinal contrast ultrasonography with the reference standard of magnetic resonance enterography in pediatric Crohn's disease

	MRE	SICUS				Kappa	Sensitivity	Specificity
		TP	FP	TN	FN			
Presence of lesion	11	9	1	5	2	0.63 (0.25–1)	0.82 (0.48–0.97)	0.83 (0.36–0.97)
Site: distal	10	9	0	6	1	0.87 (0.63–1)	0.9 (0.55–0.98)	1 (0.54–1)
Site: proximal	4	3	0	6	1	0.78 (0.39–1)	0.75 (0.20–0.96)	1 (0.54–1)
Stricturing disease	3	2	0	14	1	0.77 (0.34–1)	0.67 (0.12–0.95)	1 (0.77–1)
Site of stricture	3	2	0	14	1	0.77 (0.34–1)	0.67 (0.12–0.95)	1 (0.77–1)
Dilatation	3	3	2	12	0	0.68 (0.26–1)	1 (0.31–1)	0.86 (0.56–0.97)

95% confidence intervals given in brackets.

FN, false negative; FP, faecal calprotectin; MRE, magnetic resonance enterography; SICUS, small intestinal contrast ultrasonography; TN, true negative; TP, true positive.

**TUS versus SICUS.** When comparing sonographic findings before and after contrast administration, the sensitivity and specificity of detecting CD small bowel lesions in those with suspected disease were 85.7 and 87.5% for TUS and 98.7 and 100% for SICUS, respectively. In patients with known CD, sensitivity and specificity of TUS were 80.0 and 100% and 97.3 and 100% for SICUS, respectively.

**SICUS versus IC.** Thirty-nine patients were evaluated with both TUS/SICUS and IC, with a mean interval of 89.7 days  $\pm$  SD 76.5 between investigations. Inflammatory markers at the time of SICUS (CRP 24.4  $\pm$  33.3, ESR 21.1  $\pm$  22.8, FC 514.8  $\pm$  830.5) and IC (CRP 21.1  $\pm$  31.8, ESR 26.9  $\pm$  23.3, FC 686.6  $\pm$  949.4) were not significantly different ( $P = 0.39, 0.18$  and  $0.77$ , respectively). Agreement between SICUS and TUS with IC for the presence of terminal ileal lesions was substantial ( $\kappa = 0.73$ , 95% CI 0.43–1.0) and fair ( $\kappa = 0.31$ , 95% CI 0.09–0.71), respectively. Agreement between SICUS and IC was almost perfect for detecting strictures ( $\kappa = 0.84$ , 95% CI 0.54–1), with 100% sensitivity and 97.5% specificity.

**SICUS versus surgery.** Three patients underwent resective bowel surgery, all within 2 months of SICUS evaluation (range 24–60 days). At surgery, terminal ileal disease and wall thickening was noted in all three cases, corroborating SICUS findings. In one patient, a 5 cm ileocolonic stricture was present at operation, and in another, a colovesical fistula was identified; SICUS correctly delineated both CD-related complications.

## Discussion

As clinical symptoms and signs may lag behind intestinal mucosal disease activity in CD, disease monitoring using biochemical markers, cross-sectional imaging, and endoscopy is important.<sup>29,30</sup> This approach aims to identify subclinical disease to allow timely diagnosis and medical therapy and to monitor mucosal response to treatment with the aim of reducing the need for surgery. However, the requirement for more frequent imaging increases the potential risks of a high cumulative exposure to ionizing radiation for the patient when performing small bowel barium studies and CT imaging; this is particularly relevant in children and adolescents amongst whom there is a rising incidence.<sup>2,31</sup> MRE has therefore emerged as the preferred imaging

technique in evaluating small bowel CD as it avoids this while offering high sensitivity and specificity in diagnosing CD.<sup>32</sup> Its drawback is a lack of availability, high relative cost, and difficulty performing it in young children who may be unable to lie still during image acquisition without a general anesthetic. Our study, the first to compare the use of SICUS with MRE in routine clinical practice in a pediatric cohort, suggests that SICUS offers a satisfactory alternative with comparable diagnostic yield. Agreement between SICUS and MRE was substantial for detecting small bowel lesions ( $\kappa = 0.63$ ) and stricturing disease ( $\kappa = 0.77$ ). Furthermore, SICUS had near-perfect agreement with IC in detecting terminal ileal disease ( $\kappa = 0.87$ ).

TUS is an inexpensive, readily available option in the assessment of pediatric CD, with a reported sensitivity of between 74 and 88%.<sup>33–35</sup> Some groups have demonstrated results comparable to MRE,<sup>36,37</sup> but it can fail to detect proximal small bowel lesions reliably, with reported sensitivity as low as 50%.<sup>26</sup> This has led to interest in administering oral contrast prior to ultrasonography to promote bowel loop distension to enhance the clarity of visualization of adjacent bowel loops.<sup>38</sup> In our cohort, SICUS proved to be superior in terms of both sensitivity and specificity when compared to TUS in defining small bowel lesions.

We found agreement between SICUS and MRE to be substantial in identifying small bowel lesions, stricturing disease, and wall dilatation. In a prospective pediatric case series, Pallotta *et al.* reported that SICUS correlated well with SBFT in both identifying small bowel lesions and assessing their length.<sup>26</sup> They found the agreement between SICUS and SBFT to be almost perfect in delineating both distal and proximal disease ( $\kappa = 0.93$ ). In another recent Italian study,<sup>27</sup> SICUS had a higher sensitivity than MRE in detecting jejunal disease (92 vs 75%), which occurs more commonly in pediatric CD.<sup>10</sup> The sensitivity of MRE was slightly higher than SICUS in detecting lesions of the proximal and mid ileum (100 vs 80%, respectively) and identical (94%) for detecting terminal ileal disease. They also reported that MRE and SICUS were both well tolerated. In our study, SICUS fared well when compared to MRE with substantial/almost perfect agreement for both proximal ( $\kappa = 0.78$ ) and distal lesions ( $\kappa = 0.87$ ).

While we did not formally assess the tolerability of SICUS and MRE in this retrospective study, anecdotally, clinicians, patients, and parents reported that SICUS was well tolerated,

sometimes better so than MRE. It appeared to be particularly suited to young patients who may otherwise struggle to lie still in the enclosed environment of an MR scanner. Indeed, MRE can be problematic in those under 8 years of age, and a general anesthetic is often required, which is not always straightforward. SICUS offers a promising alternative in the very young as it can be performed using a nasogastric tube without a general anesthetic in patients as young as 2 years of age in our cohort.

Our study is limited by its retrospective design, small sample size, and the fact that it was undertaken in a single regional center. It is that possible disease progression may have occurred in the interval between SICUS and other investigations. This was considered unlikely because the ESR, CRP, and FC, all validated surrogate markers of disease activity, were not significantly different at the time of each investigation.<sup>39,40</sup> All SICUS studies were performed independently by one of three radiologists, but the retrospective design did not allow assessment of interobserver variability. Finally, the evaluation of SICUS as part of service development prevented masking of the multidisciplinary team from the results, a potential confounder, although SICUS was usually performed as the first investigation. In terms of training new personnel, it has been established in adults that SICUS performed by an inexperienced ultrasonographer can achieve better diagnostic accuracy over conventional TUS performed by an experienced sonographer in the detection of small bowel pathology in CD; nevertheless, there is clearly a learning curve.<sup>41</sup> We chose not to reevaluate and rereport MRE images as it was believed that, first, the study aimed to compare SICUS and MRE in routine clinical practice, and second, because SICUS is a dynamic test that cannot easily be accurately reported retrospectively without defined and stored cine clips, it would favor MRE if additional features were identified on reevaluation. Clearly the small size of this study means our findings must be interpreted cautiously. However, this is the first study to evaluate SICUS against MRE in a pediatric cohort in a real-world setting.

In conclusion, our findings provide preliminary evidence to suggest that SICUS offers a comparable diagnostic yield to that of MRE and IC and performed better than TUS in a pediatric cohort with suspected or established CD. Our work comparing SICUS and MRE in routine clinical practice adds to the existing, albeit very limited evidence, that SICUS offers a radiation-free alternative to MRE for the evaluation of CD in children and adolescents. Our findings support its wider adoption in this age group. Further dedicated prospective comparative studies of SICUS and MRE, such as the United Kingdom-based MR Enterography or ulTrasound In Crohn's disease (METRIC) trial in adults, are now needed in children.<sup>42</sup>

## Acknowledgments

We thank Dr. Rosemary Allan (RA), who performed and reported the ultrasound examinations in the younger patient group, and Dr. Ioannis 'Johnny' Vlahos (JV), who reported the MR enterography examinations as part of their routine clinical practice, alongside other members of staff in the department of Radiology at St George's University Hospitals NHS Foundation Trust. We are also grateful to them for their constructive review and critique of early drafts of the manuscript. We also thank

Dr. Nkem Onyeador for reviewing the manuscript prior to submission.

## References

- 1 Benchimol EI, Fortinsky KJ, Gozdyra P, Van den Heuvel M, Van Limbergen J, Griffiths AM. Epidemiology of pediatric inflammatory bowel disease: a systematic review of international trends. *Inflamm. Bowel Dis.* 2011; **17**: 423–39.
- 2 Henderson P, Hansen R, Cameron FL *et al.* Rising incidence of pediatric inflammatory bowel disease in Scotland. *Inflamm. Bowel Dis.* 2012; **18**: 999–1005.
- 3 Vernier-Massouille G, Balde M, Salleron J *et al.* Natural history of pediatric Crohn's disease: a population-based cohort study. *Gastroenterology.* 2008; **135**: 1106–13.
- 4 Diefenbach KA, Breuer CK. Pediatric inflammatory bowel disease. *World J. Gastroenterol.* 2006; **12**: 3204–12.
- 5 Sawczenko A, Sandhu BK. Presenting features of inflammatory bowel disease in Great Britain and Ireland. *Arch. Dis. Child.* 2003; **88**: 995–1000.
- 6 Kim SC, Ferry GD. Inflammatory bowel diseases in pediatric and adolescent patients: clinical, therapeutic, and psychosocial considerations. *Gastroenterology.* 2004; **126**: 1550–60.
- 7 Hildebrand H, Karlberg J, Kristiansson B. Longitudinal growth in children and adolescents with inflammatory bowel disease. *J. Pediatr. Gastroenterol. Nutr.* 1994; **18**: 165–73.
- 8 Cuffari C, Darbari A. Inflammatory bowel disease in the pediatric and adolescent patient. *Gastroenterol. Clin. North Am.* 2002; **31**: 275–91.
- 9 Kugathasan S, Denson LA, Walters TD *et al.* Prediction of complicated disease course for children newly diagnosed with Crohn's disease: a multicentre inception cohort study. *Lancet.* 2017; **389**: 1710–18.
- 10 Van Limbergen J, Russell RK, Drummond HE *et al.* Definition of phenotypic characteristics of childhood-onset inflammatory bowel disease. *Gastroenterology.* 2008; **135**: 1114–22.
- 11 North American Society for Pediatric Gastroenterology, Hepatology and Nutrition, Colitis Foundation of America, Bousvaros A *et al.* Differentiating ulcerative colitis from Crohn disease in children and young adults: report of a working group of the North American Society for Pediatric Gastroenterology, Hepatology, and Nutrition and the Crohn's and Colitis Foundation of America. *J. Pediatr. Gastroenterol. Nutr.* 2007; **44**: 653–74.
- 12 Reid JR, Pozzuto J, Morrison S, Obuchowski N, Davros W. Comparison of gonadal radiation doses from CT enterography and small-bowel follow-through in pediatric patients. *AJR Am. J. Roentgenol.* 2015; **204**: 615–9.
- 13 Sauer CG, Kugathasan S, Martin DR, Applegate KE. Medical radiation exposure in children with inflammatory bowel disease estimates high cumulative doses. *Inflamm. Bowel Dis.* 2011; **17**: 2326–32.
- 14 Sauer CG. Radiation exposure in children with inflammatory bowel disease. *Curr. Opin. Pediatr.* 2012; **24**: 621–6.
- 15 Huang JS, Tobin A, Harvey L, Nelson TR. Diagnostic medical radiation in pediatric patients with inflammatory bowel disease. *J. Pediatr. Gastroenterol. Nutr.* 2011; **53**: 502–6.
- 16 Chatu S, Subramanian V, Pollok RC. Meta-analysis: diagnostic medical radiation exposure in inflammatory bowel disease. *Aliment. Pharmacol. Ther.* 2012; **35**: 529–39.
- 17 Zakeri N, Pollok RC. Diagnostic imaging and radiation exposure in inflammatory bowel disease. *World J. Gastroenterol.* 2016; **22**: 2165–78.
- 18 Pomerri F, Al Bunni F, Zuliani M *et al.* Assessing pediatric ileocolonic Crohn's disease activity based on global MR enterography scores. *Eur. Radiol.* 2017; **27**: 1044–51.

- 19 Brenner DJ. Should computed tomography be the modality of choice for imaging Crohn's disease in children? The radiation risk perspective. *Gut*. 2008; **57**: 1489–90.
- 20 Parente F, Maconi G, Bollani S *et al.* Bowel ultrasound in assessment of Crohn's disease and detection of related small bowel strictures: a prospective comparative study versus x ray and intraoperative findings. *Gut*. 2002; **50**: 490–5.
- 21 Dillman JR, Smith EA, Sanchez RJ *et al.* Pediatric small bowel crohn disease: correlation of US and MR enterography. *Radiographics*. 2015; **35**: 835–48.
- 22 Kumar S, Hakim A, Alexakis C *et al.* Small intestinal contrast ultrasonography for the detection of small bowel complications in Crohn's disease: correlation with intraoperative findings and magnetic resonance enterography. *J. Gastroenterol. Hepatol.* 2015; **30**: 86–91.
- 23 Chatu S, Pilcher J, Saxena SK, Fry DH, Pollok RC. Diagnostic accuracy of small intestine ultrasonography using an oral contrast agent in Crohn's disease: comparative study from the UK. *Clin. Radiol.* 2012; **67**: 553–9.
- 24 Pallotta N, Vincoli G, Montesani C *et al.* Small intestine contrast ultrasonography (SICUS) for the detection of small bowel complications in crohn's disease: a prospective comparative study versus intraoperative findings. *Inflamm. Bowel Dis.* 2012; **18**: 74–84.
- 25 Pallotta N, Tomei E, Viscido A *et al.* Small intestine contrast ultrasonography: an alternative to radiology in the assessment of small bowel disease. *Inflamm. Bowel Dis.* 2005; **11**: 146–53.
- 26 Pallotta N, Civitelli F, Di Nardo G *et al.* Small intestine contrast ultrasonography in pediatric Crohn's disease. *J. Pediatr.* 2013; **163**: 778–84 e1.
- 27 Aloï M, Di Nardo G, Romano G *et al.* Magnetic resonance enterography, small-intestine contrast US, and capsule endoscopy to evaluate the small bowel in pediatric Crohn's disease: a prospective, blinded, comparison study. *Gastrointest. Endosc.* 2015; **81**: 420–27.
- 28 Bossuyt PM, Reitsma JB, Bruns DE *et al.* Towards complete and accurate reporting of studies of diagnostic accuracy: the STARD initiative. *Radiology*. 2003; **226**: 24–8.
- 29 Fletcher JG, Fidler JL, Bruining DH, Huprich JE. New concepts in intestinal imaging for inflammatory bowel diseases. *Gastroenterology*. 2011; **140**: 1795–806.
- 30 Rao N, Kumar S, Taylor S, Plumb A. Diagnostic pathways in Crohn's disease. *Clin. Radiol.* 2019; **74**: 578–91.
- 31 Lophaven SN, Lynge E, Burisch J. The incidence of inflammatory bowel disease in Denmark 1980–2013: a nationwide cohort study. *Aliment. Pharmacol. Ther.* 2017; **45**: 961–72.
- 32 Chalian M, Ozturk A, Oliva-Hemker M, Pryde S, Huisman TA. MR enterography findings of inflammatory bowel disease in pediatric patients. *AJR Am. J. Roentgenol.* 2011; **196**: W810–6.
- 33 Faure C, Belarbi N, Mougnot JF *et al.* Ultrasonographic assessment of inflammatory bowel disease in children: comparison with ileocolonoscopy. *J. Pediatr.* 1997; **130**: 147–51.
- 34 Alison M, Kheniche A, Azoulay R, Roche S, Sebag G, Belarbi N. Ultrasonography of Crohn disease in children. *Pediatr. Radiol.* 2007; **37**: 1071–82.
- 35 Darge K, Anupindi S, Keener H, Rompel O. Ultrasound of the bowel in children: how we do it. *Pediatr. Radiol.* 2010; **40**: 528–36.
- 36 Barber JL, Maclachlan J, Planche K *et al.* There is good agreement between MR enterography and bowel ultrasound with regards to disease location and activity in paediatric inflammatory bowel disease. *Clin. Radiol.* 2017; **72**: 590–7.
- 37 Ahmad TM, Greer ML, Walters TD, Navarro OM. Bowel sonography and MR enterography in children. *AJR Am. J. Roentgenol.* 2016; **206**: 173–81.
- 38 Pallotta N, Baccini F, Corazziari E. Small intestine contrast ultrasonography. *J. Ultrasound Med.* 2000; **19**: 21–6.
- 39 Tilakaratne S, Lemberg DA, Leach ST, Day AS. C-reactive protein and disease activity in children with Crohn's disease. *Dig. Dis. Sci.* 2010; **55**: 131–6.
- 40 Quail MA, Russell RK, Van Limbergen JE *et al.* Fecal calprotectin complements routine laboratory investigations in diagnosing childhood inflammatory bowel disease. *Inflamm. Bowel Dis.* 2009; **15**: 756–9.
- 41 Calabrese E, La Seta F, Buccellato A *et al.* Crohn's disease: a comparative prospective study of transabdominal ultrasonography, small intestine contrast ultrasonography, and small bowel enema. *Inflamm. Bowel Dis.* 2005; **11**: 139–45.
- 42 Taylor SA, Mallett S, Bhatnagar G *et al.* Diagnostic accuracy of magnetic resonance enterography and small bowel ultrasound for the extent and activity of newly diagnosed and relapsed Crohn's disease (METRIC): a multicentre trial. *Lancet Gastroenterol. Hepatol.* 2018; **3**: 548–58.