

what's your diagnosis?

A young male presented with acute inguinal pain, bilateral quadriceps weakness and hyperesthesia of anterior thighs post-thrombolysis for acute myocardial infarction

Shekhar Lamdhade,^a Raja Dashti,^b Anil Thussu,^{ac} Raed Alroughani^{ac}

From the ^aDivision of Neurology, Department of Medicine, Amiri Hospital, Sharq, Kuwait; ^bDepartment of Cardiology, Sabah Al-Ahmad Cardiac Center, Sharq, Kuwait; ^cNeurology Clinic, Dasman Diabetes Institute, Dasman, Kuwait

Correspondence: Dr. Raed Alroughani, MD · FRCPC Division of Neurology, Department of Medicine, Amiri Hospital Arabian Gulf Street, Kuwait City, 13041, Kuwait · T: +965 22450005 Ext. 4444, F: +965 22467499 · alroughani@gmail.com

Ann Saudi Med 2014; 34(3): 265-266

DOI: 10.5144/0256-4947.2014.265

A 34-year old male presented with typical anginal pain of duration of one-and-half hours, and he reported a brief transient loss of consciousness. His past reports revealed a history of 4 years of hypertension, hyperlipidemia, and mild renal impairment with baseline serum urea 9.5 mmol/L, creatinine 250 μ mol/L (glomerular filtration rate [GFR] 33mL/min), and raised 24-hour urinary protein 677 mg (normal <150 mg). His medication included Aldomet (Methyldopa) 500 mg thrice a day and Lipanthyl (Fenofibrate) 200 mg twice daily.

In the emergency department, his heart rate was 40/min in sinus rhythm and BP 110/60 mm Hg. His peripheral pulses were well felt, and he had no features of ventricular or congestive cardiac failure. He was fully conscious and oriented, and his systemic examination was unremarkable. His electrocardiography showed features of inferior wall myocardial infarction with complete heart block, and the heart rate normalized with intravenous (IV) Atropine (1 mg). The severity of chest pain was reduced with IV Pethedine 50 mg. Laboratory parameters revealed the following: hemoglobin 13 g/dL, white blood cells 15.4×10^9 , platelets 359×10^9 , prothrombin time (PT) 11/11 s, activated partial thromboplastin time (aPTT) 29/30 s, international normalized ratio (INR) 1.0, troponin 0.05 ng/mL, Na 136 mmol/L, K 3.8 mmol/L, urea 18.1 mmol/L, and serum creatinine 398 μ mol/L (GFR 19.5 mL/min). After the initial workup, a standard thrombolytic therapy in the cardiac care unit was administered using IV Reteplase (10 IU bolus and repeat after 30 min) followed by Heparin 5000 units bolus and 1000 units/h. Two and a half hours later, he developed bilateral conjunctival hemorrhage and mild hematoma at the jugular puncture site. The Heparin

dose was reduced to 800 units/h. Fifteen minutes later, he complained of bilateral moderate to severe inguinal pain. There was no change in hemoglobin and coagulation parameters, but high CK of 5420 IU/L was noted. On Day 2, his jugular hematoma increased in size and hematuria (RBC 4+ in urine) was noted; thus Heparin was stopped. His follow-up hemoglobin was stable with PT 14/11 s, aPTT 107/30 s, and INR 1.3. Passive hip movements aggravated his inguinal pain, and he preferred to lie on the lateral side keeping hips flexed. He could not tolerate the ultrasonographic examination of the abdomen. A drop in his hemoglobin was noticed after 12 hours from 12.6 gm/dL to 9.3 gm/dL, and 1 unit of blood transfusion was subsequently administered. Except for initial hematuria, no obvious major bleeding site was detected clinically. On Day 3, he noticed hyperesthesia over the anterior aspect of both thighs. Motor power could not be assessed due to pain, but absent knee jerks were noted. On day 4, bilateral quadriceps weakness was apparent (MRC grade 2/5) with diminished sensations over anterior thigh. Based on the neurological examination, the possibility of lumbar root or femoral nerve involvement was considered. The urgent ultrasound of abdomen did not reveal any intraabdominal pathology. Noncontrast abdominal computed tomography showed symmetrical prominence of both iliopsoas without any focal blood collection. Magnetic resonance imaging (MRI) of the abdomen showed bilateral enlarged heterogeneous iliopsoas muscles with the areas of hyperintensity (**Figure 1**). Due to progressive renal impairment, he received hemodialysis. His cardiovascular and neurological status remained stable. He improved over the period of 40 days with physiotherapy and was discharged walking unassisted.

what's your diagnosis?

RUNNING HEAD

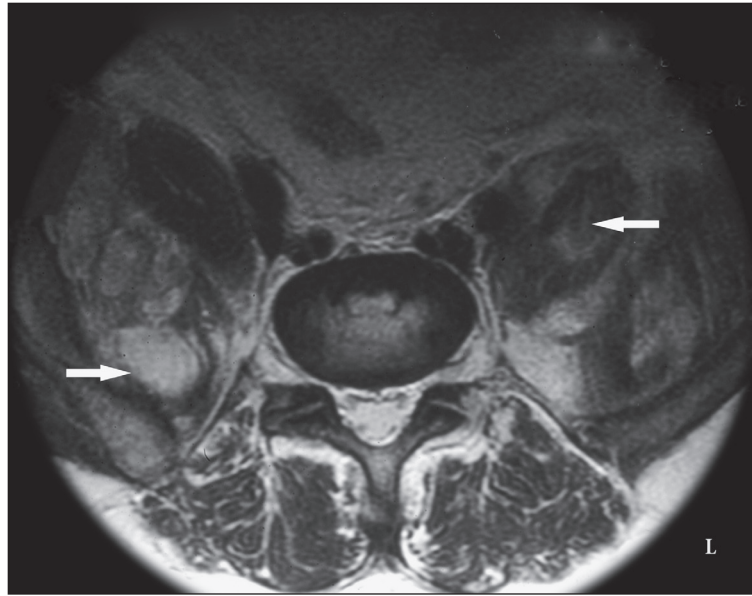


Figure 1. Gadolinium-enhanced axial inversion time MRI sequences of abdomen revealing bilateral enlarged heterogeneous hyperintense signals in both iliopsoas muscles (arrows).

what's your diagnosis?

Answer: Bilateral femoral neuropathy due to bilateral iliopsoas hematoma in a young patient with acute myocardial infarction

Shekhar Lamdhade,^a Raja Dashti,^b Anil Thussu,^{ac} Raed Alroughani^{ac}

From the ^aDivision of Neurology, Department of Medicine, Amiri Hospital, Sharq, Kuwait; ^bDepartment of Cardiology, Sabah Al-Ahmad Cardiac Center, Sharq, Kuwait; ^cNeurology Clinic, Dasman Diabetes Institute, Dasman, Kuwait

Correspondence: Dr. Raed Alroughani, MD · FRCPC Division of Neurology, Department of Medicine, Amiri Hospital Arabian Gulf Street, Kuwait City, 13041, Kuwait · T: +965 22450005 Ext. 4444, F: +965 22467499 · alroughani@gmail.com

Ann Saudi Med 2014; 34(3): 265-266

DOI: 10.5144/0256-4947.2014.265

Spontaneous unilateral iliopsoas hematomas secondary to the use of anticoagulants are increasingly documented in the published reports, but bilateral occurrence is uncommon. **Table 1** summarizes the previous reported cases in the published reports. The incidence of major bleeding during various lytic treatments is approximately 3 times higher than heparin alone. The overall incidence of hemorrhagic complications and intracranial hemorrhage are 10% and 0.8%, respectively.¹ Various medications have been implicated including antiplatelet agents, and oral and intravenous anticoagulants in different clinical settings such as deep vein thrombosis (DVT), transient ischemic attack (TIA), and myocardial infarction (MI) prophylaxis.²⁻⁷

Bleeding is an unwanted complication despite the proper selection of patients and therapeutic monitoring. Common bleeding sites are gastrointestinal tract, soft tissue, and urinary tracts. Unusual sites of bleeding, such as iliopsoas muscles, can be overlooked due to their varied presentation and rarity. The subject of iliopsoas hematomas in acute coronary disease setting has been exhaustively reviewed by Sasson et al. who reported unilateral iliopsoas hematomas in 3 elderly females (aged 73, 79, and 67 years) receiving intravenous (IV) heparin.⁸ They suspected that this complication might be related to advanced age and female gender. Enoxaparin-associated iliopsoas hematoma was also reported in an elderly 83-year-old female with acute non-

Table 1. List of cases of spontaneous bilateral iliopsoas hematomas associated with anticoagulation in the published reports.

N	Age/Sex	Indication	Anticoagulant type	Coagulation level	Onset	Treatment	Author (Y)
1	55/F	DVT	Heparin, Warfarin	Therapeutic	5 d	Surgery	Storen EJ (1978)
2	65/F	MI	Ticlid, Heparin	Normal	9 mo	Conservative	Barontini and Macucci (1986)
3	54/F	PE	Heparin, Warfarin	-	-	Conservative (L) Surgery (R)	Niakan et al. (1991)
4	19/F	DVT	Heparin, Warfarin	Therapeutic	3 wk	Surgery	Jamjoom et al. (1993)
5	85/F	TIA	Heparin, Warfarin	Therapeutic	3 d	Conservative (TCAE)	Wada et al. (2005)
6	70/M	Neurovascular	Heparin	Therapeutic	19 d	Conservative (L) TCAE (R)	Murena et al. (2009)

DVT: Deep vein thrombosis, MI: myocardial infarction, PE: pulmonary embolism, TIA: transient ischemic attack, R: right side, L: left side

Q MI.⁹ Hematomas usually became symptomatic in 5 to 6 days but could present late.^{7,8} In our case, the patient was young, and the first sign of bleeding appeared within 3 hours after thrombolysis.

The patient may complain of poorly localized abdominal, inguinal, or hip pain and can be easily misdiagnosed for musculoskeletal in origin. Flexion deformity of the hip is frequently noted, and a tender mass in the lower abdomen can occasionally be palpated. The defining moment usually appears when there is a drop in hemoglobin with or without abdominal or inguinal pain. Abdominal pain may be the early presentation in iliacus muscle hematoma as it is well capsulated and nondistensible, while psoas muscle can accommodate a large volume of blood and delay the neurological presentation. A total of 600 to 900 mL blood collection was reported in two autopsy cases.¹⁰ Despite many case reports, no single predicting factor could be pinpointed to anticipate why bleeding occurs at this unique place unilaterally or bilaterally. The concurrent use of vasodilators producing local vascular changes might predispose to intramuscular bleeding.¹¹ Clinicians, at most of the times, are baffled because of normal coagulation parameters despite hematoma occurrence and varied presentations.

Features of femoral nerve dysfunction depend on the severity of the nerve entrapment. Motor weakness and or sensory dysfunction may become apparent after some time lag. Whether there is primarily intraneural bleeding or nerve compression due to compartment syndrome has not been clearly identified. We feel that the varied initial clinical presentation of femoral neuropathy could be multifactorial in origin. The speed of bleeding, size of hematoma, elastic properties of capsule, and muscle and nerve susceptibility to pressure are often implicated. In addition, impaired renal function could have contributed to the development of the hematoma and the acceleration of neuropathy as in our case.

In terms of investigations and diagnostics, ultrasound may not detect small hematomas and can be misleading. Although, computed tomography (CT) is more sensitive, the diagnostic value of CT scan for the detection of iliopsoas compartment is limited when the entire muscle is diffusely involved.¹² Furthermore, prominent symmetrical psoas muscle appearance on CT can be a nonspecific feature especially in young person. A recent report suggests an advantage of contrast CT where an active bleeding site can be seen and a therapeutic transcatheter embolization can be performed.¹³ Magnetic resonance imaging (MRI) is the investigation of choice for better differentiation between normal and abnormal psoas muscles, and it seems to be the definitive diagnostic imaging modality.¹⁴

Various management strategies have been tried. In mild-to-moderate cases (as in our patient), conservative management with physical therapy was associated with good neurological outcome. However, the surgical evacuation of hematoma is an invasive intervention, and it is preserved for patients with significant neurological deficits or in patients with massive hematoma resulting in hemodynamic instability despite the management of shock, blood transfusion, and correction of coagulation parameters.⁸ Transcatheter embolization is less invasive and has been found successful.^{13,15} To the best of our knowledge, the occurrence of bilateral iliopsoas hematomas with femoral neuropathy in association with the use of Reteplase has not been reported before in the published studies.

In conclusion, although spontaneous bilateral iliopsoas hematomas in association with thrombolysis are rare with normal anticoagulation parameters, high index of clinical suspicion is a key for early diagnosis. Intramuscular bleeding is not necessarily seen with advanced age. MRI scan is the preferred diagnostic modality. Patient with mild-to-moderate femoral neuropathy can be managed conservatively.

REFERENCES

1. Schulman S, Beyth RJ, Kearon C, Levine MN. Hemorrhagic complications of anticoagulant and thrombolytic treatment: American college of chest physicians evidence based clinical guidelines 8th edition. *Chest* 2008; 133(6 suppl): 257S-298S
2. Storen EJ. Bilateral iliacus hematoma with femoral nerve palsy complicating anticoagulation therapy. *Acta Chir Scand* 1978; 144(3): 181-183.
3. Barontini F, Macucci M. Simultaneous femoral nerve palsy due to hemorrhage in both iliac muscles. *Ital J. Neurol Sci* 1986; 7(4): 463-465.
4. Niakan E, Carbone JE, Adams M, Schroder F. Anticoagulants, psoas hematoma and femoral nerve compression. *American Fam Physician* 1991; 44(6): 2100-2102
5. Jamjoom ZA, al Bakry A, al Momen A, Malabary T, Tahan AR, Yacub B. Bilateral femoral nerve compression by iliacus hematomas complicating anticoagulant therapy. *Surg Today* 1993; 23(6): 535-540.
6. Wada Y, Yanagihara C, Nishimura Y. Bilateral iliopsoas hematomas complicating anticoagulant therapy. *Intern Medi* 2005; 44(6): 641-643.
7. Murena L, Vulcano E, Salvato E, Marano M, ?Angelo F, Cherubino P. Bilateral iliopsoas intramuscular bleeding following anticoagulant therapy with heparin: a case report. *Cases J* 2009; 2:7534.
8. Sasson Z, Mangat I, Peckham KA. Spontaneous iliopsoas hematoma in patients with unstable coronary syndromes receiving intravenous heparin in therapeutic doses. *Can J Cardiol* 1996; 12(5): 5490-5494.
9. Chan-Tack KM. Fatal Spontaneous Retroperitoneal Hematoma Secondary to Enoxaparin: Case Report. *South Med J* 2003; 96(1): 58-60.
10. Turk EE, Verhoff MA, Tsokos M. Anticoagulant-related iliopsoas muscle bleeding leading to fatal exsanguination: report of two autopsy cases. *Am J Forensic Med Pathol* 2002; 23(4): 342-344.
11. Johnston SR, Mather HM. Occult spontaneous intramuscular hemorrhage as a complication of heparin for unstable angina. *Postgrad Med J* 1991; 67(787): 488-489.
12. Lenchik L, Dovgan DJ, Kier R. CT of the iliopsoas compartment: Value in differentiating Tumor, Abscess and hematomas. *AJR Am J Roentgenol* 1993; 162(1): 83-86.
13. Zissin R, Gayer G, Kots E, Ellis M, Bartal G, Griton I. Transcatheter arterial embolization in anticoagulant-related hematoma – a current therapeutic option: A report of four patients and review of the literature. *Int J Clin Pract* 2007; 61(8):1321-1327.
14. Lee JK, Glazer HS. Psoas muscle disorders: MR imaging. *Radiology* 1986; 160(3): 683-687.
15. Quanadli SA, El Hajjam, Mignon F, Bruckert F, Changon S, Lacombe P. Life-threatening spontaneous psoas hematoma treated by trans catheter arterial embolization. *Euro Radiol* 1999; 9(6): 1231-1234.