

Received: 2017.05.01  
Accepted: 2017.05.20  
Published: 2017.05.30

# Outcome of a Modified Laparoscopic Suture Rectopexy for Rectal Prolapse with the Use of a Single or Double Suture: A Case Series of 15 Patients

Authors' Contribution:  
Study Design A  
Data Collection B  
Statistical Analysis C  
Data Interpretation D  
Manuscript Preparation E  
Literature Search F  
Funds Collection G

BCDEF **Daiki Yasukawa**  
ABCDEF **Tomohide Hori**  
BF **Takafumi Machimoto**  
BF **Toshiyuki Hata**  
BF **Yoshio Kadokawa**  
BF **Tatsuo Ito**  
BF **Shigeru Kato**  
BF **Yuki Aisu**  
BF **Yusuke Kimura**  
BF **Yuichi Takamatsu**  
B **Taku Kitano**  
DF **Tsunehiro Yoshimura**

Department of Digestive Surgery, Tenri Hospital, Tenri, Nara, Japan

**Corresponding Author:** Tomohide Hori, e-mail: [horitomo@tenriyorozu.jp](mailto:horitomo@tenriyorozu.jp)  
**Conflict of interest:** None declared

## Case series

**Patient:** —  
**Final Diagnosis:** **Rectal prolapse**  
**Symptoms:** **Bleeding per rectum • constipation**  
**Medication:** —  
**Clinical Procedure:** **Simple technique for rectopexy**  
**Specialty:** **Surgery**

**Objective:** **Unusual setting of medical care**

**Background:** Surgery is considered to be a mainstay of therapy for full-thickness rectal prolapse (FTRP). Surgical procedures for FTRP have been described, but optimal treatment is still controversial. The aim of this report is to evaluate the safety and feasibility of a simplified laparoscopic suture rectopexy (LSR) in a case series of 15 patients who presented with FTRP and who had postoperative follow-up for six months.





**Case Reports:** Fifteen patients who underwent a modified LSR at our surgical unit from September 2010 were retrospectively evaluated. The mean age of the patients was 72.5±10.9 years. All 15 patients underwent general anesthesia, with rectal mobilization performed according to the plane of the total mesorectal excision. By lifting the mobilized and dissected rectum cranially to the promontorium, the optimal point for subsequent suture fixation of the rectum was marked. The seromuscular layer of the anterior right wall was then sutured to the presacral fascia using only one or two interrupted nonabsorbable polypropylene sutures. The mean operative time was 176.2±35.2 minutes, with minimal blood loss. No moderate or severe postoperative complications were observed, and there was no postoperative mortality. One patient (6.7%) developed recurrence of rectal prolapse one month following surgery.

**Conclusions:** The advantages of this LSR procedure for the management of patients with FTRP are its simplicity, safety, efficacy, and practicality and the potential for its use in patients who can tolerate general anesthesia.

**MeSH Keywords:** **Colorectal Surgery • Laparoscopy • Rectal Prolapse**

**Full-text PDF:** <http://www.amjcaserep.com/abstract/index/idArt/905118>



 1989  3  4  22

## Background

Rectal prolapse is defined as a protrusion of the wall of the rectum outside the anus [1]. Full-thickness rectal prolapse (FTRP) refers to prolapse of all layers of the bowel wall; partial prolapse involves only the mucosa [1]. FTRP has a characteristic circular mucosal fold appearance, whereas partial prolapse has radial folds [1]. The etiology of rectal prolapse is not fully understood [1].

FTRP occurs in both pediatric and adult patients and has bimodal peaks of occurrence [1–3]. Almost all patients with rectal prolapse are women (>90%) aged >50 years with a history of vaginal childbirth [1,3]. Japan is becoming a more elderly society, and the incidence of FTRP in adult patients is increasing. Although FTRP is a benign anorectal disease, it causes several unpleasant symptoms, including mucus discharge, rectal bleeding, tenesmus, constipation, and incontinence.

FTRP is distinct from partial rectal prolapse, and therapeutic options for FTRP remain a topic of debate [1]. Surgery is the only definitive form of treatment [1]. Many surgical procedures have been described for the correction of FTRP and can be divided into two groups: transperineal or transabdominal [4–6]. The transperineal approach is regarded as being less invasive and is used for patients with FTRP who have comorbidities that put them at increased risk for general anesthesia [7].

Surgical management should be individualized to balance the risk of the surgery and the potential benefit to the quality of life of the patient [8]. However, transabdominal procedures are preferred by most surgeons [7,8]. Advanced laparoscopy and modern general anesthesia have made the abdominal approach more attractive, even for elderly patients [8]. Laparoscopic surgery is currently available for the transabdominal approach, although conventional open surgery has been performed historically [4–6,8]. Some studies have shown that laparoscopic surgery has several advantages over open surgery, including less pain, shorter hospital stay, and more rapid postoperative recovery [9,10].

In our institution, a very simple laparoscopic rectopexy has been developed that uses only one or two sutures without resection of the sigmoid colon, and we have used this technique for the treatment of FTRP for the past seven years. The aim of this report is to evaluate the safety and feasibility of this simplified laparoscopic suture rectopexy (LSR) in a case series of 15 patients who presented with FTRP and who had postoperative follow-up for six months.

## Case Reports

Fifteen patients who underwent laparoscopic suture rectopexy (LSR) for full-thickness rectal prolapse (FTRP) at our institution

**Table 1.** The clinical profiles of the 15 patients.

| n=15        |            |
|-------------|------------|
| Age         | 72.5±10.9  |
| Female      | 14 (93.3%) |
| BMI         | 20.3±2.5   |
| Comorbidity |            |
| No          | 3 (20.0%)  |
| Yes         | 12 (80.0%) |
| ASA score   |            |
| 1           | 3 (20.0%)  |
| 2           | 10 (66.7%) |
| 3           | 2 (13.3%)  |

**Table 2.** The intraoperative factors.

| n=15                       |             |
|----------------------------|-------------|
| Operation time [minute]    | 176.2±35.2  |
| Blood loss [mL]            | 0 (0–85 mL) |
| Conversion to open surgery | 0 (0%)      |

from September 2010 to October 2016 were retrospectively evaluated. All patients were proven to be able to tolerate general anesthesia. The patient profiles, surgical techniques, intraoperative factors, short-term and long-term course were analyzed. Data on their short-term clinical course were obtained from the clinical and operation records, and the current status of all patients was confirmed through telephone interviews to evaluate their long-term clinical course. The median postoperative follow-up period was 16.3 months (range, 7 months to 7 years).

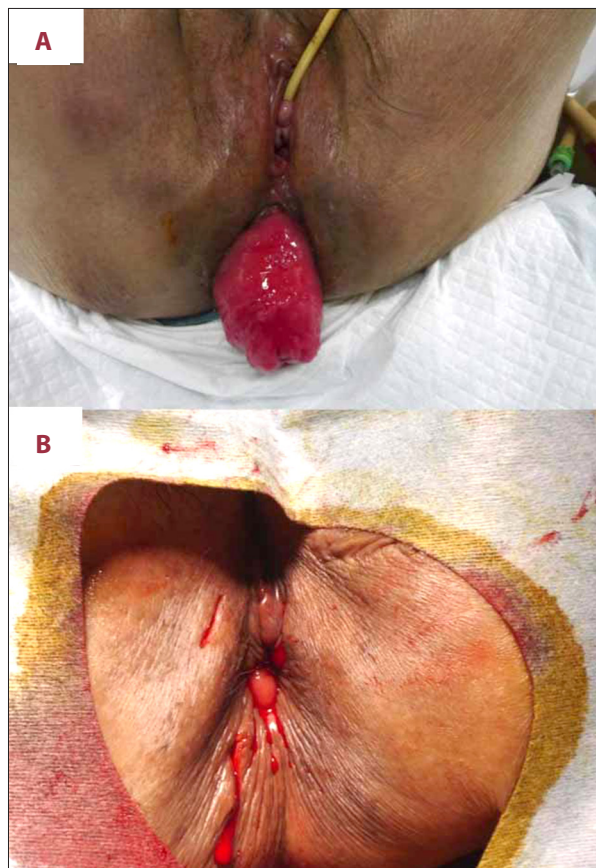
The clinical profiles of the 15 patients are summarized in Table 1. The mean age of the patients was 72.5±10.9 years, and 14 (93.3%) were women. Comorbidities were found in 12 patients (80.0%). The number of patients with an American Society of Anesthesiologists (ASA) score of ≥2 was 12 (80.0%).

The intraoperative factors are summarized in Table 2. The mean operative time was 176.2±35.2 minutes, and the volume of blood loss during surgery ranged from 0–85 ml. No conversion to open surgery occurred.

The short-term and long-term clinical course of the 15 patients studied following LSR are summarized in Table 3. A grade II postoperative complication according to the Clavien-Dindo classification [11] was observed in one patient with urinary retention. Severe-to-moderate complication (grade ≥III of the Clavien-Dindo classification) did not occur. No postoperative mortality occurred. One patient (6.7%) developed recurrence one month

**Table 3.** The short-term and long-term clinical course of the 15 patients studied following LSR.

|                              | n=15     |
|------------------------------|----------|
| Postoperative complication   |          |
| Urinary retention (grade II) | 1 (6.7%) |
| Postoperative stay [day]     | 6 (1–19) |
| Recurrence of FTRP           | 1 (6.7%) |

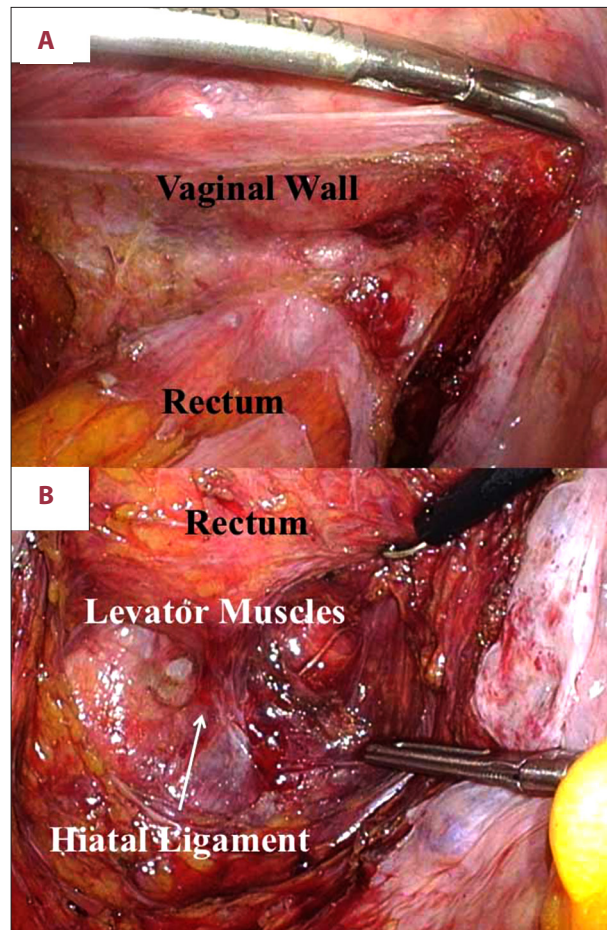


**Figure 1.** Laparoscopic suture rectopexy (LSR) for full-thickness rectal prolapse (FTRP). (A) Full-thickness rectal prolapse (FTRP) has a characteristic circular mucosal fold appearance. (B) The FTRP was resolved and a normalized anus was observed.

after surgery. In 10 patients, constipation had been reported as a symptom before surgery, and this symptom improved in four patients following surgery (26.7%), although constipation was reported to have worsened postoperatively in one patient (6.7%).

### Surgical procedure

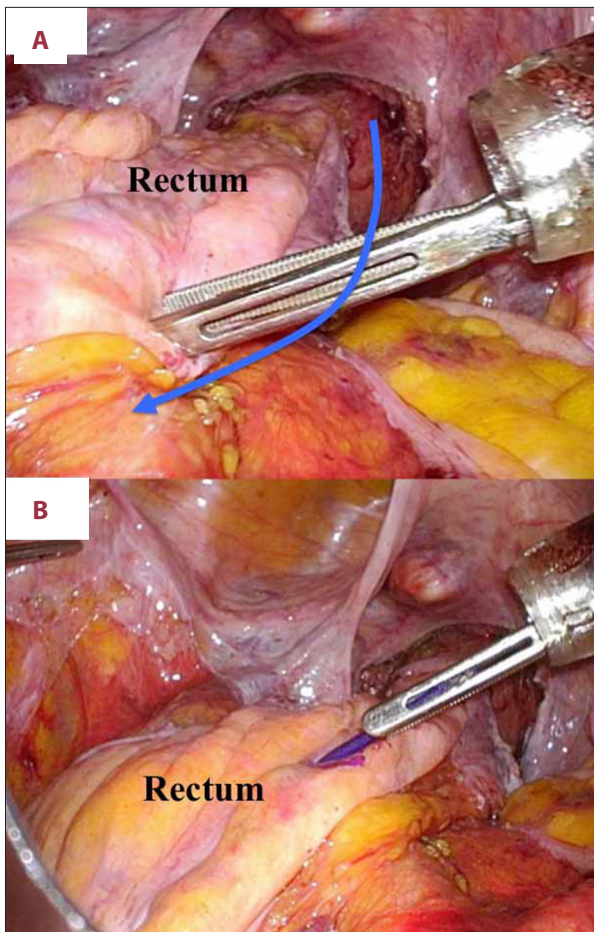
Under general and epidural anesthesia, the patient was placed in the lithotomy position. The anal tonus was routinely checked



**Figure 2.** Rectal dissection and mobilization were performed in the plane of total mesorectal excision. (A) Anterior rectal dissection was completed 10 to 20 mm caudal to the peritoneal reflection. (B) Posterior rectal dissection was accomplished until the levator muscles were exposed.

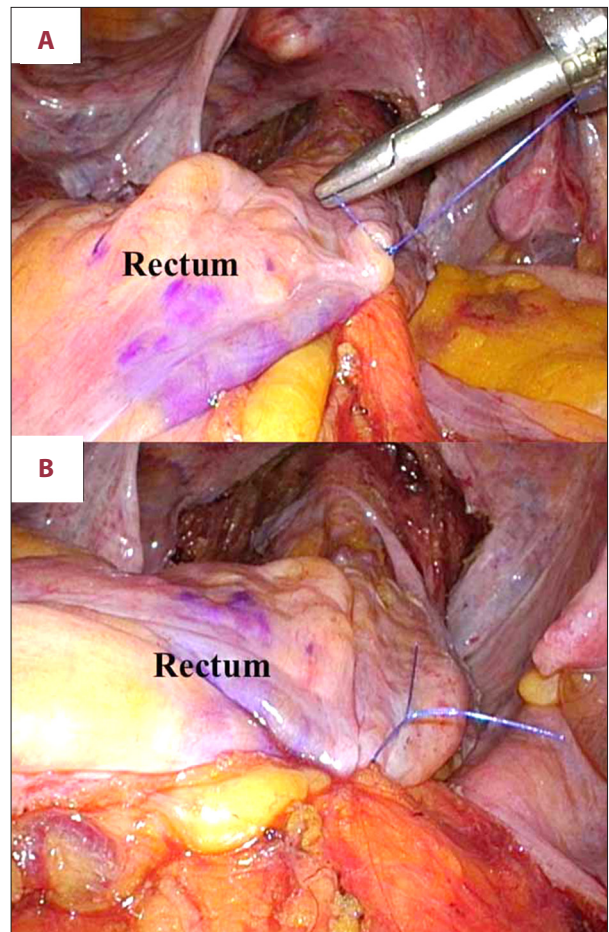
before beginning surgery (Figure 1A). The operator stood on the right side of the patient, the first assistant stood on the left side, and the laparoscopist stood behind the operator. After the establishment of carbon dioxide pneumoperitoneum of 8 to 10 cm H<sub>2</sub>O through the umbilical port, four working ports were placed in the lower abdomen. A flexible video laparoscope was then introduced via the umbilical port.

We carefully observed the abdominal cavity via laparoscopic vision. We initially employed a medial approach, and a lateral approach was subsequently used for rectal mobilization from the sacral promontory. Rectal dissection and mobilization were performed according to the plane of total mesorectal excision, and anterior rectal dissection was completed 10 to 20 mm caudal to the peritoneal reflection (Figure 2A). Posterior rectal dissection was performed until the levator muscles were exposed (Figure 2B), and bilateral rectal dissection



**Figure 3.** Laparoscopic suture rectopexy (LSR) for full-thickness rectal prolapse (FTRP). (A) The mobilized rectum was cranially lifted to the promontorium (blue arrow). (B) The optimal point for suture fixation of the rectum was clearly marked.

was accomplished with the skeletonized lateral ligament. We made a complete rectal mobilization with dissection of the lateral ligament, in order to prevent the postoperative recurrence. By lifting the mobilized/dissected rectum cranially to the promontorium (Figure 3A), the optimal point for suture fixation of the rectum was clearly marked (Figure 3B). The seromuscular layer of anterior right wall of the rectum was then sutured to the presacral fascia using one or two interrupted sutures (Figure 4A, 4B). Non-absorbable polypropylene suture (3-0 Prolene, SH-1, 90 cm; Ethicon, Somerville, NJ, USA) was used for this fixation. No intra-abdominal drain was placed. The FTRP was resolved and a normalized anus was observed (Figure 1B). In our institution, a total of 11 surgeons performed this laparoscopic surgery, under two supervisors. Therefore, all surgical procedures were performed in a standardized way.



**Figure 4.** Laparoscopic suture rectopexy (LSR) for full-thickness rectal prolapse (FTRP). (A) The seromuscular layer of anterior right wall of the rectum was sutured to the presacral fascia. Only one or two non-absorbable polypropylene sutures were placed in an interrupted fashion. (B) The advantage of this laparoscopic suture rectopexy (LSR) is its simplicity.

## Discussion

Although there have been several surgical procedures described for the repair of rectal prolapse, the optimal treatment of full-thickness rectal prolapse (FTRP) is still controversial [7]. Because FTRP is a benign disease, a less invasive and more effective treatment is required. Older patients with FTRP often have a greater risk of perioperative complications and may not be suitable for general anesthesia. From this viewpoint, the transperineal approach, which does not require general anesthesia, has a clinical advantage for patients with FTRP who are in poor general health.

Transperineal approaches include mucosal plication (the Gant-Miwa procedure, first described in 1962), anal encirclement (the Thiersch procedure, first described in 1891), mucosal sleeve

resection (the Delorme procedure, first described in 1900), and perineal rectosigmoidectomy (the Mikulicz procedure, first described in 1889 and the Altemeier procedure, first described in 1971) [1,12,13]. The transperineal approach was popularized by the Altemeier procedure [1,12] and has some advantages because it is a less invasive technique [1]. The less-invasive transperineal approach can be easily performed even in patients with poor general health who are at risk for general anesthesia. However, the recurrence rate associated with this approach is greater than for the transabdominal approach [7]. Hence, the transabdominal approach is considered to be the first choice for the surgical treatment of FTRP [7,8].

Transabdominal procedures usually involve rectopexy with or without resection of the redundant sigmoid colon. Mesh fixation for rectopexy in conventional open surgery was originally described as the Ripstein procedure in 1963, and this technique has since been modified by many surgeons. The use of the Ripstein procedure spread worldwide, despite the fact that it is associated with a significant morbidity rate [1]. Modifications of the mesh fixation, such as posterior wrapping and using a laparoscopic approach, have been documented [14]. However, postoperative complications related to the mesh, such as tissue erosion, infection, and mesh migration, became critical problems [14]. Abdominal rectopexy and sigmoid colectomy were originally described by Frykman in 1955 [15]. Thereafter, many surgeons focused on the usefulness of sigmoidectomy [1]. Resection of the sigmoid colon requires colonic anastomosis, which always carries a risk of anastomotic leak and subsequent fatal complications.

With the development of laparoscopic devices and surgical instruments, laparoscopic surgery has become a widespread approach throughout the world. The increased safety and feasibility of the laparoscopic transabdominal approach for the treatment of FTRP has been supported by several studies [8,16–18]. The laparoscopic transabdominal approach has been shown to be a safe and reliable procedure with minimal morbidity and a low recurrence rate [8,19].

During the approximately seven-year study period, 15 patients with FTRP underwent treatment at our surgical unit with the laparoscopic suture rectopexy (LSR) we have described in this case series. One of the most important components of this procedure is the attachment of the anterior right seromuscular wall of the rectum to the presacral fascia using only one or two sutures after adequate rectal mobilization from the sacral promontory. No moderate-to-severe complications or mortality occurred after our simplified LSR, and the recurrence rate was 6.7%. Previous reports have described the outcome of several laparoscopic transabdominal procedures for FTRP, specifically laparoscopic suture rectopexy, laparoscopic mesh rectopexy, and laparoscopic resection rectopexy; the overall recurrence

rates of FTRP after these three procedures reportedly range from 2.0% to 20.0%, 1.3% to 6.0%, and 0.0% to 11.0%, respectively [1,3,20]. We consider that the recurrence rate of our simplified LSR technique is comparatively acceptable.

The lateral ligaments are not always clearly identifiable, and a complete rectal dissection or just a separation of the lateral tissue should be chosen during surgery. The management of the lateral ligaments during surgery, that is, their division or preservation, has been previously investigated [1,4]. Complete division of the lateral ligaments of the rectum was associated with a reduced zero recurrence rate, but an increased rate of postoperative constipation (67%) [4]. In our institution, we made a complete rectal mobilization with dissection of the lateral ligament in each case, in order to prevent the postoperative recurrence. For our patients who underwent a complete rectal mobilization with dissection of the lateral ligament, constipation was drastically improved in 4 patients (26.7%), though postoperative constipation worsened in one case (6.7%).

The main advantage of this modified LSR technique is its simplicity. The procedure requires neither mesh fixation nor resection of the sigmoid colon, and it is safe with low morbidity and mortality rates. Moreover, this simple surgical procedure is a reliable treatment for FTRP with an acceptably low recurrence rate. However, this is a small case series in a single center that describes the use of the technique in only 15 patients operated on by 11 different surgeons over a long period. The mean operative time of approximately three hours was long. However, this operative time was acceptable for us, because operative times for laparoscopic mesh fixation (posterior wall fixation) were reported by colleagues in other hospitals to be longer, at more than four hours.

Previous studies have been reported in the field of FTRP treatment. However, the lack of high-quality evidence on the safety, effectiveness, and outcome of different techniques, small study sample size, and lack of descriptive or analytical detail have been documented [4,20–22]. Therefore, large-scale, controlled studies, with long-term follow-up are needed to improve the evidence base and to define the optimum surgical treatment for FTRP [4,20–22]. The present study had several limitations, including the fact that this was a retrospective case series conducted at a single center. Our conclusion may be unreliable because the median follow-up duration was short. However, we propose that our simple LSR method can serve as a therapeutic option for the surgical management of patients with FTRP. Future randomized controlled prospective studies are required to establish the optimal approach for the surgical management of patients with FTRP in a range of clinical contexts.

## Conclusions

This case series of 15 patients has shown that the main advantage of the modified laparoscopic suture rectopexy (LSR) procedure for the treatment of full-thickness rectal prolapse (FTRP) is its simplicity. No moderate-to-severe complications

or postoperative deaths occurred, and the postoperative recurrence rate during six-month follow-up was acceptable.

## Conflict of interest

None.

## References:

1. Garely A, Krieger B, Ky A: Rectal prolapse. In: Cameron J, Cameron A (eds.), *Current surgical therapy*. 11<sup>th</sup> ed. Philadelphia: Elsevier Saunders, 2014; 190–94
2. Siafakas C, Vottler TP, Andersen JM: Rectal prolapse in pediatrics. *Clin Pediatr*, 1999; 38: 63–72
3. Emile SH, Elfeki HA, Youssef M et al: Abdominal rectopexy for the treatment of internal rectal prolapse: A systematic review and meta-analysis. *Colorectal Dis*, 2017; 19: O13–24
4. Tou S, Brown SR, Malik AI, Nelson RL: Surgery for complete rectal prolapse in adults. *Cochrane Database Syst Rev*, 2008; (4): CD001758
5. Ramage L, Georgiou P, Tekkis P, Tan E: Is robotic ventral mesh rectopexy better than laparoscopy in the treatment of rectal prolapse and obstructed defecation? A meta-analysis. *Tech Coloproctol*, 2015; 19: 381–89
6. van Iersel JJ, Paulides TJ, Verheijen PM et al: Current status of laparoscopic and robotic ventral mesh rectopexy for external and internal rectal prolapse. *World J Gastroenterol*, 2016; 22: 4977–87
7. van Iersel JJ, Consten EC: Ventral mesh rectopexy for rectal prolapse: Level-I evidence. *Lancet Gastroenterol Hepatol*, 2016; 1: 264–65
8. Murphy PB, Wanis K, Schlachta CM, Alkhamesi NA: Systematic review on recent advances in the surgical management of rectal prolapse. *Minerva Chir*, 2017; 72: 71–80
9. Purkayastha S, Tekkis P, Athanasiou T et al: A comparison of open vs. laparoscopic abdominal rectopexy for full-thickness rectal prolapse: A meta-analysis. *Dis Colon Rectum*, 2005; 48: 1930–40
10. Magruder JT, Efron JE, Wick EC, Gearhart SL: Laparoscopic rectopexy for rectal prolapse to reduce surgical-site infections and length of stay. *World J Surg*, 2013; 37: 1110–14
11. Dindo D, Demartines N, Clavien PA: Classification of surgical complications: A new proposal with evaluation in a cohort of 6336 patients and results of a survey. *Ann Surg*, 2004; 240: 205–13
12. Altemeier WA, Culbertson WR, Schowengerdt C, Hunt J: Nineteen years' experience with the one-stage perineal repair of rectal prolapse. *Ann Surg*, 1971; 173: 993–1006
13. Yamana T, Iwadare J: Mucosal plication (Gant-Miwa procedure) with anal encircling for rectal prolapse – a review of the Japanese experience. *Dis Colon Rectum*, 2003; 46: S94–99
14. Joubert K, Laryea JA: Abdominal Approaches to rectal prolapse. *Clin Colon Rectal Surg*, 2017; 30: 57–62
15. Frykman HM: Abdominal proctopexy and primary sigmoid resection for rectal procidentia. *Am J Surg*, 1955; 90: 780–89
16. Bloemendaal AL, Mishra A, Nicholson GA et al: Laparoscopic rectopexy is feasible and safe in the emergency admission setting. *Colorectal Dis*, 2015; 17: O198–201
17. Lundby L, Iversen LH, Buntzen S et al: Bowel function after laparoscopic posterior sutured rectopexy versus ventral mesh rectopexy for rectal prolapse: A double-blind, randomised single-centre study. *Lancet Gastroenterol Hepatol*, 2016; 1: 291–97
18. Rose J, Schneider C, Scheidbach H et al: Laparoscopic treatment of rectal prolapse: Experience gained in a prospective multicenter study. *Langenbecks Arch Surg*, 2002; 387: 130–37
19. Wilson J, Engledow A, Crosbie J et al: Laparoscopic nonresectional suture rectopexy in the management of full-thickness rectal prolapse: Substantive retrospective series. *Surg Endosc*, 2011; 25: 1062–64
20. Rickert A, Kienle P: Laparoscopic surgery for rectal prolapse and pelvic floor disorders. *World J Gastrointest Endosc*, 2015; 7: 1045–54
21. Hotouras A, Ribas Y, Zakeri S et al: A systematic review of the literature on the surgical management of recurrent rectal prolapse. *Colorectal Dis*, 2015; 17: 657–64
22. Schiedeck TH: Complications after rectal prolapse surgery. *Chirurg*, 2015; 86: 747–51