



Case report

Phenotypic contrasts of Duchenne Muscular Dystrophy in women: Two case reports



Karen T. Nozoe^a, Ricardo T. Akamine^a, Diego R. Mazzotti^a, Daniel N. Polesel^a,
Luís F. Grossklauss^b, Sergio Tufik^a, Monica L. Andersen^a, Gustavo A. Moreira^{a,*}

^a Department of Psychobiology, Universidade Federal de São Paulo, São Paulo, SP, Brazil

^b Department of Neurology, Universidade Federal de São Paulo, São Paulo, SP, Brazil

ARTICLE INFO

Article history:

Received 14 September 2015

Received in revised form

30 March 2016

Accepted 20 July 2016

Available online 18 August 2016

Keywords:

Duchenne Muscular Dystrophy

Female symptomatic

Sleep disorders

Noninvasive ventilatory support

ABSTRACT

We discussed two cases of symptomatic female carriers to Duchenne Muscular Dystrophy. The first case is a 20 year-old girl with classical phenotypic manifestation of the disease, similar to the condition in boys. The case 2 is a 62 year-old woman with progressive muscular weakness. The disease is much less common in woman than men so both cases described here are considered rare forms of the disease, with several clinical implications. In both cases, a progressive muscle weakness, impairment in walking and sleeping was observed, in addition to obstructive sleep apnea syndrome and alveolar hypoventilation, that required noninvasive ventilatory support.

© 2016 Brazilian Association of Sleep. Production and Hosting by Elsevier B.V. This is an open access article under the CC BY-NC-ND license (<http://creativecommons.org/licenses/by-nc-nd/4.0/>).

1. Introduction

Duchenne Muscular Dystrophy (DMD) is an X-linked recessive neuromuscular disease. This fatal disease affects approximately 1:3,500 to 6,000 live male births [1] and 1:50,000,000 live female births [2,3]. It is a neuromuscular disorder characterized by a mutation in the dystrophin (*DMD*) gene caused by deletions (65% of cases) [4], specific mutations (26% of cases) [5], duplications (7% of cases) [6] and other unidentified causes (about 2% of cases) [5].

In general, women with an abnormal X chromosome are asymptomatic as long as it is compensated by the other normal allele. Cases of DMD in which the patient develops a similar phenotype as the male gender are rare in women [7]. Women may be symptomatic carriers of DMD when they are affected by homozygous mutations in the dystrophin gene, with partial or total expression of the abnormal gene. The signs and symptoms in women can vary from mild muscular weakness to severe clinical complications, when the patient is defined as a manifesting or symptomatic carrier. About 20% of heterozygous female carriers have the characteristic signs of the disease [8]. Often, carriers are symptomatic due to chromosomal translocations, Turner syndrome [9,10] or abnormal X chromosome [11]. Women have two X chromosomes and are normally not affected by X-linked disorders, due to the capacity of the unaffected chromosome to compensate

for the deficiency of the abnormal gene of the other chromosome. A number of females with X-autosome translocations with breakpoint in the Xp21 locus have also been shown to manifest signs and symptoms of DMD. One interpretation is that the gene locus is in that region, and that the locus on the normal X is inactivated, a mechanism called preferential inactivation of the X. On rare occasions, an X chromosome may be completely missing or present with a particular breaking point disrupting the dystrophin gene [12].

In women, the muscle weakness is usually mild, with asymmetric predominance and proximal distribution [13]. The onset of symptoms in affected women is variable. It can be observed from the first until the fourth decade of life. It is noteworthy that those who manifest before 15 years-old often have greater impairment and severity of clinical manifestations [13,14]. In this study we described two case reports of female carriers of DMD, representing manifestations in a young and an adult women.

2. Case report

2.1. Case 1

Female, single, 20 years-old, born preterm but otherwise a normal pregnancy without complications. Parents are not consanguineous and the first case of DMD in her family. Within 18 months showed hypertrophy of the calf. At five years-old, the child began to show difficulties in getting up from the sitting position

* Corresponding author.

E-mail address: gustavo.a.moreira@sono.org.br (G.A. Moreira).

Peer review under responsibility of Brazilian Association of Sleep.

Table 1
Polysomnography findings in symptomatic female carriers of Duchenne Muscular Dystrophy.

	Case 1 (PSG 1)	Case 2 (PSG 1)	Case 2 (PSG 2)
Total sleep time (min)	423.5	324.4	233.0
Sleep efficiency (%)	84.2	80.0	55.3
Sleep latency (min)	14.0	20.2	45.4
REM sleep latency (min)	81.5	351.5	–
Wake after sleep onset (min)	63.5	61.0	143.0
Arousal index (events/hour)	3.3	15.2	24.2
Stage 1 (%)	2.8	5.4	26.2
Stage 2 (%)	39.2	69.0	64.8
Stage 3 (%)	33.2	16.3	9.0
Sleep REM (%)	24.8	9.2	0
Obstructive apneas index (events/hour)	0	0.6	2.3
Central apnea index (events/hour)	0	0	0
Mixed apnea index (events/hour)	0	0	0
AHI (events/hour)	0.3	5.7	13.4
SpO ₂ < 90% (min.)	4.0	1.5	26.2
Desaturation events < 3% (n)	6.3	40	57

Legend: REM=rapid eye movement; AHI=apnea hypopnea index; SpO₂=oxygen saturation. Polysomnography was performed without use ventilation in all cases. In Case 1 patient with age at 10 years old and in Case 2 patient in PSG 1 with age at 61 years old and in PSG 2 with age at 62 years old.

(Gowers' sign) and constant falls. The disease had a rapid clinical course with progressive weakness in the lower limbs and foot deformities. At nine years-old, she lost the ability to walk and began to use a wheelchair and consequently became progressively obese. Menarche was at ten years-old. At 10 years old, she presented complaints of dyspnea on moderate efforts, diurnal headache, snoring, nocturnal sweating and witnesses apnea during sleep. She has a complete diagnostic polysomnography (PSG) that showed preserved sleep architecture and sleep efficiency (Table 1), although mild snoring, rare hypopneas events and 0.2% of total sleep time with SpO₂ below 90% was detected. Spirometry showed 64% of forced vital capacity-FVC (1.35 L) and FVC/forced expiratory volume (FEV1)=101. At 11 years old patient persists with headache and dyspnea. The patient had gain 10 kg of body weight. FVC=0.85 L (31%), FEV1=0.83 (33%), FVC/FEV1=98. At that moment, NIV therapy was started due to the low forced vital capacity and symptoms. She had good adherence to the noninvasive ventilation (NIV) device using it for about 6 h/night. At 11 years-old, she was with 61 kg and 1.58 m. Three years later, she presented a considerable weight gain, being 78.1 kg and 1.65 m, without corticoid use. At 17 years-old, she was diagnosed with dysphagia, and consequently suffered a significant weight loss (42.5 kg and 1.65 m). One year later this had progressed to anorexia (35 kg and 1.65 m) and underwent gastrostomy. Currently, the patient is confined to bed and receives mixed feeding (oral and gastrostomy). She has motor strength grade 1 in four members and fibrous tendon retractions and uses noninvasive mechanical ventilation with bi-level positive airway pressure parameters in spontaneous/timed mode with a respiratory rate of 12 per min, inspiratory pressure of 16 cm H₂O, expiratory pressure of 4 cm H₂O, generating tidal volumes of 200–400 mL.

The karyotype was performed by G-banding with analysis of metaphases from temporary lymphocyte cultures of peripheral blood. Result revealed karyotype 46,X,t(X;4)(p21;q13) [20], with a reciprocal translocation involving the short arm of the X chromosome and the long arm of one chromosome 4, with breakpoints in Xp21 and 4q13. In addition, microarray analysis of chromosomal aberrations and copy number variants was performed. In this case, the test did not show copy number variations within *DMD* gene;

however, a 471 kb duplication in the pseudoautosomal region PAR1 (arr[hg19] Xp22.33(524,439–995,018)×3) was found, overlapping the *SHOX* gene (OMIM #312865).

2.2. Case 2

Women, married, 62 years-old, who reported onset of weakness of the muscles of the lower limbs at 56 years of age, with progressive evolution year-by-year. Had 2 pregnancies, 1 son with DMD, who died with aged 19 years-old, and a healthy 35 year old daughter. Also complained of snoring, apneas, daytime sleepiness, mood changes, morning headache, sudden awakening and fragmented sleep. At that time, she was taking sertraline (50 mg), amitriptyline (25 mg), diazepam (10 mg) and metformin (500 mg). At 61 years old, spirometry showed 83% of FVC (2.41 L) and FVC/FEV1=107. The PSG report showed a mild increase of the respiratory disturbance index due to obstructive events, increased N2 stage (64.8%), reduced sleep efficiency (80%) and REM sleep (9.2%), mild snoring and oxygen desaturation. The oxygen desaturation index was more pronounced in REM sleep. End-tidal carbon dioxide remained 166.9 min (51.4%) of total sleep time above 50 mmHg. For this reason, mechanical ventilation was indicated with bi-level positive pressure. She had good adherence to the treatment and reported important improvement in the previous symptoms. At 62 years old, the patient was submitted to a new PSG to monitoring since the first polysomnography was performed at baseline (without NIV). A new baseline polysomnography was performed to verify whether the patient's subtle symptoms reflect abnormal nocturnal gas exchange, showing a slight increase in apnea-hypopnea index (13.4) due obstructive events, and increased respiratory disturbance index (22.1 events/hour) mainly caused by respiratory effort related to arousal; mild to severe snoring; sleep efficiency reduced to 55.3% as a result of increased sleep latency and frequent awakenings; reduction in slow wave sleep and absence of REM sleep; increase in arousal index (24.2 events/hour). She presented 26.2 min of oxygen saturation below 90% (8.1% of total sleep time). Currently, she has a myopathic gait and walks with the aid of a walking stick. Her muscular weakness is proximal grade 4 and distal grade 5 in her right arm, as well as proximal grade 3 and distal grade 5 in her left lower limb. She reported the onset of severe pain in the lumbar region, related to body posture. After a few months, she complained of frequent falls while walking. The patient evolved with the onset of progressive weakness in the lower limbs initially and subsequently in the upper limbs. She reported "a trembling sensation in the body" and chronic widespread pain. She presented other co-morbidities such as diabetes mellitus, chronic constipation and depressive disorder.

The additional examination of karyotype by G-banding of peripheral blood revealed a normal karyotype 46, XX with a resolution level of 440–550 chromosomal bands. However, through the microarray analysis of chromosomal aberrations and copy number variants, a duplication of exons 43–52 of the dystrophin gene was identified, being classifiable as a manifesting carrier. The microarray test revealed two pathogenic gains in these patient, within the *DMD* gene (arr[hg19] Xp21.1(31,746,944–31,923,772)×3 and arr[hg19] Xp21.1(32,110,375–32,328,188)×3, with 177 kb and 218 kb respectively. These variants overlap exons 42–44 and 48–52 of *DMD* gene (OMIM #300377), respectively.

3. Discussion

The patients described in this report represent uncommon clinical manifestations in women with DMD. Case 1 is of a 20 year old with clinical features of DMD (early symptoms since 18

months of age). She has muscular weakness, loss of gait and is underweight. Low weight is due to severe muscle atrophy and the consequences of dysphagia and anorexia, which possibly intensified the loss of muscle mass. Body Mass Index (BMI) of this patient was calculated from the wingspan, due to difficulty in properly positioning the anthropometer. In the adult Brazilian female population, height can be estimated by dividing the wingspan by 1.03 [18]. A severe manifestation of DMD is uncommon in women, with mild to moderate muscular weakness only being expected and increased creatine kinase (CK) and creatine kinase isoform MB levels (CKMB) [19]. In case 1 in particular, the concentration of CK and CKMB was reduced due to severe muscle atrophy (175 U/L and 16 U/L, respectively). The microarray did not show copy number variations within the DMD gene; however, a 471 kb duplication in the pseudoautosomal region PAR1 (arr [hg19] Xp22.33(524,439–995,018)×3) was found, overlapping the *SHOX* gene (OMIM #312865). Mutations and deletions in this gene or its 3' regulatory region were found in ~15% of patients with idiopathic short stature, and ~60% of patients with Leri-Weill dyschondrosteosis [20]. Since this region has been described as important to some genetic syndrome phenotypes, although not directly involved in DMD, we cannot discard its participation in the patient phenotype; therefore this variant was classified as a variant of uncertain significance. We also found a 289 kb duplication in the long arm of chromosome 10 (arr[hg19] 10q11.23(51,874,162–52,163,027)×3), encompassing 4 genes (*FAM21A*, *FAM21B*, *ASAH2*, *SGMS1*). Since this variant overlaps three DGV entries, did not overlap any DECIPHER entry and the genes contained did not show evidence for participation in DMD, this variant was described as benign in relation to the DMD phenotype. In case1, we also found a 322 kb deletion in chromosome 14 (arr [hg19] 14q21.2(46,638,889–46,961,056)×1), encompassing no genes with only one DGV entry. Since no genes were found, to the best of our knowledge, this variant is likely to be benign in regards to the DMD phenotype. The microarray analysis does not show changes in copy number, unless there is major loss or gain of genetic material. In this case, the balanced translocation involving Xp21 raises the hypothesis of a breakpoint within the *DMD* gene in this segment and inactivation of the normal X chromosome. The *DMD* gene is cleaved into two parts and joins another portion of autosomal chromosome. This possibly blocks the production of a functional protein, resulting in the classical DMD phenotype.

In the second case report, there was a significant increase in CK and CKMB enzymes due to the muscle degeneration (779 U/L and

26 U/L, respectively). Female carriers usually have a reduction in dystrophin and consequently mild muscle loss. The main characteristics found in muscle biopsy in women with DMD is the presence of regenerating fibers with large nucleoli, necrotic fibers, increased connective tissue and fiber type 1 muscle fibers and fibrofatty replacement [22]. Moreover, there is a mosaic pattern found in immunohistochemical findings with the fiber with normal dystrophin sarcolemma interspersed by fibers with dystrophin deficiency (dystrophin positive and negative) [23]. For ethical reasons, it was only possible to perform a biopsy on patient 2, since the patient in case 1 had a severe clinical condition and intense muscular atrophy. Muscle biopsy of the deltoid muscle in case 2 was performed. ATPase staining in pH 9.4 identified the presence of a slight predominance of type 1 fibers (Fig. 1A). The immunoperoxidase test showed partial expression of the protein dystrophin (Fig. 1B). Cavalcanti and colleagues [24] observed atrophy, variability in fiber size and endomysial fibrosis with infiltration of fat in their histological analysis of patients with DMD, with a predominance of type 1 muscle. In DMD, there is a frequently occurrence of progressive loss of muscle fiber simultaneous to muscle weakness and loss, as well as reduced sarcolemmal expression, of dystrophin in carriers [25].

The microarray study of chromosomal aberrations revealed two pathogenic gains in patient 2, within the *DMD* gene (arr[hg19] Xp21.1(31,746,944–31,923,772)×3 and arr[hg19] Xp21.1(32,110,375–32,328,188)×3), with 177 kb and 218 kb respectively. These variants overlap exons 42–44 and 48–52 of *DMD* gene (OMIM #300377) respectively. Duplications found in *DMD* have been described in 5–10% patients with Duchenne and Becker muscular dystrophies [26–29]. Gains in the *DMD* gene were found primarily between exons 1–7, but duplications were also found between exons 45–55 in patients with DMD [30]. Zeng and colleagues [31] described 13 duplications in a total of 249 DMD patients, 7 duplications were found between exons 44–52. These results reinforce the association between duplications in this region and phenotype expression in DMD.

During the progression of the disease, muscular weakness worsening leading to respiratory impairment is a great landmark in the life of patient. Consequently, the patient is forced to use noninvasive ventilation when this weakness affects the respiratory muscles. This impairment culminates with a decline in inspiratory and expiratory pressures and a subsequent reduction in vital and total lung capacity. In female carriers, muscle weakness is predominantly asymmetric, being observed 41% in the upper limbs,

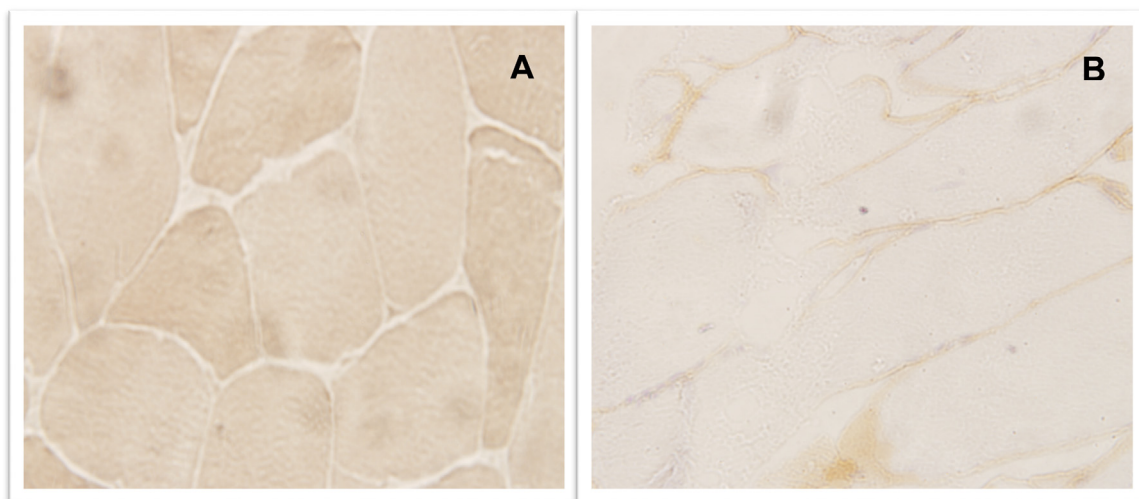


Fig. 1. Muscle biopsy of the deltoid muscle of case 2. Legend: 1 A: ATPase 9,4 demonstrated slight predominance of type 1 fibers; 1B: Immunoperoxidase showed partial dystrophin protein expression.

23% in lower limbs and 36% in both [32]. In case 1, we observed flaccid tetraparesis with grade 1 of gross motor strength, and in case 2, proximal tetraparesis with grade 4 driving force. In both patients there was muscle hypotonia and weakness of the respiratory muscles, resulting in increased respiratory events during sleep. The referral for PSG of the two patients was due to complaints during sleep. The sleep studies observed obstructive events, reduced sleep efficiency and alveolar hypoventilation in case 2, common findings in patients with neuromuscular diseases. During the PSG of case 2, the patient showed hypercapnia, having 51.4% of total sleep time with end-tidal CO₂ above 50 mmHg. Additionally, she presented an increased respiratory disturbance index (5.7 events/hour). This can be explained by progressive muscle weakness, especially the respiratory muscles. When these muscles are affected, it leads to alterations in gas exchange and consequently hypercapnia and hypoxemia. For this reason, patient of case 2 was advised to use non-invasive ventilatory support at night. The patient had good adherence to respiratory support with reduced daytime symptoms. Recently, this patient repeated the PSG exam and an improvement in the hypercapnia was observed. Nevertheless, there was an increase in respiratory disturbance index (22.1 events/hour), probably caused by multifactorial reasons related to weight gain in recent years, menopause and also by the physical disabilities. Bi-level parameters were adjusted to correct for these abnormalities.

Impairment in the sleep in boys with DMD is common, particularly in regard to the development of respiratory sleep disorders. The PSG findings in both these cases are expected consequences of disease progression. In boys with DMD, the sleep pattern and percentage of the different sleep stages are generally not significantly compromised [33]. Generally, incidences of hypoventilation [34,35], hypopnea, hypercapnia, central apnea [33] and obstructive apnea [35] are observed. For these patients, events like apnea become even more severe during REM sleep, because at this stage there is a decrease in intercostal muscle tonus [36] and decreased activity of the muscles of the upper airways [35], intensifying the consequences of hypoxia. Sleep-disordered breathing causes negative repercussions on the patients' quality of life, such as nocturnal awakenings, daytime sleepiness and headache [35], fatigue, dyspnea, and impaired cough mechanism [37]. Indeed, frequent awakenings, fatigue and excessive daytime sleepiness were some of the main complaints cited in both cases. Therefore, this study suggests that symptomatic female carriers should also be evaluated for muscle weakness and sleep impairment. To provide effective treatment and appropriate health care to the patient, the use of ventilatory support to improve the quality of life, sleep and increased survival is essential.

Funding sources

AFIP, CAPES, CNPq and FAPESP (grant #2014/08067-0 to KTN).

Conflict of interest

None to declare.

Acknowledgements

We appreciate the comments and suggestions made by Helio Rodrigues on the interpretation of microarray findings and Fernanda Bellucco on the karyotype analysis. The authors wish to acknowledge the Associação Fundo de Incentivo à Pesquisa (AFIP) and CAPES,

CNPq (MLA and ST are recipients of the CNPq fellowship) and São Paulo Research Foundation (FAPESP) (grant #2014/08067-0 to KTN).

References

- [1] L.F. Grossklauss. *Distrofia Muscular de Duchenne*. In: Oliveira AS. *Reabilitação em doenças neuromusculares: guia terapêutico prático*. 2014, São Paulo: Atheneu.
- [2] Webb CL. Parents' perspectives on coping with Duchenne muscular dystrophy. *Child: Care, Health and Development* 2005;31:385–96.
- [3] Pena FR, Rosolém FC, Alpino AMS. The contribution of physiotherapy for the well-being and participation of two students with Duchenne Muscular Dystrophy in regular school. *Rev Bras Educ Espec* 2008;14:447–62.
- [4] Den Dunnen JT, Grootsholten PM, Bakker E, Blondin LA, Ginjaar HB, Wapenaar MC, van Paassen HM, van Broeckhoven C, Pearson PL, van Ommen GJ. Topography of the Duchenne muscular dystrophy (DMD) gene: FIGE and cDNA analysis of 194 cases reveals 115 deletions and 13 duplications. *Am J Hum Genet* 1989;45:835–47.
- [5] Deburgrave N, Daoud F, Llése S, Barbot JC, Récan D, Peccate C, Bérout C, Garcia L, Kaplan JC, Chelly J, Leturcq F. Protein- and mRNA-based phenotype-genotype correlations in DMD/BMD with point mutations and molecular basis for BMD with nonsense and frameshift mutations in the DMD gene. *Hum Mutat* 2007;28:183–95.
- [6] White SJ, Aartsma-Rus A, Flanigan KM, Weiss RB, Kneppers AL, Lalic T, Janson AA, Ginjaar HB, Breuning MH, den Dunnen JT. Duplications in the DMD gene. *Hum Mutat* 2006;27:938–45.
- [7] Fujii K, Minami N, Hayashi Y, Nishino I, Nonaka I, Tanabe Y, Takanashi J, Kohno Y. Homozygous female Becker muscular dystrophy. *Am J Med Genet A*. 2009;149A:1052e5.
- [8] Ou Z, Li S, Li Q, Chen X, Liu W, Sun X. Duchenne muscular dystrophy in a female patient with a karyotype of 46,X,i(X)(q10). *Tohoku J Exp Med* 2010;222:149–53.
- [9] Somer H, Voutilainen A, Knuutila S, Kaitila I, Rapola J, Leinonen H. Duchenne-like muscular dystrophy in two sisters with normal karyotypes: evidence for autosomal recessive inheritance. *Clin Genet* 1985;28:151–6.
- [10] Yoshioka M, Itagaki Y, Saida K, Nishitani Y. Clinical and genetic studies of muscular dystrophy in young girls. *Clin Genet* 1986;29:137–42.
- [11] Berg BO, Conte F. Duchenne Muscular Dystrophy in a female with a structurally abnormal X-chromosome. *Neurology* 1974;24:356.
- [12] Lindenbaum RH, Clarke G, Patel C, Moncrieff M, Hughes JT. Muscular dystrophy in an X; 1 translocation female suggests that Duchenne locus is on X chromosome short arm. *J Med Genet* 1979;16:389–92.
- [13] Yoshioka M. Clinically manifesting carriers in Duchenne muscular dystrophy. *Clin Genet* 1981;20:6–12.
- [14] Sewry CA, Sansome A, Clerk A, Sherratt TG, Hasson N, Rodillo E, Heckmatt JZ, Strong PN, Dubowitz V. Manifesting carriers of Xp21 muscular dystrophy; lack of correlation between dystrophin expression and clinical weakness. *Neuromuscul Disord* 1993;3:141–8.
- [15] Rufino R, Costa CH, Antão VCS, Pinheiro GA, Jansen JM. *Relação envergadura/altura: um valor para estudos espirométricos em brasileiros*. *Pulmão/RJ* 1996;7:40–4.
- [16] Griggs RC, Mendell JR, Brooke MH, Fenichel GM, Miller JP, Province M, et al. Clinical investigation in Duchenne dystrophy: V. Use of creatine kinase and pyruvate kinase in carrier detection. *Muscle Nerve* 1985;8:60–7.
- [17] Benito-Sanz S, Thomas NS, Huber C, Gorbenko del Blanco D, Aza-Carmona M, Crolla JA, Maloney V, Rappold G, Argente J, Campos-Barros A, Cormier-Daire V, Heath KE. A novel class of pseudoautosomal region 1 deletions downstream of SHOX is associated with Leri-Weill dyschondrosteosis. *Am J Hum Genet* 2005;77:533–44.
- [18] Engel AG, Yamamoto M, Fishbeck KH. *Dystrophinopathies: Definitions and basic: Definitions and basic concepts*. In: *Myology: Basic and Clinical*. McGraw-Hill; 2nd 1994: 1133–1187.
- [19] Arahata K, Ishihara T, Kamakura K, Tsukahara T, Ishiura S, Baba C, Matsumoto T, Nonaka I, Sugita H. Mosaic expression of dystrophin in symptomatic carriers of Duchenne's muscular dystrophy. *N Engl J Med* 1989;320:138–42.
- [20] Cavalcanti GM, Oliveira ASB, Assis TO, Chimelli LMC, Medeiros PL, Mota DL. Histochemistry and morphometric analysis of muscle fibers from patients with Duchenne Muscular Dystrophy (DMD). *Int J Morphol* 2011;29:934–8.
- [21] Yamamoto H, Hagiwara Y, Mizuno Y, Yoshida M, Ozawa E. Heterogeneity of dystrophin-associated proteins. *J Biochem* 1993;114:132–9.
- [22] White S, Kalf M, Liu Q, Villerius M, Engelsma D, Kriek M, Vollebregt E, Bakker B, van Ommen GJ, Breuning MH, den Dunnen JT. Comprehensive detection of genomic duplications and deletions in the DMD gene, by use of multiplex amplifiable probe hybridization. *Am J Hum Genet* 2002;71:365–74.
- [23] White SJ, Aartsma-Rus A, Flanigan KM, Weiss RB, Kneppers AL, Lalic T, Janson AA, Ginjaar HB, Breuning MH, den Dunnen JT. Duplications in the DMD gene. *Hum Mutat* 2006;27:938–45.
- [24] Flanigan KM, Dunn DM, von Niederhausen A, Soltanzadeh P, Gappmaier E, Howard MT, Sampson JB, Mendell JR, Wall C, King WM, Pestronk A, Florence JM, Connolly AM, Mathews KD, Stephan CM, Laubenthal KS, Wong BL, Morhart PJ, Meyer A, Finkel RS, Bonnemann CG, Medne L, Day JW, Dalton JC, Margolis MK, Hinton VJ. Mutational spectrum of DMD mutations in dystrophinopathy patients: application of modern diagnostic techniques to a large

- cohort. *Hum Mutat* 2009;30:1657–66.
- [29] Takeshima Y, Yagi M, Okizuka Y, Awano H, Zhang Z, Yamauchi Y, Nishio H, Matsuo M. Mutation spectrum of the dystrophin gene in 442 Duchenne/Becker muscular dystrophy cases from one Japanese referral center. *J Hum Genet* 2010;55:379–88.
- [30] White SJ, den Dunnen JT. Copy number variation in the genome; the human DMD gene as an example. *Cytogenet Genome Res* 2006;115:240–6.
- [31] Zeng F, Ren ZR, Huang SZ, Kalf M, Mommersteeg M, Smit M, White S, Jin CL, Xu M, Zhou DW, Yan JB, Chen MJ, van Beuningen R, Huang SZ, den Dunnen J, Zeng YT, Wu Y. Array-MLPA: comprehensive detection of deletions and duplications and its application to DMD patients. *Hum Mutat* 2008;29:190–7.
- [32] Hoogerwaard EM, Bakker E, Ippel PF, Oosterwijk JC, Majoor-Krakauer DF, Le-schot NJ, van Essen AJ, Brunner HG, van der Wouw PA, Wilde AA, de Visser M. Signs and symptoms of Duchenne muscular dystrophy and Becker muscular dystrophy among carriers in The Netherlands: a cohort study. *Lancet* 1999;353:2116–9.
- [33] Barbé F, Quera-Salva MA, McCann C, Gajdos P, Raphael JC, de Lattre J, Agustí AG. Sleep-related respiratory disturbances in patients with Duchenne muscular dystrophy. *Eur Respir J* 1994;7:1403–8.
- [34] Suresh S, Wales P, Dakin C, Harris M-A, Cooper DGM. Sleep-related breathing disorder in Duchenne muscular dystrophy: disease spectrum in the paediatric population. *J Paediatr Child Health* 2005;41:500–3.
- [35] Finder JD, Birnkrant D, Carl J, Farber HJ, Gozal D, Iannaccone ST, Kovesi T, Kravitz RM, Panitch H, Schramm C, Schroth M, Sharma G, Sievers L, Silvestri JM, Sterni L, American Thoracic Society. Respiratory care of the patient with Duchenne muscular dystrophy: ATS consensus statement. *Am J Respir Crit Care Med* 2004;170:456–65.
- [36] McNicholas WT. Impact of sleep in respiratory failure. *Eur Respir J* 1997;10:920–33.
- [37] Manzur AY, Muntoni F. Diagnosis and new treatments in muscular dystrophies. *Postgrad Med J* 2009;85:622–30.