

OVARIAN PREGNANCY ASSOCIATED WITH PELVIC ADHESIONS

RĂZVAN CIORTEA¹, NICOLAE COSTIN¹, BOGDAN CHIROIU²,
ANDREI MĂLUTAN¹, RADU MOCAN¹, AURORA HUDACSKO¹,
ADRIANA GAIA¹, CARMEN BUCURI¹, DAN MIHU¹

¹Department of Obstetrics-Gynecology, Iuliu Hațieganu University of Medicine and Pharmacy, Cluj-Napoca, Romania

²Service of Radiology, Rehabilitation Hospital, Cluj-Napoca, Romania

Abstract

Ovarian pregnancy is a rare entity. Making a definitive preoperative or even intraoperative diagnosis of ovarian pregnancy is difficult and the diagnosis is usually established by the pathologist. Rupture in the first trimester is the usual rule in ovarian ectopy. Thus, it continues to challenge practicing clinicians. The literature shows an association between intrauterine device usage and ovarian gestation. We present a case of ovarian pregnancy in a secundipara complaining of abdominal pain that also has pelvic adhesions. This case meets the four criteria of Spiegelberg and is interesting because of its rarity and association with adhesions, which makes diagnosis more difficult.

Keywords: ovarian pregnancy, pelvic adhesions, diagnosis.

Introduction

Ovarian pregnancy is a rare entity of ectopic locations. The real incidence is unknown due to asymptomatic cases in which the evolution of the product of conception stops and diagnosis is sometimes difficult to make both preoperatively and intraoperatively. The increase in the incidence of ovarian pregnancy is closely related to the use of intrauterine devices as a contraceptive method. These prevent uterine implantation, but do not provide protection against ovarian implantation.

Primary ovarian pregnancy should meet the 4 diagnostic criteria of Spiegelberg: the fallopian tube should be intact; the gestational sac should be in normal ovarian position and connected to the uterus through the utero-ovarian ligament; ovarian tissue should be present in the sac wall [1]. A correct diagnosis of ovarian pregnancy during surgery is only possible in 28% of the cases, because it is difficult to differentiate from a hemorrhagic corpus luteum intraoperatively [2].

Case report

A 31-year-old secundipara presented in June 2009 with low intensity abdominal pain in the left flank, without

amenorrhea, with a negative pregnancy test. Pain started in April 2009 and was no longer improved by analgic drugs, being accompanied by menorrhagia, characterized by an abundant flow and which lasted longer than her normal menstruations (7-8 days in comparison with 3-4 days, the patient's normal anterior menstruations) and also metrorrhagia, which appeared seven days away in moderate quantity and accompanied by abdominal discomfort. The relevant personal physiological history in this case included 2 pregnancies (in 1999 and 2004), both ended by cesarean section. The patient had no personal history of diseases, was not a smoker, consumed no other toxic drugs and used no intrauterine device as a contraception method.

On local examination, the uterus was found to be in an intermediate position, mobile, with regular outline, normal volume and consistency. A well delimited left lateral anterior uterine tumor formation 7 cm in size was palpated. The right adnexa and Douglas cul-de-sac were free.

Following laboratory examinations, a CA125 level of 44.56 was found. Abdominal ultrasound evidenced a hypoechogenic tumor formation 7.4/4.4 cm in size at pelvic level, on the anterior wall of the uterus, slightly laterally to the left. The tumor had a mixed structure with hypoechogenic areas, with a well delimited outline, with vascular signal on Doppler examination, apparently without peripheral infiltration (figures 1, 2).

Manuscript received: 09.10.2012

Received in revised form: 19.01.2013

Accepted: 24.01.2013

Address for correspondence: r_ciortea@yahoo.com

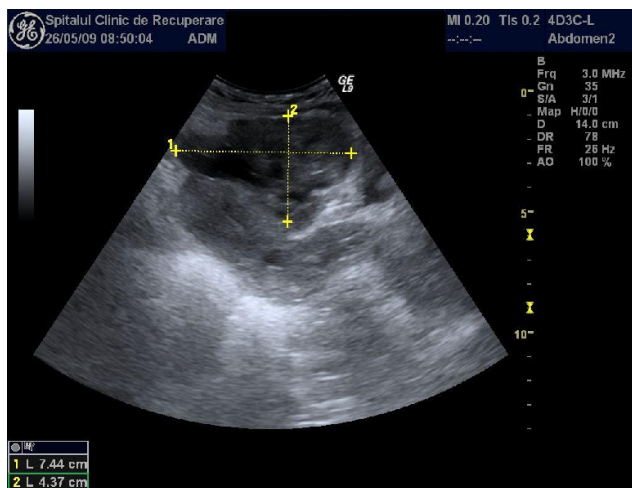


Figure 1.

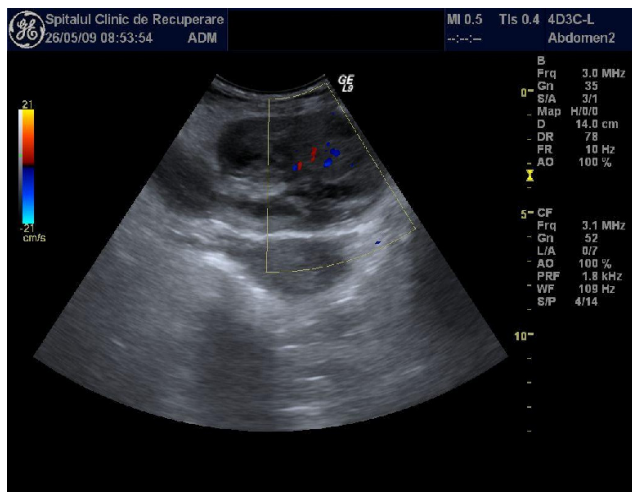


Figure 2.

Endovaginal ultrasound evidenced the previously described tumor, which had a cleavage plane in relation to the uterus. The left ovary, 3/2/2 cm in size, presented cystic images with sizes of up to 9-10 mm. A minimal collection in Douglas cul-de-sac was detected.

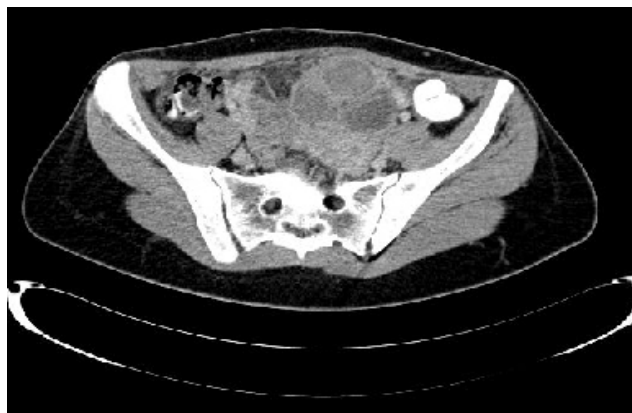

Figure 3A.

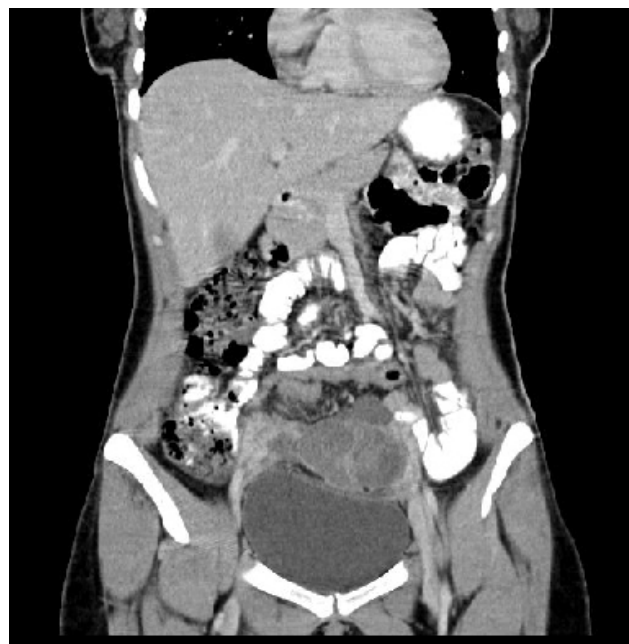

Figure 3B.

CT examination with intravenous contrast substance evidenced a left utero-ovarian block of approximately 75/72 mm, with an inhomogeneous structure and a cystic component, with iodine uptake in the periphery. The left cystic ovary was adherent to that formation, without the presence of pelvic fluid collections or ganglionic masses of significant sizes (figures 3A, 3B).

Based on anamnesis, objective examination and laboratory examination, the diagnosis of abdominal pelvic tumor was made.

In the absence of a certainty diagnosis, surgery was decided, with a view to deciding the therapeutic approach after intraoperative diagnosis. The decision of the classical approach and not the laparoscopic one was made taking into account the fact that the patient had 2 pregnancies, both ended by cesarean section and considering a potential adhesion syndrome after those two operations by Pfannenstiel incision. Following preoperative preparation under classical aseptic and antiseptic conditions, a Pfannenstiel incision was performed over the old scar, with its excision. After the opening of the peritoneal cavity, multiple omental-parietal and omental-intestinal adhesions were found. At the level of the left ovary, a cystic tumor formation approximately 8 cm in diameter, with multiple adhesions with the uterus and the ipsilateral fallopian tube was found. The macroscopic appearance of the uterine tubes was quasi normal, except for the extensive pelvic adhesions. The utero-ovarian ligament was in close contact with the ovarian formation and important pelvic adhesions were also identified at this level. Adhesion lysis, left adnexectomy and partial omental resection were decided and performed.

The morphopathological examination evidenced a left ovary with cystic areas, with smooth walls. On sectioning, a brownish-violaceous content and unilocular cysts with smooth inner walls were seen. On the wall of one of the cysts, there was a sessile polypoid formation of low consistency, with a brownish appearance. Microscopic examination showed an ovary with serous follicular cysts and a hematically changed old pregnancy. Chorionic villi were ischemically degenerated and enclosed in fibrinohematic material. The salpinx was free (figures 4, 5).

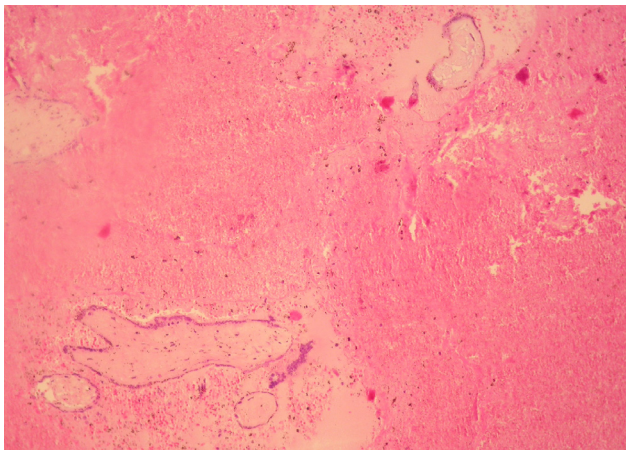


Figure 4.

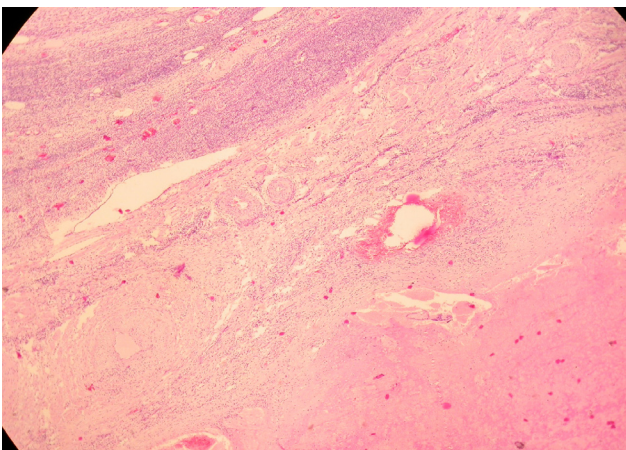


Figure 5.

Discussion

Nidation in the ovary is extremely rare, having a 0.3-3% incidence of all ectopic pregnancies.

The mechanism of production of primary ovarian pregnancy is still unknown. Some hypotheses suggest an interference between the release of the ovule from the ruptured follicle, the impairment of the uterine tube function and the inflammatory thickening of the albuginea.

In the etiopathogenesis of ectopic pregnancies various factors play a role, such as a history of pelvic

inflammatory disease, previous tubal pregnancy, the current use of contraceptive uterine devices, a history of uterine tube surgery. However, only the use of an intrauterine device as a contraceptive method is associated with an increase in the incidence of ovarian location. A study performed by Lehfeldt et al. [3] shows that intrauterine devices reduce uterine implantation by 99.5%, tubal implantation by 95%, and they have no effect on ovarian location.

Clinical symptoms and signs such as abdominal pain, menorrhagia, metrorrhagia, palpable adnexal mass are similar to those present in tubal pregnancy, hemorrhagic corpus luteum or ruptured ovarian cyst.

Diagnosis is based on the classical ultrasonographic description of a cyst with a large exterior echogenic ring, situated inside or on the surface of the ovary [4]. Because diagnosis is difficult to make following imaging examination, in cases with a suspicion of ectopic pregnancy the repeated measurement of β -hCG will sometimes allow for a definitive diagnosis (40% sensitivity, 90% specificity) [5,6]. β -hCG values in the case of normal pregnancies increase two-fold at almost 48 hours, unlike non-viable or ectopic pregnancies, in which this two-fold increase occurs more slowly [7,8]. An ectopic pregnancy should be considered in the case of the absence of the ovular sac from the uterine cavity at β -hCG concentrations higher than 2,000 IU/L [9,10].

In our case the CA125 value was measured, as a neoplastic process was suspected. The CA125 level increases in the first trimester of pregnancy and returns to the initial value during the second and third trimesters. CA125 values were studied for the early diagnosis of spontaneous abortion. Although a positive correlation between high CA125 levels 18-22 days after conception and spontaneous abortion was demonstrated, the measurement at 6 weeks of gestation was not correlated with the initial result [11]. Other contradictory results were also reported: a study evidenced a higher increase in the CA125 level in normal pregnancies compared to ectopic pregnancies at 2-4 weeks of amenorrhea, while another study found higher CA125 values in ectopic pregnancies [12,13]. The slightly increased value detected for this parameter is explained by the presence of pregnancy, either extrauterine or intrauterine.

Because of the impossibility of a precise macroscopic evaluation and of the risk of intraoperative misdiagnosis, it is histopathological examination that establishes the certainty diagnosis. In the case reported by us, the presence of pelvic adhesions made the intraoperative diagnosis of ovarian pregnancy impossible. Taking into consideration the diagnostic algorithm of Spiegelberg in which the ipsilateral uterine tube must be intact, the cases associated with pelvic adhesions or tubal inflammation secondary to ovarian pregnancy can be misdiagnosed. A study monitoring 25 ovarian pregnancy cases reported the impossibility of differentiating between ovarian

pregnancy and ruptured corpus luteum, which emphasizes the difficulty of diagnosis [2].

Laparoscopy can be used as a diagnostic method for ectopic pregnancy when transvaginal ultrasound and β -hCG determinations are inconclusive, but also as a treatment method [14].

The majority of the ovarian pregnancies become ruptured in the first trimester (75-90%), of which 2/3 during the first 8 weeks [15], but they can stop during evolution or spontaneously heal through resorption. There were no recurrence cases and prognosis was favorable for future pregnancies.

The treatment of ovarian pregnancy depends on the gestational age and complications. The medical treatment of ovarian pregnancy with methotrexate, prostaglandin F 2α , prostaglandin E 2 and estrogen was described only in a few cases. The therapy indicated for the majority of the ovarian pregnancy cases is surgery, the preservation of ovarian tissue being essential. Thus, partial ovariectomy, ovarian cystectomy can be performed. Ablation therapy such as ovariectomy or adnexectomy is indicated for advanced or life threatening cases, like the case presented by us. These interventions can be carried out through laparotomy or laparoscopy.

Conclusions

Ovarian pregnancy has a non-specific clinical picture and laboratory and intraoperative diagnosis is sometimes difficult to make, being a challenge to the surgeon.

The association of ovarian pregnancy with pelvic adhesions makes diagnosis even more difficult, in which case only histopathological examination can make the certainty diagnosis.

The evolution of ovarian location is toward rupture in the majority of the cases, which requires an adequate therapeutic approach.

Gynecologists should also consider the ovarian ectopic pregnancy among the many causes of abdominal pain in women at fertile age.

Consent

Written informed consent was obtained from the patient for publication of this case report and any accompanying images.

References

1. Spiegelberg O. Zur Casuistik den Ovarial-Schwangenschaft. Arch Gynaekol, 1878; 13:73.
2. Hallatt JG. Primary ovarian pregnancy: a report of twenty-five cases. Am J Obstet Gynecol, 1982; 143:55-60.
3. Lehfeldt H, Teitze C, Gorstein F. Ovarian pregnancy and the intrauterine device. Am J Obstet Gynecol, 1970; 108:1005.
4. Comstock C, Huston K, Lee W. The ultrasonographic appearance of ovarian ectopic pregnancies. Obstet Gynecol, 2005; 105:42.
5. Yao M, Tulandi T. Current status of surgical and non-surgical treatment of ectopic pregnancy. Fertil Steril, 1997; 67:421.
6. Tulandi T. Current protocol for ectopic pregnancy. Contemp Obstet Gynecol, 1999; 44:42.
7. Silva C, Sammel MD, Zhou L, et al. Human Chorionic Gonadotropin Profile for Women With Ectopic Pregnancy. Obstet Gynecol, 2006; 107:605.
8. Kadar N, DeVore G, Romero R. Discriminatory hCG zone: its use in the sonographic evaluation for ectopic pregnancy. Obstet Gynecol, 1981; 58:156.
9. Cacciatore B, Korhonen J, Stenman U, Ylöstolalo P. Transvaginal sonography and serum hCG in monitoring of presumed ectopic pregnancies selected for expectant management. Ultrasound Obstet Gynecol, 1995; 5:297-300.
10. Atri M, Chow C, Kintzen G et al. Expectant management of ectopic pregnancies: clinical and sonographic predictors. Am J Roentgenol, 2001; 176:123-127.
11. Check JH, Nowroozi K, Winkel CA, et al. Serum CA125 levels in early pregnancy and subsequent spontaneous abortion. Obstet Gynecol, 1990; 75:742-744.
12. Brumsted JR, Nakajima ST, Badger G, et al. Serum concentration of CA125 during the first trimester of normal and abnormal pregnancies. J Reprod Med, 1990; 35:499-502.
13. Sadovsky Y, Pineda J, Collins JL. Serum CA125 levels in women with ectopic and intrauterine pregnancies. J Reprod Med, 1991; 36:875-878.
14. Ona D, Surcel M, Petrescu M, Stamatian F, Kovacs T, Harsa R. Rezolvarea laparoscopică a unui caz de sarcină extrauterină cu localizare ovariană. Obstetrica și Ginecologia, 2008; LVI(1):43-46.
15. Eienkel J, Baier D, Horn LC. Laparoscopic therapy of an intact primary ovarian pregnancy with ovarian hyperstimulation syndrome. H Reprod, 2000; 2037-2040.