

Inadvertent Rupture of a Silicone Breast Implant during Fat Grafting: Surgical and Radiological Findings

Christopher N. Stewart, MD*
Cherrie A. Heinrich, MD†

Summary: Autologous fat grafting is a common, relatively safe procedure for breast augmentation and reconstruction. The most commonly reported complications tend to be fat necrosis and oil cysts. The incidence of rare events, such as breast implant rupture, is likely underreported. Here we present the case of a patient who underwent fat grafting and sustained implant rupture with injection of fat within the silicone implant. She complained of her implant changing shape and magnetic resonance imaging (MRI) showed classic signs of implant rupture (linguini sign). At the time of surgery however, fat was surprisingly found to be within the implant itself. To our knowledge this finding has yet to be reported. Here we review the radiologic and surgical findings of implant rupture following fat grafting and present some suggestions to prevent this occurrence and ensure safe, aesthetically pleasing outcomes. (*Plast Reconstr Surg Glob Open* 2020;8:e2863; doi: [10.1097/GOX.0000000000002863](https://doi.org/10.1097/GOX.0000000000002863); Published online 4 June 2020.)

INTRODUCTION

Autologous fat grafting has quickly become an integral part of both breast augmentation and reconstruction. In this technique, adipose tissue is harvested via liposuction and injected via a blunt cannula or needle to correct various breast deformities. Numerous studies have been published evaluating both its efficacy and safety.^{1,2} Common complications related to fat grafting of the breast include palpable lumps, fat necrosis, oil cysts, and infection. Rare complications include hematoma and pneumothorax, but there are no reported deaths associated with fat grafting into the breast.³ Damage to the breast implant has been rarely reported. In a study of 1000 patients undergoing fat transfer via needle, Maione et al⁴ reported a single implant rupture. In another study evaluating patient satisfaction, Cogliandro et al⁵ reported 1 rupture among 70 patients. In this case report, we discuss the surgical and radiologic findings of a silicone implant rupture from inadvertent damage during fat grafting.

CASE REPORT

The patient is a 61-year-old woman who underwent bilateral mastectomy due to multifocal ductal carcinoma in situ in March 2009. She underwent immediate left side autologous tissue reconstruction with a free transverse rectus abdominis myocutaneous (TRAM) flap and right-sided tissue expander–based reconstruction due to a flap failure. The implant was placed in the prepectoral space. In December 2014, she underwent implant exchange with a form-stable silicone gel implant and fat grafting of bilateral breasts (approximately 300 mL total). She underwent further fat grafting in March 2015 (250 mL bilateral) and again in February 2017 (250 mL to right side only) due to asymmetry between the autologous and implant-based reconstructions. The final fat grafting was performed by the senior author because the previous surgeon left the department. In 2019, she presented to our clinic reporting a change in shape of her implant over the previous 6 months. Physical examination at that time revealed deflation and increased asymmetry. There was concern for rupture, and magnetic resonance imaging (MRI) was ordered.

RADIOLOGIC FINDINGS

A standard breast MRI without contrast was performed and interpreted by a staff radiologist. A “linguini” sign was present, as well as “water droplets and free water at the periphery of the implant” on T2-suppressed images. This was concerning for implant rupture (Fig. 1).

From the *University of Minnesota Department of Surgery, Minneapolis, Minn.; and †Department of Plastic and Hand Surgery, Regions Hospital, St. Paul, Minn.

Received for publication January 19, 2020; accepted March 26, 2020.

Copyright © 2020 The Authors. Published by Wolters Kluwer Health, Inc. on behalf of The American Society of Plastic Surgeons. This is an open-access article distributed under the terms of the [Creative Commons Attribution-Non Commercial-No Derivatives License 4.0 \(CCBY-NC-ND\)](https://creativecommons.org/licenses/by-nc-nd/4.0/), where it is permissible to download and share the work provided it is properly cited. The work cannot be changed in any way or used commercially without permission from the journal.

DOI: [10.1097/GOX.0000000000002863](https://doi.org/10.1097/GOX.0000000000002863)

Disclosure: The authors have no financial interest to declare in relation to the content of this article.

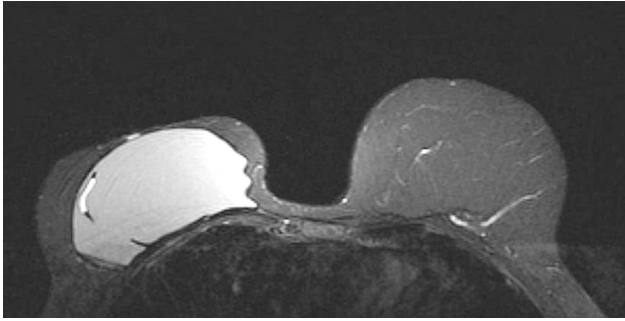


Fig. 1. A T2-suppressed MRI showing a hyperdense material within the silicone breast implant. This was later confirmed to be the injected adipose tissue, which presumably has a high water content.

SURGICAL FINDINGS

Due to the concerns for implant rupture, the patient was taken to the operating room in June 2019 for implant exchange. Her original mastectomy scar was used to access the pocket. The implant was identified and removed, at which point we noted a single small puncture site and obvious yellow fat within the implant shell (Fig. 2). There was no free silicone or fat within the pocket. We proceeded with placing a new implant and further fat grafting (200 mL to the right side only).

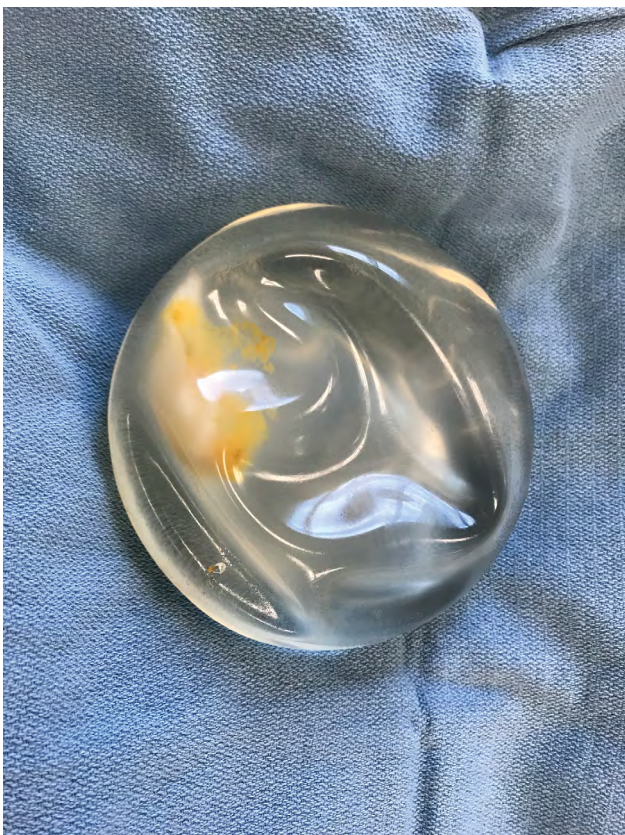

Fig. 2. Silicone breast implant with a single puncture site (lower left) and obvious yellow fat within the implant.

RESULTS

At 2 weeks follow-up, the patient had anticipated bruising and swelling, but subjectively stated that she was overall happy with the current size and shape of her breast.

DISCUSSION

Given the form stability of modern silicone implants, rupture detection can be difficult and often relies on imaging. MRI has been the gold standard (typically reported as having over 90% sensitivity and specificity) for detecting rupture. The classic finding of a linguini sign results from the collapsed shell floating within the silicone, taking on a redundant curvilinear appearance resembling the pasta.⁶ The main drawbacks of MRI are the cost and specialized equipment needed; however, it remains the current FDA recommendation to obtain imaging 3 years following implant placement and every 2 years thereafter for screening.⁷ Ultrasonography can be a cost-efficient and easy-to-use method for evaluating implants; however, the sensitivity and specificity for detecting intracapsular rupture (often referred to as the “step-ladder sign”) are approximately 50%. Detection rates are much higher,

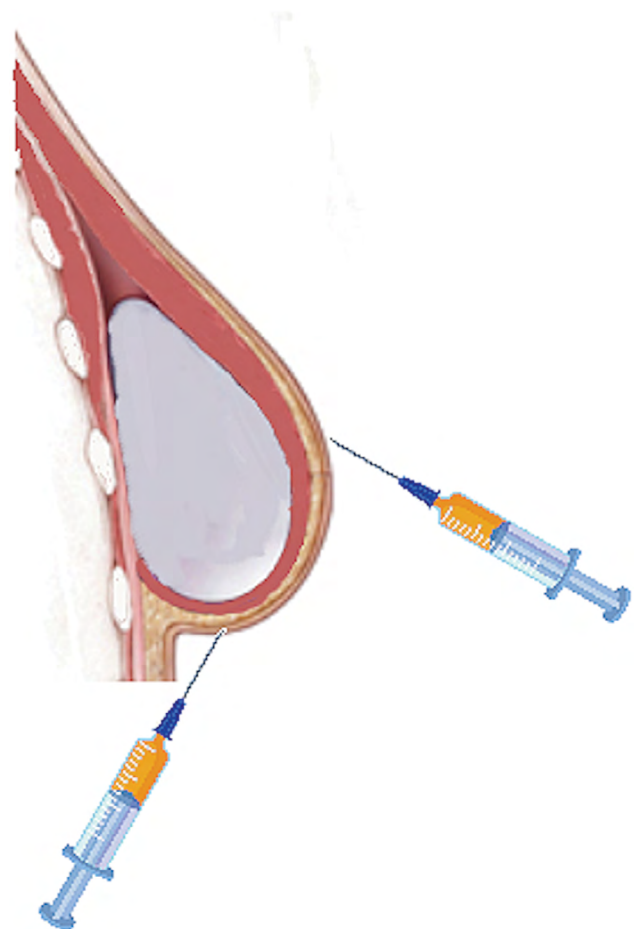


Fig. 3. The syringe on the right demonstrates a “down the hill” approach where a wandering cannula tends to skive away from the implant. The syringe on the left takes an “up the hill” approach, which is harder to control, where a misdirected cannula has a higher tendency to enter into the implant.

nearing 95% in some studies, at detecting extracapsular ruptures (seen as the “snowstorm sign”); however, most ruptures are intracapsular, making this less useful.⁸ There are ongoing studies comparing ultrasound directly with MRI in detecting implant rupture, which showed promising results in regard to safety and accuracy.⁹ Likewise, there are many surgeons successfully using ultrasound in-office to evaluate breast implant integrity without the need for a radiologist.¹⁰ Like ultrasound, mammography can more accurately detect extracapsular versus intracapsular ruptures. Because of aforementioned limitations, most abnormal ultrasound or mammographic findings should prompt follow-up MRI to evaluate silicone implant status.¹¹

There are conflicting data regarding the association of silicone and increased rates of connective tissue disease or other adverse events. Singh et al¹² reviewed 55,000 patients following breast augmentation for up to 8 years and reported no increased risk of systemic disease or adverse events when compared with that reported in national norms or with those with saline implants. However, in 2019, Coroneos et al¹³ reviewed nearly 100,000 patients and found an increased incident ratio for Sjogren’s disease, scleroderma, and rheumatoid arthritis in those with silicone implants. Nahabedian¹⁴ reviewed the diagnosis and management of form-stable implant complications and recommended that once a rupture is diagnosed, all attempts to remove shell fragments and free gel should be made.

Over the past few decades, there has been overall improvement in the quality and integrity of these devices; however, damage from medical instruments continues to be the cause of device failures in over 50% of reported cases.¹⁵ Due to the nature of autologous fat transfer with multiple passes and essentially a blind technique, one can see how this may represent a high-risk procedure for treating implant damage. Interestingly, one study even suggested that left-sided implants seem to be damaged more often owing to surgeons’ overall right handedness.¹² To ensure safety of the implant, surgeons should consider a few guidelines during fat transfer. One should ensure subcutaneous visibility of the tip of the cannula while it is being inserted and avoid plunging the cannula deep. Fat grafting can also be performed with a sizer in place under temporary closure to avoid damaging the permanent implant. Finally, we aim for “down the hill” fat grafting (Fig. 3). With this technique, the cannula is inserted into the skin at or near the apex of the implant mound and passed down the slope of the device. In this manner, it is much less likely that a misplaced cannula will puncture the implant and tends to skive away from the device. With an “up the hill” technique, the patient’s body and the angle of the surgeon’s hand make it much more difficult to direct the cannula and it may inadvertently dive deeper, making contact with the implant and possibly causing a rupture.

CONCLUSIONS

Autologous fat transfer is a common and safe technique used in breast reconstruction and augmentation. When combined with a breast implant, there is a chance for rupture and fat placement within the implant. By following certain principles, surgeons can reduce any risk of this and ensure a cosmetically pleasing and long-lasting result.

Christopher N. Stewart, MD
University of Minnesota
420 Delaware St
Minneapolis, MN 55455
E-mail: stewa909@umn.edu

REFERENCES

- Cohen O, Lam G, Karp N, et al. Determining the oncologic safety of autologous fat grafting as a reconstructive modality: an institutional review of breast cancer recurrence rates and surgical outcomes. *Plast Reconstr Surg*. 2017;140:382e–392e.
- Coleman SR, Saboeiro AP. Fat grafting to the breast revisited: safety and efficacy. *Plast Reconstr Surg*. 2007;119:775–785; discussion 786.
- Herly M, Ørholt M, Larsen A, et al. Efficacy of breast reconstruction with fat grafting: a systematic review and meta-analysis. *J Plast Reconstr Aesthet Surg*. 2018;71:1740–1750.
- Maione L, Vinci V, Klinger M, et al. Autologous fat graft by needle: analysis of complications after 1000 patients. *Ann Plast Surg*. 2015;74:277–280.
- Cogliandro A, Barone M, Tenna S, et al. The role of lipofilling after breast reconstruction: evaluation of outcomes and patient satisfaction with BREAST-Q. *Aesthetic Plast Surg*. 2017;41:1325–1331.
- Gorczyca DP, Gorczyca SM, Gorczyca KL. The diagnosis of silicone breast implant rupture. *Plast Reconstr Surg*. 2007;120(7 suppl 1):49S–61S.
- Hillard C, Fowler JD, Barta R, et al. Silicone breast implant rupture: a review. *Gland Surg*. 2017;6:163–168.
- Bouzghar G, Pokorny K. Intracapsular breast implant rupture. *Ultrasound Q*. 2017;33:93–95.
- Bengtson BP, Eaves FF III. High-resolution ultrasound in the detection of silicone gel breast implant shell failure: background, *in vitro* studies, and early clinical results. *Aesthet Surg J*. 2012;32:157–174.
- Swanson E. The expanding role of diagnostic ultrasound in plastic surgery. *Plast Reconstr Surg Glob Open*. 2018;6:e1911.
- Stivala A, Rem K, Leuzzi S, et al. Efficacy of ultrasound, mammography and magnetic resonance imaging in detecting breast implant rupture: a retrospective study of 175 reconstructive and aesthetic sub-pectoral breast augmentation cases. *J Plast Reconstr Aesthet Surg*. 2017;70:1520–1526.
- Singh N, Picha GJ, Hardas B, et al. Five-year safety data for more than 55,000 subjects following breast implantation: comparison of rare adverse event rates with silicone implants versus national norms and saline implants. *Plast Reconstr Surg*. 2017;140:666–679.
- Coroneos CJ, Selber JC, Offodile AC II, et al. US FDA Breast implant postapproval studies: long-term outcomes in 99,993 patients. *Ann Surg*. 2019;269:30–36.
- Nahabedian MY. Round form-stable breast implants: diagnosis and management of complications. *Plast Reconstr Surg*. 2019;144(1S Utilizing a Spectrum of Cohesive Implants in Aesthetic and Reconstructive Breast Surgery):73S–81S.
- Maisel Lotan A, Retchkiman M, Tuchman I, et al. Analysis of 109 consecutive explanted breast implants: correlation between suspected implant rupture and surgical findings. *Aesthetic Plast Surg*. 2016;40:739–744.