

Buried broken extraction instrument fragment

Access this article online

Website:
www.amsjournal.com

DOI:
10.4103/2231-0746.110076

Quick Response Code:



S. M. Balaji

Consultant Oral and Maxillofacial Surgeon,
Balaji Dental and Craniofacial Hospital, Chennai, India

Address for correspondence:

Dr. S. M. Balaji, Consultant Oral and Maxillofacial Surgeon,
Balaji Dental and Craniofacial Hospital, 30,
Kavingar Bharathidasan Road, Teynampet, Chennai - 600 018, India.
E-mail: smbalaji@gmail.com

ABSTRACT

Despite adequate effort to perform tooth removal carefully, some accidents may happen when defective instruments are unknowingly used. This article reports of a non-symptomatic case of a retained fractured dental elevator tip during an uneventful extraction a decade earlier. Patient was not aware till routine radiographic examination revealed its presence. Use of three dimensional imaging techniques in this case is highlighted. Rarely, instruments breakage may occur during surgical procedures. It is duty of the dentists to check the surgical instrument for signs of breakage and be prepared to solve a possible emergency. Retained fragments should be carefully studied prior to attempt of removal.

Keywords: Cone beam computed tomography, elevator, foreign body, mandible, tooth extraction

INTRODUCTION

Breakage of surgical instruments is an uncommon intra-operative complication that has been reported sporadically in the Exodontia literature. Instrument breakage has to be managed with a successful search for the broken fragment and removal to avoid potential issues like infection or other complications including swallowing or aspiration of the fragment.^[1]

The aim of the present report is to describe an unusual case of a retained tip of an elevator in the left mandibular molar region and remained asymptomatic for ten years till it was diagnosed during routine radiographic examination for rehabilitation of some other tooth.

CASE REPORT

A 60 year old female reported to this centre for rehabilitation of the periodontally compromised anterior teeth. In routine radiographical examination, a triangular radiopaque mass was identified in the orthopantomogram [Figure 1a] in the left mandibular third molar region. On history, an uneventful extraction of the third molar ten years back in some other surgery was performed. There was no history of pain, swelling, discharge or paraesthesia elicited. Based on the history and clinical

correlation, the object was assumed to be a tip of an elevator. A three dimensional Cone Beam Computerized Tomography was performed and reformatting done.

It was observed that the metallic tip was positioned in an oblique fashion with the tip directed distally. [Figure 1b] There was a split in the bone with radiographical evidence of a wedge like split in the mandible in the region [Figure 1c]. This was observed in axial section. The tip of the elevator had a good clearance with the Inferior Alveolar Nerve. The tip was planned to be removed under local anesthesia with curettage of any granulation tissue. After achieving adequate anesthesia with lignocaine, a trough was made in the area after reflection of the mucoperiosteal flap. Bone was removed for a depth for about 3 mm and the tip was localized. There was a grayish tissue material surrounding the tip [Figure 1d]. A trough was cut surrounding the upper half of the tip of the elevator. The tip [Figure 1e] was retrieved using artery forceps and the area thoroughly curetted. The tissue was closed with sutures. The healing was uneventful.

DISCUSSION

Burs, endodontic files and occasionally other dental instruments tend to break during surgical procedures owing to several reason

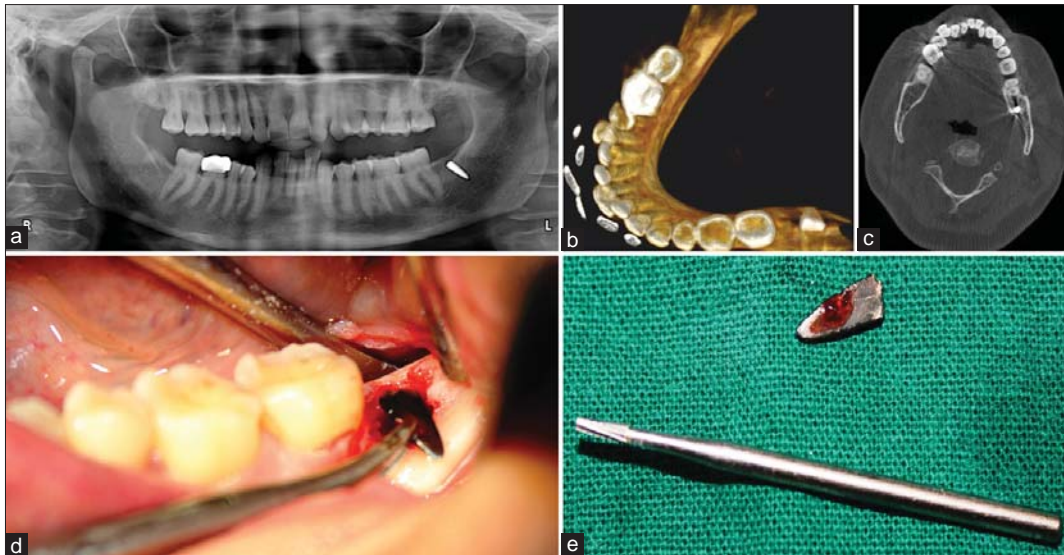


Figure 1: (a) Orthopantomogram of the patient with tip in place, (b) 3D formatted image of the root tip from CBCT, (c) Axial View in CBCT. Note the horizontal split, (d) Clinical Photo. Note the blackish tissue, (e) The size of the elevator tip

including defective manufacturing, stress, fatigue, rust or poor handling.^[1] It is in the better interest of the patients that the broken part be retrieved. This case, in particular, is unique as the tip had been left *in situ* for about a decade.

The location and retrieval of fragments broken during surgery due to broken exodontic instruments is not a common problem in dental practice. In the literature, only four papers were found to be associated with exodontias instruments. These reported five cases where in four involved elevators and in one instance a hinge pin was loosened inside patient's mouth and swallowed by the patient.^[1,2]

In the present case, contradictory to earlier reports, elevator tip was lodged inside the bone and was subsequently surrounded by a layer of granulation tissue. It is to be emphasized that in most of the situations, elevator's fracture happened during permanent teeth extractions and were identified immediately.^[1] However, in the present case, it was identified a decade later. Although metallic fragments, if left *in situ* could be enclosed in a fibrous tissue capsule when recognized by the host as a foreign body, objects dislodged into the soft tissues may gain access to the adjacent spaces.

CBCT is an excellent tool to identify metallic foreign objects. It has been proved to be a versatile technique in identifying the foreign objects in its near original structure and orientation.^[3] Hence this imaging modality was employed.

In the present case, probably the tip was left back in the socket and subsequently surrounded by granulation tissue and by bone later. In CBCT, the tip was localized 3 mm below the alveolar crest. The tip of the elevator has caused a split in the mandible

as observed in the Figure 1b and c. If the split had been caused during the extraction, it would have caused pain. The split could have been as a result of the wedging action of the tip during the bone remodeling. Owing to prior knowledge of the weak area, surgical manipulation was done carefully avoiding a potential fracture.

CONCLUSION

Dentists are expected to be careful especially when instruments are used in poorly visible areas such as the third molar regions. It is always advisable to use quality and reliable products. Preoperative and postoperative checkup of instruments is also essential. If an untoward accident happens, dentists should inform the patients and take adequate measures to solve the issue without further injury to the patient. In case, retention of broken instrument is suspected, a three dimensional imaging will indicate the actual position and will help to avoid potential surgical complications.

REFERENCES

1. da Silva Pierro VS, de Morais AP, Granado L, Maia LC. An unusual accident during a primary molar extraction. *J Clin Pediatr Dent* 2010;34:193-6.
2. Moore UJ, Fanibunda K, Gross MJ. The use of a metal detector for localization of a metallic foreign body in the floor of the mouth. *Br J Oral Maxillofac Surg* 1993;31:191-2.
3. Eggers G, Welzel T, Mukhmadiev D, Wortche R, Hassfeld S, Muhling J. X ray Based Volumetric Imaging of foreign Bodies: A comparison of Computed tomography and digital volume tomography. *J Oral Maxillofac Surg* 2007;65:1880-5.

Cite this article as: Balaji SM. Burried broken extraction instrument fragment. *Ann Maxillofac Surg* 2013;3:93-4.

Source of Support: Nil, **Conflict of Interest:** None declared.