

[CASE REPORT]

Effectiveness of Additional Immunosuppressive Drugs for Corticosteroid-refractory Immune Checkpoint Inhibitor-induced Myocarditis: Two Case Reports

Hiroyuki Sakaguchi¹, Shigeki Nanjo², Shigeki Sato¹, Hiroshi Kotani¹, Akihiro Nishiyama¹,
Kaname Yamashita¹, Koushiro Ohtsubo¹, Chiaki Suzuki³, Masaya Shimojima⁴,
Seiji Yano² and Shinji Takeuchi¹

Abstract:

Immune checkpoint inhibitors (ICIs) improve the outcomes of several types of cancer. However, they are also associated with various immune-related adverse events including myocarditis. ICI-induced myocarditis is a rare, potentially life-threatening adverse event. We herein report two cases of corticosteroid-refractory ICI-induced myocarditis. In both cases, additional immunosuppressive therapies, such as intravenous immunoglobulin and tacrolimus, successfully resolved myocarditis. Given the corticosteroid-refractory nature of these cases, we suggest that prompt addition of other immunosuppressive drugs to corticosteroid therapy should be considered in the treatment of ICI-induced myocarditis.

Key words: irAEs, myocarditis, IVIG, tacrolimus

(Intern Med 64: 1205-1210, 2025)

(DOI: 10.2169/internalmedicine.4162-24)

Introduction

Immune checkpoint inhibitors (ICIs) have recently improved the prognosis of patients with various types of cancer. However, these drugs may cause immune-related adverse events (irAEs) (1). Previous reports indicate that ICI-induced myocarditis occurs in only 0.06% to 1% of cases but is associated with a 30% to 50% mortality rate (2-4). The American Society of Clinical Oncology (ASCO) clinical guidelines for irAEs recommend high-dose corticosteroids and additional immunosuppressive therapy if steroids fail to treat ICI-induced myocarditis (1). However, few clinical trials have compared the efficacy of immunosuppressive drugs with that of other treatments, including placebo, in the treatment of myocarditis. Therefore, reporting cases in which additional immunosuppressive drugs are effective in treating corticosteroid-refractory ICI-induced myocarditis is essential.

We herein report two cases of corticosteroid-refractory ICI-induced myocarditis in which irAEs were controlled with additional immunosuppressive therapies, such as intravenous immunoglobulin (IVIG) and tacrolimus.

Case Reports

Case 1

A 73-year-old man with lung adenocarcinoma (cT4N2M1 c, stage IVB) was treated with carboplatin, pemetrexed, and pembrolizumab as first-line therapy. On day 20, after the second course of treatment, the patient presented with proximal muscle pain. A physical examination revealed tenderness in the neck, upper arms, and thighs, which led to a diagnosis of myositis.

His serum total creatine kinase (CK) and troponin T levels were elevated to 21,322 IU/L (normal range: 30-287 IU/

¹Department of Medical Oncology, Kanazawa University Hospital, Japan, ²Department of Respiratory Medicine, Kanazawa University Hospital, Japan, ³Department of Otolaryngology-Head and Neck Surgery, Graduate School of Medicine, Kyoto University, Japan and ⁴Department of Cardiovascular Medicine, Kanazawa University Graduate School of Medical Sciences, Japan

Received: May 20, 2024; Accepted: July 10, 2024; Advance Publication by J-STAGE: September 4, 2024

Correspondence to Dr. Hiroyuki Sakaguchi, h.sakaguchi@staff.kanazawa-u.ac.jp

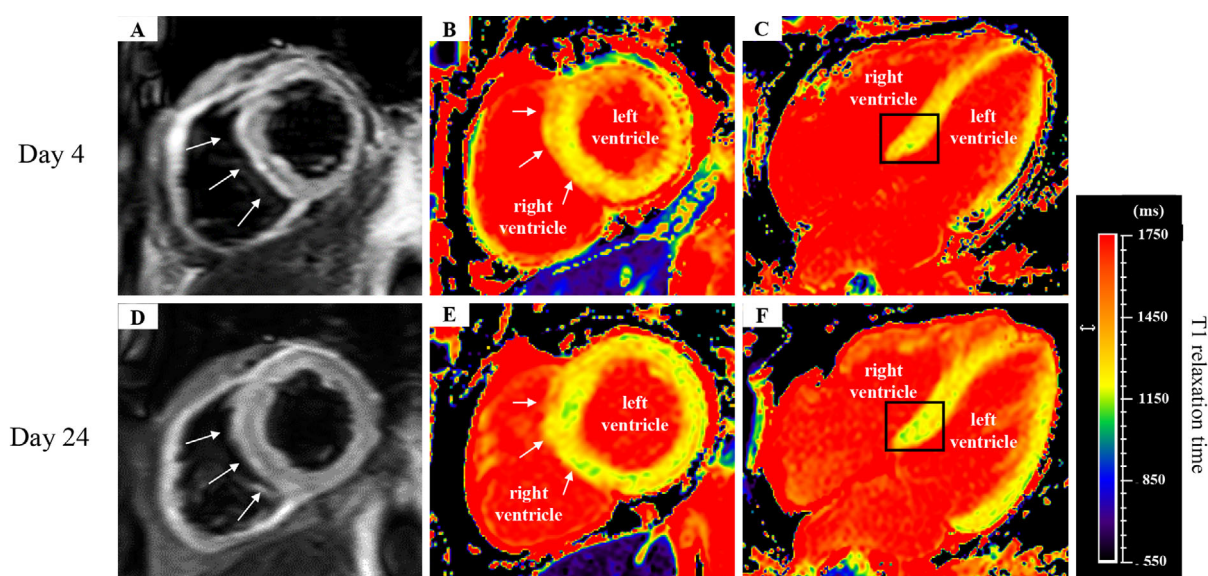


Figure 1. CMRI findings for Case 1. (A-C) Initial CMRI performed on day 4. These figures depict the STIR and increased T2 signal (A); T1 relaxation time was prolonged due to myocardial edema at the onset of myocarditis (B, C). (D-F) Second CMRI examination performed on day 24. Following immunosuppressive therapy, the STIR T2 signal had decreased (D) and the T1 relaxation time shortened (E, F) compared with before myocarditis treatment, indicating improvement of myocardial edema. CMRI: cardiovascular magnetic resonance imaging, STIR: short tau inversion recovery

L) and 0.697 ng/mL (normal range: <0.014 ng/mL), respectively. Electrocardiography (ECG) revealed sinus rhythm with right bundle branch block. Chest radiography and echocardiography revealed no signs of heart failure. However, cardiovascular magnetic resonance imaging (CMRI) findings, including short tau inversion recovery (STIR) T2 and T1 relaxation times, were consistent with myocarditis. CMRI revealed an increased T2 signal and prolonged T1 relaxation time, indicative of myocardial edema (Fig. 1A-C). The patient was therefore diagnosed with ICI-induced myocarditis.

ICI therapy was discontinued, and treatment with intravenous methylprednisolone 1 g/day was initiated for 3 days. Within the first 48 h, the patient's CK level and muscle pain improved significantly with corticosteroid monotherapy; however, troponin T levels increased to 2.52 ng/mL. Intravenous methylprednisolone was re-administered for another 3 days, followed by 1 mg/kg/day (60 mg/day). Despite this, his troponin T level further increased to 4.35 ng/mL, and ECG indicated complete heart block (CHB).

Given the inadequate response to corticosteroids, immunosuppressive drugs have been added to the management of myocarditis in our facility. IVIG (20 g) was therefore administered for 5 days along with tacrolimus (2 mg/day), and a temporary pacemaker was placed. Subsequently, the troponin T level decreased rapidly and the patient's ECG findings returned to normal sinus rhythm. Consequently, intravenous methylprednisolone was switched to prednisolone and the dose was tapered without adverse cardiac events (Fig. 2).

Following the improvement in myocarditis, CMRI per-

formed 24 days after the onset of myocarditis as an irAE revealed an improvement in myocardial edema, with normalization of the STIR T2 signal and T1 relaxation time (Fig. 1D-F). In addition, follow-up contrast-enhanced computed tomography performed two months after the onset of the irAE showed a 90% reduction in lung tumor size according to the Response Evaluation Criteria In Solid Tumors (RECIST) version 1.1 (Fig. 3).

Case 2

A 67-year-old man was diagnosed with papillary renal cell carcinoma (RCC) with lymph node metastasis (cT1aN2M1, stage IV). The patient was treated with ipilimumab and nivolumab as first-line therapy. Twenty-one days after the first dose, the patient developed palpitations. ECG revealed atrial fibrillation with tachycardia, and his serum troponin T level was elevated to 0.143 ng/mL. Thyroid function tests indicated thyrotoxicosis, with a thyroid-stimulating hormone level of 0.03 μ U/mL (normal range: 0.27-4.20 μ U/mL) and a free thyroxine (T4) level of 5.72 ng/dL (normal range: 1.00-1.80 ng/dL). He was re-admitted with suspected thyrotoxicosis and diagnosed with ICI-induced destructive thyroiditis based on technetium-99 m pertechnetate thyroid imaging. Despite a decrease in serum free T4 levels, the troponin T level increased to 0.625 ng/mL, and ECG showed no improvement. Based on the results of these tests, the patient was diagnosed with ICI-induced myocarditis, and prednisolone (2 mg/kg) was initiated.

However, the troponin T levels did not decrease following this treatment. Therefore, on hospital day 24, we administered methylprednisolone at 1 g/day for 3 days, followed by

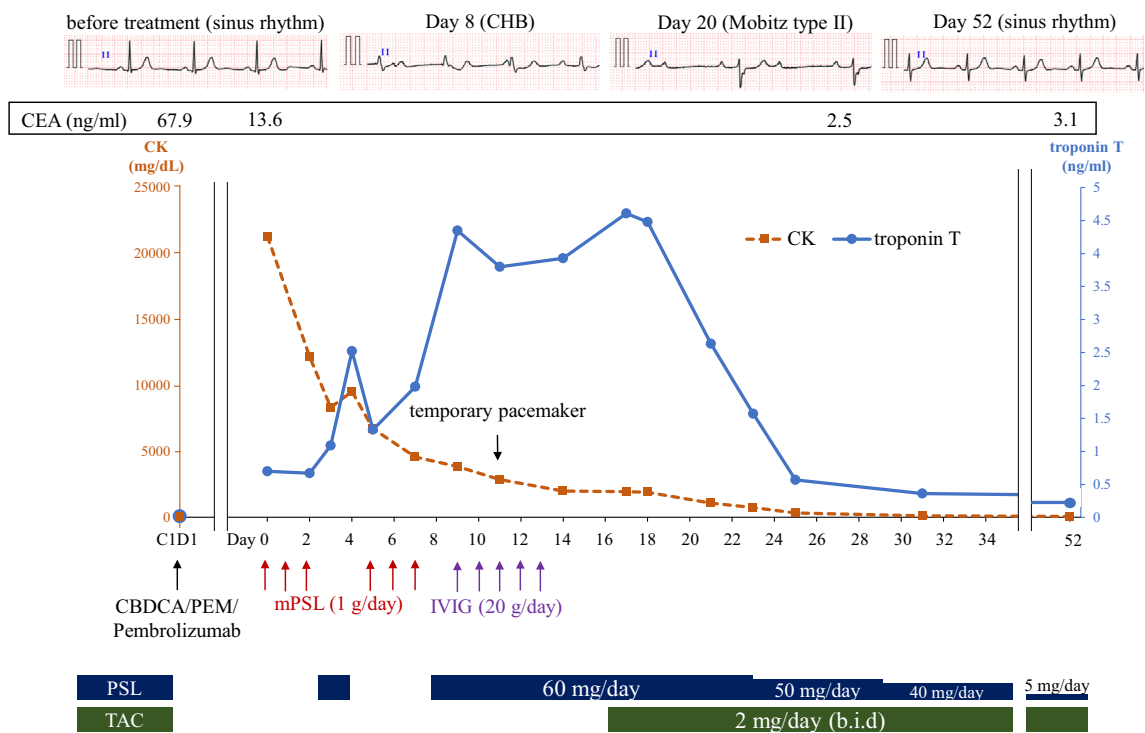


Figure 2. Timeline of CK, troponin T, and treatment of ICI-induced myocarditis and myositis for Case 1. b.i.d.: bis in die (two times a day), CBDCA: carboplatin, CEA: carcinoembryonic antigen, CHB: complete heart block, CK: creatine kinase, IVIG: intravenous immunoglobulin, mPSL: methylprednisolone, PEM: pemetrexed, PSL: prednisolone, TAC: tacrolimus

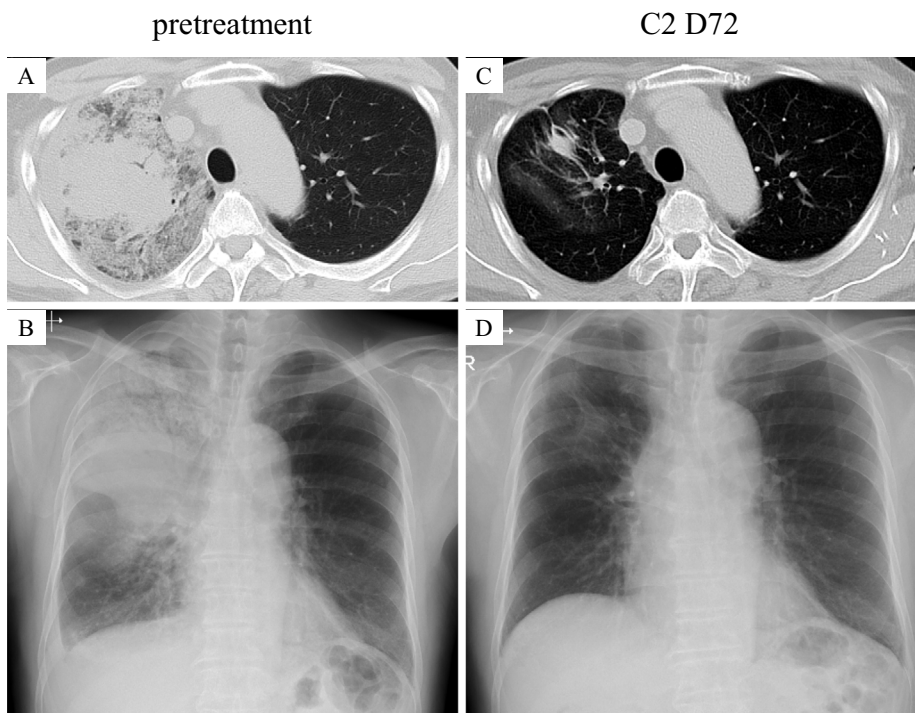


Figure 3. The course of treatment for lung cancer. (A, B) Pretreatment chest X-ray and CT showing the primary lesion in the upper lobe of the right lung. (C, D) Chest X-ray and CT findings 72 days after last chemotherapy, showing that the tumor had maintained 90% reduction in size according to the Response Evaluation Criteria In Solid Tumors (RECIST) version 1.1. CT: computed tomography

a dose of 1 mg/kg/day (60 mg/day). This treatment initially decreased the troponin T level but increased it again on hospital day 34. A myocardial biopsy was performed to assess the extent of myocarditis, which revealed myocardial fibro-

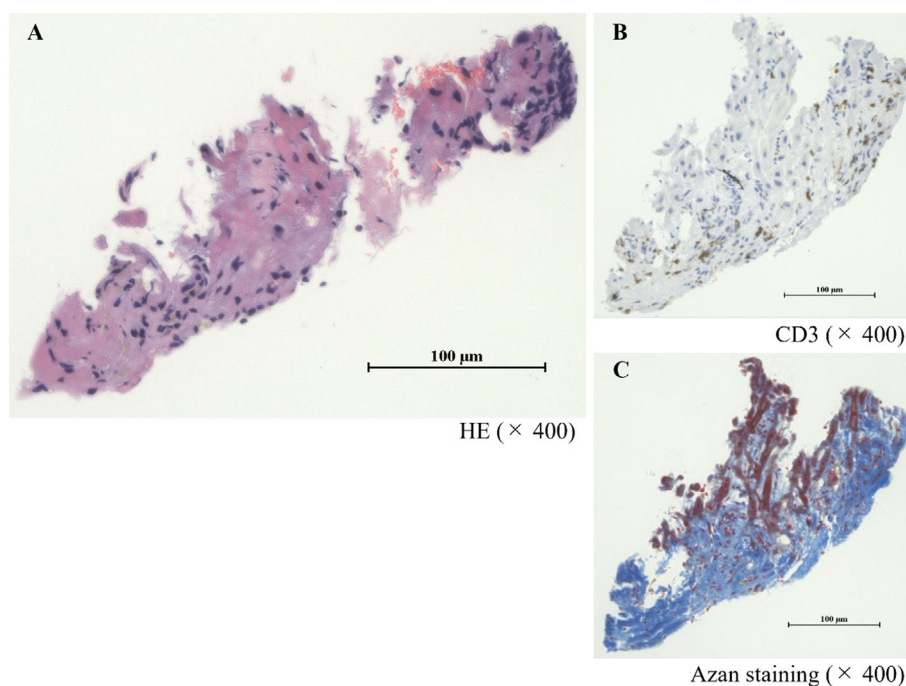


Figure 4. Histological findings of a myocardial biopsy for Case 2. The myocardial biopsy performed on day 34. (A, B) There is observable infiltration of lymphocytes into the myocardial extracellular space. (C) Azan staining depicting fibrosis (blue area). HE: Hematoxylin and Eosin staining

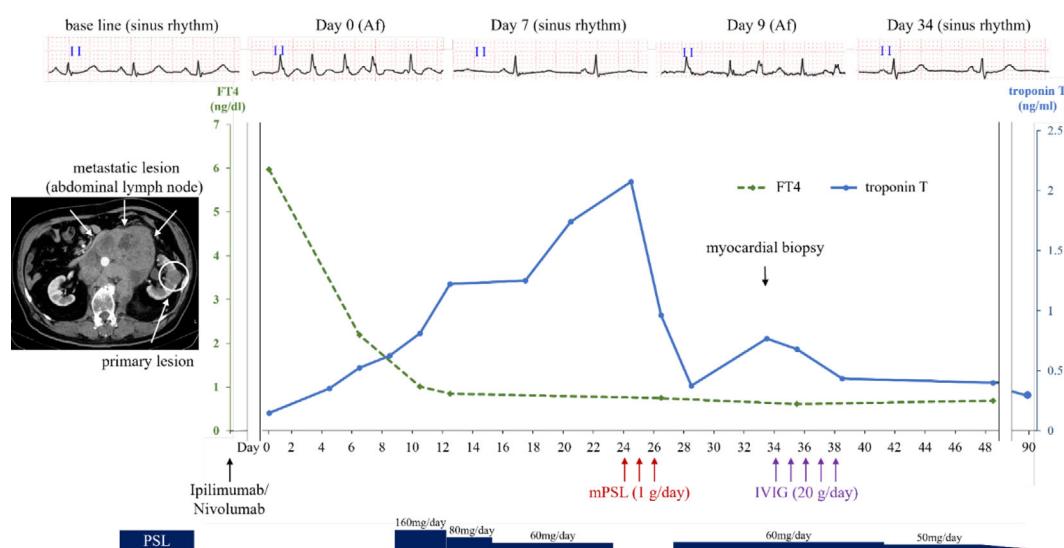


Figure 5. Timeline of CK, free T4, and treatment of ICI-induced myocarditis for Case 2. Af: atrial fibrillation, CK: creatine kinase, FT4: free T4, ICI: immune checkpoint inhibitor, IVIG: intravenous immunoglobulin, mPSL: methylprednisolone, PSL: prednisolone

sis due to myocarditis as well as lymphocytic infiltration of the myocardium despite treatment with high-dose corticosteroids (Fig. 4), suggesting that corticosteroid monotherapy was insufficient for treating myocarditis. As a result, we administered IVIG at 20 g/day for 5 days. Subsequently, the troponin T level decreased rapidly, and the corticosteroid was switched back to prednisolone, which was slowly tapered without further adverse cardiac events (Fig. 5). The patient did not receive any further therapy for RCC and ex-

perienced disease progression six months after the initial treatment.

Discussion

Immunotherapy with ICIs is an effective treatment for several types of cancer and has become the standard cancer therapy (5). However, severe irAEs, such as myocarditis, can be life-threatening. Although myocarditis is rare, affecting

only 0.06-1% of patients (2), it is associated with a high mortality rate of 30-50% (2-4). Corticosteroid therapy is considered effective for treating myocarditis; however, there is limited literature comparing its efficacy with that of placebo or determining its overall effectiveness. Many cases of ICI-induced myocarditis are refractory to corticosteroid treatment (6). The ASCO clinical guidelines for irAEs recommend that patients who do not respond immediately to high-dose corticosteroids (1-2 mg/kg/day of prednisolone) receive early consideration for the administration of 1 g of methylprednisolone daily, along with additional immunosuppressive drugs (1). In many cases, corticosteroid monotherapy does not improve the course of ICI-induced myocarditis, necessitating the use of additional immunosuppressive drugs to suppress its activity (7-10).

The efficacy of additional immunosuppressive drugs targeting T cells has been reported for corticosteroid-refractory ICI-induced myocarditis (11, 12). Tacrolimus, used in Case 1, is a known calcineurin inhibitor. Calcineurin activation increases Interleukin-2 (IL-2) expression and promotes the T cell differentiation and survival. Tacrolimus inhibits calcineurin activity by binding to the immunophilin FK506 binding protein (13). In addition, recent studies have reported that IVIG has immunosuppressive effects on T cells. IVIG administration expands Tregs, leading to negatively regulation of T cell activation via antigen-presenting cell-derived IL-33 and prostaglandin E2 (14, 15). It has also been reported that Treg expansion is induced by antigen presentation of IgG Treg epitopes called Tregitopes (16). Other mechanisms that directly suppress T cell activity by suppressing IL-2 in the absence of regulatory T cells have also been reported (17). Although potentially effective, the use of additional immunosuppressive drugs can lead to infectious complications. According to previous reports, sepsis is also associated with the use of additional immunosuppressive drugs (11, 12). In this regard, no adverse events leading to death were reported in a clinical trial evaluating the efficacy of IVIG for dermatomyositis, and the combination of tacrolimus was acceptable in this trial (18). However, thrombosis should be noted as a serious adverse event in IVIG therapy (18), and the safety and efficacy of tacrolimus should be evaluated through therapeutic drug monitoring (19). Although there are few case reports on the efficacy of tacrolimus (20, 21) and IVIG (22) in ICI-induced myocarditis, we used these drugs as T cell-targeted immunosuppressive agents, which are considered effective and relatively safe for the reasons mentioned above.

CHB is a complex and potentially fatal condition, as noted in the first case. A previous report suggested that CHB is associated with 36% of myocarditis cases and 64% of related fatalities (6). Clinicians should consider the combination of additional immunosuppressive drugs with steroid therapy as the first-choice treatment for ICI-induced myocarditis, especially in cases involving complicated conduction disturbances, such as CHB.

Myositis is among the most frequently reported irAEs as-

sociated with myocarditis, followed by hepatitis and thyroiditis (6). In the two cases presented here, myocarditis did not improve with corticosteroid monotherapy; however, conditions such as myositis and thyroiditis responded to corticosteroid treatment. This finding suggests that the sensitivity of myocarditis to corticosteroids may differ from that of other complicating irAEs.

In conclusion, clinicians should consider prompt supplementation of immunosuppressive drugs, targeting T cells, beyond corticosteroids to effectively address ICI-induced myocarditis, even if other complicated irAEs respond to corticosteroid monotherapy.

The author states that he has no Conflict of Interest (COI).

References

- Schneider BJ, Naidoo J, Santomaso BD, et al. Management of immune-related adverse events in patients treated with immune checkpoint inhibitor therapy: ASCO guideline update. *J Clin Oncol* **39**: 4073-4126, 2021.
- Ganatra S, Neilan TG. Immune checkpoint inhibitor-associated myocarditis. *Oncologist* **23**: 879-886, 2018.
- Salem JE, Manouchehri A, Moey M, et al. Cardiovascular toxicities associated with immune checkpoint inhibitors: an observational, retrospective, pharmacovigilance study. *Lancet Oncol* **19**: 1579-1589, 2018.
- Nguyen LS, Cooper LT, Kerneis M, et al. Systematic analysis of drug-associated myocarditis reported in the World Health Organization pharmacovigilance database. *Nat Commun* **13**: 25, 2022.
- Postow MA, Callahan MK, Wolchok JD. Immune checkpoint blockade in cancer therapy. *J Clin Oncol* **33**: 1974-1982, 2015.
- Atallah-Yunes SA, Kadado AJ, Kaufman GP, Hernandez-Montfort J. Immune checkpoint inhibitor therapy and myocarditis: a systematic review of reported cases. *J Cancer Res Clin Oncol* **145**: 1527-1557, 2019.
- Wang H, Tian R, Gao P, Wang Q, Zhang L. Tocilizumab for fulminant programmed death 1 inhibitor-associated myocarditis. *J Thorac Oncol* **15**: e31-e32, 2020.
- Imai R, Ono M, Nishimura N, Suzuki K, Komiyama N, Tamura T. Fulminant myocarditis caused by an immune checkpoint inhibitor: a case report with pathologic findings. *J Thorac Oncol* **14**: e36-e38, 2019.
- Frigeri M, Meyer P, Banfi C, et al. Immune checkpoint inhibitor-associated myocarditis: a new challenge for cardiologists. *Can J Cardiol* **34**: 92. e91-92. e93, 2018.
- Yanase T, Moritoki Y, Kondo H, Ueyama D, Akita H, Yasui T. Myocarditis and myasthenia gravis by combined nivolumab and ipilimumab immunotherapy for renal cell carcinoma: a case report of successful management. *Urol Case Rep* **34**: 101508, 2021.
- Wang C, Lin J, Wang Y, et al. Case series of steroid-resistant immune checkpoint inhibitor associated myocarditis: a comparative analysis of corticosteroid and tofacitinib treatment. *Front Pharmacol* **12**: 770631, 2021.
- Salem JE, Bretagne M, Abbar B, et al. Abatacept/ruxolitinib and screening for concomitant respiratory muscle failure to mitigate fatality of immune-checkpoint inhibitor myocarditis. *Cancer Discov* **13**: 1100-1115, 2023.
- Thomson AW, Bonham CA, Zeevi A. Mode of action of tacrolimus (FK506): molecular and cellular mechanisms. *Ther Drug Monit* **17**: 584-591, 1995.
- Fiebiger BM, Maamary J, Pincetic A, Ravetch JV. Protection in antibody- and T cell-mediated autoimmune diseases by antiinflam-

- matory IgG Fcs requires type II FcRs. *Proc Natl Acad Sci U S A* **112**: E2385-E2394, 2015.
15. Trinath J, Hegde P, Sharma M, et al. Intravenous immunoglobulin expands regulatory T cells via induction of cyclooxygenase-2-dependent prostaglandin E2 in human dendritic cells. *Blood* **122**: 1419-1427, 2013.
16. De Groot AS, Moise L, McMurry JA, et al. Activation of natural regulatory T cells by IgG Fc-derived peptide "Tregitopes". *Blood* **112**: 3303-3311, 2008.
17. Hori A, Fujimura T, Murakami M, Park J, Kawamoto S. Intravenous immunoglobulin (IVIg) acts directly on conventional T cells to suppress T cell receptor signaling. *Biochem Biophys Res Commun* **522**: 792-798, 2020.
18. Aggarwal R, Charles-Schoeman C, Schessl J, et al. Trial of intravenous immune globulin in dermatomyositis. *N Engl J Med* **387**: 1264-1278, 2022.
19. Brunet M, van Gelder T, Åsberg A, et al. Therapeutic drug monitoring of tacrolimus-personalized therapy: second consensus report. *Ther Drug Monit* **41**: 261-307, 2019.
20. Norwood TG, Lenneman CA, Westbrook BC, Litovsky SH, McKee SB, Conry RM. Evolution of immune checkpoint blockade-induced myocarditis over 2 years. *JACC Case Rep* **2**: 203-209, 2020.
21. Arangalage D, Delyon J, Lermuzeaux M, et al. Survival after fulminant myocarditis induced by immune-checkpoint inhibitors. *Ann Intern Med* **167**: 683-684, 2017.
22. Norwood TG, Westbrook BC, Johnson DB, et al. Smoldering myocarditis following immune checkpoint blockade. *J Immunother Cancer* **5**: 91, 2017.

The Internal Medicine is an Open Access journal distributed under the Creative Commons Attribution-NonCommercial-NoDerivatives 4.0 International License. To view the details of this license, please visit (<https://creativecommons.org/licenses/by-nc-nd/4.0/>).