

# Liquid-based cytological and immunohistochemical study of nasopharyngeal swab from persons under investigation for SARS-CoV-2 infection

David Parada,<sup>1</sup>  Karla B Peña,<sup>1</sup> Josep Gumà,<sup>2</sup> Carmen Guilarte<sup>1</sup> & Francesc Riu<sup>1</sup>

<sup>1</sup>Department of Pathology, Hospital Universitari de Sant Joan, Institut d'Investigació Sanitària Pere Virgili, Facultat de Medicina, Universitat Rovira i Virgili, and <sup>2</sup>Department of Oncology, Hospital Universitari de Sant Joan, Institut d'Investigació Sanitària Pere Virgili, Facultat de Medicina, Universitat Rovira i Virgili, Reus, Spain

Date of submission 20 July 2020

Accepted for publication 16 September 2020

Published online Article Accepted 24 September 2020

Parada D, Peña K B, Gumà J, Guilarte C & Riu F

(2021) *Histopathology* 78, 586–592. <https://doi.org/10.1111/his.14257>

## Liquid-based cytological and immunohistochemical study of nasopharyngeal swab from persons under investigation for SARS-CoV-2 infection

**Introduction:** We describe cytologic and immunohistologic findings in virus transport medium on cases under investigation of SARS-CoV-2 infection.

**Methods:** Cytologic findings in cases under investigation of SARS-CoV-2 infection from one hundred consecutive nasopharyngeal swab were reviewed. Immunohistochemistry and SARSCoV-2 RT-PCR determination were performed to detect virus.

**Results:** No viral inclusions were noted in squamous cells obtained from virus transport medium. Immunohistochemical study with monoclonal antibody

against SARS-CoV-2 viral nucleoprotein showed positivity in squamous cells. No positivity was present in others cellular components.

**Conclusions:** SARS-CoV-2 predominantly localizes squamous cells in cytology samples of patients with RT-PCR positive determination of SARSCoV-2. The results of the current study support the notion that the nasopharyngeal region is the anatomical station that SARS-CoV-2 infects first, and the infection can lead to the migration of the virus into the lower airways.

**Keywords:** COVID-19, cytology, immunohistochemical, liquid-based, nasopharynx, RT-PCR, SARS-CoV-2, swab, viral transport medium

## Introduction

In December 2020, a new type of coronavirus was identified as the causative factor in a series of cases of severe pneumonia in the city of Wuhan, province of Hubei, in the People's Republic of China.<sup>1</sup> The World Health Organization gave the official name “COVID-19” for this coronavirus disease, as well as the term “severe acute respiratory syndrome coronavirus 2” (SARS-CoV-2) for the virus.<sup>2</sup> This virus is currently the cause of a global pandemic, producing hundreds

of thousands of hospital admissions and deaths, with enormous effects on the health and life of the population and serious economic consequences for society.

The tests currently used for the direct identification of SARS-CoV-2 are mainly aimed at detecting viral RNA through nucleic acid amplification, generally using the polymerase chain reaction. The nasopharynx and/or oropharynx are the most tested sampling sites using swabs, with a slightly greater sensitivity shown by the nasopharyngeal swab.<sup>3</sup> This test uses virus transport medium to carry it out, however to the best of our knowledge no cytological studies of the virus transport medium have been carried out.

In this article, we report the cytological findings of the universal transport medium used to investigate

Address for correspondence: D Parada, Pathology Molecular Unit, Department of Pathology, Hospital Universitari de Sant Joan, Av. Del Dr Josep Laporte, 1, Reus, Tarragona 43204, Spain. e-mail: david.parada@urv.cat

cases of SARS-CoV-2 infection, as to cell types present and whether there is a viral cytopathic effect in the infected cells. In addition, we included the immunohistochemical study for the SARS-CoV-2 viral nucleoprotein and viral RNA.

## Materials and methods

### STUDY DESIGN AND PATIENT COHORT

This is a prospective and descriptive cohort study conducted on consecutive cases under investigation (CUI) of SARS-CoV-2 infection in Hospital Universitari de Sant Joan, in Reus, Spain, between 1st April 2020 and 30th July 2020. The study protocol followed the principles of the Declaration of Helsinki 1964 and its subsequent modifications. We included 100 samples of nasopharyngeal swab in universal transport medium (UTM) for SARS-CoV-2 infection submitted to molecular pathology unit of our pathology department. SARS-CoV-2 infection detection was performed by reverse transcription-polymerase chain reaction (RT-PCR) using swab samples from the upper respiratory tract (nasopharyngeal exudate). Tests were carried out with the VIASURE SARS-CoV-2 Real Time PCR Detection kit that detects ORF1ab and N genes (CerTest Biotec, Zaragoza, Spain). RNA was extracted in a QIAcube apparatus with RNeasy reagents (Qiagen N.V., Hilden, Germany) according to the manufacturer's instructions, and analyses were carried out in a 7500 Fast RT-PCR System (Applied Biosystems, Foster City, CA, USA). Patient clinical, and laboratory data were extracted from medical records. The cycle threshold (Ct) values were reported by the cobas SARS-CoV-2 test as either "positive" (N and ORF1a genes detected, Ct values < 38), "presumptive positive" (N gene or ORF1a gene detected, Ct values < 38), or "negative" (N and ORF1a genes not detected, Ct value ≥ 38).

### LIQUID-BASED CYTOLOGY

After SARS-CoV-2 RT-PCR determination, the UTM was processed to liquid-based cytology with the Thin Prep 5000™ LBC method (Hologic Co., Marlborough, MA, USA). All the UTM material was fixed with the hemolytic and preservative solution Cytolyt™. The UTM material was spun at 1008 g per 5 min.; the sediment was then transferred to 20 ml Preservcyt™ solution, keeping for 15 min at room temperature, to be processed with a T5000 automated processor according to the manufacturer's recommendations. Two slides for each sample were obtained and were

fixed in 95% ethanol. The second slide was stained with Papanicolaou, whilst the first slide was processed to immunocytochemistry. This was done to try to preserve as much material as possible for the immunohistochemical study. Cell types were assessed and quantitative analysis was performed, taking 10 consecutive fields at 10×.

### IMMUNOHISTOCHEMISTRY

Immunocytochemical staining protocol was previously validated with anti-SARS-CoV-2 NP antibody, Clone # 6F10 (BioVision Incorporated®, Milpitas, CA, USA) in samples obtained from UTM material processed by liquid-based cytology, with 10 positive and 10 negative samples by RT-PCR. Immunocytochemical staining was carried out on all the samples processed for liquid cytology which were placed in a VENTANA® Benchmark ULTRA/LT automatic immunohistochemistry processor (Ventana Medical Systems, Oro Valley, AZ, USA), using the previously standardized protocol for SARS-CoV-2 detection that included recovery solution pH9, 40 min. at 100°C and the Optiview® DAB Immunohistochemistry Detection Kit (VENTANA®). For incubation with the primary anti-SARS-CoV-2 NP antibody, Clone # 6F10 (BioVision Inc®), after reconstitution with 100 ml of distilled water, a 1:1000 dilution was used, this incubation was carried out for 32 min. at 36°C. Finally, slides were treated with diaminobenzidine, contrasted with Meyer's hematoxylin, dehydrated with alcohols at increasing concentrations and rinsed with xylol, to finally be examined under an Olympus BX41 light microscope at 3.5× and 60×. The presence of SARS-CoV-2 positivity was considered when cytoplasmic labeling was obtained in cells of liquid-based cytology. The intensity of the reaction was cataloged as negative: no staining; 1+: weak cytoplasmic staining; 2+: moderate cytoplasmic staining, and 3+: intense cytoplasmic staining. Positive cells of SARS-CoV-2 were counted in ten fields consecutive at 20× increase, representing a total area of 1.25 mm<sup>2</sup>. RT-PCR SARS-CoV-2 test results were unknown at the time of evaluating both the cytological and the immunohistochemical studies.

### STATISTICAL ANALYSIS

The results of the cellular analysis are shown as means ± SD and percentage. The differences in the results of cell count and SARS-CoV-2 test were examined by the non-parametric Mann-Whitney test for two independent groups. *P* < 0.05 was considered

statistically significant. All of the analyses were performed using IBM.SPSS version 23.

## Results

### CLINICAL FINDINGS

Our analysis included 54 male and 46 female patients with a median age of 59 years (range, 27–93 years). Sixty-four (64%) cases were asymptomatic. Thirty-six cases (36%) showed symptoms related to SARS-CoV-2 infection, such as fever, dry cough, shortness of breath, fatigue, rhinorrhea and respiratory distress. Four (4%) patients died from COVID-19. Forty (40%) cases were negative to RT-PCR SARS-CoV-2 test. Thirty-three (33%) cases showed N and ORF1a genes positivity (positive test). Gene N or ORF1a positivity was seen in twenty-seven (27%) cases (presumptive positive test) (Gene N positive: 24; Gene ORF1a positive: 3). Tables 1 and 2, summarized the results.

### CYTOLOGICAL FINDINGS

The cytomorphological characteristics were similar for all groups. Papanicolaou smears showed squamous cells with preserved nucleus/cytoplasm ratio and there was no viral cytopathic effect, such as multinucleation, nuclear hyperchromatism, or eosinophilic nucleolus prominent. Another epithelial component was ciliated respiratory-type epithelial cells, with no evidence of viral cytopathic effect. In

**Table 1.** Clinical characteristics of people under investigation for SARS-CoV-2 infection ( $n = 100$ )

	<i>n</i>	%
Male	54	54
Female	46	46
Symptoms		
Absent	64	64
Present	36	36
RT-PCR SARS-CoV-2 test		
Negative	40	40
Positive	33	33
Presumptive positive	27	27

RT-PCR, Reverse transcription–polymerase chain reaction.

**Table 2.** RT-PCR SARS CoV-2 test results, immunohistochemical study, clinical symptoms and evolution from people under investigation for SARS-CoV-2 infection ( $n = 100$ )

	RT-PCR SARS-CoV-2 test negative (40)	RT-PCR SARS-CoV-2 test positive (33)	RT-PCR SARS-CoV-2 test presumptive positive (27)
ICC-positive	3	33	27
ICC-negative	37	0	0
Asymptomatic	28	15	21
Symptomatic	12	18	6
Alive	40	29	27
Dead	0	4	0

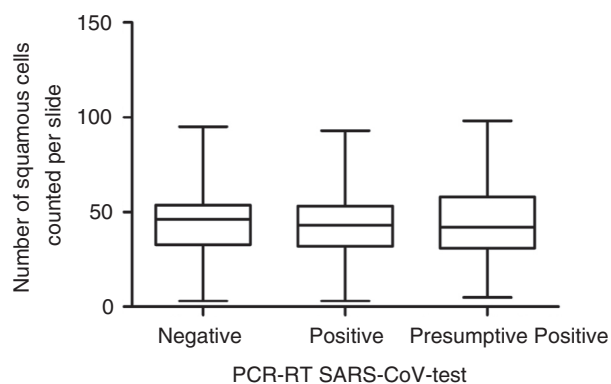
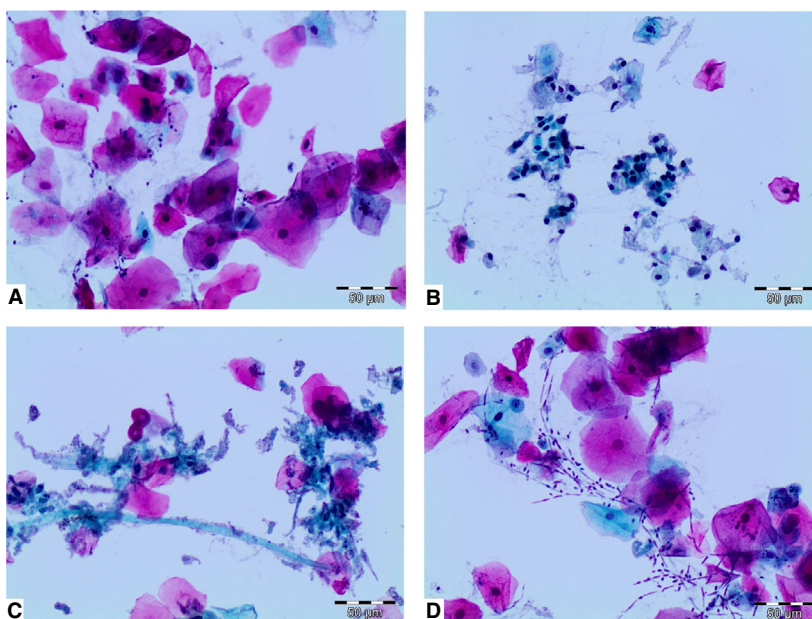
ICC, Immunocytochemistry study; RT-PCR, Reverse transcription–polymerase chain reaction.

three cytologies, fungal structures compatible with *Candida* sp. were present. (Figure 1). In 40 cytological smears from PCR-RT-SARS-CoV test negative group the number of squamous cells was  $45.08 \pm 19.34$ , and  $67 \pm 20$  ciliated respiratory-type epithelial cells. In 33 PCR-RT-SARS-CoV test positive group there were  $43.74 \pm 19.81$  squamous cells, and  $38.01 \pm 18.48$  ciliated respiratory-type epithelial cells. In 27 PCR-RT-SARS-CoV test presumptive positive group there were  $44.93 \pm 22.69$  squamous cells, and  $51.84 \pm 21.01$  ciliated respiratory-type epithelial cells. There were no differences between the groups analyzed ( $P = 0.97$ ) (Figure 2). Other cellular component present in the cytological smears were isolated lymphocytes, neutrophils and macrophages. In seven cases the material present was scarce, with cellular count between 3 to 10 squamous cells and 2 to 12 ciliated respiratory-type epithelial cells.

### IMMUNOHISTOLOGICAL FINDINGS

Immunohistological study from 37 SARSCoV-2 RT-PCR negative cases, did not show immunoreactivity for anti-SARS-CoV-2 nucleoprotein antibody. Granular cytoplasmatic positivity was observed in 3 SARS-CoV-2 RT-PCR negative cases. In 33 SARSCoV-2 RT-PCR positive cases showed granular cytoplasmatic positivity in squamous cells, and the positive cell numbers was  $50.52 \pm 19.89$ . Immunoreaction was not observed in ciliated respiratory-type cells. Similarly, macrophages and neutrophils did not show immunoreactivity (Figure 3). Immunohistological

**Figure 1.** Cytological findings in cases under investigation for SARS-CoV-2 infection from nasopharyngeal swabs. (A) Characteristic finding of squamous cells. No viral cytopathic effect was present. (B) Ciliated respiratory-type epithelial cells, with no evidence of any viral cytopathic effect. (C) Isolated squamous cell metaplasia is present. (D) *Candida* sp. pseudohyphal, and hyphal forms are seen (Papanicolaou staining DA 20×).



**Figure 2.** Squamous cells present in samples obtained from universal transport medium, processed by liquid-based cytology. Negative ( $N = 40$ ), positive ( $N = 33$ ) and presumptive positive ( $N = 27$ ) (No significant differences were observed between groups).

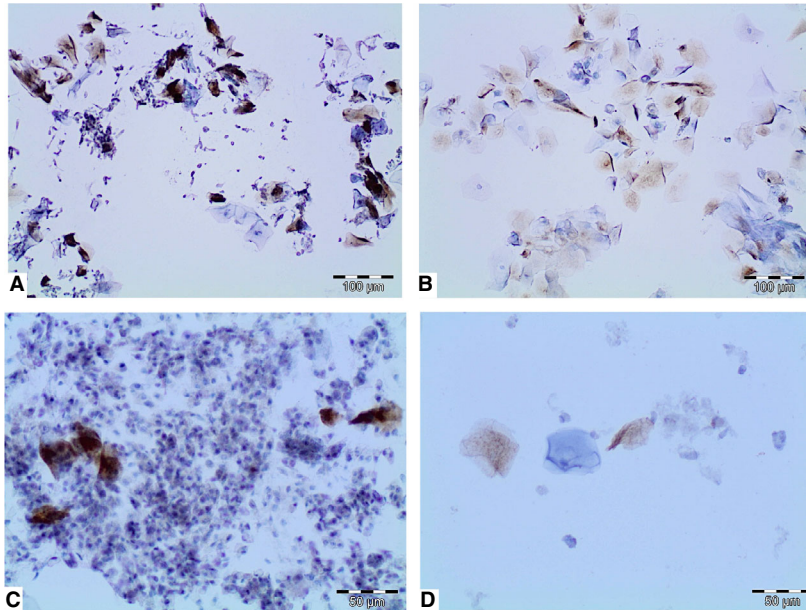
study, in 27 SARSCoV-2 RT-PCR presumptive positive cases, showed also granular cytoplasmatic reactivity, and the positive cell numbers was  $47.26 \pm 18.82$ . No difference between SARSCoV-2 RT-PCR positive and SARSCoV-2 RT-PCR presumptive positive cases was established (Figure 4). The intensity of cells in SARSCoV-2 RT-PCR presumptive positive cases were lower compared to the SARSCoV-2 RT-PCR positive cases (2+ versus 3+) (Table 3).

## Discussion

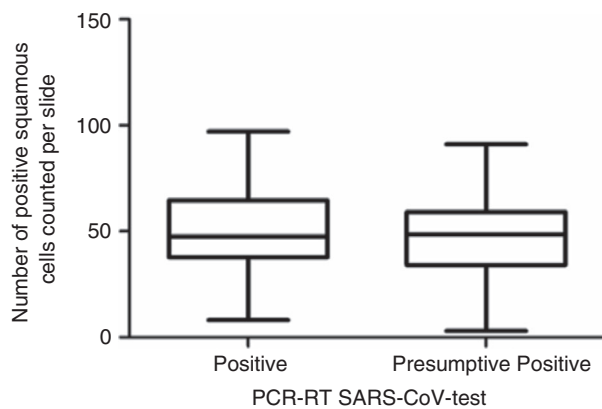
We performed a cytological and immunohistochemical study of the universal transport medium for RT-PCR

determination of SARSCoV-2 in one hundred patients admitted to our center, for SARS-CoV-2 infection investigation. Reverse transcription-polymerase chain reaction (RT-PCR) has emerged as the primary mode of diagnosis of acute infection with SARS-CoV-2,<sup>4</sup> but there is currently no gold standard for the diagnosis of COVID-19; therefore, sensitivity and specificity could not be calculated.<sup>5</sup> The diagnostic strategy recommended by the CDC to identify patients with COVID-19 is to test samples taken from the respiratory tract to assess for the presence of one or several nucleic acid targets specific to SARS-CoV-2.<sup>6</sup> A nasopharyngeal specimen is the preferred choice for SARS-CoV-2 testing.<sup>7</sup> In the present study of the viral transport medium on cases under investigation (CUI) of SARS-CoV-2 infection, variable cellular composition was evident, with predominance of squamous cells. Only in seven samples material was limited for cytological evaluation. However, in these cases with limited material for cytological evaluation, the analysis for the determination of the SARS-CoV-2 RT-PCR analysis was valid. These findings confirm that the nasopharyngeal swab is an adequate source of material for the diagnosis of COVID-19.

A finding of our study was the presence of 3 cases with a negative SARS-CoV-2 RT-PCR test, which showed immunohistochemical positivity for viral nucleoprotein. Currently, RT-PCR is the valid diagnostic method for the diagnosis of COVID-19, however different studies have shown a high rate of false negatives of RT-PCR technique.<sup>8-10</sup> This may be caused by insufficient viral material in the specimen,



**Figure 3.** Immunohistological findings in cases under investigation for SARS-CoV-2 infection from nasopharyngeal swabs. (A,B) Cytoplasmatic immunostaining in squamous cells (RT-PCR, positive). (C) Squamous cells positive, with no reactivity seen in neutrophils, cylindrical cells, or macrophages. (D) RT-PCR presumptive positive showing immunostaining in squamous cells, note that the staining is weaker (DAB staining). DA 10× and 20×.



**Figure 4.** Immunohistological positive squamous cells in cases of RT-PCR SARS-CoV-2 infection positive and presumptive positive (No significant differences was observed between groups).

laboratory error during sampling, or restrictions on sample transportation.<sup>8–10</sup> The difference with the three cases found in our series could be explained by a lack of sampling, low amount of RNA template of the sample near or below the detection limit of the reactions, mutations in the nucleic acid sequences targeted, slightly different amplification yield of the targets regions, or other factors related to the RT-PCR test.

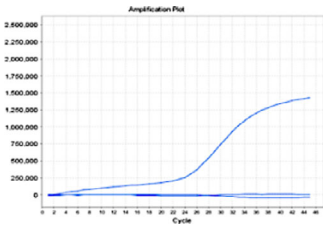
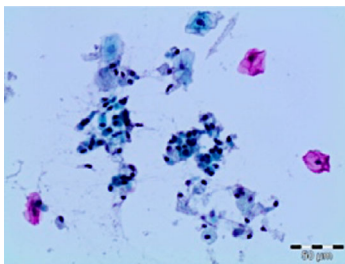
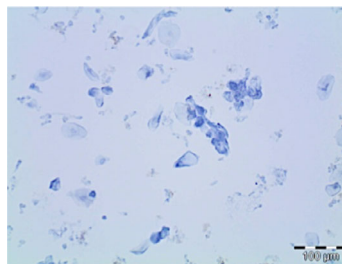
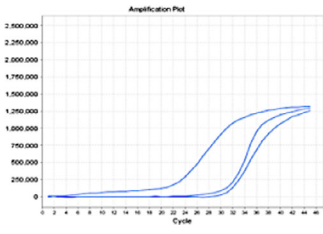
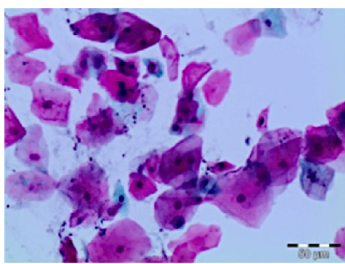
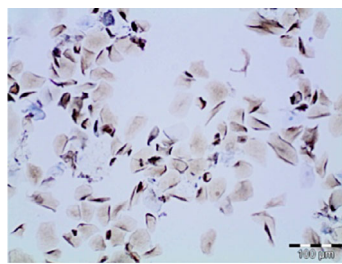
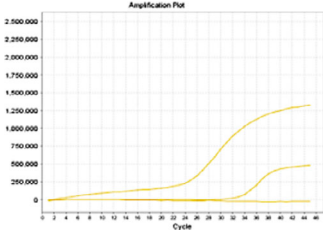
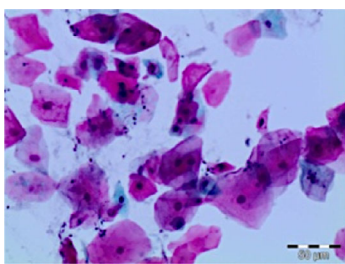
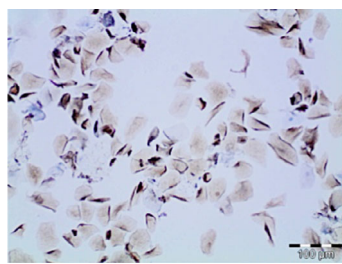
Another point of the present study is the diagnostic category of presumptive positive RT-PCR test, when one of the studied genes was positive. The possibility that these are false positive results, arising either from spurious amplification or from detection of a

closely related virus, cannot be excluded.<sup>5</sup> Another possibility is that these samples contain low levels of virus, near the limit of detection for the cobas SARS-CoV-2 tests but below the threshold of detection. However, in the 33 presumptive positive cases, cytoplasmic reactivity was demonstrated for the viral nucleoprotein SARS-CoV-2. This finding could indicate that cases classified as presumptive positives should be classified as positive.

In the present study, one of our initial approaches was to demonstrate whether there were characteristic viral cytopathic changes related to SARS-CoV-2 infection in cells analyzed from nasopharyngeal swab in universal transport medium, and whether these changes could serve as an indicator of infection. The cytological study showed that no changes were observed associated with the SARS-CoV-2 infection. This could imply that in order to demonstrate the presence of SARS-CoV-2 infection, more specific tests are required to demonstrate genetic targets using molecular biology, RT-PCR, or the demonstration of viral products by immunohistochemistry, such as nucleoproteins.

Histopathological studies on SARS-CoV-2 infection have shown involvement of different organs, being the most relevant findings at pulmonary level.<sup>11–15</sup> Non-specific findings are described in early stages, and included oedema, pneumocyte hyperplasia, focal inflammation and multinucleated giant cell formation.<sup>11</sup> In advanced stages, histopathological characteristics included diffuse alveolar damage with exudates (10–15; 7–11). However, there is no

**Table 3.** Cases under investigation for SARS-CoV-2 infection from nasopharyngeal swabs. Relation between RT-PCR, cytology and immunohistochemistry study (Papanicolaou staining and DAB,  $\times 20$  and  $\times 10$ ). [Colour figure can be viewed at [wileyonlinelibrary.com](http://wileyonlinelibrary.com)]

RT-PCR	Cytology	Immunohistochemistry
SARSCoV-2-negative, (case 10) 		
SARSCoV-2-positive, (case 50) 		
SARSCoV-2-presumptive positive (case 35) 		

RT-PCR, Reverse transcription-polymerase chain reaction.

characteristic viral cytopathic effect of SARS-CoV-2 in the different organs studied in patients with this infection.<sup>11–15</sup> In our study, no definitive viral inclusions were noted in squamous cells correlated with the immunohistochemical study.

The immunohistochemical analysis of the present study showed granular cytoplasmic positivity to SARS-CoV-2 viral nucleoprotein in squamous cells, without other cellular components showing this reactivity. This finding seems to indicate that SARS-CoV-2 would have the ability to infect squamous cells and, therefore, produce viral replication in these cells, and ACE2 receptors in the nasopharyngeal and oral

mucosa could support the infectious capacity of squamous cells.<sup>16–18</sup> The ACE2 receptor is necessary for the virus to enter the cell, through endocytosis, to release its RNA, and it uses cellular machinery to replicate and assemble more virions.<sup>17</sup> However, other studies have not demonstrated the presence of the ACE-2 receptor in the nasal region.<sup>19</sup> However, SARS-CoV-2 infection remarkably induces the expression of ACE2, as an interferon-stimulated gene, in human airway epithelial cells.<sup>20,21</sup> In addition, squamous cells in the nasopharyngeal region could serve as reservoir for SARS-CoV-2, since it has been shown that after 4 weeks, 26.3% of the samples by RT-PCR

tests remain positive for the SARS-CoV-2.<sup>8</sup> These findings suggest that SARS-CoV-2 viral replication has a relatively long period in infected patients<sup>8</sup> and it is likely that nasopharyngeal squamous cells play a role in viral maintenance. Further studies are required to establish the role of nasopharyngeal squamous cells, ACE2 receptor, and their interaction in SARS-CoV-2 infection.

In conclusion, we demonstrate that SARS-CoV-2 predominantly localizes squamous cells in patients with RT-PCR positive determination of SARS-CoV-2. SARS-CoV-2 infects the nasopharyngeal region, likely due to the presence of ACE2 receptors, which facilitates the viral replication and that facilitates the contagious state of the disease. This region is the first anatomical station infected that can allow the migration of the virus into the lower airways.

## Conflict of interest

The authors have no conflicts of interest to disclose.

## Author contributions

DP, KP: conception, design, primary acquisition and analysis of data (citology and SARS-CoV-2 ICC), drafting and critical revision of manuscript. JG: design, drafting and critical revision of manuscript. CG: primary acquisition and analysis of data (citology and ICC), contributed PCR-RT SARS-CoV-2 results. FR: integration and synthesis of relevant clinical information, revisions of manuscript.

## References

- Zhu N, Zhang D, Wang W *et al.* A novel coronavirus from patients with pneumonia in China, 2019. *N. Engl. J. Med.* 2020; **382**: 727–733.
- World Health Organization. Novel Coronavirus (2019-nCoV). Updated 3 May 2020. Available at: <https://www.who.int/emergencies/diseases/novel-coronavirus-2019>
- Patel R, Babady E, Theel ES *et al.* Report from the American Society for Microbiology COVID-19 international summit, March 23, 2020: value of diagnostic testing for SARS-CoV-2/COVID-19. *mBio* 2020; **11**: e00722–00720.
- World Health Organization. *Laboratory testing for 2019 novel coronavirus (2019-nCoV) in suspected human cases. Interim guidance.* WHO/COVID-19/laboratory/2020.5. Geneva, Switzerland: World Health Organization, 2020. Updated 27 March 2020. Available at: <https://www.who.int/publications-detail/laboratory-testing-for-2019-novel-coronavirus-in-suspected-human-cases-20200117>
- Pujadas E, Ibeh N, Hernandez MM *et al.* Comparison of SARS-CoV-2 detection from nasopharyngeal swab samples by the Roche cobas 6800 SARS-CoV-2 test and a laboratory-developed real-time RT-PCR test. *J. Med. Virol.* 2020; **92**: 1695–1698. <https://doi.org/10.1002/jmv.25988>.
- Corman VM, Landt O, Kaiser M *et al.* Detection of 2019 novel coronavirus (2019-nCoV) by real-time RT-PCR. *Euro Surveill.* 2020; **25**: 2000045. <https://doi.org/10.2807/1560-7917>.
- Cheng MP, Papenburg J, Desjardins M *et al.* Diagnostic testing for severe acute respiratory syndrome-related coronavirus-2: a narrative review. *Ann. Intern. Med.* 2020; **172**: 726–734.
- Xiao AT, Tong YX, Gao C, Zhu L, Zhang YJ, Zhang S. Dynamic profile of RT-PCR findings from 301 COVID-19 patients in Wuhan, China: a descriptive study. *J. Clin. Virol.* 2020; **127**: 104346.
- Xiao AT, Tong YX, Zhang S. False negative of RT-PCR and prolonged nucleic acid conversion in COVID-19: Rather than recurrence. *J. Med. Virol.* 2020. <https://doi.org/10.1002/jmv.25855>.
- Li Y, Yao L, Li J *et al.* Stability issues of RT-PCR testing of SARS-CoV-2 for hospitalized patients clinically diagnosed with COVID-19. *J. Med. Virol.* 2020; **92**: 903–908.
- Hanley B, Lucas SB, Youd E, Swift B, Osborn M. Autopsy in suspected COVID-19 cases. *J. Clin. Pathol.* 2020; **73**: 239–242.
- Sauter JL, Baine MK, Butnor KJ *et al.* Insights into pathogenesis of fatal COVID-19 pneumonia from histopathology with immunohistochemical and viral RNA studies. *Histopathology* 2020; **77**: 915–925. <https://doi.org/10.1111/his.14201>.
- Schaefer IM, Padera RF, Solomon IH *et al.* In situ detection of SARS-CoV-2 in lungs and airways of patients with COVID-19. *Mod. Pathol.* 2020; **33**: 2104–2114.
- Barton LM, Duval EJ, Stroberg E, Ghosh S, Mukhopadhyay S. COVID-19 autopsies, Oklahoma, USA. *Am. J. Clin. Pathol.* 2020; **153**: 725–733.
- Xu Z, Shi L, Wang Y *et al.* Pathological findings of COVID-19 associated with acute respiratory distress syndrome. *Lancet Respir. Med.* 2020; **8**: 420–422.
- Hamming I, Timens W, Bulthuis ML, Lely AT, Navis G, van Goor H. Tissue distribution of ACE2 protein, the functional receptor for SARS coronavirus. A first step in understanding SARS pathogenesis. *J. Pathol.* 2004; **203**: 631–637.
- Wiersinga WJ, Rhodes A, Cheng AC, Peacock SJ, Prescott HC. Pathophysiology, transmission, diagnosis, and treatment of coronavirus disease 2019 (COVID-19). *JAMA* 2020; **324**: 782.
- Xu H, Zhong L, Deng J *et al.* High expression of ACE2 receptor of 2019-nCoV on the epithelial cells of oral mucosa. *Int. J. Oral Sci.* 2020; **12**: 8.
- Hikmet F, Méar L, Edvinsson Å, Micke P, Uhlén M, Lindskog C. The protein expression profile of ACE2 in human tissues. *Mol. Syst. Biol.* 2020; **16**: e9610.
- Zhuang MW, Cheng Y, Zhang J *et al.* Increasing host cellular receptor-angiotensin-converting enzyme 2 expression by coronavirus may facilitate 2019-nCoV (or SARS-CoV-2) infection. *J. Med. Virol.* 2020; **92**: 2693–2701. <https://doi.org/10.1002/jmv.26139>.
- Ziegler CGK, Allon SJ, Nyquist SK *et al.* SARS-CoV-2 receptor ACE2 is an interferon-stimulated gene in human airway epithelial cells and is detected in specific cell subsets across tissues. *Cell* 2020; **181**: 1016–1035.e19.