



Contents lists available at ScienceDirect

## International Journal of Surgery Case Reports

journal homepage: [www.casereports.com](http://www.casereports.com)

## Bilateral asymmetrical hip dislocation with one side obturator intra-pelvic dislocation. Case report



Abdullah Saad Abdulfattah Abdullah\*, Ayman Abdelhady\*, Abduljabbar Alhammoud\*

Hamad Medical Corporation, Department of Orthopedic Surgery, P.O. Box 3050, Doha, Qatar

### ARTICLE INFO

#### Article history:

Received 23 November 2016  
Received in revised form 9 February 2017  
Accepted 9 February 2017  
Available online 14 February 2017

#### Keywords:

Hip dislocation  
Bilateral  
Asymmetrical hip dislocation  
Obturator intra-pelvic dislocation

### ABSTRACT

**INTRODUCTION:** Hip dislocations usually occur as a result of motor vehicle accidents and require high energy trauma. Bilateral hip dislocations are rare compared to unilateral ones. Most reported cases are asymmetrical simultaneous bilateral anterior and posterior dislocations.

**CASE PRESENTATION:** This case report describes a 32years female passenger who was involved in road traffic accident and had bilateral asymmetrical hip dislocations with one side posterior and the other side obturator intra-pelvic dislocation. Concentric reduction was achieved by closed reduction of both sides under general anesthesia but the patient required skeletal traction applied to the unstable side for three weeks.

**DISCUSSION:** Hip dislocation is considered an orthopedic emergency and should be reduced as soon as possible to decrease rate of complications. Since hip dislocation usually occurs with high energy trauma so looking for associated injuries is of paramount importance and assessing such patients should be done according to advanced trauma life support.

**CONCLUSION:** Obturator intra-pelvic hip dislocation is challenging case and can be treated by closed reduction.

© 2017 The Authors. Published by Elsevier Ltd on behalf of IJS Publishing Group Ltd. This is an open access article under the CC BY-NC-ND license (<http://creativecommons.org/licenses/by-nc-nd/4.0/>).

## 1. Introduction

In general joint dislocations are more common in male with male to female ratio of about 8:1 with highest incidence among individuals in the 20s years of age [6]. Hip dislocation accounts for 2–5% of all joint dislocations [1]. About 90% of hip dislocations are posterior while bilateral ones are very rare constituting 0.025–0.05% of all dislocations [4]. Most of reported cases are caused by road traffic accident [13]. It is very crucial not to miss associated injuries such as acetabular, femoral head or shaft fractures [14–16]. We present case of 32years female passenger who was involved in road traffic accident and had bilateral asymmetrical hip dislocations with one side posterior and the other side obturator intra-pelvic dislocation, case presented according to SCARE Guidelines [25].

## 2. Case presentation

A 32 year old female previously healthy, front seat passenger was ejected from the vehicle during a road traffic accident, She was intoxicated with alcohol and was not wearing a seat belt. The patient was brought to the trauma room of Hamad General Hospital (HGH) by ambulance. She was complaining of severe pelvic pain and inability to feel her lower limbs. Physical assessment showed that she was hemodynamically stable with Glasgow Coma Score of 15. There were facial lacerated wounds and multiple burns in the lower limbs, left upper limb and left side of the chest. Right lower limb was flexed, internally rotated and adducted. The left lower limb was flexed, externally rotated and abducted. There were no distal neurovascular deficit.

Radiological assessment revealed right hip posterior dislocation. The left proximal femur (head, neck and greater trochanter) was dislocated inside the pelvis through the obturator foramen with fracture of left superior and inferior pubic rami (Fig. 1)

The patient underwent closed reduction of both hips in supine position under general anesthesia in the operating theatre. The left hip was reduced in two steps, first by traction in the line of deformity with some more flexion which brought the hip out of the pelvis and became as a posterior dislocation. Second step was to reduce the posterior dislocation by traction in the line of deformity, with

\* Corresponding authors.

E-mail addresses: [abdullahsaad21@gmail.com](mailto:abdullahsaad21@gmail.com) (A.S. Abdulfattah Abdullah), [Ayman2882@hotmail.com](mailto:Ayman2882@hotmail.com) (A. Abdelhady), [aabdulwahed@hamad.qa](mailto:aabdulwahed@hamad.qa) (A. Alhammoud).

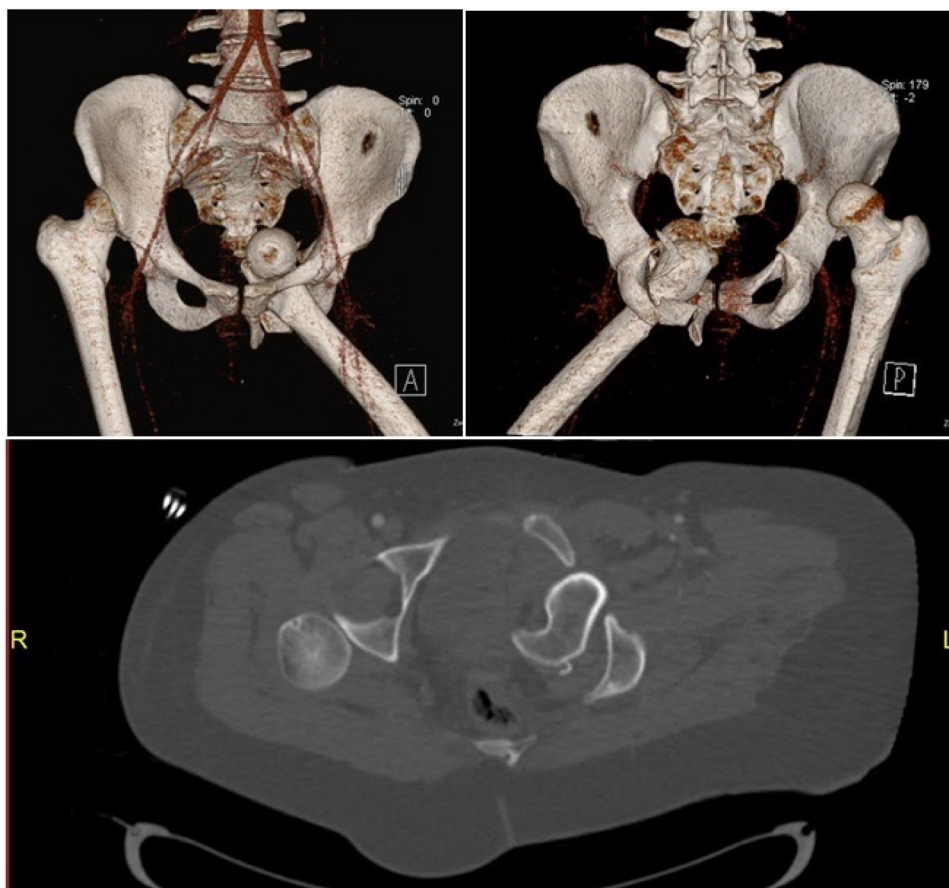


Fig. 1. pre-reduction 3D reconstructive CT Images and axial cuts.

adduction and internal rotation. The right hip was reduced with the same previous technique.

Post reduction the right hip was stable on examination, but the left hip was unstable posteriorly in 90° flexion (although no fracture detected in left acetabulum) plus internal rotation. Thus skeletal traction was applied to the left proximal tibia.

Post reduction pelvic radiograph and computerized tomography (CT scan) of the pelvis showed both hips were concentrically reduced with no intra-articular fragments (Fig. 2).

### 2.1. Hospital course

The Patient was kept in bed rest for three weeks with abduction pillow then traction was removed and physiotherapy started before she was transferred to burn unit in another hospital for management of friction burn and stayed there for another 3 weeks mobilized on a wheel chair after which she was discharged and travelled outside the country and lost followup.

### 3. Discussion

In general joint dislocations are more common in male (81%) compared to female (19%) and are commonest in the 21–30 years age group, average age 32.9 years, range 11–65 years [24]. Hip dislocations account for 2–5% of all joint dislocations [1]. Bilateral dislocations of the hip are very rare constituting 1.25% of all hip dislocations [2] and 0.025–0.05% of all joint dislocations [4]. Hip dislocations are 93% posterior with 74.4% associated with fractures mostly hip fractures [7]. Hip joint is very congruent and stable joint

therefore it requires a traction force of more than 400 N for separation [5]. So that hip dislocations whether pure ones or with fracture mostly occur with high energy trauma. Most of reported cases are caused by road traffic accident [13]. Most hip dislocations occur as dashboard mechanism [3]. In this case, our patient sustained asymmetrical bilateral simultaneous hip dislocation with right hip was posteriorly dislocated and left hip was dislocated intra-pelvic through the obturator foramen and was associated with superior and inferior pubic rami fractures.

Buckwalter J et al. reviewed the literatures and found 104 bilateral hip dislocations, 72 in english and 32 in non english literatures, 44 cases were asymmetrical dislocations [24]. Three cases of bilateral obturator hip dislocation, each was reported [21–23]. To the best of our knowledge there were no previously reported bilateral hip dislocations, with obturator intrapelvic dislocation on one side in the English literature.

Hip dislocation should be reduced as soon as possible under general anesthesia in the operating theatre or in the emergency under sedation. In this patient closed reduction was done under general anesthesia in the operating theatre in less than 6 h from the accident. It was reported that avascular necrosis of femoral head is increasing significantly with delayed reduction of hip dislocation from 4.8% if reduced within 6 h to 58.8% if delayed more than 6 h [8]. After hip reduction patient should undergo plain AP radiograph and Computerized Tomography scan of the pelvis with at least 2 mm cuts to detect any intra-articular loose bodies and to ensure concentric reduction [11] and also to detect any associated fractures. In our case the patient had post-reduction Computerized Tomography with 1.5 mm slice thickness. The patient had to

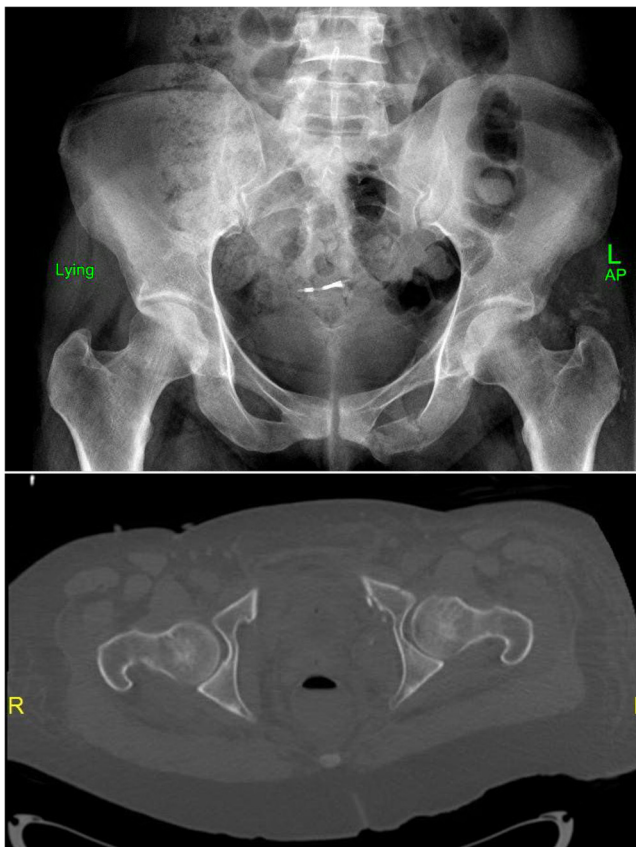


Fig. 2. post-reduction AP radiograph and axial CT scan Cut.

be assessed for associated fractures including acetabular fracture, femoral head fracture [14] and femoral shaft fracture [15,16] which had been frequently reported in the literature. The recommended period of non weight bearing mobilization should be limited to 6–8 weeks if there are no other injuries that restrict ambulation [17]. Others recommended bed rest for short period of few days followed by wheel chair mobilization [18]. Our patient underwent post-reduction rehabilitation in the form of bed rest and skeletal traction of the unstable side only for 3 weeks followed by wheel chair mobilization for another 3 weeks.

#### 4. Conclusion

Bilateral hip dislocation is very rare and usually results from high energy trauma mostly motor vehicle collisions. Hip dislocation is an orthopedic emergency and requires prompt accurate diagnosis and proper reduction without delay. Complex dislocation might better be reduced in the theatre. Management and rehabilitation are influenced by the character of the dislocation and associated injuries.

#### Conflicts of interest

The authors have no conflict of interest to declare.

#### Funding

No sponsors or sources of funding.

#### Ethical approval

Informed consent was taken from the patient for publication of the case and related data. The local research committee at Hamad Medical Corporation's Medical Research Center granted final approval.

#### Consent

Informed consent was taken from the patient for publication of the case and related data.

#### Author contribution

Dr. Abdullah Abdullah – resident orthopedic involved in writing the manuscript and first author.

Dr. Ayman Abdelhady – consultant orthopedic and the primary physician of the patient and data collection.

Dr. Abduljabbar Alhammoud – secondary contributor to data collection and in writing the manuscript.

All of the authors stated above have read and approved this manuscript.

#### Guarantor

Abduljabbar Alhammoud

#### Acknowledgements

We want to acknowledge the Orthopedic Department in Hamad General Hospital and orthopedic team who was involved in the management of this case and appreciate their priceless effort.

Dr. Saleh Al Yazeedi.

Dr. Ghalib O. Ahmed.

Dr. Yasir Ahmed Jameel.

Dr. Adel Omar El Feghah.

#### References

- [1] H.C. Epstein, Traumatic dislocations of the hip, *Clin. Orthop. Relat. Res.* 92 (1973) 116–142.
- [2] V.P. Thompson, H.C. Epstein, Traumatic dislocation of the hip: a survey of 204 cases covering a period of 21 years, *J. Bone Joint Surg.* 33A (1951) 746–778.
- [3] R.V. Funsten, P. Kinser, C.J. Frankel, Dashboard dislocation of the hip, *J. Bone Joint Surg.* 20 (1938) 124–130.
- [4] A. Phillips, A. Konchwalla, The pathologic features and mechanism of traumatic dislocation of the hip, *Clin. Orthop. Relat. Res.* 377 (2000) 7–10.
- [5] K.J. Fairbairn, M.E. Mulligan, M.D. Murphey, et al., Gas bubbles in the hip joint on CT: An indication of recent dislocation, *Am. J. Roentgenol.* 164 (1995) 931–934.
- [6] E.O. Edomwonyi, O.C. Nwokike, J.E. Onuminya, Management of traumatic joint dislocations in irrua, *Surg. Sci.* 6 (2015) 116–122.
- [7] Luciana Cascão Lima, Robson Alves do Nascimento, Victor Monte Tenório de Almeida, Fernando Antônio Mendes Facanha filho, Epidemiology of traumatic hip dislocation in patients treated in Ceará, Brazil, *Acta Ortop. Bras. Online* 22 (3) (2014) 151–154, cited 2015-03-17.
- [8] K. Hougaard, P.B. Thomsen, Coxarthrosis following traumatic posterior dislocation of the hip, *J. Bone Joint Surg. Am.* 69 (1987) 679–683.
- [9] K. Karthik, S. Sundararajan, J. Dheenadhayalan, S. Rajasekaran, Incongruent reduction following post-traumatic hip dislocations as an indicator of intra-articular loose bodies: a prospective study of 117 dislocations, *Indian J. Orthop.* 45 (1) (2011) 33–38, <http://dx.doi.org/10.4103/0019-5413.73650>.
- [10] S. Sanders, N. Tejwani, K.A. Egol, Traumatic hip dislocation—a review, *Bull. NYU Hosp. Jt. Dis.* 68 (2) (2010) 91–96.
- [11] A.A. Martinez, F. Gracia, J. Rodrigo, Asymmetrical bilateral traumatic hip dislocation with ipsilateral acetabular fracture, *J. Orthop. Sci.* 5 (3) (2000) 307–309.
- [12] M. Maqsood, A.P. Walker, Asymmetrical bilateral traumatic hip dislocation with ipsilateral fracture of the femoral shaft, *Injury* 27 (September (7)) (1996) 521–522.
- [13] A.O. Shannak, Bilateral traumatic dislocation of the hip with ipsilateral femoral fracture, *Clin. Orthop.* 215 (1985) 126–129.

- [17] V. Sahin, E.S. Karakas, S. Aksu, et al., Traumatic dislocation and fracture-dislocation of the hip: a long-term follow-up study, *J. Trauma-Injury Infect. Crit. Care* 54 (3) (2003) 520–529.
- [18] J.C. Tornetta III, Fractures and Dislocations of the Hip, in: R.W. Bucholz, J.D. Heckman (Eds.), *Fractures in adults*, Lippincott/Williams and Wilkins, 2002, pp. 1547–1578.
- [21] A. Gibbs, Bilateral obturator dislocation of the hip joint, *Injury* 12 (November (3)) (1980) 250–251.
- [22] S. Endo, S. Hoshi, H. Takayama, E. Kan, Traumatic bilateral obturator dislocation of the hip joint, *Injury* 22 (May (3)) (1991) 232–233.
- [23] A.1 Sultan, T.A. Dar, M.I. Wani, M.M. Wani, S. Shafi, Bilateral simultaneous anterior obturator dislocation of the hip by an unusual mechanism – a case report, *Ulus Travma Acil Cerrahi Derg.* 18 (September (5)) (2012) 455–457, <http://dx.doi.org/10.5505/tjtes.2012.77012>.
- [24] J. Buckwalter, B. Westerlind, M. Karam, Asymmetric bilateral hip dislocations: a case report and historical review of the literature, *Iowa Orthop. J.* 35 (2015) 70–91.
- [25] R.A. Agha, A.J. Fowler, A. Saetta, I. Barai, S. Rajmohan, Orgill DP and the SCARE group: the SCARE statement: consensus-based surgical case report guidelines, *Int. J. Surg.* 34 (2016) 180–186.

#### Open Access

This article is published Open Access at [sciedirect.com](http://sciedirect.com). It is distributed under the [IJSCR Supplemental terms and conditions](#), which permits unrestricted non commercial use, distribution, and reproduction in any medium, provided the original authors and source are credited.