

HHV-6 Encephalitis After Chimeric Antigen Receptor T-cell Therapy (CAR-T): 2 Case Reports and a Brief Review of the Literature

Melanie T. Rebechi,^{1,a} Jacqueline T. Bork,^{1,2} and David J. Riedel^{1,2}

¹University of Maryland School of Medicine, Baltimore Maryland, USA, and ²Institute of Human Virology, University of Maryland School of Medicine, Baltimore, Maryland, USA

^aPresent affiliation: The Ohio State University Wexner Medical Center, Columbus, Ohio, USA

Human herpesvirus 6 (HHV-6) reactivation can occur in patients who are highly immunosuppressed, including those who have undergone hematopoietic stem cell transplantation (HSCT). HHV-6 encephalitis is a severe manifestation that is well described in the HSCT population. Chimeric antigen receptor T-cell (CAR-T) therapy is a novel cancer-directed immunotherapy that results in severe immunosuppression. Patients undergoing CAR-T therapy may be at risk for HHV-6 encephalitis, which can be difficult to distinguish from a common adverse effect of CAR-T therapy, neurotoxicity. Herein, we describe 2 patients diagnosed with HHV-6 encephalitis after CAR-T therapy and discuss the diagnostic approach and differential diagnosis for altered mental status after CAR-T therapy. Diagnosing HHV-6 encephalitis can be difficult in this patient population as altered mental status is common after CAR-T therapy and may be attributed to CAR-T-associated neurotoxicity.

Keywords. CAR-T; chimeric antigen receptor T-cell therapy; HHV-6 encephalitis; human herpesvirus 6.

Primary human herpesvirus-6 (HHV-6) infection usually occurs in the first 3 years of life as a mild illness with self-limiting fever, diarrhea, and rash. Like all herpesviruses, HHV-6 establishes lifelong latency [1]. HHV-6 latency has been established in the monocyte/macrophage cell population, bone marrow progenitor cells, and T cells. Latency of HHV-6B has also been established in astrocytes, while latency of HHV-6A has been demonstrated in oligodendrocytes. Additionally, chromosomally integrated HHV-6 has been reported, and integration into gametes can result in the inheritance of

HHV-6. Reactivation of latent HHV-6 can occur during immunosuppression, such as hematopoietic stem cell transplantation (HSCT), critical illness, and solid organ transplant [2]. HHV-6 reactivation is common after HSCT, occurring in 30%–70% of patients [3–5], typically 2–4 weeks following HSCT [3]. Most patients with HHV-6 reactivation are asymptomatic; however, a small number may develop encephalitis. In 1 study of 1344 allogeneic HSCT patients, the incidence of HHV-6 encephalitis was 1.4% [6]. In another prospective study of 230 allogeneic HSCT patients, 7 patients (3%) developed HHV-6 encephalitis by day 70 following transplantation [7].

In the HSCT population, pretransplant risk factors for HHV-6 reactivation include younger age, male sex [3, 8], and use of unrelated human leukocyte antigen mismatched donors [7–11], umbilical cord blood donors [6, 7, 10–13], and certain monoclonal antibodies [14] or corticosteroids [3, 8]. HHV-6 reactivation after HSCT is also associated with grade 2–4 graft-versus-host disease [2, 3, 15–23], cytomegalovirus (CMV) reactivation [2, 24, 25], and bone marrow suppression [3, 4, 9, 26–30].

HHV-6 encephalitis following HSCT usually presents 2 to 6 weeks after HSCT [31–37]. Presentation typically involves headache and acute confusion, followed by anterograde amnesia [31, 33]; fever is uncommon [31, 33]. Both overt and subclinical seizures are common, occurring in 40%–70% of patients [31–33, 35, 36, 38]. Typical magnetic resonance imaging (MRI) abnormalities include T2/FLAIR/DWI hyperintensities in the medial temporal lobes, especially the amygdala and the hippocampus [33, 35, 36, 39]. The clinical features and imaging findings are often referred to as post-transplant acute limbic encephalitis (PALE) [32, 33]. CSF studies are often only mildly abnormal. In 1 series, the median (range) white blood cell count in the CSF was 5 (1–41)/mcl, the median protein (range) was 48 (19–189) mg/dL, and the glucose concentration was normal [33]. Similar findings were reported in another case series [31].

HSCT patients with HHV-6 encephalitis have variable outcomes, ranging from complete recovery with no residual neurologic deficits to permanent disability and death [26, 32–34, 40]. In a review of 44 cases, 25% had a progressive course and died within 4 weeks, 19% improved but with residual neurologic deficits, and 43% had a full recovery [36]. Studies evaluating long-term outcomes are limited, but in 1 review of 121 patients, 57% had persistent neuropsychological dysfunction, most commonly memory impairment, at a median follow-up of 4.5 years [41].

Chimeric antigen receptor T-cell (CAR-T) therapy is a novel cancer-directed immunotherapy developed for the treatment of chemotherapy-resistant or refractory hematologic malignancies. Infectious complications following CAR-T therapy

Received 29 May 2021; editorial decision 8 September 2021; accepted 22 September 2021.

Correspondence: Melanie T. Rebechi, MD, The Ohio State University Wexner Medical Center, 410 W. 10th Ave, Columbus, OH 43210 (melanie.rebechi@osumc.edu).

Open Forum Infectious Diseases® 2021

© The Author(s) 2021. Published by Oxford University Press on behalf of Infectious Diseases Society of America. This is an Open Access article distributed under the terms of the Creative Commons Attribution-NonCommercial-NoDerivs licence (<https://creativecommons.org/licenses/by-nc-nd/4.0/>), which permits non-commercial reproduction and distribution of the work, in any medium, provided the original work is not altered or transformed in any way, and that the work is properly cited. For commercial re-use, please contact journals.permissions@oup.com <https://doi.org/10.1093/ofid/ofab470>

Table 1. Demographics and Clinical Characteristics of 2 Patients With HHV-6 Encephalitis Following CAR-T Therapy

Case	1	2
Age, y	69	57
Sex	Male	Male
Cancer	Relapsed DLBCL	Refractory DLBCL transformed from follicular lymphoma
Prior therapy		2 lines of chemotherapy + autologous SCT
CAR-T conditioning regimen	Fludarabine/cyclophosphamide	Fludarabine/cyclophosphamide
CAR-T neurotoxicity (d)	Present (4)	Present (2)
Immunosuppressants (d)	Tocilizumab 560 mg (4, 5) dexamethasone 10 mg q6h (9–11)	Tocilizumab 560 mg (2, 3) solumedrol 1 g, (8–10, 26–28) siltuximab 800 mg (8)
Onset of symptoms after CAR-T, d	29	6
Presenting signs/symptoms	Fever, altered mental status	Difficulty concentrating, slowed thought process, stuttering, repetitive speech
LP, d	31	33
CSF WBC, cells/mcL	50 (53% lymphs, 32% monos, 1% polys, 1% basos)	2 (89% lymphs, 10% monos, 1% polys)
CSF RBC, cells/mcL	570	0
CSF protein, mg/dL	222	167
CSF glucose, mg/dL	43	34
HHV-6B DNA in CSF, copies/mL ^a	1460	2910
HHV-6B in PB	Not detected	Detected, not quantified
MRI findings	Mild bilateral areas of T2/FLAIR increased signal and mild restricted diffusion within bilateral hippocampi	Mild diffuse FLAIR hyperintensity in the periventricular white matter and brainstem
EEG results	Mild to moderate generalized slowing, no clear interictal epileptiform discharges	Rare generalized discharges with triphasic morphology, no seizures
Treatment (drug, dose, duration)	Ganciclovir 5 mg/kg q12 h for 7 d, valganciclovir 900 q12 h for 27 d	Ganciclovir 1.25 mg/kg daily (renally dosed) for 26 d
Outcome (d)	Mild short-term memory difficulty; no focal deficits (50)	Persistent cognitive deficits (55)

Abbreviations: CAR-T, chimeric antigen receptor T-cell therapy; CSF, cerebrospinal fluid; DLBCL, diffuse large B-cell lymphoma; EEG, electroencephalogram; HHV-6B, human herpesvirus 6; LP, lumbar puncture; MRI, magnetic resonance imaging; PB, peripheral blood; PCR, polymerase chain reaction; SCT, stem cell transplantation; T2/FLAIR, T2-weighted fluid attenuated inversion recovery; RBC, red blood cells; WBC, white blood cells.

^aHHV-6B PCR testing was performed by ARUP Laboratories. The quantitative range of this assay is 3.0–6.0 log copies/mL (1000–999 000 copies/mL).

are common. CAR-T therapy is often given to patients with hematologic malignancies who are already heavily pretreated and significantly immunosuppressed. Adding to infection risk, lymphocyte-depleting chemotherapy is given before CAR-T infusion, and anti-interleukin (IL)-6 or IL-6 receptor monoclonal antibodies and high-dose corticosteroids are frequently used for management of cytokine release syndrome (CRS) or neurotoxicity. Reported infectious complications following CAR-T include bacteremias, viral infections (eg, CMV viremia), and invasive fungal infections [42]. HHV-6 encephalitis has now been reported in 3 patients following CAR-T therapy [43, 44]; these patients share similar risk factors to HSCT patients. Herein, we describe 2 cases of HHV6 encephalitis following CAR-T therapy (details in Table 1) and review the differential diagnosis, diagnostic approach, and treatment challenges.

CASE PRESENTATION

Case 1

A 69-year-old man underwent CAR-T infusion (day 0) for relapsed diffuse large B-cell lymphoma (DLBCL). His course was complicated by grade 2 CRS requiring tocilizumab on days 4 and 5 and grade 3 neurotoxicity on day 9 requiring

high-dose dexamethasone. He was discharged on day 12. On day 29, he was febrile to 39.3°C and was noted to have altered mental status (AMS) and difficulty speaking. His mental status worsened over the next 2 days, and he was only oriented to person but not place or time. He inconsistently followed commands but denied headache. MRI of the brain revealed no acute abnormality. On day 31, mental status worsened, and a lumbar puncture (LP) was performed. On day 32, HHV-6 was detected by polymerase chain reaction (PCR) in the cerebrospinal fluid (CSF). Ganciclovir was initiated at 5 mg/kg q12h. Repeat MRI on day 33 revealed mild bilateral symmetric areas of T2/FLAIR increased signal and mild restricted diffusion within bilateral hippocampi (Figure 1). On day 35, he was able to answer questions but was confabulating. On day 36, his mental status improved slightly, and he was oriented to person and place but not time. He was slow to respond and confused but no longer confabulating. His mental status continued to improve slowly. On day 43, ganciclovir was changed to valganciclovir 900 mg orally twice daily, and he was discharged to outpatient cognitive rehabilitation. He was seen in clinic on day 50, where he reported feeling well with some short-term memory difficulty but no focal deficits.

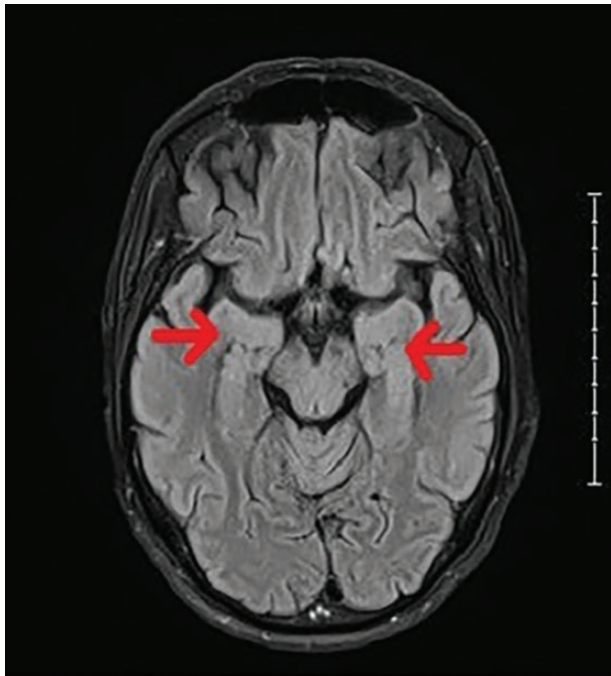


Figure 1. Patient 1 MRI with mild bilateral symmetric areas of T2/FLAIR increased signal within bilateral hippocampi. Abbreviations: MRI, magnetic resonance imaging; T2/FLAIR, T2-weighted fluid attenuated inversion recovery.

Case 2

A 57-year-old man underwent CAR-T infusion (day 0) for refractory DLBCL transformed from follicular lymphoma. His course was complicated by CRS requiring tocilizumab on days 2 and 3. Bowel incontinence was noted on day 4. On day 6, he began to have difficulty concentrating, slowed thought process, stuttering, and repeating himself. On day 7, he was more confused, anxious/agitated, and hypothermic. MRI of the brain revealed a new 12-mm inferior left cerebellar hemorrhage. Steroids were initiated for presumed CAR-T neurotoxicity. On day 8, he was sedated and intubated. By day 13, he was following commands off sedation and was extubated on day 15. On day 21, he was answering questions appropriately but perseverating. MRI of the brain revealed no evidence of intracerebral infectious process. He continued to be intermittently agitated, somnolent, and confused. On day 25, he was more alert and interactive but with slowed and repetitive responses and new emotional lability. Repeat brain MRI was stable with no abnormalities. On day 27, he was delirious, and his mental status continued to decline over the next few days. On day 32, repeat MRI brain showed mild diffuse FLAIR hyperintensity in the periventricular white matter and brainstem, consistent with leukoencephalopathy (Figure 2). LP was performed on day 33, and HHV-6 from the CSF was detected by PCR on day 39 (JC virus PCR was negative). Ganciclovir was initiated at 1.25 mg/kg (reduced for poor renal function). After starting ganciclovir, he became more alert and was now oriented to self and place.

A repeat LP was done on day 47 that showed that HHV-6 levels in the CSF had decreased from 3000 to 1200 copies. He remained confused for several days. On day 52, he had confused, tangential speech. On day 54, he was slightly dysarthric with slowed speech, but his cognition was not significantly impaired. On day 55, HHV-6 was still detectable in the CSF but not quantifiable. Ganciclovir was discontinued at that time.

DISCUSSION

Challenges in Diagnosis

HHV-6 is a common cause of infectious encephalitis after HSCT and is an important new consideration for patients undergoing CAR-T therapy. Given the similarities in severe immunosuppression in patients receiving CAR-T therapy, HHV-6 encephalitis after CAR-T therapy must be included in the differential diagnosis of altered mental status. However, making a diagnosis of HHV6 encephalitis in this setting may be quite challenging.

Neurotoxicity is common after CAR-T therapy [45–47]. Neurotoxicity after CAR-T cell infusion is defined by a syndrome known as immune effector cell–associated neurotoxicity syndrome (ICANS) [48]. ASTCT defines ICANS as a disorder characterized by a pathologic process involving the central nervous system following any immune therapy that results in the activation or engagement of endogenous or infused T cells and/or other immune effector cells. Symptoms or signs can be progressive and may include aphasia, altered level of consciousness, impairment of cognitive skills, motor weakness, seizures, and cerebral edema.

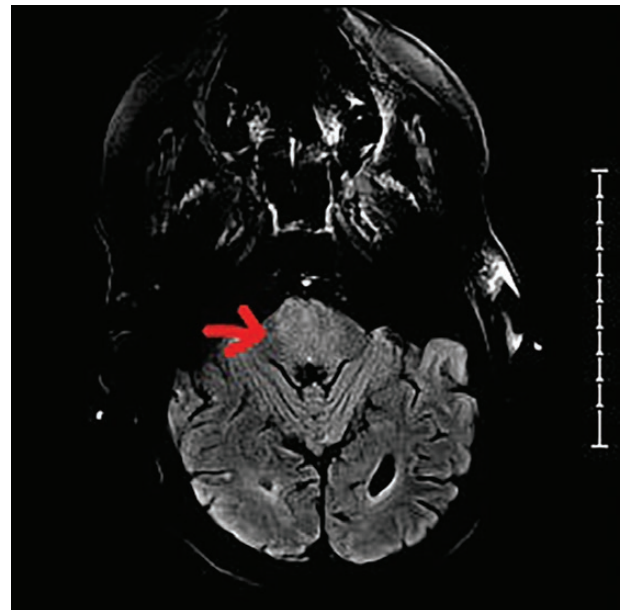


Figure 2. Patient 2 MRI with mild diffuse FLAIR hyperintensity in the periventricular white matter and brainstem. Abbreviations: FLAIR, ; MRI, magnetic resonance imaging.

ICANS grade is determined by the most severe event (encephalopathy scoring, level of consciousness, seizure, motor findings, raised intracranial pressure/cerebral edema) not attributable to any other cause. Patients receiving CAR-T therapy often have a severe net state of immunosuppression that includes cytopenias (lymphopenia, neutropenia) and hypogammaglobulinemia. There is significant overlap in the signs and symptoms associated with neurotoxicity and those associated with HHV-6 encephalitis after HSCT, the most similar patient population available for comparison. A comparative analysis between CAR-T-associated neurotoxicity and HHV-6 encephalitis is provided in Table 2. It is important to note that not all findings are present in every patient, and they are not all required for diagnosis.

An LP with PCR evaluation of CSF for HHV-6 is often performed on all HSCT patients presenting with confusion or delirium. Because confusion and delirium are common after CAR-T therapy due to high incidence of neurotoxicity, recommendations for which patients should be tested for HHV-6 encephalitis after CAR-T therapy are unclear. Therefore, we propose a low threshold for consideration of LP in patients presenting with AMS after CAR-T therapy, especially in patients who fail to improve after appropriate treatment of CAR-T-associated neurotoxicity or in patients who initially improve and then decline again.

Diagnosis of HHV-6 encephalitis in HSCT patients involves PCR testing of CSF. HHV-6 can be detected in the CSF of asymptomatic hematologic malignancy patients, so detection alone is not specific for disease [49]. Similarly, while detection of HHV-6 in the peripheral blood indicates reactivation, it is not specific for encephalitis, as most patients with reactivation do not develop encephalitis. MRI can be helpful as abnormalities are seen in most patients, typically T2/FLAIR/DWI hyperintensities in the medial temporal lobes, especially the amygdala and the hippocampus [33, 35, 36, 39]. These changes were found in case 1,

but not in case 2. Lastly, EEG monitoring is recommended in patients with suspected or confirmed HHV-6 encephalitis, as seizures may be subclinical, and testing would guide treatment decisions on the use of antiepileptics.

Other infectious and noninfectious causes should be considered in the differential diagnosis of AMS after CAR-T therapy. Other infectious etiologies to consider include bacterial and fungal CNS infections, as well as other viral CNS infections such as EBV, HSV, CMV, VZV, and JCV. Sepsis from non-CNS infections can also cause delirium. Noninfectious causes to consider include medication effect, electrolyte derangements, acidosis, renal failure, and hypoxia.

Challenges in Treatment

There is currently no Food and Drug Administration–approved drug for the treatment of HHV-6 infection or reactivation in HSCT patients; however, antivirals with activity against CMV (eg, ganciclovir and foscarnet) are commonly used in clinical practice. Cidofovir also has in vitro activity against HHV-6 but is less used due to nephrotoxicity. Current recommendations include using either foscarnet or ganciclovir in HSCT patients with HHV-6 encephalitis [50–53].

There are no clear definitions for response to therapy, and as such response rates are difficult to ascertain. However, studies have shown an association between antiviral therapy and reduction of viral load in CSF and serum [37]. Currently no data exist establishing clear superior response rates to either foscarnet or ganciclovir in HSCT patients with HHV-6 encephalitis. One study showed that receiving foscarnet at any point was beneficial, although a single-agent comparison between foscarnet and ganciclovir did not show a significant difference [41]. In 1 retrospective study including 145 patients, full-dose foscarnet or full-dose ganciclovir was associated with better neurologic response rates compared with lower-dose therapy [54]. The

Table 2. Differentiation and Overlap of CAR-T Related Neurotoxicity and HHV-6 Encephalitis After HSCT or CAR-T Therapy

	Neurotoxicity After CAR-T therapy	HHV-6 Encephalitis
Clinical presentation	Tremor, dysphagia, expressive aphasia, impaired attention, apraxia, and lethargy	Headache, confusion or delirium; progresses to anterograde then retrograde amnesia
Timing	Very early (usually within first 3–10 d)	Typically within the first 21 d
Progression	Rapidly over hours to days	More slowly, over several days
Associated symptoms	Cytokine release syndrome	Fever is uncommon
Seizures	Less common	Very common
CSF findings	Often normal, may have mildly elevated protein	Mildly abnormal (minimal pleocytosis, slightly elevated protein, normal glucose)
CSF HHV-6	PCR negative	PCR positive
EEG abnormalities	Diffuse slowing	Epileptiform activity
Imaging findings (MRI)	Usually normal, although vasogenic edema, leptomeningeal enhancement, and microhemorrhages	T2/FLAIR/DWI hyperintensities in the medial temporal lobes, especially the amygdala and the hippocampus
Treatment	Corticosteroids and/or anti-IL-6 monoclonal antibodies	Antivirals (ganciclovir, foscarnet, cidofovir)
Outcomes	Highly variable, ranges from complete recovery to significant residual disability and death	Highly variable, ranges from complete recovery to disability and death; majority recover

Abbreviations: CAR-T, chimeric antigen receptor T-cell therapy; CSF, cerebrospinal fluid; EEG, electroencephalogram; HHV-6B, human herpesvirus 6; IL-6, interleukin-6; MRI, magnetic resonance imaging; PCR, polymerase chain reaction; T2/FLAIR/DWI, T2-weighted fluid attenuated inversion recovery/diffusion-weighted imaging.

rate of residual neurologic deficit and rate of death were not significantly different between those who received foscarnet vs ganciclovir.

Currently there are no studies determining how best to monitor response to therapy, when to consider switching to alternative therapy, or the appropriate duration of antiviral therapy. Therapy can be prolonged if persistence of virus in the CSF is detected, although there are no clear recommendations for repeat testing of HHV-6 in CSF. CSF HHV-6 viral load declines may be delayed compared with peripheral blood [37]. Repeat LP at day 21 may be a reasonable approach. If viral copies are not reduced, changing therapies is recommended, as there may be a possibility of drug resistance. Antiviral therapy may also be switched as a result of drug-associated toxicity.

CONCLUSIONS

HHV-6 encephalitis should be included in the differential diagnosis for AMS after CAR-T therapy. Diagnosing HHV-6 encephalitis can be difficult in this patient population as AMS is common after CAR-T therapy and is usually attributed to CAR-T-associated neurotoxicity. HHV-6 encephalitis following CAR-T-associated neurotoxicity should also be considered as treatment of CAR-T-associated neurotoxicity includes high-dose steroids and other immunomodulatory agents, which have been associated with HHV-6 encephalitis in HSCT patients. HHV-6 encephalitis should be considered, especially in patients who fail to respond to management of CAR-T neurotoxicity or who respond initially and then worsen. More studies are needed to describe the incidence and presentation of HHV-6 encephalitis in this patient population, as well as optimal treatment strategies and methods to assess response to therapy.

Acknowledgments

Financial support. Not applicable.

Potential conflicts of interest. All authors: no reported conflicts of interest. All authors have submitted the ICMJE Form for Disclosure of Potential Conflicts of Interest. Conflicts that the editors consider relevant to the content of the manuscript have been disclosed.

Author contributions. M.T.R. wrote the first draft; J.T.B. and D.J.R. provided clinical care for the patients and revised the manuscript; all authors provided final approval.

Patient consent. This study does not include factors necessitating patient consent

References

1. Pantry SN, Medveczky PG. Latency, integration, and reactivation of human herpesvirus-6. *Viruses* **2017**; *9*: 194.
2. Zerr DM, Boeckh M, Delaney C, et al. HHV-6 reactivation and associated sequelae after hematopoietic cell transplantation. *Biol Blood Marrow Transplant* **2012**; *18*:1700–8.
3. Zerr DM, Corey L, Kim HW, et al. Clinical outcomes of human herpesvirus 6 reactivation after hematopoietic stem cell transplantation. *Clin Infect Dis* **2005**; *40*:932–40.
4. Ljungman P, Wang FZ, Clark DA, et al. High levels of human herpesvirus 6 DNA in peripheral blood leucocytes are correlated to platelet engraftment and disease in allogeneic stem cell transplant patients. *Br J Haematol* **2000**; *111*:774–81.

5. Yoshikawa T, Asano Y, Ihira M, et al. Human herpesvirus 6 viremia in bone marrow transplant recipients: clinical features and risk factors. *J Infect Dis* **2002**; *185*:847–53.
6. Hill JA, Koo S, Guzman Suarez BB, et al. Cord-blood hematopoietic stem cell transplant confers an increased risk for human herpesvirus-6-associated acute limbic encephalitis: a cohort analysis. *Biol Blood Marrow Transplant* **2012**; *18*:1638–48.
7. Ogata M, Satou T, Kadota J, et al. Human herpesvirus 6 (HHV-6) reactivation and HHV-6 encephalitis after allogeneic hematopoietic cell transplantation: a multicenter, prospective study. *Clin Infect Dis* **2013**; *57*:671–81.
8. Ogata M, Kikuchi H, Satou T, et al. Human herpesvirus 6 DNA in plasma after allogeneic stem cell transplantation: incidence and clinical significance. *J Infect Dis* **2006**; *193*:68–79.
9. Hentrich M, Oruzio D, Jäger G, et al. Impact of human herpesvirus-6 after haematopoietic stem cell transplantation. *Br J Haematol* **2005**; *128*:66–72.
10. Yamane A, Mori T, Suzuki S, et al. Risk factors for developing human herpesvirus 6 (HHV-6) reactivation after allogeneic hematopoietic stem cell transplantation and its association with central nervous system disorders. *Biol Blood Marrow Transplant* **2007**; *13*:100–6.
11. Zerr DM, Fann JR, Breiger D, et al. HHV-6 reactivation and its effect on delirium and cognitive functioning in hematopoietic cell transplantation recipients. *Blood* **2011**; *117*:5243–9.
12. Sashihara J, Tanaka-Taya K, Tanaka S, et al. High incidence of human herpesvirus 6 infection with a high viral load in cord blood stem cell transplant recipients. *Blood* **2002**; *100*:2005–11.
13. Chevallier P, Hebia-Fellah I, Planche L, et al. Human herpes virus 6 infection is a hallmark of cord blood transplant in adults and may participate to delayed engraftment: a comparison with matched unrelated donors as stem cell source. *Bone Marrow Transplant* **2010**; *45*:1204–11.
14. Zerr DM, Gooley TA, Yeung L, et al. Human herpesvirus 6 reactivation and encephalitis in allogeneic bone marrow transplant recipients. *Clin Infect Dis* **2001**; *33*:763–71.
15. Aoki J, Numata A, Yamamoto E, et al. Impact of human herpesvirus-6 reactivation on outcomes of allogeneic hematopoietic stem cell transplantation. *Biol Blood Marrow Transplant* **2015**; *21*:2017–22.
16. Dulery R, Salleron J, Dewilde A, et al. Early human herpesvirus type 6 reactivation after allogeneic stem cell transplantation: a large-scale clinical study. *Biol Blood Marrow Transplant* **2012**; *18*:1080–9.
17. Phan TL, Carlin K, Ljungman P, et al. Human herpesvirus-6B reactivation is a risk factor for grades II to IV acute graft-versus-host disease after hematopoietic stem cell transplantation: a systematic review and meta-analysis. *Biol Blood Marrow Transplant* **2018**; *24*:2324–36.
18. de Pagter PJ, Schuurman R, Keukens L, et al. Human herpes virus 6 reactivation: important predictor for poor outcome after myeloablative, but not non-myeloablative allo-SCT. *Bone Marrow Transplant* **2013**; *48*:1460–4.
19. Cirrone F, Ippoliti C, Wang H, et al. Early human herpes virus type 6 reactivation in umbilical cord blood allogeneic stem cell transplantation. *Leuk Lymphoma* **2016**; *57*:2555–9.
20. Verhoeven DH, Claas EC, Jol-van der Zijde CM, et al. Reactivation of human herpes virus-6 after pediatric stem cell transplantation: risk factors, onset, clinical symptoms and association with severity of acute graft-versus-host disease. *Pediatr Infect Dis J* **2015**; *34*:1118–27.
21. Wang LR, Dong LJ, Zhang MJ, Lu DP. Correlations of human herpesvirus 6B and CMV infection with acute GVHD in recipients of allogeneic haematopoietic stem cell transplantation. *Bone Marrow Transplant* **2008**; *42*:673–7.
22. Admiraal R, de Koning CCH, Lindemans CA, et al. Viral reactivations and associated outcomes in the context of immune reconstitution after pediatric hematopoietic cell transplantation. *J Allergy Clin Immunol* **2017**; *140*: 1643–50.e1649.
23. de Pagter PJ, Schuurman R, Visscher H, et al. Human herpes virus 6 plasma DNA positivity after hematopoietic stem cell transplantation in children: an important risk factor for clinical outcome. *Biol Blood Marrow Transplant* **2008**; *14*:831–9.
24. Tormo N, Solano C, de la Cámara R, et al. An assessment of the effect of human herpesvirus-6 replication on active cytomegalovirus infection after allogeneic stem cell transplantation. *Biol Blood Marrow Transplant* **2010**; *16*:653–61.
25. Wang FZ, Larsson K, Linde A, Ljungman P. Human herpesvirus 6 infection and cytomegalovirus-specific lymphoproliferative responses in allogeneic stem cell transplant recipients. *Bone Marrow Transplant* **2002**; *30*:521–6.
26. Drobyski WR, Knox KK, Majewski D, Carrigan DR. Brief report: fatal encephalitis due to variant B human herpesvirus-6 infection in a bone marrow-transplant recipient. *N Engl J Med* **1994**; *330*:1356–60.
27. Wang FZ, Dahl H, Linde A, et al. Lymphotropic herpesviruses in allogeneic bone marrow transplantation. *Blood* **1996**; *88*:3615–20.
28. Maeda Y, Teshima T, Yamada M, et al. Monitoring of human herpesviruses after allogeneic peripheral blood stem cell transplantation and bone marrow transplantation. *Br J Haematol* **1999**; *105*:295–302.

29. Imbert-Marcille BM, Tang XW, Lepelletier D, et al. Human herpesvirus 6 infection after autologous or allogeneic stem cell transplantation: a single-center prospective longitudinal study of 92 patients. *Clin Infect Dis* **2000**; 31:881–6.
30. Savolainen H, Lautenschlager I, Piiparinen H, et al. Human herpesvirus-6 and -7 in pediatric stem cell transplantation. *Pediatr Blood Cancer* **2005**; 45:820–5.
31. Bhanushali MJ, Kranick SM, Freeman AF, et al. Human herpes 6 virus encephalitis complicating allogeneic hematopoietic stem cell transplantation. *Neurology* **2013**; 80:1494–500.
32. Wainwright MS, Martin PL, Morse RP, et al. Human herpesvirus 6 limbic encephalitis after stem cell transplantation. *Ann Neurol* **2001**; 50:612–9.
33. Seeley WW, Marty FM, Holmes TM, et al. Post-transplant acute limbic encephalitis: clinical features and relationship to HHV6. *Neurology* **2007**; 69:156–65.
34. Fotheringham J, Akhyani N, Vortmeyer A, et al. Detection of active human herpesvirus-6 infection in the brain: correlation with polymerase chain reaction detection in cerebrospinal fluid. *J Infect Dis* **2007**; 195:450–4.
35. Muta T, Fukuda T, Harada M. Human herpesvirus-6 encephalitis in hematopoietic SCT recipients in Japan: a retrospective multicenter study. *Bone Marrow Transplant* **2009**; 43:583–5.
36. Zerr DM. Human herpesvirus 6 and central nervous system disease in hematopoietic cell transplantation. *J Clin Virol* **2006**; 37(Suppl 1):S52–6.
37. Zerr DM, Gupta D, Huang ML, et al. Effect of antivirals on human herpesvirus 6 replication in hematopoietic stem cell transplant recipients. *Clin Infect Dis* **2002**; 34:309–17.
38. Tiacci E, Luppi M, Barozzi P, et al. Fatal herpesvirus-6 encephalitis in a recipient of a T-cell-depleted peripheral blood stem cell transplant from a 3-loci mismatched related donor. *Haematologica* **2000**; 85:94–7.
39. Noguchi T, Mihara F, Yoshiura T, et al. MR imaging of human herpesvirus-6 encephalopathy after hematopoietic stem cell transplantation in adults. *Am J Neuroradiol* **2006**; 27:2191–5.
40. De Almeida Rodrigues G, Nagendra S, Lee CK, De Magalhães-Silverman M. Human herpes virus 6 fatal encephalitis in a bone marrow recipient. *Scand J Infect Dis* **1999**; 31:313–5.
41. Ogata M, Oshima K, Ikebe T, et al. Clinical characteristics and outcome of human herpesvirus-6 encephalitis after allogeneic hematopoietic stem cell transplantation. *Bone Marrow Transplant* **2017**; 52:1563–70.
42. Gudiol C, Lewis RE, Strati P, Kontoyiannis DP. Chimeric antigen receptor T-cell therapy for the treatment of lymphoid malignancies: is there an excess risk for infection? *Lancet Haematol* **2021**; 8:e216–28.
43. Handley G, Hasbun R, Okhuysen P. Human herpesvirus 6 and central nervous system disease in oncology patients: a retrospective case series and literature review. *J Clin Virol* **2021**; 136:104740.
44. Shah M, Kuhn A, Shields G, et al. Human herpesvirus 6 encephalitis following axicabtagene ciloleucel treatment for refractory diffuse large B cell lymphoma. *Hemasphere* **2021**; 5:e535.
45. Neelapu SS, Locke FL, Bartlett NL, et al. Axicabtagene ciloleucel CAR T-cell therapy in refractory large B-cell lymphoma. *N Engl J Med* **2017**; 377:2531–44.
46. Santomaso BD, Park JH, Salloum D, et al. Clinical and biological correlates of neurotoxicity associated with CAR T-cell therapy in patients with B-cell acute lymphoblastic leukemia. *Cancer Discov* **2018**; 8:958–71.
47. Gust J, Hay KA, Hanafi LA, et al. Endothelial activation and blood-brain barrier disruption in neurotoxicity after adoptive immunotherapy with CD19 CAR-T cells. *Cancer Discov* **2017**; 7:1404–19.
48. Lee DW, Santomaso BD, Locke FL, et al. ASTCT consensus grading for cytokine release syndrome and neurologic toxicity associated with immune effector cells. *Biol Blood Marrow Transplant* **2019**; 25:625–38.
49. Wang FZ, Linde A, Hägglund H, et al. Human herpesvirus 6 DNA in cerebrospinal fluid specimens from allogeneic bone marrow transplant patients: does it have clinical significance? *Clin Infect Dis* **1999**; 28:562–8.
50. Tunkel AR, Glaser CA, Bloch KC, et al; Infectious Diseases Society of America. The management of encephalitis: clinical practice guidelines by the Infectious Diseases Society of America. *Clin Infect Dis* **2008**; 47:303–27.
51. Tomblyn M, Chiller T, Einsele H, et al; Center for International Blood and Marrow Research; National Marrow Donor program; European Blood and Marrow Transplant Group; American Society of Blood and Marrow Transplantation; Canadian Blood and Marrow Transplant Group; Infectious Diseases Society of America; Society for Healthcare Epidemiology of America; Association of Medical Microbiology and Infectious Disease Canada; Centers for Disease Control and Prevention. Guidelines for preventing infectious complications among hematopoietic cell transplantation recipients: a global perspective. *Biol Blood Marrow Transplant* **2009**; 15:1143–238.
52. Dewhurst S. Human herpesvirus type 6 and human herpesvirus type 7 infections of the central nervous system. *Herpes* **2004**; 11:105A–11A.
53. Ogata M, Uchida N, Fukuda T, et al. Clinical practice recommendations for the diagnosis and management of human herpesvirus-6B encephalitis after allogeneic hematopoietic stem cell transplantation: the Japan Society for Hematopoietic Cell Transplantation. *Bone Marrow Transplant* **2020**; 55:1004–13.
54. Ogata M, Satou T, Inoue Y, et al. Foscarnet against human herpesvirus (HHV)-6 reactivation after allo-SCT: breakthrough HHV-6 encephalitis following antiviral prophylaxis. *Bone Marrow Transplant* **2013**; 48:257–64.