



The Clinical Value of Serial Radionuclide Gastric-Emptying Scintigraphy for Objective Evaluation of Gastroparesis in a Patient with Superior Mesenteric Artery Syndrome Post Corrective Surgery

Amir Javaid¹ Qaisar Hussain Siraj¹

¹Department of Medical Imaging, Nuclear Medicine Unit, Farwaniya Hospital, Kuwait City, Kuwait

Address for correspondence Amir Javaid, Department of Medical Imaging, Nuclear Medicine Unit, Farwaniya Hospital, Kuwait City, Kuwait (e-mail: dramir10@gmail.com).

World J Nuclear Med 2022;21:156–160.

Abstract

Keywords

- ▶ superior mesenteric artery syndrome
- ▶ gastric emptying
- ▶ Tc-99m Tin colloid
- ▶ gastroparesis
- ▶ duodenojejunostomy

Superior mesenteric artery syndrome is a rare cause of intestinal obstruction. The condition results from compression of the duodenum between the aorta and the superior mesenteric artery, which causes an impairment of gastric emptying and associated chronic symptoms. There is a need to objectively assess the severity of gastric-emptying disorder in these patients post-treatment to assess the efficacy of the conservative or surgical management. We report here a case of a patient where the radionuclide gastric-emptying study was crucial in monitoring the effectiveness of surgical management of this syndrome.

Introduction

Superior mesenteric artery syndrome (SMAS), also known as Cast syndrome, chronic duodenal ileus, or Wilkie's syndrome^{1,2} is an acquired disorder due to intestinal obstruction resulting from the compression of third part of the duodenum between the abdominal aorta and the superior mesenteric artery (SMA). The recorded incidence of this disorder is 0.013 to 0.3%.³ The patients usually present clinically with chronic symptoms of abdominal discomfort, nausea, and vomiting.

SMAS is initially managed conservatively, with nutritional supplementation and medications but corrective surgical procedures such as “duodenojejunostomy” are undertaken when conservative therapy fails. Despite surgical correction, prolonged gastroparesis is a frequently

encountered problem related to gastric and duodenal atony.⁴

Gastric-emptying scintigraphy (GES) is a well-established radionuclide imaging modality for evaluating gastric motility and diagnosing gastroparesis in long-standing diabetic patients.

We present a case of SMAS in a 54-year-old woman who presented with nausea, vomiting, and abdominal discomfort that did not respond to conservative management in whom follow-up gastric-emptying studies provided accurate and reliable information for monitoring gastric motility postsurgery. Although recently the use of GES for documenting gastric-emptying status in a patient with SMAS has been published,⁵ to the best of our knowledge, the use of GES for the postsurgical evaluation of gastric motility in a patient with SMAS has not previously been reported.

DOI <https://doi.org/10.1055/s-0042-1750339>.
ISSN 1450-1147.

© 2022. World Association of Radiopharmaceutical and Molecular Therapy (WARMTH). All rights reserved.

This is an open access article published by Thieme under the terms of the Creative Commons Attribution-NonDerivative-NonCommercial-License, permitting copying and reproduction so long as the original work is given appropriate credit. Contents may not be used for commercial purposes, or adapted, remixed, transformed or built upon. (<https://creativecommons.org/licenses/by-nc-nd/4.0/>)

Thieme Medical and Scientific Publishers Pvt. Ltd., A-12, 2nd Floor, Sector 2, Noida-201301 UP, India

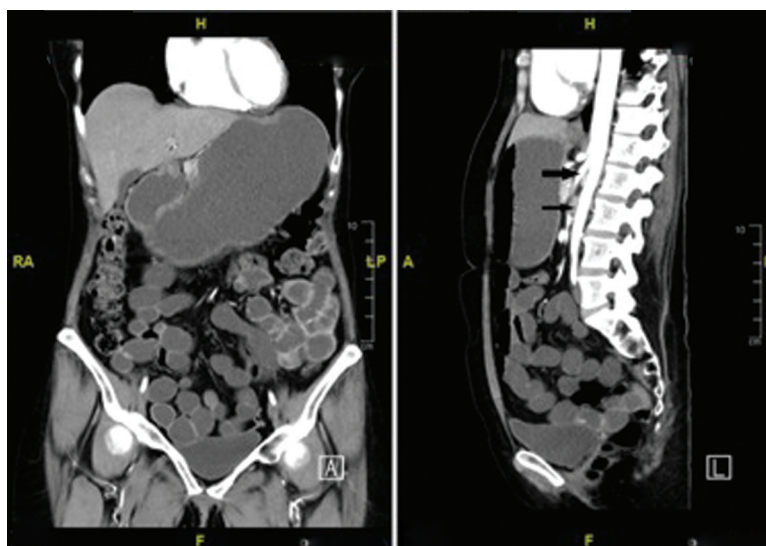


Fig. 1 Contrast-enhanced computed tomography scan showing a distended stomach (left) with the angiogram (right) showing compression of the duodenum (lower arrow) between the superior mesenteric artery (upper arrow) and the aorta.

Case Report

A 54-year-old nondiabetic female presented with 2 years history of abdominal discomfort associated with nausea and vomiting for which the patient was given antiemetic and H₂-receptor blocker therapy in the primary care clinic. However, her symptoms worsened over time, becoming particularly severe in the last couple of months prior to her referral to the gastroenterologist in the district general hospital outpatient clinic. Her routine laboratory biochemical and hematological tests were normal. Abdominal and pelvic ultrasound was also unremarkable. A contrast-enhanced computed tomography (CT) was next performed. The arterial phase of the study showed an acute aortomesenteric angle, with the third part of the duodenum seen to be compressed between the aorta and the SMA with dilatation of the proximal duodenum (► Fig. 1).

The patient was conservatively managed for the next 8 months with different medications including an antacid (simethicone), an H₂-blocker (ranitidine), a prokinetic

(itopride), and a proton pump inhibitor (esomeprazole), which, however, failed to provide significant relief in her symptoms. Because of the failure of conservative treatment, surgery was planned. The arterial phase sagittal reconstruction images of contrast-enhanced CT through the mid-abdomen with the measurements showed an aortomesenteric distance of approximately 5.5 mm and a reduction in the angle between the aorta and the mesenteric artery (SMA-aorta angle) at 15 degrees (► Fig. 2).

The patient underwent laparoscopic duodenojejunostomy procedure where the third and fourth parts of the duodenum were mobilized and resected with a side-to-side anastomosis of the duodenum and the jejunum performed. Postoperative gastroscopy showed a significant amount of retained duodenogastric fluid, mild edema at the site of the anastomosis, and mild antral gastritis but a normal duodenojejunostomy. The postoperative fluoroscopic follow-through study showed no evidence of contrast leakage or narrowing/compression of the operative bed. The stomach had a normal contour with normal

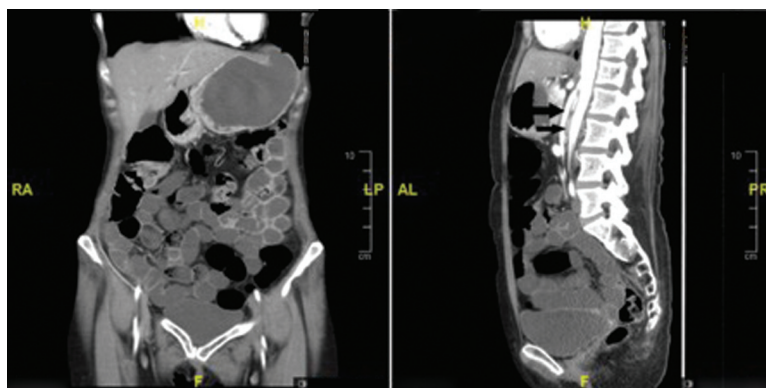


Fig. 2 Preoperative contrast-enhanced computed tomography scan showing normal stomach distention (left) with the sagittal angiogram (right) showing compression of the duodenum (lower arrow) between the superior mesenteric artery (upper arrow) and the aorta.

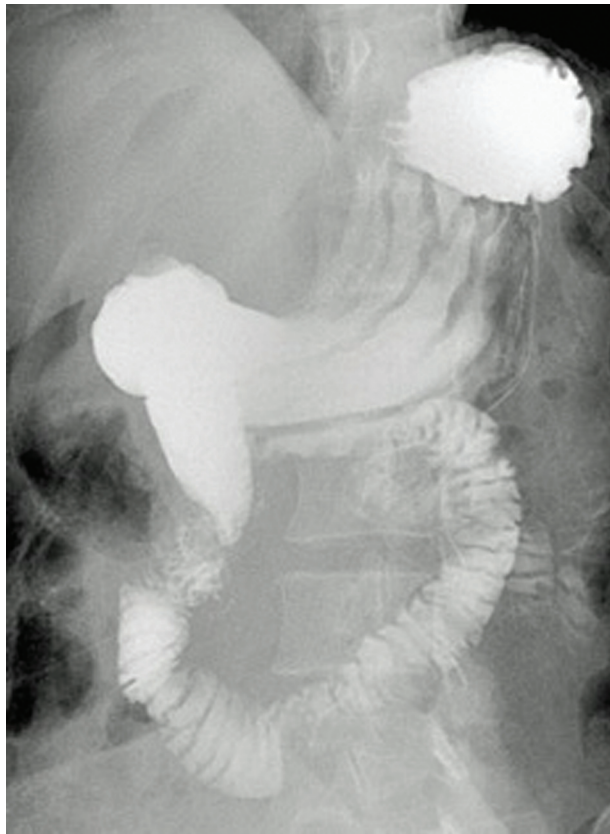


Fig. 3 Postoperative fluoroscopic follow-through study using water-soluble contrast shows no evidence of contrast leakage.

distention and showed a normal mucosal pattern. There was normal esophageal, gastric, and duodenal peristalsis (see ►Fig. 3).

During the next 2 weeks after surgery, the patient complained of diffuse abdominal pain associated with nausea and repeated vomiting. In view of the persistence of symp-

oms following surgery, the patient was referred to the nuclear medicine department for the estimation of her gastric motility status. Gastric-emptying study was performed using a radiolabeled semisolid meal (oat meal labeled with 37 MBq of Tc-99m Tin colloid) with sequential static imaging of the stomach in the erect posture performed for 120 minutes postingestion of the meal. The gastric-emptying curve was very shallow and did not allow for measurement of gastric emptying half-time, but the 1-hour retention of 95% (normal > 30%, < 90%) and 2-hour retention of 75% (normal < 60%). These findings were consistent with severe gastroparesis (►Fig. 4).

The second follow-up gastric-emptying study (►Fig. 5) was performed 11 months later when the patient developed postprandial gastric discomfort. The follow-up semisolid meal (38 MBq of Tc-99m Tin colloid) gastric-emptying study now showed a marked improvement. The immediate postprandial image showed accumulation of activity in the lower part of the stomach with the subsequent images showing slow but progressive distal transit of activity with continuing partial retention of the radioactive meal in the pyloric antrum. The gastric-emptying curve showed a prolonged lag-phase of 20 minutes and the gastric-emptying half-time was prolonged at 73 minutes (normal range: 33 ± 15 minutes). The scan findings were consistent with stasis involving the pyloric antrum. Compared with the previous study, the half-time of gastric emptying was markedly improved though still abnormal. The percentage retention of gastric contents at 90 minute was 38% compared with 78% on the early postoperative scan.

The third follow-up GES was performed 15 months after surgery when the only symptom experienced by the patient was postprandial fullness. The GES study (►Fig. 6) using a solid radioactive meal (egg-white sandwich labeled with 39 MBq of Tc-99m Tin Colloid) showed progressive emptying of gastric contents with a normal shaped gastric-emptying

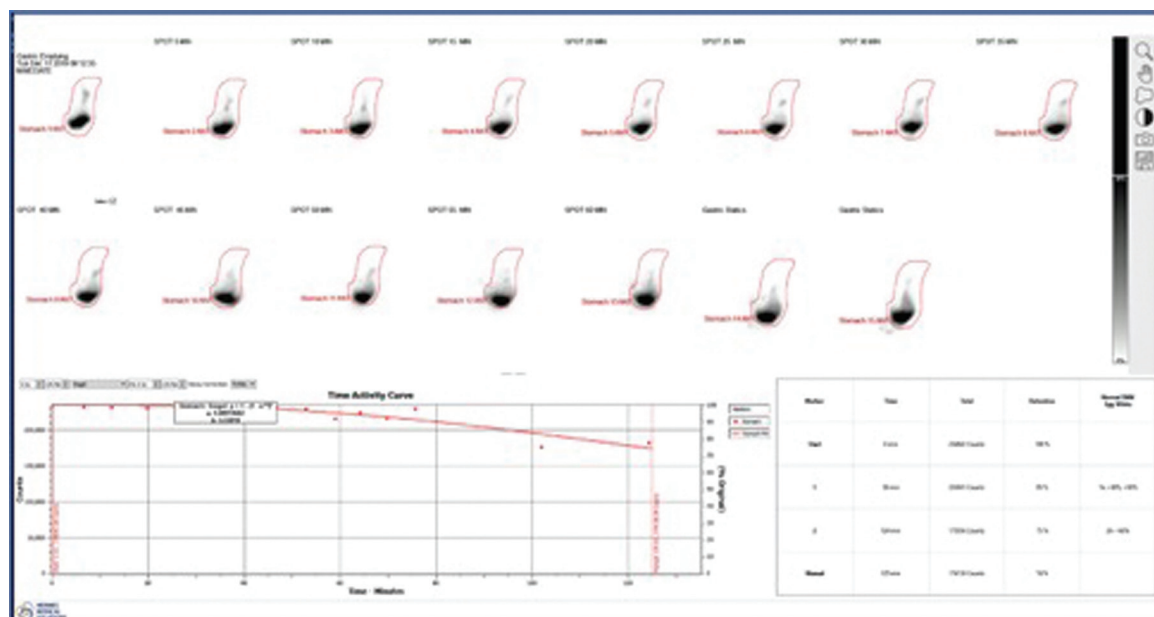


Fig. 4 Semisolid gastric-emptying study performed 2 weeks after surgery showing severe gastroparesis,

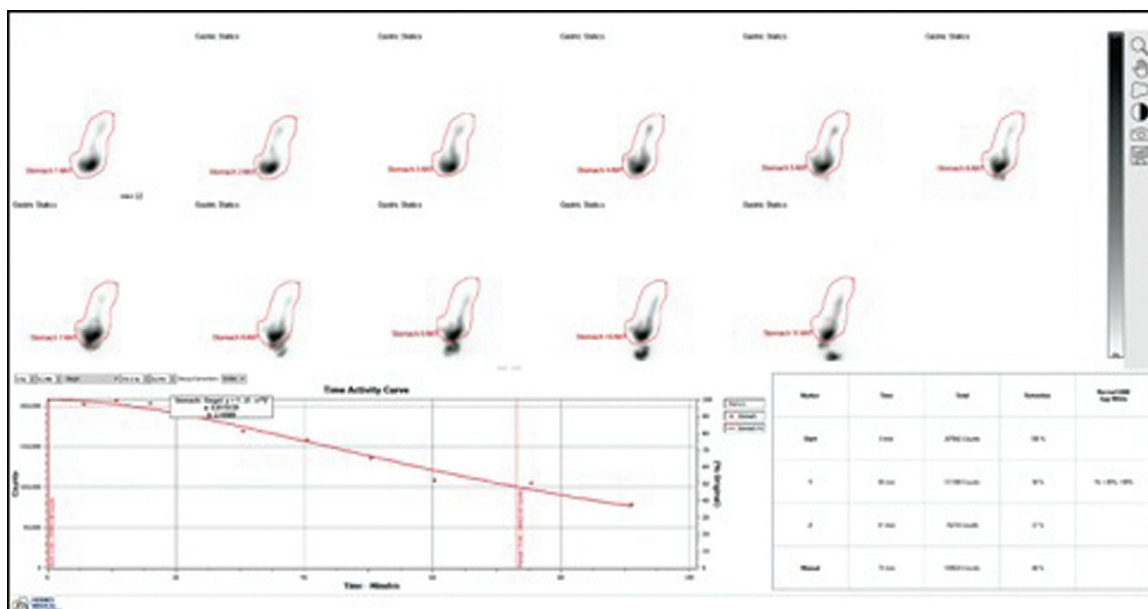


Fig. 5 Follow-up gastric-emptying study performed 11 months after surgery showing abnormal but significantly improved gastric emptying.




Fig. 6 Second follow-up gastric-emptying study 15 months after surgery showing almost normal gastric emptying.

curve with the images showing progressive emptying of the gastric contents with 96% retention at 1 hour (normal > 30%, < 90%), 62% retention at 2 hours (normal < 60%), 41% retention at 3 hours (normal < 30%), and 13% retention at 4 hours (normal < 10%). Compared with the previous studies, there was a very marked improvement in gastric motility seen with only borderline gastroparesis documented.

Discussion

SMA normally arises from the anterior aspect of the aorta at the level of the L1 vertebral body, and is enveloped in fatty and lymphatic tissue.^{6,7} In healthy individuals, the arch of

the SMA is held away from the aorta by the mesenteric pad of fat. The normal SMA-aorta angle is 25 to 50 degrees, which is reduced to around 7 to 22 degrees in SMAS. The normal SMA-aorta distance is 10 to 28 mm, which is reduced to 2 to 8 mm in the SMAS.⁸ The severity of symptoms in a patient with SMAS is proportionate to the reduction in distance between the SMA and the aorta.⁹

The main cause of this syndrome is the loss of retroperitoneal fat padding between the two vessels thus reducing the aortomesenteric angle to less than 25.¹⁰ The absence of fatty support together with an already acute SMA-aortic angle promotes further compression of the third portion of the duodenum between the vertebrae and the SMA.^{11,12}

Conditions that decrease the aortomesenteric angle and narrow the distance between the two vessels may cause duodenal obstruction.

The possibility of SMAS should be considered in a patient presenting with unexplained abdominal pain provoked by eating and accompanied by nausea and vomiting with an endoscopic evidence of retained food in the stomach and a dilated proximal duodenum.

Radiography of the abdomen is only useful in showing a distended stomach. An upper gastrointestinal contrast study is valuable in demonstrating dilatation of the first and second parts of the duodenum and the obstruction of the third part of the duodenum together with a significant delay in the transit of contrast from the duodenum to the jejunum. Historically, barium meal and arteriography were used as diagnostic tools in patients with ¹³SMAS but more recently CT angiography has been used and shown higher diagnostic sensitivity. Measurement of the aortomesenteric angle by CT angiography has a high diagnostic yield at around 94% of the cases.¹⁴

Radionuclide gastric-emptying study provides accurate diagnosis and assessment of gastroparesis. GES offers a noninvasive, physiologic means to assess gastric motor function.^{3,15} The patient ingests a radiolabeled meal; emptying from the stomach is monitored over time by serial images using a gamma camera. Solid-phase meals are more sensitive than liquid meals in detecting gastroparesis because normal emptying of liquids is often preserved until gastroparesis is advanced. The GES can potentially differentiate patients with functional abdominal pain due to psychological factors like anorexia, but it can help diagnose anatomical causes of delayed gastric emptying such as SMAS-induced gastroparesis both pre- and postoperatively.

Open or laparoscopic duodenojejunostomy has been described as the commonest and the best surgical treatment options for SMAS. The technique involves bypassing the compressed third part of the duodenum by constructing an anastomosis between the second portion of the duodenum and proximal jejunum anterior to the SMA.

Laparoscopic duodenojejunostomy provides relief of symptoms, weight restoration and improves the quality of life with the further advantage of relative noninvasiveness of the procedure with minimal trauma and a shorter duration of hospital stay.

This case underscores the importance of serial follow-up scan after surgery. As seen in our case, the early postoperative study showed very poor gastric emptying and motility.

The follow-up scan after a few months showed significant improvement in gastric emptying but documented antral dilatation and delay in gastric emptying was presumably related to chronic residual atony, which, however, was seen to improve with time but significant local stasis was seen to persist, and although there was an overall improvement in gastroparesis, there was persistent chronic delay in gastric emptying. The third follow-up scan 15 months postsurgery showed almost normal motility. The scintigraphic improvement in gastric motility postsurgery follow-up scans closely depicted the symptomatic relief experienced by the patient.

Surgery does not usually provide complete resolution of symptoms and a proportion of patients with refractory symptoms continue to suffer from prolonged gastroparesis that resolves slowly over a variable time after corrective surgery. In these patients, it is important to document gastric motility status postsurgery.

As seen in this case, GES is not only an objective tool for the postoperative assessment of gastric-emptying status in patients with SMAS but also underscores the importance of serial studies as a sensitive measure of gastric motility status over a longer period of time by documenting improvement in improvement in gastric motility reflecting symptomatic relief experienced by a patient.

Conflict of Interest

None declared.

References

- 1 Kwan E, Lau H, Lee F. Wilkie's syndrome. *Surgery* 2004;135(02): 225–227
- 2 Wilkie DPD. Chronic duodenal ileus. *Br J Surg* 1921;9(34): 204–214
- 3 Lee TH, Lee JS, Jo Y, et al. Superior mesenteric artery syndrome: where do we stand today? *J Gastrointest Surg* 2012;16(12): 2203–2211
- 4 Aslam MI, Finch JG. Prolonged gastroparesis after corrective surgery for Wilkie's syndrome: a case report. *J Med Case Reports* 2008;2:109
- 5 Kang S, Choi BW. Clinical usefulness of gastric-emptying scintigraphy in the superior mesenteric artery syndrome: a case report. *Nucl Med (Stuttg)* 2020;59(04):335–337
- 6 Wayne ER, Burrington JD. Duodenal obstruction by the superior mesenteric artery in children. *Surgery* 1972;72(05):762–768
- 7 Ozkurt H, Cenker MM, Bas N, Erturk SM, Basak M. Measurement of the distance and angle between the aorta and superior mesenteric artery: normal values in different BMI categories. *Surg Radiol Anat* 2007;29(07):595–599
- 8 Mansberger AR Jr, Hearn JB, Byers RM, Fleisig N, Buxton RW. Vascular compression of the duodenum. Emphasis on accurate diagnosis. *Am J Surg* 1968;115(01):89–96
- 9 Unal B, Aktaş A, Kemal G, et al. Superior mesenteric artery syndrome: CT and ultrasonography findings. *Diagn Interv Radiol* 2005;11(02):90–95
- 10 Ylinen P, Kinnunen J, Höckerstedt K. Superior mesenteric artery syndrome. A follow-up study of 16 operated patients. *J Clin Gastroenterol* 1989;11(04):386–391
- 11 Matheus CdeO, Waisberg J, Zewer MH, Godoy AC. Syndrome of duodenal compression by the superior mesenteric artery following restorative proctocolectomy: a case report and review of literature. *Sao Paulo Med J* 2005;123(03):151–153
- 12 Valdes A, Cárdenas O, Espinosa A, Villazón O, Valdes V. Superior mesenteric artery syndrome. *J Am Coll Surg* 2005;201(05):808
- 13 Baltazar U, Dunn J, Floresguerra C, Schmidt L, Browder W. Superior mesenteric artery syndrome: an uncommon cause of intestinal obstruction. *South Med J* 2000;93(06):606–608
- 14 Camilleri M, Hasler WL, Parkman HP, Quigley EM, Soffer E. Measurement of gastrointestinal motility in the GI laboratory. *Gastroenterology* 1998;115(03):747–762
- 15 Sachdeva P, Malhotra N, Pathikonda M, et al. Gastric emptying of solids and liquids for evaluation for gastroparesis. *Dig Dis Sci* 2011;56(04):1138–1146