



Long-Term Outcome of Single-Session, Ultrasound-Guided, Radiofrequency Ablation for Symptomatic Small, Lower Limb, Venous Malformations

ORIGINAL ARTICLE

LAURENCE VERHAEGHE

VEERLE LABARQUE

JAN VRANCKX

INGE FOURNEAU

STEVEN PANS

GEERT MALEUX

*Author affiliations can be found in the back matter of this article

]u[ubiquity press

ABSTRACT

Objectives: To analyze the long-term clinical outcome of percutaneous, ultrasound-guided radiofrequency ablation (RFA) of peripheral low-flow vascular malformations (VM).

Materials & Methods: Adolescent patients presenting with symptomatic VMs and referred for percutaneous management using RFA between January 2010 and January 2015 were identified by a search in the institutional interventional radiology database. Clinical and radiological follow-up up to April 2021 was based on retrospective analysis of patients' electronic medical records and imaging files. This retrospective study was approved by the institutional ethics committee.

Results: Four female patients (median age 16 years) presented with lower extremity pain, swelling and functional disability related to VM as confirmed by magnetic resonance imaging. Two patients underwent percutaneous sclerotherapy previously. Clinical follow-up (mean of 8,5 years) showed complete and sustained resolution of the symptoms in all patients; in one patient a persistent decrease in muscular strength of the treated limb was noted.

Conclusion: Percutaneous, ultrasound-guided RFA is relatively safe and efficient with durable symptom relief in the management of small, lower limb VMs in adolescent patients.

CORRESPONDING AUTHOR:

Geert Maleux, MD, PhD

Department of Radiology,
University Hospitals KU
Leuven, Herestraat 49, 3000
Leuven, BE

geert.maleux@uzleuven.be

KEYWORDS:

vascular malformation; lower limb; radiofrequency ablation; percutaneous; outcome

TO CITE THIS ARTICLE:

Verhaeghe L, Labarque V, Vranckx J, Fourneau I, Pans S, Maleux G. Long-Term Outcome of Single-Session, Ultrasound-Guided, Radiofrequency Ablation for Symptomatic Small, Lower Limb, Venous Malformations. *Journal of the Belgian Society of Radiology*. 2022; 106(1): 68, 1–6. DOI: <https://doi.org/10.5334/jbsr.2801>

INTRODUCTION

Venous malformations (VMs) are congenital, developmental anomalies which might occur anywhere in the body, but typically seen in the head and neck region (40%), extremities (40%) and trunk (20%) [1]. Symptoms may vary, depending on extent and location of the VM, and may include swelling, pain, bleeding, muscle motion restriction and contracture and thrombophlebitis [2].

Management of VMs traditionally includes compression therapy, percutaneous sclerotherapy and debulking surgery [3, 4, 5]. Percutaneous sclerotherapy, using various types of liquid sclerosants, is not free of complications, including tissue ischemia and infarction, nerve injury, muscle contracture, and skin ulceration in up to 13% of cases [6]. In addition, patient satisfaction is around 50% at five years of follow-up [7]. Recently, a few case reports and small case series reported the feasibility on safety of percutaneous, image-guided ablation of small intramuscular and/or subcutaneous VM using both radiofrequency ablation (RFA) [8–11] as well as cryoablation [12]. In this report we retrospectively evaluated the safety and long-term clinical outcome of small, symptomatic VM in adolescents treated with percutaneous, single-session radiofrequency ablation.

MATERIALS AND METHODS

STUDY DESIGN & STUDY POPULATION

This is a retrospective study, including consecutive adolescent patients presenting with a symptomatic extra-truncular low flow venous malformation, located in the subcutaneous and/or intramuscular region of the extremities and treated with RFA between April 2010 & January 2015. Patients were seen at the institutional multidisciplinary clinic for vascular malformations including different specialties: interventional radiology, vascular medicine, pediatrics, plastic & reconstructive surgery, vascular surgery, and maxillofacial surgery. Data of patients' history and characteristics, indication for referral to percutaneous ablation therapy and follow-up data were gathered from the electronic medical records, and the hospital Picture Archiving and Communicating System (PACS, Agfa Gevaert, Mortsel, Belgium).

This retrospective study was approved by the institutional ethics committee and all patients gave informed consent before percutaneous ablation procedure.

RADIOLOGICAL ASSESSMENT AT BASELINE AND DURING FOLLOW-UP

Soft tissue ultrasound was performed using a 4–15 MHz array linear probe to localize and differentiate the VM. In addition, magnetic resonance imaging of the VM was performed, including T2 fat saturated images (STIR/SPAIR/SPIR) as well as T1-weighted axial and coronal images without and with 15 ml of Gadolinium-contrast medium

(gadoteric acid-gadoterate meglumine, Dotarem, Guerbet, Villepinte, France).

PERCUTANEOUS RADIOFREQUENCY ABLATION PROCEDURE

Procedures were performed under general anesthesia. After draping the affected limb, the VM was punctured percutaneously under ultrasound guidance using various types of RFA needles (Cool-Tip RF Electrode Kit, Valleylab, Tyco, Boulder, CO, USA or StarBurst, Angiodynamics, Queensbury, NY, USA). Conventionally, the needle tips were placed in the central portion of the lesion and depending on the extent of the lesion one or more needles were inserted in accordance with the manufacturer's instructions for use. Ablation time varied between four and six minutes with needle tip temperatures reached in between 85° and 100°.

PATIENTS' FOLLOW-UP

Patients were followed-up clinically at 1, 6 and 12 months or in case of adverse events. Late clinical follow-up was performed by telephone calls.

In case of residual or persistent complaints, additional follow-up magnetic resonance imaging was performed using T2 fat saturated imaging and T1 imaging without intravenous injection of Gadolinium contrast medium.

RESULTS

Patients were female and in between 11 and 20 years of age (median 16 years); the majority of patients presented with an intramuscular symptomatic VM with a median diameter of 2.9 cm at the lower limb (Figure 1a); two

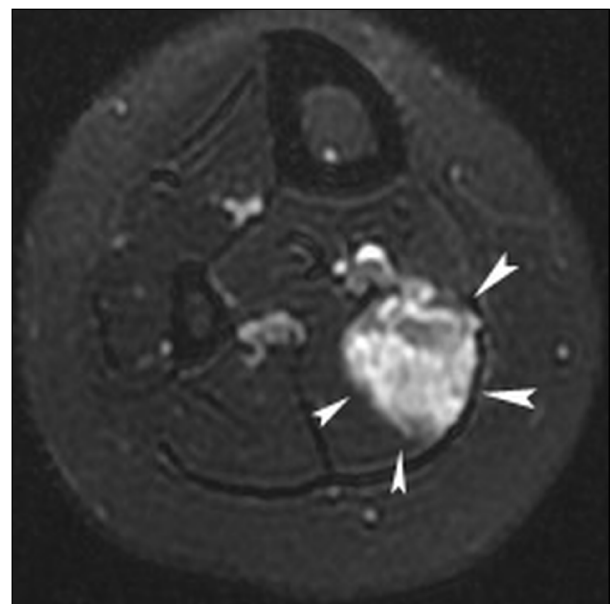


Figure 1a Twenty-year-old female with chronic calf pain. T2-weighted axial magnetic resonance image of the calf demonstrating an hyperintense mass lesion with a maximal diameter of 3.6 cm (white arrowheads) in the right soleus muscle, suggestive for low-flow vascular malformation.

out of four patients previously underwent unsuccessful percutaneous sclerotherapy as summarized in Table 1.

Clinical follow-up at 1 and 6 months revealed complete resolution of the swelling symptoms in all patients; resolution of pain was observed in three out of four patients and less invalidating pain in the remaining patient as summarized in Table 2. One patient presented with new onset of partial loss of muscle strength over the first six months after the index RFA. Radiological re-evaluation with magnetic resonance imaging, performed three months after RFA, demonstrated in this patient complete disappearance of the ablated VM (Figure 1b).

Mid-term (6–12 months) and long-term (median 8.5 years) clinical follow-up showed complete resolution of pain, swelling and functional disability in all patients; the residual, partial, post-ablation loss of muscle strength in one patient decreased during follow-up owing to several months of intensive physiotherapy.

DISCUSSION

This report demonstrates the feasibility of percutaneous RFA for small, lower limb intramuscular and subcutaneous VMs, which is in line with the findings of van der Linden et al. demonstrating high short-term clinical success after RFA for small VMs [8]. In addition, RFA seems to be a valuable treatment option for VMs, not only after failed sclerotherapy [8], but also as a first treatment option. This might be an important advantage compared to percutaneous sclerotherapy, which typically needs several sessions before resulting in meaningful clinical success: Bianchini et al. performed on average two to three sessions of sclerotherapy using polidocanol or ethanol as sclerosant agent [13]; van der Linden et al. found a 42% of clinical failures at three months of follow-up using the same sclerosant agents for sclerotherapy [7].

Treatment of small VMs with percutaneous RFA is not free of adverse events. We encountered in one

D/C/R PARAMETER	PATIENT 1	PATIENT 2	PATIENT 3	PATIENT 4
Age	11 y	14 y	20 y	19 y
Sex	female	female	female	female
Location of VM: Lower extremity				
upper leg	-	-	-	+
lower leg	-	+	+	-
Foot	+	-	-	-
Intramuscular	-	+	+	+
	(lateral gastrocnemius)	(soleus)	(vastus intermedius)	
Subcutaneous tissue	+	-	-	-
Maximum diameter of the VM	2 cm	1, 8 cm	3, 6 cm	4, 3 cm
Patients' symptoms:				
Local pain	+	+	+	+
Local swelling	+	+	+	+
Functional disability	+	+	-	+
Duration of symptoms since onset	NM	4 y	3 y	3 y
Previous treatment				
sclerotherapy	-	+	+	-
. ethanol 96%	-	+	-	-
. sotradecol 3%	-	+	+(2x)	-
Interval between last sclerotherapy and RFA	-	8 months	8 months	-

Table 1 Patients demographics, clinical and radiological presentation of the VM.

VM = venous malformations.

RFA = radiofrequency ablation.

NM = not mentioned in electronic medical record.

PARAMETER	PATIENT 1	PATIENT 2	PATIENT 3	PATIENT 4
<u>Short & midterm FU (1 year)</u>				
Local pain	-	-	-	-
Local swelling	-	-	-	-
Functional disability	-	-	+	-
Procedure-related complication	-	-	+	-
<u>Long-term follow-up (until 1/4/2021)</u>				
FU interval (years)	10 y	11 y	7 y	6 y
Local pain	-	-	-	-
Local swelling	-	-	-	-
Functional disability	-	-	-/+	-
Procedure-related complication	-	-	+	-

Table 2 Patients' clinical short- and long-term follow-up.

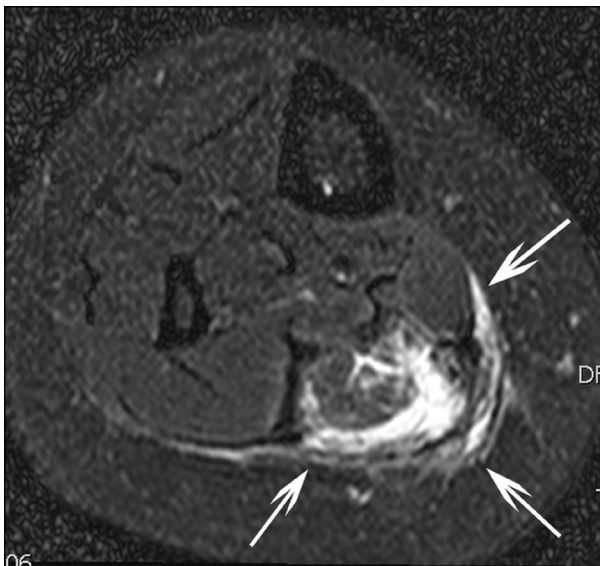


Figure 1b T2-weighted axial magnetic resonance image in the same patient three months after percutaneous radiofrequency ablation which was performed after two failed percutaneous sclerotherapies with sotradecol. Hyperintense rim (white arrows) around the ablated area suggestive for perilesional oedema.

patient local nerve injury resulting in partial loss of muscle strength, which partially recovered after several months and several sessions of physiotherapy. Systemic complications, including systemic ethanol contamination [14] or cardiovascular collapse due to right heart failure as sometimes seen after sclerotherapy [15], nearly seems impossible after RFA.

Last, symptom relief after RFA seems to be much more durable compared to percutaneous sclerotherapy. In the presented report, based on four patients, we did not encounter any recurrent symptoms after more than five years of follow-up, whereas van der Linden et al. found only 58% of partial or complete relief of VM complaints after a follow-up of five years [7].

LIMITATIONS

Limitations of the report mainly include the retrospective nature of the study design and the limited number of included patients ($n = 4$). In addition, only one interventionalist performed the procedures with two types of radio frequency devices. Multicenter, prospective study design with various types of radiofrequency devices are required to confirm the presented, preliminary data.

CONCLUSION

In conclusion, this short report, based on follow-up data of four selected cases of small, lower limb VMs, seems to suggest the durable clinical effect of percutaneous RFA for both de novo VMs and VMs after failed sclerotherapy and might suggest initiation of larger studies on RFA as the first treatment option for small (diameter less than 4 cm) intramuscular and/or subcutaneous VMs and being a real alternative to percutaneous sclerotherapy.

MAIN POINTS

- Percutaneous, ultrasound-guided radiofrequency ablation is relatively safe and effective for the treatment of small, low-flow venous malformations in the lower limb.
- Long-term clinical outcome data shows this treatment is durable.
- Peripheral nerve damage during the intervention might occur with partial recovery after several months of physiotherapy.

COMPETING INTERESTS


The authors have no competing interests to declare.


AUTHOR AFFILIATIONS

Laurence Verhaeghe, MD  orcid.org/0000-0003-2806-3639
Department of Radiology, University Hospitals KU Leuven,
Leuven, BE

Veerle Labarque, MD, PhD  orcid.org/0000-0002-5052-9274
Department of Pediatrics, University Hospitals KU Leuven,
Leuven, BE

Jan Vranckx, MD, PhD  orcid.org/0000-0002-0920-8620
Department of Plastic and Reconstructive Surgery, University
Hospitals KU Leuven, Leuven, BE

Inge Fourneau, MD, PhD  orcid.org/0000-0002-3794-4107
Department of Vascular Surgery, University Hospitals KU
Leuven, Leuven, BE

Steven Pans, MD  orcid.org/0000-0003-0176-454X
Department of Radiology, University Hospitals KU Leuven,
Leuven, BE

Geert Maleux, MD, PhD  orcid.org/0000-0003-0598-0258
Department of Radiology, University Hospitals KU Leuven,
Leuven, BE

REFERENCES

- McCafferty I.** Management of low-flow vascular malformations: clinical presentation, classification, patient selection, imaging and treatment. *Cardiovasc Intervent Radiol.* 2015; 38: 1082–1104. DOI: <https://doi.org/10.1007/s00270-015-1085-4>
- Bowman J, Johnson J, McKusick M, Glociczki P, Driscoll D.** Outcomes of sclerotherapy and embolization for arteriovenous and venous malformations. *Semin Vasc Surg.* 2013; 26: 48–54. DOI: <https://doi.org/10.1053/j.semvascsurg.2013.04.001>
- Burrows P, Mason K.** Percutaneous treatment of low flow vascular malformations. *J Vasc Intervent Radiol.* 2004; 15: 431–445. DOI: <https://doi.org/10.1097/01.RVI.0000124949.24134.CF>
- Lee B, Do Y, Byun H, Choo I, Kim D, Huh S.** Advanced management of venous malformation with ethanol sclerotherapy: mid-term results. *J Vasc Surg.* 2003; 37: 533–538. DOI: <https://doi.org/10.1067/mva.2003.91>
- Vogelzang R, Atassi R, Vouche M, Resnick S, Salem R.** Ethanol embolotherapy of vascular malformations: Clinical outcomes at a single center. *J Vasc Interv Radiol.* 2014; 25: 206–213. DOI: <https://doi.org/10.1016/j.jvir.2013.10.055>
- Lim C, Evans N, Kaur I, et al.** Incidence of major complication following embolo-sclerotherapy for upper and lower extremity vascular malformations. *Vascular.* 2021; 29: 69–77. DOI: <https://doi.org/10.1177/1708538120937616>
- Van Der Linden E, Pattynama P, Heeres B, de Jong S, Hop W, Kroft L.** Long-term patient satisfaction after percutaneous treatment of peripheral vascular malformations. *Radiology.* 2009; 251: 926–932. DOI: <https://doi.org/10.1148/radiol.2513081579>
- Van Der Linden E, Overbosch J, Kroft L.** Radiofrequency ablation for treatment of symptomatic low-flow vascular malformations after previous unsuccessful therapy. *J Vasc Intervent Radiol.* 2005; 16: 747–750. DOI: <https://doi.org/10.1097/01.RVI.0000157245.60426.7B>
- Chils D, Emory C.** Successful treatment of intramuscular venous malformation with image-guided radiofrequency ablation. *J Vasc Intervent Radiol.* 2012; 23: 1391–1393. DOI: <https://doi.org/10.1016/j.jvir.2012.07.013>
- Cho S, Lee J, Chung S, Choi Y, Baek J.** Radiofrequency ablation of facial venolymphatic malformations: assessment of efficacy and safety and the role of injectable electrodes. *J Vasc Intervent Radiol.* 2020; 31: 544–550. DOI: <https://doi.org/10.1016/j.jvir.2019.04.006>
- Kim A, Ko H, Won J, Lee D.** Percutaneous radiofrequency ablation: a novel treatment of facial venous malformation. *J Vasc Surg.* 2009; 50: 424–427. DOI: <https://doi.org/10.1016/j.jvs.2009.03.047>
- Cornelis F, Marin F, Labrèze C, et al.** Percutaneous cryoablation of symptomatic venous malformations as a second-line therapeutic option: a five-year single institution experience. *Eur Radiol.* 2017; 27: 5015–5023. DOI: <https://doi.org/10.1007/s00330-017-4892-y>
- Bianchini G, Camilli D, Furgiele S.** Intramuscular venous malformations of the upper and lower limbs: Indications and outcomes of sclerotherapy. *Cardiovasc Intervent Radiol.* 2018; 41: 1505–1512. DOI: <https://doi.org/10.1007/s00270-018-1997-x>
- Hammer F, Boon L, Mathurin P, Vanwijck R.** Ethanol sclerotherapy of venous malformations: evaluation of systemic ethanol contamination. *J Vasc Intervent Radiol.* 2001; 12: 595–600. DOI: [https://doi.org/10.1016/S1051-0443\(07\)61482-1](https://doi.org/10.1016/S1051-0443(07)61482-1)
- Jo J, Chin J, Park P, Ku S.** Cardiovascular collapse due to right heart failure following ethanol sclerotherapy. *Korean J Anesthesiol.* 2014; 66: 388–391. DOI: <https://doi.org/10.4097/kjae.2014.66.5.388>

TO CITE THIS ARTICLE:

Verhaeghe L, Labarque V, Vranckx J, Fourneau I, Pans S, Maleux G. Long-Term Outcome of Single-Session, Ultrasound-Guided, Radiofrequency Ablation for Symptomatic Small, Lower Limb, Venous Malformations. *Journal of the Belgian Society of Radiology*. 2022; 106(1): 68, 1–6. DOI: <https://doi.org/10.5334/jbsr.2801>

Submitted: 07 March 2022 **Accepted:** 21 June 2022 **Published:** 13 July 2022

COPYRIGHT:

© 2022 The Author(s). This is an open-access article distributed under the terms of the Creative Commons Attribution 4.0 International License (CC-BY 4.0), which permits unrestricted use, distribution, and reproduction in any medium, provided the original author and source are credited. See <http://creativecommons.org/licenses/by/4.0/>.

Journal of the Belgian Society of Radiology is a peer-reviewed open access journal published by Ubiquity Press.

