

Available online at www.sciencedirect.com

ScienceDirect

journal homepage: www.elsevier.com/locate/radcr

Case Report

Regression of a solitary osteochondroma of the distal humerus in a toddler following trauma

Paul B. Heyworth, MBBS*, Muddassir Rashid, MBBS, FRANZCR

Gold Coast University Hospital Radiology Department, 1 Hospital Blvd, Southport QLD 4215, Australia

ARTICLE INFO

Article history:

Received 5 September 2018

Revised 3 October 2018

Accepted 13 October 2018

Available online 7 November 2018

Keywords:

Osteochondroma

Regression

Exostoses

Bone neoplasm

Bone

ABSTRACT

Osteochondromas are bone exostoses, with the vast majority extending from the metaphyseal region of long bones and are capped by cartilage. A review of the current literature reveals spontaneous regression of osteochondromas is a rarely documented event, with all but two of these recorded events resolving before skeletal maturity and within 6 years of identification. We present a case of trauma-induced resolution of a solitary osteochondroma after less than 3 months in a 15-month-old male, with a review of current literature.

© 2018 The Authors. Published by Elsevier Inc. on behalf of University of Washington.

This is an open access article under the CC BY-NC-ND license.

(<http://creativecommons.org/licenses/by-nc-nd/4.0/>)

Introduction

Osteochondromas are bone exostoses, with the vast majority extending from the metaphyseal region of long bones and are capped by cartilage [1,2]. They are the most common benign bone tumor, with 85% of osteochondromas presenting as solitary nonhereditary lesions, whilst the other 15% occur as multiple lesions associated with hereditary multiple osteochondromas [1,3].

Osteochondromas are generally slow-growing lesions in the skeletally immature patient, which usually stabilize in size once fusion of the epiphyseal growth plate occurs [3]. Most lesions are asymptomatic and when issues arise it is generally from a complication such as fracture, poor cosmesis, mechan-

ical joint problem, or entrapment of a nerve or blood vessel [1,3,4].

A review of the current literature reveals spontaneous regression of osteochondromas is a rarely documented event, with all but two of these recorded events resolving before skeletal maturity and within 6 years of identification [3,5,6]. We present a case of trauma-induced resolution of a solitary osteochondroma after less than 3 months in a 15-month-old male.

Case description

A 15-month-old boy presented with his mother to the local emergency department following an unwitnessed fall from

No conflicts of interest to disclose.

* Corresponding author.

E-mail addresses: Heyworth.paul@gmail.com (P.B. Heyworth), Muddassir.Rashid@health.qld.gov.au (M. Rashid).<https://doi.org/10.1016/j.radcr.2018.10.006>

1930-0433/© 2018 The Authors. Published by Elsevier Inc. on behalf of University of Washington. This is an open access article under the CC BY-NC-ND license. (<http://creativecommons.org/licenses/by-nc-nd/4.0/>)

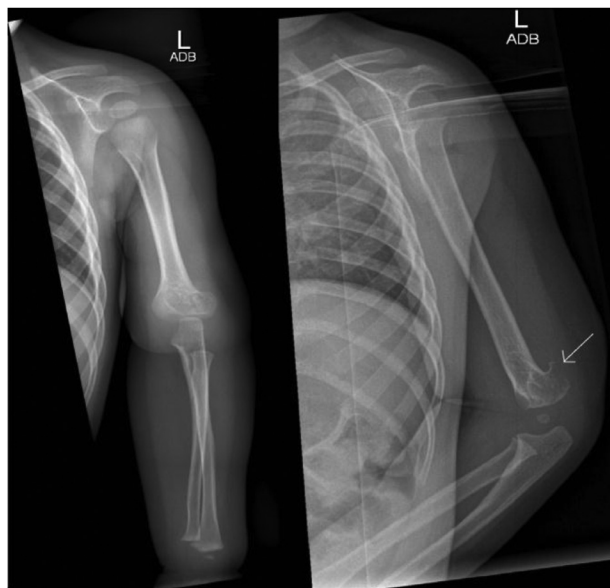


Fig. 1 – AP and lateral view on day of injury—there is a bone exostoses arising from the posterior aspect of the left lateral epicondyle consistent with a pedunculated osteochondroma. Anatomy is otherwise unremarkable.

the back of a sofa ~1.5 m in height. He was beside his mother on the sofa and she did not notice or hear the fall but looked back and noticed he was not there. The patient was initially quiet, however by the time they presented to the ED (~1 hour after the incident), he was back to his usual self.

He was born at 36 weeks via emergency caesarean for pre-eclampsia. He was developmentally up to date and had no significant medical history. On review, patient was moving all limbs, however had obvious swelling and pain in his left arm overlying the lateral epicondyle.

An x-ray of the left humerus and elbow was ordered, which showed no acute fracture, however an exostoses of the lateral distal humerus was noted (Fig. 1). He was discharged with outpatient follow-up arranged for 10 days in fracture clinic.

At the 10 day review he was back to his baseline and there were no concerns. He was booked for 3 month review with x-ray. Interestingly, the x-ray at this appointment showed the osteochondroma had fully resolved (Fig. 2). He was pain free at his elbow and had full range of motion. He was again seen at 6 months with an x-ray which showed no further osteochondroma (Fig. 3).

He was lost to follow-up however re-referred 5 years later after his GP noted he was lost to follow-up. At this review the patient was using his arm normally and had no complaints. The x-ray showed no lesion (Fig. 4).

Discussion

Osteochondromas are the most common benign bone tumors, with the majority of solitary lesions appearing at the humerus (26%), femur (30%), and tibia (43%) [1]. Whilst there are case

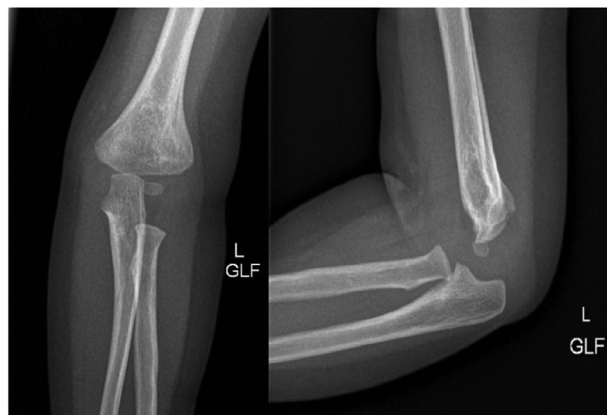


Fig. 2 – Three months postinjury. No further osteochondroma seen.

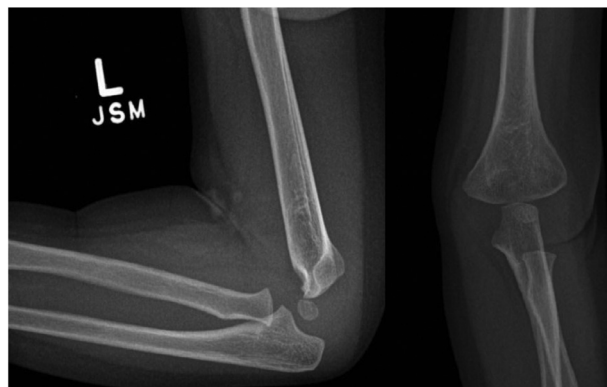


Fig. 3 – Six months postinjury (3 month interval scan)—again no osteochondroma identified.

reports describing spontaneous regression of these lesions, it is a rare documented entity. This may be due to the asymptomatic nature of the condition, with osteochondromas so infrequently presenting with symptoms [3].

The cause as to why some osteochondromas will spontaneously regress is not yet known. Some proposed theories are: presence of a fracture through the exostoses [8], persistent pressure from an external source (in the reported case—a pseudoaneurysm) [9], or the osteochondroma growth ceases before somatic growth ceases, thereby allowing the adjacent bone to incorporate the osteochondroma into its growth [10].

Of the current documented cases, the average age of diagnosis was 8.8 years old with a range of 5–15. In addition, it took an average of 2.8 years (range 0.16–6) before the lesion had fully regressed [10]. With the patient described, the regression of the osteochondroma occurred after a trauma to the site of the lesion and took less than 3 months to resorb. Whilst it is possible that somatic growth was occurring at a rate greater than that of the osteochondroma, it is not feasible to suggest that this was the only cause for disappearance of the lesion with serial scanning. It is theorized that the trauma to the arm has caused a disturbance in the osteochondroma's modeling process, whether from disruption to the blood

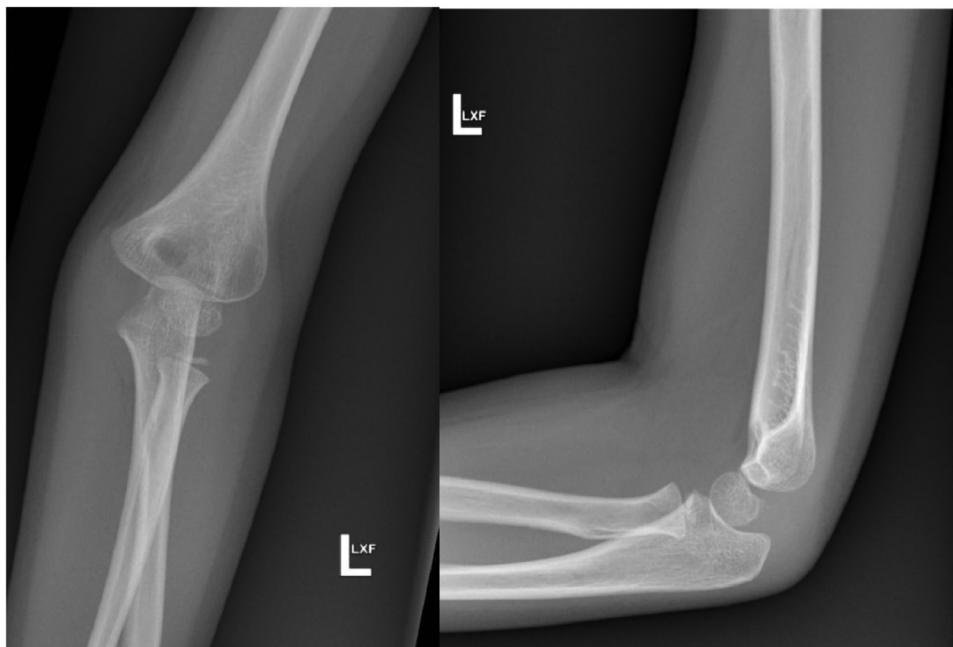


Fig. 4 – Interval scan at 5 year old reveals no recurrence of the osteochondroma and normal development of the left elbow.

supply to the lesion or occult fracture not seen on x-ray imaging, thereby disrupting the bone modeling process, which has been previously described by Nikolaos Et Al [7]. There are no cases recorded of regression of these lesions at such a young age and thus the process for regression may be different to prior case reports when the skeleton is so immature and bone growth is rapid.

In conclusion, we have described a case of spontaneous resorption of an osteochondroma at the young age of 15 months following trauma to the affected limb.

Supplementary materials

Supplementary material associated with this article can be found, in the online version, at [doi:10.1016/j.radcr.2018.10.006](https://doi.org/10.1016/j.radcr.2018.10.006).

REFERENCES

- [1] Kitsoulis P, Galani V, Stefanaki K, Paraskevas G, Karatzias G, Agnantis NJ, et al. Osteochondromas: review of the clinical, radiological and pathological features. *In Vivo* 2008;22(5):633–46.
- [2] Khurana J, Abdul-Karim F, Bovée JVMG. Osteochondroma. In: Fletcher CDM, Unni KK, Mertens F, editors. *World Health Organization classification of tumours pathology and genetics of tumours of soft tissue and bone*. Lyon: IARC Press; 2002. p. 234–6.
- [3] Murphey MD, Choi JJ, Kransdorf MJ, Flemming DJ, Gannon FH. Imaging of osteochondroma: variants and complications with radiologic-pathologic correlation. *Radiographics* 2000;20(5):1407–34.
- [4] Cardelia JM, Dormans JP, Drummond DS, Davidson RS, Duhaime C, Sutton L. Proximal fibular osteochondroma with associated peroneal nerve palsy: a review of six cases. *J Pediatr Orthop* 1995;15:574–7.
- [5] Passanise AM, Mehlman CT, Wall EJ, et al. Radiographic evidence of regression of a solitary osteochondroma: a report of 4 cases and a literature review. *J Pediatr Orthop* 2011;31:312–16.
- [6] Lee AK, Woll AK, Malone WJ, Mirenda WM. Trauma-induced resolution of solitary osteochondroma of the distal femur. *Orthopedics* 2016;39(5):e1001–4.
- [7] Sferopoulos Nikolaos K. Complicated fracture and resorption of an osteochondroma. *Br J Med Med Res* 2014;4(8):1719–28.
- [8] Choi J-Y, Hwan Hong S, Kim H-S, Chang CB, Joon Lee Y, Sik Kang H. Resorption of osteochondroma by accompanying pseudoaneurysm. *AJR. Am J Roentgenol* 2005;185:394–6.
- [9] Paling MR. The “disappearing” osteochondroma. *Skeletal Radiol* 1983;10:40–2.
- [10] Stitzman-Wengrowicz ML, Pretell-Mazzini J, Dormans JP, Davidson RS. Regression of a sessile osteochondroma: a case study and review of the literature; 2018.