

Clinical Article

Y-Stenting Endovascular Treatment for Ruptured Intracranial Aneurysms : A Single-Institution Experience in Korea

Woo Joo Lee, M.D., Chun-Sung Cho, M.D., Ph.D.

Department of Neurosurgery, Dankook University College of Medicine, Cheonan, Korea

Objective : Stent-assisted coiling on intracranial aneurysm has been considered as an effective technique and has made the complex aneurysms amenable to coiling. To achieve reconstruction of intracranial vessels with preservation of parent artery the use of stents has the greatest potential for assisted coiling. We report the results of our experiences in ruptured wide-necked intracranial aneurysms using Y-stent coiling.

Methods : From October 2003 to October 2011, 12 patients (3 men, 9 women; mean age, 62.6) harboring 12 complex ruptured aneurysms (3 middle cerebral artery, 9 basilar tip) were treated by Y-stent coiling by using self-expandable intracranial stents. Procedural complications, clinical outcome, and initial and midterm angiographic results were evaluated. The definition of broad-necked aneurysm is neck diameter over than 4 mm or an aneurysm with a neck diameter smaller than 4 mm in which the dome/neck ratio was less than 2.

Results : In all patients, the aneurysm was successfully occluded with no apparent procedure-related complication. There was no evidence of thromboembolic complication, arterial dissection and spasm during procedure. Follow-up studies showed stable and complete occlusion of the aneurysm in all patients with no neurologic deficits.

Conclusion : The present study did show that the Y-stent coiling seemed to facilitate endovascular treatment of ruptured wide-necked intracranial aneurysms. More clinical data with longer follow-up are needed to establish the role of Y-stent coiling in ruptured aneurysms.

Key Words : Intervention · Stent · Subarachnoid hemorrhage.

INTRODUCTION

Despite rapid technological advances in endovascular technology and development of coil engineering, complex aneurysms have remained difficult because of their unfavorable geometry, which reduces the possibility of complete elimination of aneurysm from the parent artery. Many devices and techniques have been introduced to overcome these limitations including three-dimensional (3D) coils, techniques using multiple catheters, and balloon remodeling technique, etc^{8,9,14}.

Before the device of self-expandable intracranial stent like Neuroform (Boston Scientific/Target, Fremont, CA, USA) which has been available in Korea after October 2003, coronary stents were used for the treatment of intracranial complex aneurysms before available. The self-expandable stent has been applied frequently and makes the complex aneurysm treatment possible

with endovascular way. In selected cases, stent-assisted coiling offers an advantage over traditional coiling and balloon remodeling technique. The stent can not only prevent coil herniation but provide as a matrix of durable membrane formation in the lumen of aneurysm neck.

Stent-assisted coiling was first reported by Higashida et al.⁵ several years ago and it was admitted as a relative new idea in endovascular treatment. When this technique was introduced, the utility of technique was restricted by the technical limitation and commercial availability. Furthermore, some broad neck aneurysms, such as the ones located at bifurcation, are not amenable to treatment with a single stent. There is limited information on the use and efficacy of stent treatment of such aneurysms. In case of the bifurcation broad neck aneurysm, Y-configuration using two stents often is necessary to cover the full lumen of the aneurysm neck for preserving the patency of the parent vessel.

• Received : February 25, 2012 • Revised : May 14, 2012 • Accepted : August 19, 2012

• Address for reprints : Chun-Sung Cho, M.D., Ph.D.

Department of Neurosurgery, Dankook University College of Medicine, San 29 Anseo-dong, Cheonan 330-714, Korea

Tel : +82-41-550-6369, Fax : +82-41-552-6870, E-mail : babyface@dankook.ac.kr

• This is an Open Access article distributed under the terms of the Creative Commons Attribution Non-Commercial License (<http://creativecommons.org/licenses/by-nc/3.0>) which permits unrestricted non-commercial use, distribution, and reproduction in any medium, provided the original work is properly cited.

The present report demonstrates whom an acutely ruptured, bifurcation aneurysm was treated by means of a Y-stent coiling.

MATERIALS AND METHODS

Patients

Between October 2003 and October 2011, a total of 255 aneurysms (191 ruptured; 64 unruptured) were treated using the stent-assisted coiling. We retrospectively analyzed the files of all patients with ruptured wide-necked aneurysms (dome/neck ratio <2) who treated with stent-assisted coiling. Twelve patients with ruptured intracranial aneurysms were selected for this study, 3 men and 9 women, underwent placement of Y-stent for appropriate aneurysms with self expandable Neuroform stent. All endovascular interventions were carried out on the same or the next day of admission to out hospital, depending on referral from other hospitals (within 24 hours after subarachnoid hemorrhage). Eventually, 12 aneurysms in total in 12 patients were included in this study. Ages ranged from 45 to 79 years with a mean 62.7 years. Eight of aneurysms were basilar tip in location; the remaining four were middle cerebral artery bifurcation aneurysms. Aneurysms ranged in size 2 to 14 mm. Overall, follow-up ranged from 6 to 18 months, with a mean of 10 months.

Follow-up digital subtraction angiography (DSA) images were obtained in the previous working projection and in conventional frontal and lateral projections. Rotational angiography was performed to detect any change in angiographic outcome. DSA also was performed at the projections determined optimal by rotational angiography in all patients at 6 month and/or 12 months from the first procedure.

Clinical evaluation was performed in all patients before their discharge from the hospital and clinical modified Rankin Scale (mRS) scores were recorded at 24 hours post-procedure and 2 weeks, 6 months, and last follow-up period.

Technique

Patients were not pretreated with antiplatelet drugs (Patients were started on 75 mg of clopidogrel and 300 mg of aspirin on the same evening or the next morning if the intervention was performed in the evening or during the night). The procedures were performed under intravenous sedation using propofol and alfentanil, which is the general anesthetic method for endovascular aneurysm coiling in this institute. After completion of the diagnostic angiogram, patients were anticoagulated with heparin adequate to keep the activated clotting time longer than 2-2.5 times the baseline value. The patients received 5000 IU of heparin, the stent was placed in the parent artery covering the aneurysmal neck, and the aneurysm was microcatheterized and embolized with detachable coils.

A self-expanding stent (Neuroform) was prepared by attaching the stent delivery catheter and stabilizer to heparinized saline flushed, and advancing the stabilizer into the delivery catheter proximal to the stent. All self-expandable stents were oversized

by 0.5 mm compared with the parent artery. The initial stent deployed from the distal part of aneurysm to proximal parent artery of aneurysm. The second stent was advanced over the wire through interstices of the initial stent and the proximal portion overlapping the first stent in the proximal parent artery.

The stents were deployed over the neck of the aneurysm in a satisfactory position. After successful stent placement, coiling was performed with multiple coils through a microcatheter (Excelsior SL-10; Boston Scientific, Fremont, CA, USA) placed in the aneurysm through the mesh of the stent. In short-duration interventions (1-2 hours), the patients received an additional 2000 IU of heparin upon completion and longer-intentions, the patients received an additional 2000 IU of heparin every 2 hours. For daily antiplatelet medication after stent deployment, 2 drugs (aspirin, 100 mg and clopidogrel, 75 mg) were used for the first 3 months, and then aspirin at 100 mg was continued.

Homeostasis was achieved by use of an arterial closure device and heparin was not reversed at the end of the procedure. Follow-up angiograms are typically performed between 6 and 12 months.

RESULTS

Basic demographic data, aneurysmal characteristics, and initial angiographic outcomes after embolization are summarized in Table 1. Twelve patients were treated with Y-stent coiling. According to the Hunt and Hess (H-H) grade, 3 patients were classified as grade II, 9 patients as grade III. Selective embolization was successfully performed in all patients and resulted in good clinical outcomes. Stent deployments were technically successful in all patients. There was no evidence of thromboembolic complication, arterial dissection and spasm including aneurysm rupture during procedures. There was no evidence of flow compromise in the stent or distal territory at the time of latest follow-up.

One patient with a poor pre-procedural condition died as a consequence of severe vasospasm within 12 days after the embolization procedure. Each patient presented mRS score 0 in 3, score 1 in 2, score 2 in 5, score 3 in 1 and score 6 in 1 (Table 1).

Illustrative cases

Case 1

A 62-year-old woman was admitted with a subarachnoid hemorrhage (SAH) and intraventricular hemorrhage. The clinical condition at presentation was equivalent to grade III of the H-H grading scale. On the first day in the hospital, diagnostic cerebral angiography revealed a basilar tip aneurysm, measuring approximately 2x2 mm in size (Fig. 1). Due to the size, location of the aneurysm and the poor clinical status of the patient, surgical clipping were not considered feasible. Subsequently, we elected to proceed with basilar artery to posterior cerebral artery (PCA) stent placement to reconstruct the basilar artery aneu-

Table 1. Characteristics of 12 ruptured aneurysms treated with Y-stent coiling

Case	Age	Sex	Location	H-H grade	Fisher grade	Stent size (mm)	Angiographic results		mRS last	Cx last
							Initial	F/U		
1	62	F	Basilar tip	3	3	2.5×20/2.5×20	Class 1	Class 1	0	None
2	65	F	Basilar tip	3	3	2.5×15/2.5×20	Class 1	Class 1	2	None
3	65	M	MCA	3	4	2.5×20/2.5×20	Class 1	Class 1	2	None
4	45	F	Basilar tip	2	3	2.5×20/2.5×20	Class 1	Class 1	2	None
5	66	M	Basilar tip	3	3	2.5×15/2.5×20	Class 1	Class 1	3	None
6	70	F	MCA	2	3	2.5×20/2.5×20	Class 1	Class 1	0	Dies
7	79	F	Basilar tip	3	3	2.5×15/2.5×20	Class 1	-	6	None
8	50	M	MCA	2	3	2.5×20/2.5×20	Class 1	Class 1	0	None
9	59	F	Basilar tip	3	4	2.5×20/2.5×20	Class 1	Class 1	2	None
10	54	F	Basilar tip	3	3	2.5×15/2.5×20	Class 1	Class 1	2	None
11	68	F	Basilar tip	3	3	2.5×20/2.5×20	Class 1	Class 1	1	None
12	69	F	MCA	3	3	2.5×20/2.5×20	Class 1	Class 1	1	None

Class 1 : complete occlusion, Class 2 : remnant neck (nearly complete occlusion). H-H grade : Hunt and Hess grade, mRS : modified Rankin Scale, Cx : complication, MCA : middle cerebral artery

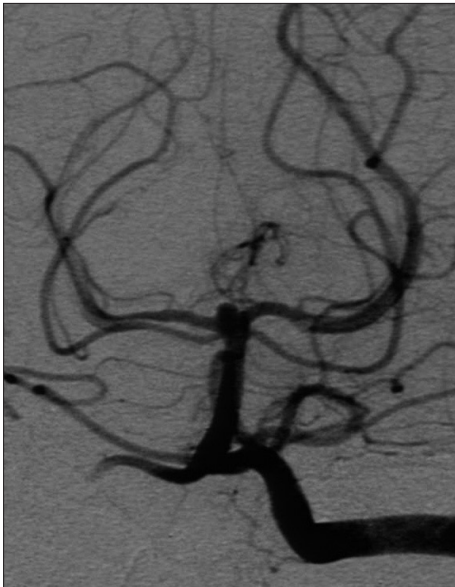

Fig. 1. Working view of the left vertebral artery angiogram showing the aneurysm at the basilar tip prior to endovascular intervention.

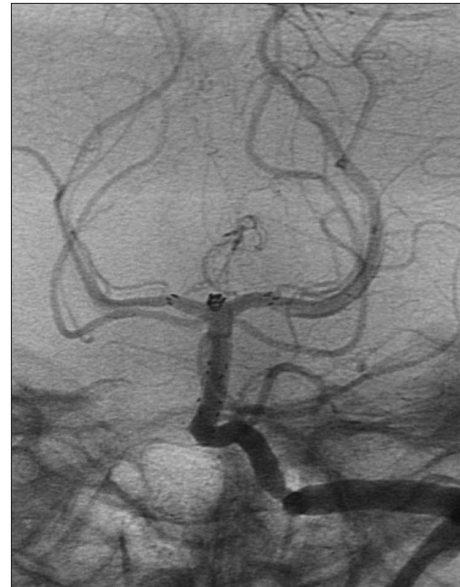

Fig. 2. Immediately post-treatment, working unsubtracted view of the left vertebral artery angiogram showing optimal deployment and no contrast dye filling in aneurysm sac after Y-stenting coiling.

aneurysm base. 2.5×20 mm and 2.5×20 mm Neuroform stent placed was 20 mm in length and was deployed from the left PCA into the basilar artery. The microwire was pulled retrograde into basilar artery, then advanced through the stent struts. The second, 20 mm stent, was advanced over the wire through the first stent within the basilar artery then through the struts of the left PCA stent and into the right PCA.

Following placement of the stents, the aneurysm was embolized with one ultra-soft coil (Fig. 2). After the procedure, the patient was taken to the intensive care unit (ICU). She was maintained on oral antiplatelet agents for two weeks and heparinization for two days. The patient was discharged from the hospital without any neurological defects on the 21th day of hospitalization. A follow-up angiogram 6 months later demonstrated stable com-

plete occlusion (Fig. 3).

Case 8

A 50-year-old man presented with SAH was admitted in H-H Grade II. 3D cerebral angiography showed a small aneurysm of right middle cerebral artery (MCA) aneurysm (Fig. 4). Because of the small size and intolerable dome and neck ratio, we decided to place a stent before placing the coil. Pretreatment with antiplatelet agents was not done. A 2.5×20 mm Neuroform stent was deployed, followed by second stent was deployment to reconstruct the MCA aneurysm base. After stent placement, coil embolization was performed with detachable coils through a microcatheter placed in the aneurysm through the interstices of the stent. An unsubtracted image shows the stent and coil in

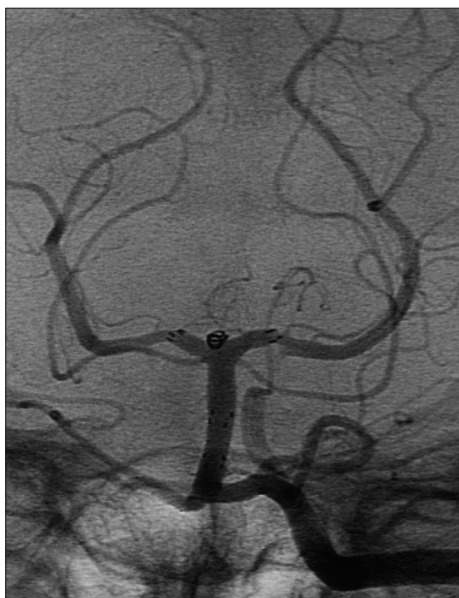

Fig. 3. Follow-up angiography was performed 12 months after treatment. Working unsubtracted view of left vertebral artery angiography shows a no interval change after initial treatment.

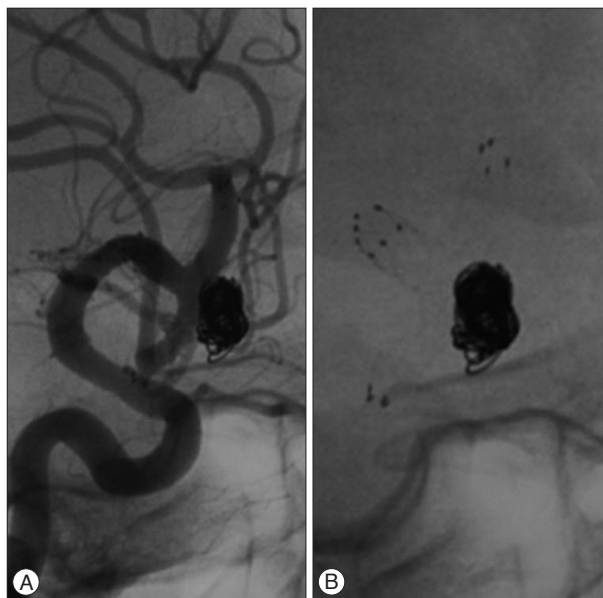


Fig. 5. A : Immediately post treatment, working view unsubtracted right ICA angiography demonstrating a complete embolization. B : Working view demonstrating an optimal Y-stent deployment.

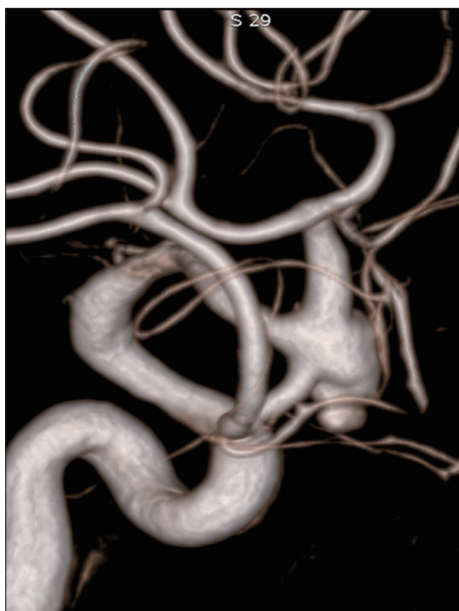


Fig. 4. Three dimensional (3D) cerebral angiography working views shows a middle cerebral artery bifurcation aneurysm in the right internal carotid artery.

place (Fig. 5). Follow-up angiogram 12 months later demonstrated no interval change (Fig. 6).

DISCUSSION

The endovascular treatment of intracranial aneurysms with detachable coils has developed into a widely used and effective technique. Despite increasing clinical experience and technological improvements, endovascular treatment still has inherent risks of morbidity and mortality. In particular, this treatment is

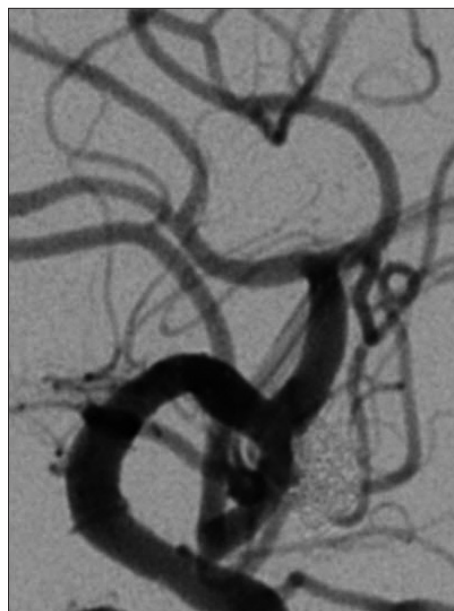

Fig. 6. Follow-up angiography was performed 13 months after treatment. Working unsubtracted view of right ICA angiography shows a no interval change after initial treatment.

not useful option for the treatment of certain types of complicated aneurysms : wide-necked aneurysms are still complicated to embolize because of the risk of coil migration or coil protrusion into the parent vessel. These aneurysms unfavorable for simple coiling can be embolized by various methods, besides stent-assisted coiling.

Development of a flexible and self-expandable intracranial stents has increased the options for the treatment of complex aneurysms. The efficacy and safety of intracranial stents for endovascular treatment of broad neck intracranial aneurysms

have been evaluated in several studies^{1,2,11}. In associated with coiling, the development of a stent within the parent vessel has some advantage : once a stent is deployed across the aneurysmal neck, coils can be placed within the aneurysmal sac more easily with less concern of coil migration and it enables dense packing in aneurysm; it induces significant intraaneurysmal flow modification that may lead to spontaneous thrombosis, and it may provide a framework for endothelial growth resulting in permanent separation of the aneurysm from parent vessel lumen⁵. Accordingly, these additional effects of stents may enhance the durability of coiled aneurysms.

An increasing number of publications have reported on the use of the self-expandable stent in treatment of wide-necked intracranial aneurysms^{4,5,13}. While most reports expressing a favorable disposition, it seems that the self expandable stent is considered as a very useful device that facilitates the endovascular treatment of unruptured wide-necked aneurysms, and the safety of the procedure during acute subarachnoid hemorrhage (SAH) is still open to discussion.

Additionally, there is limited knowledge of effects of Y-stent coiling on the ruptured aneurysms. It is very interesting that some reports on unconventional use of the Neuroform stent have provided intelligent technical solutions to difficult endovascular cases.

Sani et al.¹² and Perez-Arjona and Fessler¹⁰ reported on a Y-configuration deployment of 2 Neuroform stents applied in the treatment of a unruptured wide-necked middle cerebral artery and basilar tip aneurysm.

In theory, aneurysm base Y-stenting reconstruction can cause blood to become stagnant and lead to progressive thrombosis and the promotion of endothelialization that can help the aneurysmal neck close. Accordingly, these additional effects of stents may enhance the durability of coiled aneurysm. However, there are very few reports in the literature describing the feasibility, use a safety of the Y-stent coiling in ruptured aneurysms. Clinically, it is unclear whether these effects really improve long-term outcome, especially when one consider that the stents designed for neck modeling have open strut. Thus, we conducted this study to determine the actual effect of a Y-stent coiling in ruptured wide-necked intracranial aneurysm.

Cekirge et al.² and Chow et al.³ reported the impact of this technique would be important in endovascular treatment of bifurcation aneurysms with a very wide neck or with no definable neck, large or giant aneurysms with mass effect, and those too small to be packed. The major current concern is the small size of the parent vessel relative to the diameter of the smallest available stent. As we reported in results, aneurysm base Y-stenting reconstruction can be helpful to treat selected case of wide neck aneurysm, such as complex MCA bifurcation aneurysm or basilar top aneurysm, even though all wide neck aneurysms not be indicated.

Most authors report that the premedication of antiplatelet drugs have been strongly recommended to prevent the throm-

boembolic events enhanced by stent positioning. But, in the cases of ruptured aneurysms, the procedures should be performed as early as possible in most cases. Katsaridis et al.⁷ reported a series of 44 patients treated with stent and coiling for ruptured intracranial aneurysms who were not pretreated with antiplatelet agents. Satisfactory aneurysm occlusion was achieved in 94.4% of cases, whereas there was no aneurysm bleeding, and no aneurysm recanalization or thromboembolic events have been reported. Ries et al.¹¹ presented peri-operative infusion of acetylsalicylic acid has been shown to decrease the rate of operative bleeding rate and is advocated in the endovascular treatment of aneurysms, including ruptured aneurysm. The optimal antiplatelet medication during acute-phase series is needed to evaluate the safety and efficacy of stent-assisted coiling in acute ruptured aneurysms.

Stent has some limitations⁹. When stents are inserted in arteries with important perforating branches can also elicit complications related to the untoward occlusion of some of these perforating arteries by the stent strut. Also, stent deployed across an artery with angulations exerts a certain longitudinal rebounding force and could straighten the angle of the parent vessel. This phenomenon could have adverse consequences, such as proximal or distal arterial kinking, dissection, asymptomatic mechanical strain on the aneurysm, or increased compliance mismatch at the stent ends, which might cause marginal or in-stent stenosis especially, in stents overlapping state. Last, intracranial stent is considered to be thrombogenic until the stent has been covered by endothelialization and the normal intrinsic fibrinolytic activity of the endothelium has renewed⁶.

The current report has some limitations. There were relatively short term clinical and angiographic follow-up periods and cases were limited in numbers. Therefore, further follow-up and more experience are necessary to determine long-term results.

CONCLUSION

Our findings suggest that Y-stent placement provides better angiographic outcomes for ruptured wide-necked aneurysms with an unfavorable configuration for coiling; especially, in bifurcation aneurysm. More clinical data with long follow-up are needed to help establish the role of Y-stenting in ruptured wide-necked aneurysms.

• Acknowledgements

The present research was conducted using the research fund of Dankook University in 2009.

References

1. Benitez RP, Silva MT, Klem J, Veznedaroglu E, Rosenwasser RH : Endovascular occlusion of wide-necked aneurysms with a new intracranial microstent (Neuroform) and detachable coils. *Neurosurgery* 54 : 1359-1367; discussion 1368, 2004
2. Cekirge HS, Yavuz K, Geyik S, Saatci I : A novel "Y" stent flow diversion

- technique for the endovascular treatment of bifurcation aneurysms without endosaccular coiling. *AJNR Am J Neuroradiol* 32 : 1262-1268, 2011
3. Chow MM, Woo HH, Masaryk TJ, Rasmussen PA : A novel endovascular treatment of a wide-necked basilar apex aneurysm by using a Y-configuration, double-stent technique. *AJNR Am J Neuroradiol* 25 : 509-512, 2004
 4. Fiorella D, Albuquerque FC, Han P, McDougall CG : Preliminary experience using the Neuroform stent for the treatment of cerebral aneurysms. *Neurosurgery* 54 : 6-16; discussion 16-17, 2004
 5. Higashida RT, Smith W, Gress D, Urwin R, Dowd CF, Balousek PA, et al. : Intravascular stent and endovascular coil placement for a ruptured fusiform aneurysm of the basilar artery. Case report and review of the literature. *J Neurosurg* 87 : 944-949, 1997
 6. Hsu SW, Chaloupka JC, Feeke JA, Cassell MD, Cheng YF : In vitro studies of the neuroform microstent using transparent human intracranial arteries. *AJNR Am J Neuroradiol* 27 : 1135-1139, 2006
 7. Katsaridis V, Papagiannaki C, Violaris C : Embolization of acutely ruptured and unruptured wide-necked cerebral aneurysms using the neuroform2 stent without pretreatment with antiplatelets : a single center experience. *AJNR Am J Neuroradiol* 27 : 1123-1128, 2006
 8. Kwon OK, Kim SH, Oh CW, Han MH, Kang HS, Kwon BJ, et al. : Embolization of wide-necked aneurysms with using three or more microcatheters. *Acta Neurochir (Wien)* 148 : 1139-1145; discussion 1145, 2006
 9. Moret J, Cognard C, Weill A, Castaings L, Rey A : [Reconstruction technique in the treatment of wide-neck intracranial aneurysms. Long-term angiographic and clinical results. Apropos of 56 cases]. *J Neuroradiol* 24 : 30-44, 1997
 10. Perez-Arjona E, Fessler RD : Basilar artery to bilateral posterior cerebral artery 'Y stenting' for endovascular reconstruction of wide-necked basilar apex aneurysms : report of three cases. *Neurol Res* 26 : 276-281, 2004
 11. Ries T, Grzyska U, Fiehler J : Antiaggregation before, during, and after coiling of unruptured aneurysms : growing evidence between scylla and charybdis. *AJNR Am J Neuroradiol* 29 : e33, 2008
 12. Sani S, Lopes DK : Treatment of a middle cerebral artery bifurcation aneurysm using a double neuroform stent "Y" configuration and coil embolization : technical case report. *Neurosurgery* 57 : E209; discussion E209, 2005
 13. Sedat J, Chau Y, Mondot L, Vargas J, Szapiro J, Lonjon M : Endovascular occlusion of intracranial wide-necked aneurysms with stenting (Neuroform) and coiling : mid-term and long-term results. *Neuroradiology* 51 : 401-409, 2009
 14. Vallée JN, Pierot L, Bonafé A, Turjman F, Flandroy P, Berge J, et al. : Endovascular treatment of intracranial wide-necked aneurysms using three-dimensional coils : predictors of immediate anatomic and clinical results. *AJNR Am J Neuroradiol* 25 : 298-306, 2004