

## CASE REPORT

## Surgical Treatment of a Patient With Nutcracker Syndrome via Transposition of the Left Renal Vein

Borislav Denchev<sup>a</sup>, Elena Domuschieva<sup>a,\*</sup>, Galin Jelev<sup>a</sup>, Valentin Govedarski<sup>b</sup>, Todor Zahariev<sup>b</sup>

<sup>a</sup>Virgin Mary University Hospital, Clinic of Vascular Surgery, Bourgas, Bulgaria

<sup>b</sup>Saint Ekaterina University Hospital, Clinic of Vascular Surgery, Sofia, Bulgaria

**Introduction:** Nutcracker syndrome (NCS) is caused by compression of the left renal vein (LRV) between the aorta and the superior mesenteric artery (SMA) where it passes in the fork formed at the bifurcation of these arteries. NCS leads to LRV hypertension, resulting in left flank and abdominal pain, with or without haematuria and pelvic ureteral varices.

**Report:** The patient was a young female with diagnostic criteria of NCS, with severe clinical manifestations. The patient underwent transposition of the LRV approximately 3.0 cm below the original anatomic site and was anastomosed to the inferior vena cava (IVC) outside the meso-aortic compression zone.

**Conclusion:** Although NCS is not as common as other clinical scenarios, it may be encountered by physicians in a variety of disciplines, and can cause substantial morbidity and mortality rates. This report addresses the surgical approach used in a particular case, as well as the possible complications and outcomes if not treated in due time.

© 2018 The Authors. Published by Elsevier Ltd on behalf of European Society for Vascular Surgery. This is an open access article under the CC BY-NC-ND license (<http://creativecommons.org/licenses/by-nc-nd/4.0/>).

Article history: Received 6 June 2018, Revised 23 September 2018, Accepted 28 September 2018,

**Keywords:** Nutcracker syndrome, Renal vein, Haematuria, Flank pain

### INTRODUCTION

Nutcracker syndrome (NCS), also known as left renal vein (LRV) entrapment syndrome, was first defined anatomically by Grant in 1937 as: "... the left renal vein, as it lies between the aorta and superior mesenteric artery, resembles a nut between the jaws of a nutcracker." Meso-aortic compression of the LRV produces LRV hypertension, and this causes left flank pain, haematuria, and pelvic ureteral varices.<sup>1,2</sup>

In early reports, NCS was regarded as a rare clinical entity. Now, an increasing number of patients complaining of haematuria or proteinuria and subsequently treated for nephritis or nephrosis are being diagnosed as having NCS. The exact prevalence of NCS is unknown, but may be slightly higher in females. NCS can be found at any time between childhood and old age, with a relatively high prevalence in young and middle aged adults. During puberty, with the rapid increase in body height and the maturation of the vertebral bodies, the angle between the SMA and aorta narrows. A low body mass index has been shown to correlate positively with NCS.<sup>3</sup>

The presence of gonadal vein involvement is a hallmark feature of the so called "pelvic congestion syndrome" (PCS), which manifests as left sided varicocele in young men and chronic lower abdominal or pelvic pain and dyspareunia in middle aged women.<sup>4</sup> Although primarily a vascular disorder, its manifestations are predominantly urological or gynaecological.<sup>5</sup>

### CASE REPORT

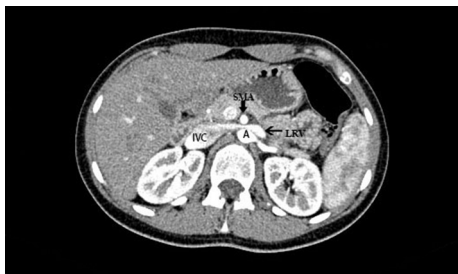The patient was a 19 year old female with an asthenic body habitus, who had medical history of left flank pain since the age of 10, with numerous visits to the emergency room (ER) and examination by various specialists but no conclusive diagnosis. At the time of admission she complained of gross, painful haematuria, which had occurred intermittently for 6 months and was further aggravated by physical exercise. The haematuria was accompanied by left flank and abdominal pain. Blood tests and urine analysis were within the normal limits. Diagnostic studies were performed to investigate the idiopathic haematuria. Cystoscopy revealed bloody urine draining through the opening of the left ureter. Computed tomography angiography (CTA) of the abdomen demonstrated meso-aortic compression of the LRV (Fig. 1), and the patient was diagnosed with anterior NCS. However, diagnosis of NCS can still be challenging to confirm based solely on imaging, therefore the presenting clinical signs and symptoms are paramount when considering management options.<sup>2</sup> Because of the patient's young age and

\* Corresponding author.

E-mail address: [zoia\\_089@yahoo.com](mailto:zoia_089@yahoo.com) (Elena Domuschieva).

2405-6553/© 2018 The Authors. Published by Elsevier Ltd on behalf of European Society for Vascular Surgery. This is an open access article under the CC BY-NC-ND license (<http://creativecommons.org/licenses/by-nc-nd/4.0/>).

<https://doi.org/10.1016/j.ejvssr.2018.09.003>



**Figure 1.** Pre-operative abdominal CT scan showing compression of the left renal vein (LRV) between the superior mesenteric artery (SMA) and the abdominal aorta (A).

asthenic body habitus, a decision was made to manage this with open surgery.

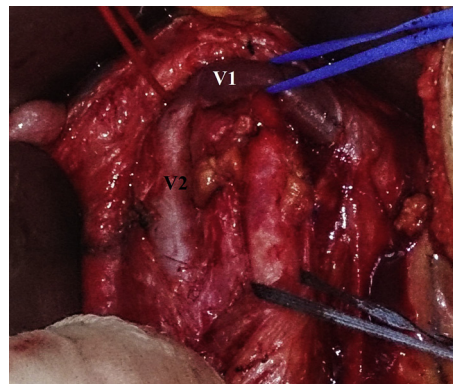
In the operating theatre, a trans-abdominal midline incision was made, the small and large bowel were packed away, and the retroperitoneum was opened in the midline, inferior to the transverse mesocolon. A tense LRV was found coursing in front of the abdominal aorta, with a palpable haemodynamically significant thrill. Severe hypoplasia of the abdominal aorta was concluded. Systemic heparin administration (5000 IU) was applied before clamping. A thorough peri-aortic, peri-caval, and mesenteric debridement was performed. The LRV was completely mobilised (Fig. 2). A Cooley-Satinsky side biting clamp was applied to the inferior vena cava (IVC) across the LRV confluence and the LRV was excised from its entry site on the IVC. Further along, the LRV was re-anastomosed to the left lateral aspect of the IVC 3.0 cm below the original anatomic site in a tension free end-to-side manner using continuous 4-0 prolene sutures, away from the SMA (Fig. 3).

The proximal opening in the IVC was closed using continuous 3-0 prolene sutures. Successful declamping of the reconstruction followed, with adequate venous supply to the left kidney. The palpable thrill from the LRV disappeared immediately after the procedure. The patient regained haemodynamic stability with no post-operative complications. By post-operative day (POD) 7, laboratory findings had decreased to within the normal range. The patient was discharged with no further complaints. On POD 22, CT scan (Fig. 4), clinical examinations, and blood tests were performed. No complications were detected whatsoever. The haematuria resolved within 2 months. Post-operative recovery was uneventful and the patient resumed full exercise after 3 months. At 36 months of follow-up the patient remained symptom-free.

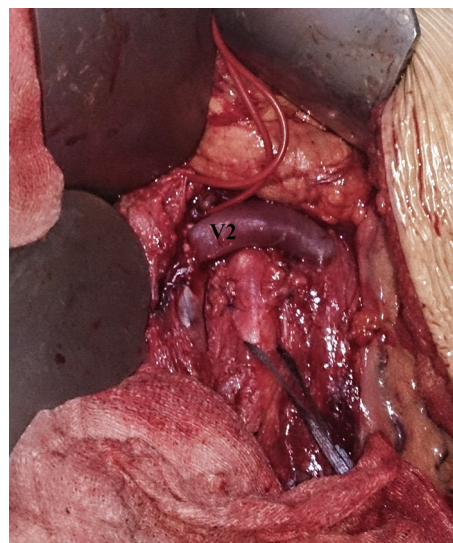
## DISCUSSION

NCS remains an under diagnosed condition. In children, it can resolve spontaneously. However, without treatment it can predispose to LRV thrombosis and resultant kidney damage. In cases of NCS presenting with haematuria, it can lead to anaemia requiring blood transfusion, with its associated complications.<sup>2</sup>

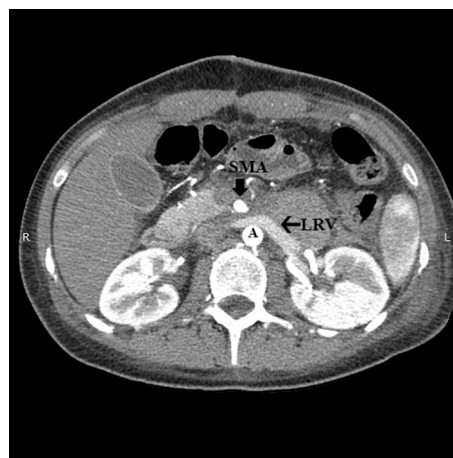
It was not until recently that communications between the dilated venous sinuses and the adjacent renal calyces,



**Figure 2.** Pre-reconstruction status — V1.



**Figure 3.** Post-reconstruction status. The left renal vein was transposed (V2) to 3.0 cm below the original anatomic site (V1).



**Figure 4.** Post-operative CT scan of the abdomen, showing no compression of the LRV.

as an explanation for the haematuria, were carefully documented.<sup>1</sup> The treatment of NCS remains a controversial topic, ranging from surveillance to nephrectomy.<sup>6</sup> However, surgery may be considered for gross haematuria

(especially if recurrent), for severe symptoms, and for ineffective conservative measures after 24 months in patients aged <18 years, and after 6 months in adults.

Both LRV transposition and autotransplantation are optimal management options for NCS. Currently, transposition is considered to be the most commonly used surgical management approach.<sup>2</sup> The consequences of transposing the SMA to an alternative origin, such as superior mesenteric arterial thrombosis, would be devastating.<sup>4,5</sup>

An asthenic body habitus with paucity of retroperitoneal fat is postulated to result in LRV compression by narrowing the aorto-mesenteric angle and/or stretching the LRV secondary to ptosis of the kidney. Ultimately, the aim of any intervention for NCS is to reduce LRV hypertension.<sup>7</sup> The narrow angle between the SMA and the aorta can cause either anterior NCS or aorto-mesenteric compression syndrome, also known as Wilkie's syndrome, with further compression of the third part of the duodenum. However, in this particular case, there was no sign of compression of the duodenum on the pre-operative CT scan images, nor did the patient complain of epigastric pain, nausea, or vomiting, and she had no weight loss prior to hospitalisation.

An open surgical approach, as used in this clinical case, has proven to be a safe and effective treatment option, particularly for young patients with an asthenic body habitus.

Further to this point, it is well known that elective ligation of the LRV during abdominal aortic aneurysm repair is tolerated well in most circumstances, as is the elective procurement of the LRV for use as a bypass conduit in abdominal vascular reconstructions. The decision to intervene, and by which method, should be tailored to the individual patient and their particular demographic circumstances.<sup>4</sup>

The long-term fate of endovascular stenting in young patients with the potential associated complications of fibromuscular stenosis, thrombosis, embolisation, and erosion is still rather unclear. Further studies are yet to be made in order to ensure its safety, efficacy, and advantageous nature over the open surgical approach. The available literature on this invasive procedure is currently limited to case reports and small series, with limited long-term follow up. It is estimated that up to 11% of stents ultimately migrate from the LRV into the IVC or the heart.<sup>4,7</sup>

On the other hand, the endovascular approach may be the preferred therapy for adult patients with prohibitively hostile anatomic constraints (e.g., those with a history of prior abdominal operations) or in the setting of a symptomatic recurrence following prior open surgical repair.

## CONCLUSION

NCS is characterised by a number of symptoms, which if not diagnosed early enough can often lead to fatal, irreversible complications. In the present case, the symptoms were masked for an extended period of time, while the patient deteriorated at a rapid pace. Most agree that clear diagnostic criteria are required with regard to symptoms and appropriate radiographic findings should be present, to reliably make a diagnosis.<sup>4</sup> Based on long-term results reported by the present study group, as well as those reported in the world literature, transposition of the LRV for the treatment of NCS is recommended for the best long-term outcomes.

## CONFLICTS OF INTEREST

None.

## FUNDING

None.

## REFERENCES

- 1 Kim JY, Joh JH, Choi HY, Do YS, Shin SW, Kim DI. Transposition of the left renal vein in nutcracker syndrome. *J Vasc Surg* 2006;**31**:80–2.
- 2 Ananthan K, Onida S, Davies AH. Nutcracker syndrome: an update on current diagnostic criteria and management guidelines. *J Vasc Endovasc Surg* 2017;**53**:886–94.
- 3 He Y, Wu Z, Chen S, Tian L, Li D, Li M, et al. Nutcracker syndrome—how well do we know it? *Urology* 2014;**83**:12–7.
- 4 McPhee JT, Menard MT. Current management approach for left renal vein entrapment syndrome: the so-called 'Nutcracker' syndrome. *Interv Cardiol* 2011;**3**:557–67.
- 5 Ahmed K, Sampath R, Khan MS. Current trends in the diagnosis and management of renal nutcracker syndrome: a review. *J Vasc Surg* 2006;**31**:410–6.
- 6 Pournasiri Z. The nutcracker syndrome as a rare cause of chronic abdominal pain: a case report. *J Compr Ped* 2016;**7**:e39741.
- 7 Reed NR, Kalra M, Bower TC, Vrtiska TJ, Ricotta JJ, Głowiczki P. Left renal vein transposition for nutcracker syndrome. *J Vasc Surg* 2009;**49**:386–94.