

Retained Intrauterine Sutures for 6 Years

Mukhit Sarsembayev¹, Svetlana Shikanova¹, Bakyt Karimova¹, Gulmira Mukhambetalyeva¹, Ibrahim A. Abdelazim^{2,3*}

¹Department of Obstetrics and Gynecology №1, West Kazakhstan Marat Ospanov Medical University, Aktobe, Kazakhstan, ²Department of Obstetrics and Gynecology, Ain Shams University, Cairo, Egypt, ³Department of Obstetrics and Gynecology, Ahmadi Hospital, Kuwait Oil Company, Ahmadi, Kuwait

Abstract

The most common sutures used for uterine suturing during cesarean section (CS) are vicryl and/or chromic catgut. The sutures' chemistry and polymer morphology alter sutures' performance and absorption. If the sutures used during CS undergo inappropriate hydrolysis and absorption, the retained intrauterine sutures may cause intrauterine inflammations with subsequent abnormal uterine bleeding (AUB) and/or infertility. This report represents a rare case report of retained intrauterine sutures for 6 years after previous CS, which were incised and released from its attachment to the uterine wall using operative hysteroscopy. This report highlights that the retained intrauterine sutures may interfere with sperm transport and implantation and act as a foreign body with subsequent intrauterine inflammation and infertility. In addition, the report highlights the role of a hysteroscopy as the gold standard for uterine cavity assessment in women presented with AUB and/or infertility.

Keywords: Intrauterine, retained, sutures

INTRODUCTION

The most common sutures used for uterine suturing during cesarean section (CS) are vicryl and/or chromic catgut.^[1] The sutures' chemistry and polymer morphology alter sutures' performance and absorption.^[1] Sutures' chemistry plays an important role in the hydrolysis rate and subsequent absorption.^[1]

If the sutures used during CS undergo inappropriate hydrolysis and absorption, the retained intrauterine sutures may cause intrauterine inflammations with subsequent abnormal uterine bleeding (AUB) and/or infertility.^[2,3]

This report represents a rare case report of retained intrauterine sutures for 6 years after previous CS.

CASE REPORT

A 28-year-old woman presented with secondary infertility despite regular sexual life after the previous CS done 6 years ago.

Her day 3 hormonal profile and her husband's semen analysis were completely normal, while the hysterosalpingography showed left tubal obstruction. The transvaginal ultrasound showed an irregular intrauterine lesion closed to the scar of the previous CS, most probably endometrial polyp or intrauterine foreign body (FB) because of its irregularity.

The preoperative investigation of the studied woman including blood picture, liver and renal function tests, and coagulation profile was normal. In addition, the markers of infection and the high vaginal swab for the common sexually transmitted diseases as gonorrhea and chlamydia were negative.

Departmental decision was taken to proceed for postmenstrual combined hysteroscopic and laparoscopic assessment after patient's counseling and written consent.

Address for correspondence: Prof. Ibrahim A. Abdelazim, Department of Obstetrics and Gynecology, Ahmadi Hospital, Kuwait Oil Company, Ahmadi, Kuwait.
E-mail: dr.ibrahimanwar@gmail.com

Article History:

Submitted: 9 May 2019

Revised: 23 October 2019

Accepted: 19 February 2020

Published: 1 August 2020

Access this article online

Quick Response Code:



Website:
www.e-gmit.com

DOI:
10.4103/GMIT.GMIT_42_19

This is an open access journal, and articles are distributed under the terms of the Creative Commons Attribution-NonCommercial-ShareAlike 4.0 License, which allows others to remix, tweak, and build upon the work non-commercially, as long as appropriate credit is given and the new creations are licensed under the identical terms.

For reprints contact: WKHLRPMedknow_reprints@wolterskluwer.com

How to cite this article: Sarsembayev M, Shikanova S, Karimova B, Mukhambetalyeva G, Abdelazim IA. Retained intrauterine sutures for 6 years. Gynecol Minim Invasive Ther 2020;9:159-61.

Combined hysteroscopy and laparoscopy showed intrauterine sutures attached to the scar of the previous CS [Figures 1 and 2] and omental adhesions attached to the anterior abdominal wall with obstructed Fallopian left tube (negative dye test).

The intrauterine sutures were incised and released from its attachment to the uterine wall using the hysteroscopic scissors under direct laparoscopic vision [Figure 3], followed by laparoscopic adhesiolysis for the omental adhesions and left salpingostomy for the obstructed left Fallopian tube. The patient had a smooth uneventful postoperative period and was discharged from the hospital on the 4th postoperative day for follow-up in the infertility specialized outpatient's department.

The studied woman was enrolled in the ovulation induction (OI) protocol for 3 months, and she is currently on OI protocol and intrauterine insemination (IUI) for another 3 months. According to the departmental protocol, the studied woman was enrolled *in vitro* fertilization and embryo transfer program if the OI and IUI failed to achieve pregnancy at the end of the 6th month.

A departmental ethical committee approval (IRB No. OBGYN_REC_19.04.02) and written consent were obtained from the studied woman to use her data for scientific education and publication as a case report.

DISCUSSION

The most common sutures used for uterine suturing during CS are chromic catgut and/or vicryl.^[1] Vicryl (polyglactin) is synthetic, braided suture used for soft-tissue approximation, and complete absorption occurs 56–70 days by hydrolysis.^[1] Chromic catgut is a biologically absorbable suture from purified collagen taken from bovine intestines and absorbed by enzymatic proteolysis within 70 days.^[2-4]

If the sutures used during CS undergo inappropriate hydrolysis and absorption, the retained intrauterine sutures may cause intrauterine inflammations with subsequent AUB and/or infertility.^[2,3]

The intra-abdominal adhesions, the obstructed left tube diagnosed during laparoscopy, are mostly related to the previous CS and can also interfere with the ovum pickup and transport with subsequent infertility.

The examination of the released intrauterine sutures showed Lavsan suture materials. Lavsan (MEDBAZA, OOO, St Petersburg, Russia) is polyester nonabsorbable surgical suture materials that has been approved and used as a surgical suture since 1990. The surgical suture “Lavsan” is made by twisting of white or green polyester multifilament

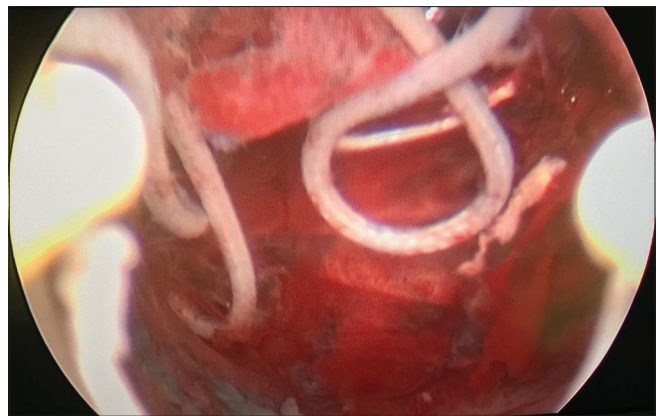


Figure 1: Intrauterine retained sutures (hysteroscopic far view)

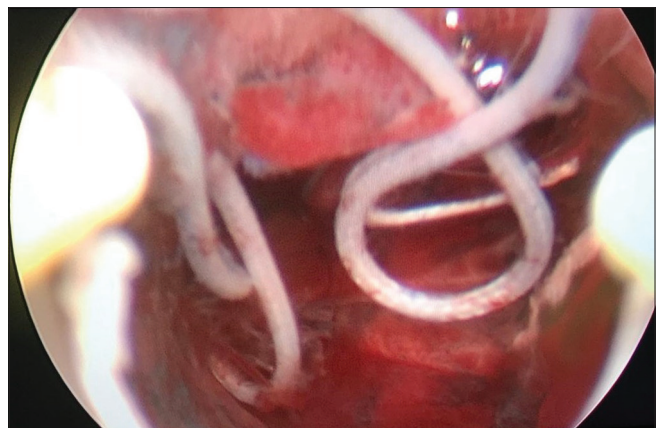


Figure 2: Intrauterine retained sutures (hysteroscopic near view)

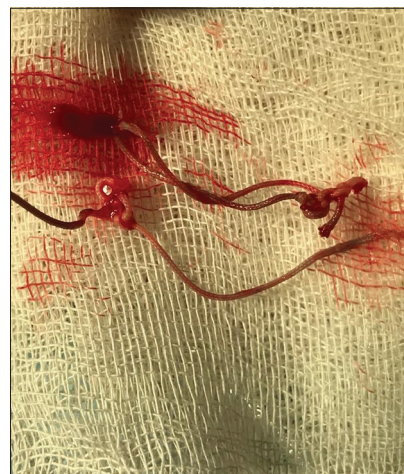

Figure 3: Retained intrauterine suture after hysteroscopic removal

yarns and characterized by high strength and elasticity, good manipulation properties, and reliable surgeon's knot.^[5]

Fedorov *et al.* found that coating of the initial Lavsan sutures with a biocompatible and biodegradable polymer (polyhydroxybutyrate) did not reduce the holding power and degree of reliability of the knots.^[5]

In addition, they found that this modification of the initial Lavsan sutures allows using of less complex knots with subsequent reduction in the sutures' consumption and risk of infection.

Vahdat *et al.* reported a case report of AUB due to retained sutures after multiple CSs, diagnosed by diagnostic hysteroscopy, which showed an abnormal mass at the level of internal cervical os and managed by polypectomy followed by endometrial curettage.^[1] They concluded that the degradation of the sutures was determined by patients' features (temperature, PH, and protein deficiency)^[6] and chemical composition of the sutures.^[1]

Endometrial polyps are the most common intrauterine focal growth, seen in 10% of the female population. It is usually asymptomatic and identified during the routine workup of AUB and/or infertility.^[7] If the sutures used during CS undergo inappropriate hydrolysis and absorption, the retained intrauterine sutures may cause intrauterine inflammations with subsequent AUB and/or infertility.^[2,3]

The intra-abdominal adhesions, the obstructed left tube diagnosed during laparoscopy, are mostly related to the previous CS and can also interfere with the ovum pickup and transport with subsequent infertility.

This case report highlights that the retained intrauterine sutures may interfere with sperm transport and implantation and act as FB with subsequent intrauterine inflammation and infertility.^[7] In addition, the presented case highlights the role of the hysteroscopy as the gold standard procedure for uterine cavity assessment in women presented with AUB and/or infertility.^[8]

CONCLUSION

Retained intrauterine sutures may interfere with sperm transport and implantation and act as FB with subsequent intrauterine inflammation and infertility.

Declaration of patient consent

The authors certify that they have obtained all appropriate patient consent forms. In the form, the patient has given

her consent for her images and other clinical information to be reported in the journal. The patient understands that her name and initials will not be published and due efforts will be made to conceal her identity, but anonymity cannot be guaranteed.

Acknowledgment

The authors are grateful to the studied woman agreed and gave consent to participate in this case report.

Financial support and sponsorship

Nil.

Conflicts of interest

There are no conflicts of interest.

REFERENCES

- Vahdat M, Rokhgireh S, Mousavi AS, Tahermanmanesh K, Khodaverdi S, Nazari L, *et al.* Retained suture material post cesarean section: A case report. *J Minim Invasive Surg Sci* 2016;5:e42295.
- Doty AC, Hirota K, Olsen KF, Sakamoto N, Ackermann R, Feng MR, *et al.* Validation of a cage implant system for assessing *in vivo* performance of long-acting release microspheres. *Biomaterials* 2016;109:88-96.
- Boland EL, Shine R, Kelly N, Sweeney CA, McHugh PE. A review of material degradation modelling for the analysis and design of bioabsorbable stents. *Ann Biomed Eng* 2016;44:341-56.
- Xodo S, Saccone G, Cromi A, Ozcan P, Spagnolo E, Berghella V. Cephalad-caudad versus transverse blunt expansion of the low transverse uterine incision during cesarean delivery. *Eur J Obstet Gynecol Reprod Biol* 2016;202:75-80.
- Fedorov MB, Vikhoreva GA, Vinokurova TI, Borisova Yu K, Gal'braikh LS. Effect of polyhydroxybutyrate coating on the characteristics of surgical knots in lavsan sutures. *Fibre Chem* 2008;40:123-6. Available from: <https://doi.org/10.1007/s10692-008-9023-8>. [Last accessed on 2020 Mar 11].
- Grillo CA, Alvarez F, Fernández Lorenzo de Mele MA. Degradation of bioabsorbable Mg-based alloys: Assessment of the effects of insoluble corrosion products and joint effects of alloying components on mammalian cells. *Mater Sci Eng C Mater Biol Appl* 2016;58:372-80.
- Al Chami A, Saridogan E. Endometrial polyps and subfertility. *J Obstet Gynaecol India* 2017;67:9-14.
- Dimitriu G, Abdelazim I, Svetlana S, Zhurabekova G, Alrbeihat R, Taso O. Saline infusion sonography compared to hysteroscopy for uterine cavity evaluation in abnormal uterine bleeding. *Journal of Obstetrics and Gynecological Investigations* 2018;1:35-40. doi:10.5114/jogi.2018.77765.