



Associations between clinical neck symptoms and various evaluations of cervical intervertebral disc degeneration by magnetic resonance imaging

Haruka Otaki, Koji Otani, Takehiro Watanabe, Miho Sekiguchi and Shin-ichi Konno

Department of Orthopaedic Surgery, Fukushima Medical University School of Medicine, Fukushima, Japan

(Received August 18, 2021, accepted September 27, 2021)

Abstract

Purpose : Magnetic resonance imaging (MRI) is widely used to evaluate intervertebral disc degeneration. Recently, various evaluations of cervical disc degeneration using MRI have been conducted, but there is no gold standard. The purpose of this study was to compare the reproducibilities of previously reported classifications for evaluating cervical disc degeneration by MRI and their associations with clinical symptoms.

Participants and methods : A total of 582 subjects underwent conventional MRI of the cervical spine. Disc degeneration was assessed in each intervertebral disc from C2/3 to C7/T1 using five different classifications : Matsumoto's grading system, Miyazaki's grading system, Nakashima's grading system, Jacobs' grading system, and Suzuki's grading system. MR images of 30 participants were used, and Cohen's kappa coefficient of agreement of each classification was calculated for intra-observer and inter-observer reliabilities. These five classifications of disc degeneration and changes of vertebral endplates were measured, and associations with clinical symptoms were assessed.

Results : Kappa (κ) values of intra-observer agreement were higher for Jacobs' classification, whereas those of inter-observer agreement were higher for Nakashima's and Jacobs' classifications than for other classifications. The prevalences of neck pain and shoulder stiffness were 27.4% and 41.9%, respectively. There were no associations for any classifications of disc degeneration and Modic types with neck pain or shoulder stiffness. Only the presence of Schmorl's nodes was associated with neck pain.

Conclusion : At present, there is no specific classification for cervical disc degeneration associated with clinical symptoms. Vertebral endplate changes might be associated with clinical symptoms. It may be necessary to create a new classification for better reproducibility of the evaluation of cervical disc degeneration.

Key words : cross-sectional study, disc degeneration, cervical spine, magnetic resonance imaging (MRI), intra-observer and inter-observer agreements

Introduction

Intervertebral disc degeneration is thought to be related to neck pain¹⁻³⁾. When it progresses, it causes radiculopathy and myelopathy⁴⁾. Early detection of disc degeneration is important for choos-

ing suitable treatment and for preventing its progression.

T2-weighted magnetic resonance imaging (MRI) is widely used to evaluate intervertebral disc degeneration^{1,4-7)}. Cervical vertebral disc degeneration is based histologically on loss of water and pro-

Corresponding author : Koji Otani E-mail : kotani@fmu.ac.jp

©2021 The Fukushima Society of Medical Science. This article is licensed under a Creative Commons [Attribution-NonCommercial-ShareAlike 4.0 International] license.
<https://creativecommons.org/licenses/by-nc-sa/4.0/>

teoglycan content in the intervertebral disc, and it is seen as a decrease in intervertebral disc height and disc protrusion^{1,4,7}. MRI is useful for observing these findings.

Recently, various studies using MRI have been conducted, and classifications of cervical disc degeneration have been established^{1,4-8}. However, few papers have described the reproducibility of the classifications for evaluating cervical disc degeneration. In addition, no study has compared cervical disc degeneration using various MRI classifications and clinical symptoms. In this study, therefore, the aims were to compare cervical disc degeneration on MR images, as assessed by five different classification systems, and to evaluate their associations with neck symptoms in a community-based cohort.

Participants and methods

This was a cross-sectional study based on epidemiologic data from public health screening conducted in 2005 by local governments in Tadami Town, Ina Village, and Tateiwa Village of Fukushima Prefecture, Japan⁹. From 3,236 participants (1,326 men, 1,910 women; age range 19-94 years; average age, 65.5 years), a total of 582 agreed to undergo MRI of the cervical spine and answered a questionnaire about the presence of neck pain or shoulder stiffness. They were asked "Do you have neck pain which needs medical care?" and "Do you have shoulder stiffness which needs medical care?" separately. Neck symptoms included those with either neck pain or shoulder stiffness. The exclusion criteria were if they were unable to walk independently or fill out questionnaires due to visual impairment, or had ever undergone brain or spinal surgery. Cases with MRI results insufficient for all classification systems, and those with missing questionnaire data, were excluded.

Municipality-based public health screening is part of Japan's system of universal health care. Participation is voluntary. This supplemental study was approved by the ethics committee of Fukushima Medical University (No.1880). Informed consent was documented in writing for all study participants.

MRI assessment

Disc degeneration, Modic change, and Schmorl's nodes were evaluated on MRI images. The detailed imaging conditions of the MRI scanners are shown in the supplemental data.

Disc degeneration was assessed using five

classifications: Matsumoto's grading system⁸, Miyazaki's grading system⁴, Nakashima's grading system⁷, Jacobs' grading system¹, and Suzuki's grading system⁵. A midsagittal T2-weighted image (WI) was obtained at each level of the intervertebral discs from C2 to Th1. Matsumoto's grading system consists of four parts: disc degeneration, posterior disc protrusion, anterior disc protrusion, and narrowing of the disc space. Grades 0 to 2 were chosen using the criteria shown in Table 1. Miyazaki's grading system evaluates disc degeneration by nucleus signal intensity, nucleus structure, distinction between the nucleus and annulus, and disc height⁴. Grades 1 to 5 were chosen using the criteria shown in Table 1. Nakashima's grading system evaluates disc degeneration by nucleus structure, the border of the nucleus, and disc height with a flow chart (Fig. 1)⁷. Jacobs' grading system uses nucleus signal intensity and disc height¹. The grades are grade 0 (normal disc height, with or without a cleft in the nucleus pulposus), grade 1 (dark disc, with normal height), grade 2 (collapsed disc, little or no osteophytes), and grade 3 (collapsed disc, with many osteophytes) (Table 1). Suzuki's grading system uses disc height, nucleus signal intensity, the border of the nucleus, and disc bulge with a flow chart (Fig. 2)^{5,10}. Disc degeneration of the entire cervical spine was assessed using the degenerative disc disease (DDD) score, which is the sum of the grades at each cervi-

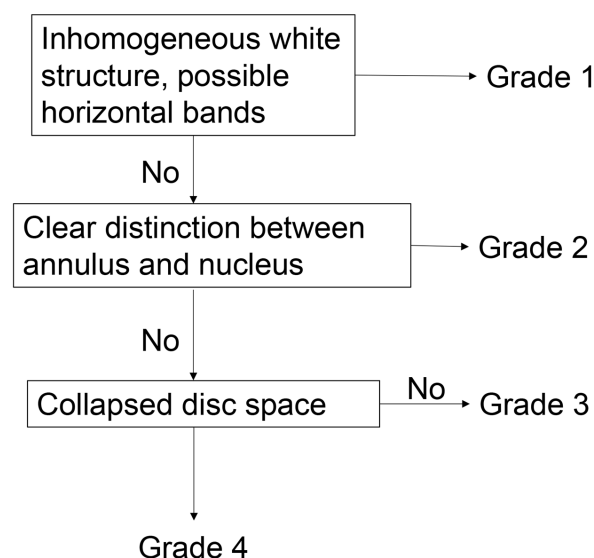


Fig. 1. Algorithm for Nakashima's classification⁷

Nakashima's classification evaluates disc degeneration in the order of nucleus structure, border of the nucleus, and disc height. If nucleus structure is inhomogeneously white, it is Grade 1. If the border of the nucleus is clear, it is Grade 2. If the disc is collapsed, it is Grade 4.

Table 1. Classifications of MRI images

Matsumoto's calcification⁸⁾				
Disc degeneration	Grade			
	0 Bright as or slightly less bright than CSF			
	1 Dark &/or speckled			
	2 Almost black			
Posterior disc protrusion	0 Disc material confined within the posterior margin of the VB			
	1 Disc material protruding beyond the posterior margin of the VB without cord compression			
	2 Beyond VB with cord compression			
Anterior disc protrusion	0 Disc material confined within the anterior margin of the VB			
	1 Disc material protruding beyond the anterior margin of the VB			
Narrowing of the disc space	0 No narrowing or less than 25% loss in height compared with the most adjacent normal disc space			
	1 25% to 50% loss of height			
	2 > more than 50% loss of height			
Miyazaki's calcification⁴⁾				
Grade	<i>Nucleus Signal Intensity</i>	<i>Nucleus Structure</i>	<i>Distinction of Nucleus and Annulus</i>	<i>Disc Height</i>
1	Hyperintense	Homogenous, white	Clear	Normal
2	Hyperintense	Inhomogenous with horizontal band, white	Clear	Normal
3	Intermediate	Inhomogenous, gray to black	Unclear	Normal to decreased
4	Hypointense	Inhomogenous, gray to black	Lost	Normal to decreased
5	Hypointense	Inhomogenous, gray to black	Lost	Collapsed
Jacobs' clasification¹⁾				
Grade	Grade			
0	Normal, light grey center, mid cleft still visible			
1	Dark disc, not collapsed			
2	Dark disc, collapsed with minimal osteophytes			
3	Dark disc, collapsed with many osteophytes			
Modic change¹²⁾				
Type	T1-WI	T2-WI		
1	Low	High		
2	High	High		
3	Low	Low		

Abbreviations : CSF, cerebrospinal fluid ; VB, vertebral body ; WI, weighted image

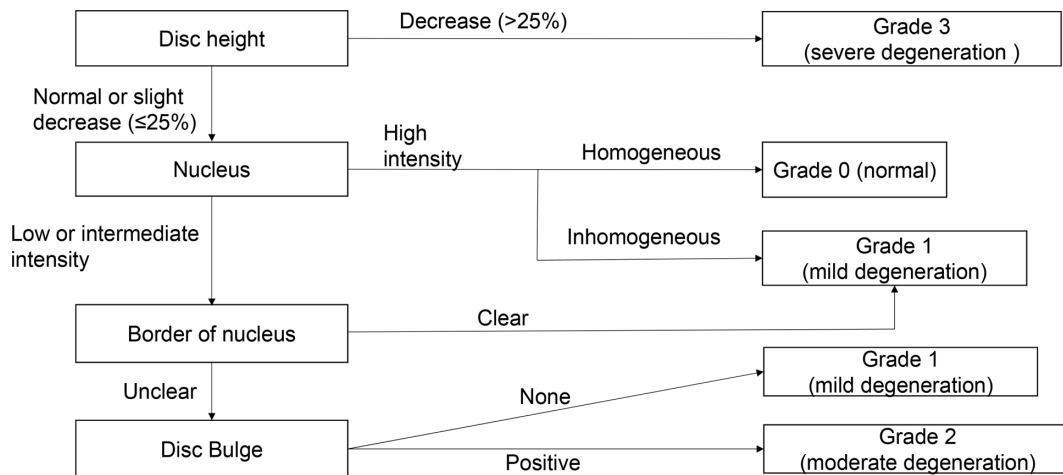


Fig. 2. Algorithm for Suzuki's classification⁵⁾

Suzuki's classification evaluates disc degeneration in the order of disc height, nucleus signal intensity, border of the nucleus, and disc bulge. If the disc height decreases by more than 25%, it is grade 3. If the nucleus is high intensity and homogeneous, it is grade 0. If the nucleus is high intensity and inhomogeneous, or if the border of the nucleus is clear, it is grade 1. If the border is not clear, but it does not have disc bulge, it is also grade 1. If the border is not clear, and it has disc bulge, it is grade 2.

cal disc level (C2/3-C7/T1) in each of the five classifications¹¹⁾.

To evaluate the intra/inter-observer reliabilities of each classification, a sample size calculation was estimated for $\rho = 0.8$ with a 95% confidence interval of 0.4, rated by two examiners; at least 20 subjects would be needed. Therefore, 30 subjects were randomly selected for kappa analysis. Each intervertebral level from C2/3 to C7/T1 was measured by two orthopedic surgeons (HO & TW). The five classifications of disc degeneration were measured four times each in each subject. The second and third measurements were performed one week and one month after the first measurement. The fourth measurement was performed one week after the third assessment. Finally, one orthopedic surgeon (HO) examined all images without any participants' information, including their symptoms. Other MRI assessments of vertebral endplate changes for Modic changes and Schmorl's nodes were examined. Modic changes were scored type I (hypointense on T1-WI and hyperintense on T2-WI), type II (hyperintense on T1- and T2-WI), and type III (hypointense on T1- and T2-WI) (Table 1)¹²⁾. Schmorl's nodes were defined as more than a 2-mm deficit on T2-WI at each vertebral body level. The presence of a Schmorl's node was defined as observation of a node at least one vertebral endplate level¹³⁾.

Data analysis

Intra-observer and inter-observer agreements

were assessed by κ values for each classification. First, the κ values of intra-observer agreement were calculated between the first and second measurement results of each intervertebral disc level by two observers. Second, the κ values were calculated between the third and fourth measurements in the same way. Finally, the average of these four κ values was used to evaluate intra-observer reliability. The inter-observer agreement was calculated between the first measurement results of each observer. Similarly, the κ values of the second to fourth measurements were calculated. The average of these four κ values was used to evaluate inter-observer reliability. Interpretations were performed in accordance with the guidelines suggested by Landis and Koch¹⁴⁾. Agreement was rated as follows: poor, κ 0 to 0.2; fair, κ 0.21 to 0.4; moderate, κ 0.41 to 0.60; substantial, κ 0.61 to 0.8; and excellent, $\kappa > 0.81$. A value of 1 indicated absolute agreement, whereas a value of 0 indicated agreement no better than chance. In addition, comparison between groups was performed using Tukey's test and the Games-Howell test. A p value of less than 0.05 was considered significant. Odds ratios (ORs) were estimated using a logistic regression model, and a two-sided $p < 0.05$ was considered significant. ORs were adjusted for age, sex, and other explanatory variables to evaluate associations between the presence of neck pain, neck stiffness, or neck symptoms (either neck pain or shoulder stiffness) and the findings of MRI images. Baseline characteristics are described using appropriate sum-

mary statistics with the chi-squared test, Mann-Whitney U test, and Cochran-Armitage's propensity test. Statistical analyses were performed using SPSS (version 13, SPSS, Chicago, IL). A *p* value of less than 0.05 was considered significant.

Results

Intra/inter-observer agreements for each classification

The κ values for intra-observer and inter-observer agreements of each classification are shown in Table 2. The κ values for intra-observer agreement of Matsumoto's, Nakashima's, and Jacobs' classifications were substantial. The κ values of Miyazaki's and Suzuki's classifications were moderate. The κ value of intra-observer agreement was significantly higher for Jacobs' classification than for Miyazaki's classification. There were no significant differences for the other classifications.

The κ values for inter-observer agreement of disc degeneration, posterior disc protrusion, and narrowing of the disc space in Matsumoto's classification were moderate. The κ values of Nakashima's and Jacobs' classifications were moderate. The κ values for anterior disc protrusion of Matsumoto's, Miyazaki's, and Suzuki's classifications were fair. The κ value of inter-observer agreement was significantly higher for Nakashima's and Jacobs' classifications than for Suzuki's classification. There were no significant differences for other classifications.

Associations of disc degeneration grading on MRI findings and clinical symptoms

The 497 participants consisted of 155 male and

342 female persons. Their mean age was 64 years (range 25 to 93 years), and most participants were aged over 70 years (Fig. 3).

A comparison of the patients' characteristics with and without neck pain is shown in Table 3. The prevalence of neck pain was 27.4% (136 of 497 participants). There were no significant differences in age and sex between participants with and without neck pain. In all classifications of disc degeneration, there was no difference in DDD scores between participants with and without neck pain. The distribution for the highest severity of grade was only significantly higher with neck pain than without neck pain in Miyazaki's classification ($p = 0.000$). The prevalence of Modic change was 5.4% (27 of 497 participants). There was no significant difference in Modic types with and without neck pain. The prevalence of Schmorl's nodes was 32.4% (161 of 497 participants). Fifty-seven participants (41.9%) with neck pain were found to have Schmorl's nodes, while in those without neck pain, 28.8% had Schmorl's nodes. The prevalence of Schmorl's nodes was significantly higher in participants with neck pain than in those without it ($p = 0.005$).

Comparisons of characteristics with and without shoulder stiffness are shown in Table 4. The prevalence of shoulder stiffness was 48.7% (242 of 497 participants). The mean age and distribution of age was younger with shoulder stiffness than without it ($p = 0.000$). DDD scores were significantly lower in the participants with than in those without shoulder stiffness in all classifications. However, these differences were very small (range, 0.56 to 1.19), and the clinical meaning might be unclear. There were no significant differences in sex, Modic

Table 2. Kappa values of intra- and inter-observer agreements for each classification

Grading system	Intra-observer agreement					Inter-observer agreement				
	Observer 1		Observer 2		Average	First time	Second time	Third time	Fourth time	Average
	First vs Second	Third vs Fourth	First vs Second	Third vs Fourth						
Matsumoto's classification										
Disc degeneration	0.447	0.604	0.651	0.688	0.606	0.402	0.485	0.376	0.407	0.418
Posterior disc protrusion	0.476	0.736	0.844	0.740	0.705	0.368	0.350	0.509	0.452	0.420
Anterior disc protrusion	0.625	0.705	0.469	0.631	0.617	0.162	0.151	0.456	0.427	0.299
Narrowing of the disc space	0.548	0.658	0.720	0.667	0.651	0.641	0.470	0.492	0.557	0.534
Miyazaki's classification	0.455	0.609	0.588	0.529	0.549	0.382	0.515	0.246	0.312	0.364
Nakashima's classification	0.664	0.691	0.667	0.512	0.628	0.431	0.508	0.565	0.469	0.493*
Jacobs' classification	0.786	0.75	0.614	0.715	0.719*	0.565	0.641	0.388	0.473	0.517*
Suzuki's classification	0.565	0.575	0.606	0.627	0.594	0.243	0.228	0.343	0.406	0.305

* ; Games-Howell test $p < 0.05$

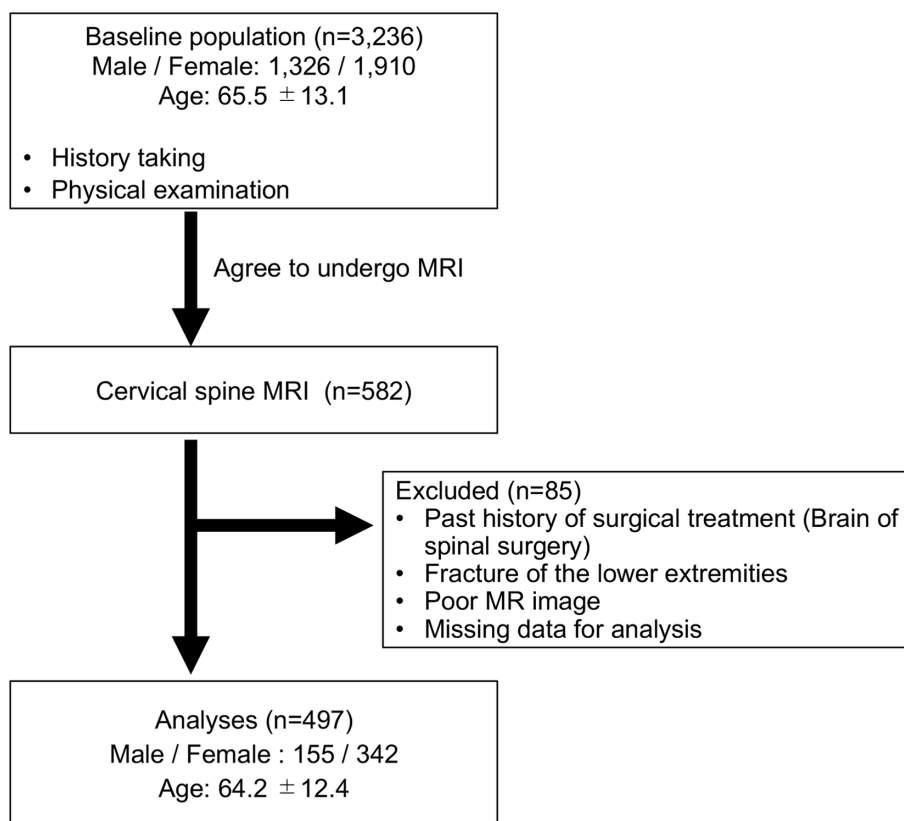


Fig. 3. Flow chart of subject selection

types, and the prevalence of Schmorl's nodes between the participants with and without shoulder stiffness.

According to the adjusted odds ratios on multivariate analysis, the associations of the MRI findings in each classification with the presence of neck pain, shoulder stiffness, and neck symptoms are shown in Table 5. There were no significant associations for any clinical symptoms with DDD scores in the five classifications. In addition, there was no association between Modic change and any clinical symptoms. The presence of Schmorl's nodes was only associated with neck pain and neck symptoms.

Discussion

MRI is a useful method for evaluating disc degeneration^{1,4,6}, but there is no gold standard for its evaluation. Several classifications of disc degeneration using MRI to evaluate signal intensity, bulge, and height of intervertebral discs have already been reported^{1,4-8}. Since morphological assessment is subjective and affected by observer bias, the reproducibility of the evaluation method is therefore important. In addition, the associations between morphological findings and clinical symptoms are still

controversial. There are previous studies in which the morphological findings using a different single assessment were evaluated for their associations with neck symptoms¹⁵. It is not clear whether the methodology for assessment of disc degeneration using MRI itself affects the result for associations with symptoms, or it is evidence that morphological findings are not associated with clinical symptoms. In the present study, five different assessments of cervical vertebral disc degeneration were analyzed for both their reproducibilities and their associations with symptoms.

In the original papers of the five classifications, both intra-observer and inter-observer agreements of each classification were reported as moderate to almost complete. In the present study, intra-observer agreement was moderate to substantial, and inter-observer agreement was fair to moderate. The present results show that Jacobs' classification has relatively high reproducibility. This classification is established for routine clinical use, and the criteria are simple; therefore, it is easy to define each criterion, and both intra-observer and inter-observer reproducibilities might be high. One of the causes for lack of agreement is thought to be the problem of defining the criteria for degeneration.

Table 3. Comparison of characteristics between participants with and without neck pain

	Neck pain (-) <i>n</i> = 361	Neck pain (+) <i>n</i> = 136	<i>p</i>
Distribution of age (y) (<i>n</i> [%])			0.570
(mean ± SD)	64.4 ± 12.1	63.6 ± 12.9	
< 50	44 (12.2)	21 (15.4)	
50-59	70 (19.3)	25 (18.4)	
60-69	99 (27.3)	35 (25.7)	
≥ 70	148 (40.9)	55 (40.4)	
Sex (<i>n</i> [%])			0.899
Male	112 (31.0)	43 (31.6)	
Female	249 (69.0)	93 (68.7)	
Disc degeneration			
Matsumoto's classification			
The most severity grade (<i>n</i> [%])			0.348
Grade 0	5 (1.4)	3 (2.2)	
Grade 1	80 (22.1)	34 (25.0)	
Grade 2	276 (76.5)	99 (72.8)	
DDD score (range 0-12)	7.16 ± 3.00	7.14 ± 3.24	0.890
Miyazaki's classification			
The most severity grade (<i>n</i> [%])			0.000
Grade 1	1 (0.3)	0 (0)	
Grade 2	7 (1.9)	58 (3.7)	
Grade 3	64 (17.7)	18 (13.2)	
Grade 4	250 (69.3)	91 (66.9)	
Grade 5	39 (10.8)	22 (16.2)	
DDD score (range 0-30)	19.36 ± 3.81	19.54 ± 4.31	0.352
Nakashima's classification			
The most severity grade (<i>n</i> [%])			0.319
Grade 1	6 (1.7)	3 (2.2)	
Grade 2	25 (6.9)	9 (6.6)	
Grade 3	288 (79.8)	100 (73.5)	
Grade 4	42 (11.6)	24 (17.6)	
DDD score (range 0-24)	14.89 ± 3.31	15.05 ± 3.61	0.392
Jacobs' classification			
The most severity grade (<i>n</i> [%])			0.403
Grade 0	10 (2.8)	11 (8.1)	
Grade 1	299 (82.8)	99 (72.8)	
Grade 2	28 (7.89)	16 (11.8)	
Grade 3	15 (4.2)	10 (7.4)	
DDD score (range 0-18)	4.33 ± 2.14	4.57 ± 2.37	0.278
Suzuki's classification			
The most severity grade (<i>n</i> [%])			0.592
Grade 0	1 (0.3)	0 (0)	
Grade 1	67 (18.6)	24 (17.6)	
Grade 2	156 (43.2)	57 (41.9)	
Grade 3	137 (38.0)	55 (40.4)	
DDD score (range 0-18)	8.64 ± 2.59	8.57 ± 2.80	0.984
Modic change (<i>n</i> [%])			0.124
None	342 (94.7)	128 (94.1)	
Presence	19 (5.3)	8 (5.9)	
Type 1	9	1	
Type 2	11	5	
Type 3	1	4	
Schmorl node (<i>n</i> [%])			0.005
None	257 (71.2)	79 (58.1)	
Presence	104 (28.8)	57 (41.9)	

Abbreviations : DDD, degenerative disc disease.

Table 4. Comparison of characteristics between participants with and without shoulder stiffness

	Shoulder stiffness (–) <i>n</i> = 255	Shoulder stiffness (+) <i>n</i> = 242	<i>p</i>
Distribution of age (y) (<i>n</i> [%])			0.000
(mean ± SD)	66.8 ± 11.1	61.3 ± 13.0	
<50	21 (8.2)	44 (18.2)	
50–59	38 (14.9)	57 (23.6)	
60–69	70 (27.5)	64 (26.4)	
≥70	126 (49.4)	77 (31.8)	
Sex (<i>n</i> [%])			0.101
Male	88 (34.5)	67 (27.7)	
Female	167 (64.5)	175 (72.3)	
Disc degeneration			
Matsumoto's classification			
The most severity grade (<i>n</i> [%])			0.002
Grade 0	3 (1.2)	5 (2.1)	
Grade 1	44 (17.3)	70 (28.9)	
Grade 2	208 (81.5)	167 (69.0)	
DDD score (range 0–12)	7.68 ± 3.03	6.60 ± 3.01	0.000
Miyazaki's classification			
The most severity grade (<i>n</i> [%])			0.051
Grade 1	0 (0)	1 (0.4)	
Grade 2	6 (2.4)	6 (2.5)	
Grade 3	29 (11.4)	53 (21.9)	
Grade 4	190 (74.5)	151 (62.4)	
Grade 5	30 (11.8)	31 (12.8)	
DDD score (range 0–30)	19.99 ± 3.78	18.80 ± 4.04	0.001
Nakashima's classification			
The most severity grade (<i>n</i> [%])			0.267
Grade 1	4 (1.6)	5 (2.1)	
Grade 2	10 (3.9)	24 (9.9)	
Grade 3	208 (81.6)	180 (74.4)	
Grade 4	30 (11.8)	33 (13.6)	
DDD score (range 0–24)	15.41 ± 3.20	14.43 ± 3.52	0.001
Jacobs' classification			
The most severity grade (<i>n</i> [%])			0.422
Grade 0	8 (3.1)	22 (9.1)	
Grade 1	213 (83.5)	185 (76.4)	
Grade 2	22 (8.6)	22 (9.1)	
Grade 3	12 (4.7)	13 (5.49)	
DDD score (range 0–18)	4.67 ± 2.02	4.11 ± 2.36	0.004
Suzuki's classification			
The most severity grade (<i>n</i> [%])			0.006
Grade 0	0 (0)	1 (0.4)	
Grade 1	38 (14.9)	53 (21.9)	
Grade 2	113 (44.3)	100 (41.3)	
Grade 3	104 (40.8)	88 (36.4)	
DDD score (range 0–18)	8.97 ± 2.53	8.27 ± 2.73	0.002
Modic change (<i>n</i> [%])			0.239
None	245 (96.1)	225 (92.9)	
Presence	10 (3.9)	17 (7.0)	
Type 1	4	6	
Type 2	5	11	
Type 3	3	2	
Schmorl node (<i>n</i> [%])			0.940
None	172 (67.5)	164 (67.8)	
Presence	83 (32.5)	78 (32.2)	

Abbreviations : DDD, degenerative disc disease.

Table 5. Associations of MRI findings with neck pain and shoulder stiffness in multivariate regression analysis

	Neck pain (<i>n</i> = 136)			Neck stiffness (<i>n</i> = 242)			Neck symptoms (<i>n</i> = 279)		
	OR	95%CI	<i>p</i> value	OR	95%CI	<i>p</i> value	OR	95%CI	<i>p</i> value
Matsumoto's classification									
Sex	1.108	0.717-1.712	0.645	0.702	0.47-1.046	0.082	1.201	0.81-1.781	0.363
Age	1.008	0.989-1.027	0.437	1.031	1.013-1.05	0.001	0.973	0.956-0.991	0.003
DDD score	0.984	0.888-1.09	0.755	1.068	0.974-1.171	0.16	0.997	0.91-1.092	0.997
Max DD grade	1.414	0.776-2.577	0.258	1.091	0.629-1.893	0.756	0.692	0.397-1.207	0.692
Modic change									
type1	2.76	0.33-23.117	0.349	0.275	0.053-1.423	0.124	2.688	0.521-13.876	0.238
type2	1.431	0.386-5.299	0.592	0.475	0.152-1.484	0.2	2.052	0.62-6.791	0.239
type3	0.13	0.014-1.194	0.071	1.455	0.231-9.184	0.69	2.699	0.292-24.912	0.381
Schmorl node	1.875	1.196-2.938	0.006	1.367	0.899-2.079	0.143	0.633	0.417-0.962	0.032
Miyazaki's classification									
Sex	1.098	0.711-1.696	0.672	0.707	0.475-1.052	0.087	1.217	0.821-1.802	0.328
Age	1.013	0.993-1.033	0.194	1.035	1.016-1.055	0	0.971	0.953-0.989	0.002
DDD score	1.02	0.943-1.103	0.621	1.05	0.978-1.127	0.178	0.992	0.924-1.064	0.817
Max DD grade	0.765	0.489-1.197	0.241	0.86	0.57-1.296	0.47	0.916	0.608-1.378	0.672
Modic change									
type1	3.144	0.376-26.291	0.29	0.273	0.052-1.418	0.273	2.585	0.502-13.322	0.256
type2	1.572	0.423-5.845	0.5	0.499	0.159-1.564	0.233	2.003	0.606-6.619	0.255
type3	0.151	0.016-1.4	0.096	1.539	0.243-9.742	0.647	2.731	0.292-25.511	0.378
Schmorl node	1.81	1.16-2.826	0.009	1.303	0.859-1.976	0.213	0.647	0.427-0.982	0.041
Nakashima's classification									
Sex	1.094	0.709-1.689	0.686	0.713	0.479-1.062	0.096	1.207	0.815-1.788	0.348
Age	1.012	0.993-1.032	0.213	1.036	1.017-1.056	0	0.97	0.953-0.989	0.001
DDD score	1.012	0.928-1.104	0.787	1.056	0.976-1.143	0.173	0.978	0.904-1.058	0.581
Max DD grade	0.801	0.484-1.325	0.387	0.786	0.496-1.247	0.306	1.019	0.642-1.616	0.937
Modic change									
type1	3.053	0.365-25.531	0.303	0.27	0.052-1.405	0.12	2.547	0.495-13.105	0.263
type2	1.564	0.419-5.834	0.505	0.502	0.16-1.582	0.239	1.988	0.6-6.593	0.261
type3	0.146	0.016-1.355	0.091	1.525	0.242-9.613	0.653	2.662	0.285-24.838	0.39
Schmorl node	1.806	1.16-2.813	0.009	1.283	0.848-1.941	0.239	0.648	0.428-0.981	0.041
Jacobs' classification									
Sex	1.085	0.702-1.675	0.714	0.702	0.471-1.046	0.082	1.212	0.818-1.795	0.338
Age	1.014	0.995-1.034	0.15	1.037	1.019-1.056	0	0.97	0.953-0.988	0.001
DDD score	0.978	0.854-1.119	0.743	1.077	0.954-1.215	0.23	0.963	0.854-1.087	0.543
Max DD grade	0.899	0.579-1.395	0.634	0.794	0.526-1.199	0.273	1.048	0.695-1.581	0.823
Modic change									
type1	3.134	0.373-26.306	0.293	0.277	0.053-1.438	0.127	2.524	0.49-12.996	0.268
type2	1.605	0.428-6.019	0.483	0.52	0.165-1.64	0.265	1.97	0.592-6.549	0.269
type3	0.156	0.017-1.472	0.105	1.678	0.261-10.776	0.585	2.622	0.275-24.96	0.402
Schmorl node	1.747	1.113-2.742	0.015	1.283	0.842-1.954	0.246	0.644	0.422-0.981	0.041
Suzuki's classification									
Sex	1.134	0.732-1.758	0.574	0.716	0.479-1.068	0.102	1.206	0.811-1.794	0.354
Age	1.008	0.99-1.027	0.404	1.036	1.018-1.054	0	0.973	0.957-0.99	0.002
DDD score	1.106	0.975-1.256	0.117	1.076	0.96-1.206	0.21	0.932	0.832-1.044	0.226
Max DD grade	0.742	0.488-1.129	0.163	0.918	0.628-1.343	0.66	1.002	0.685-1.466	0.992
Modic change									
type1	3.001	0.356-25.298	0.312	0.256	0.49-1.34	0.107	2.753	0.535-14.282	0.225
type2	1.451	0.39-5.404	0.579	0.477	0.152-1.503	0.206	2.146	0.646-7.131	0.213
type3	0.142	0.015-1.321	0.086	1.488	0.236-9.399	0.673	2.797	0.301-25.999	0.366
Schmorl node	1.992	1.265-3.136	0.003	1.338	0.878-2.041	0.176	0.605	0.396-0.925	0.02

Abbreviations : DDD, degenerative disc disease.

The criteria for judging signal intensity and disc protrusion are inferred from the written words in the papers. Therefore, the reproducibility may decrease due to differences in interpretation of the words used to describe the classification. In particular, it seems that the criteria for determining nucleus signal intensity are likely to be confusing. For example, in Matsumoto's and Suzuki's classifications, evaluation of the height has rough criteria, such as 25% or 50% reduction, so that it is easier to classify than nucleus signal intensity. However, there is no clear standard for nucleus signal intensity, because signal intensity is evaluated in Matsumoto's and Suzuki's classifications by comparison with cerebrospinal fluid, but that is not a clear standard. In other classifications, signal intensity is categorized as high signal intensity, low signal intensity, and no signal intensity, but there are no definitions of high signal intensity and of low signal intensity. It is difficult to evaluate signal intensity quantitatively, and how much signal intensity is high and how much low signal intensity is low depends on the evaluator. Therefore, the determination of nucleus signal intensity is subjective and tends to vary.

According to the present results, quantitative measurement of nuclear signal intensity is proposed as a criterion for degeneration. Use of more quantitative MRI in the study of intervertebral disc degeneration *in vivo* has been carried out previously¹⁶⁻¹⁹. It might improve the inter-observer agreement of the evaluation of disc degeneration and exclude the observer's experience, whereas quantitative measurement of MRI might not be convenient under routine clinical conditions. Currently, research using artificial intelligence (AI) for image evaluation is being conducted, and its accuracy is considered to be high^{20,21}. AI could solve the problem of reproducibility and is likely to become a method of image evaluation in the near future.

It is considered that a degenerative cervical disc is a source of neck pain²², and the prevalence of disc degeneration was 67% in patients with neck pain²³. In the present study, disc degeneration was not more severe with shoulder stiffness than without it, because the mean age of those with shoulder stiffness was younger than that of participants without shoulder stiffness. After adjustment using a logistic regression model, the severity of disc degeneration in all five classifications on MRI was not associated with neck pain, shoulder stiffness, or neck symptoms (neck pain and shoulder stiffness). The Bone and Joint 2000-2010 Task Force on Neck

Pain reported that they did not identify any evidence demonstrating that disc degeneration is a risk factor for neck pain²⁴. The results of the present study suggest that disc degeneration of the cervical spine might not be the single key factor for the presence of neck-related symptoms. In addition, according to previous studies, the prevalence of Modic change in the cervical spine varied from 5% to 40%; type 2 was predominant, and type 3 was the least prevalent^{15,25}. The prevalence of Modic change was 5.4%, type 2 was the most common, and type 3 was the least common in the present study. The morphological findings were similar to those reported previously. In a cohort study, neck pain was independently associated with all types of Modic changes (odds ratio 2.7, 95% confidence interval 1.08-6.8), but shoulder stiffness was not²⁶. On the other hand, there were no differences in neck pain intensity, Neck Disability Index, and physical and mental component summaries of the 36-Item Short Form Health Survey in participants with or without Modic change²⁷. In the present study, there was no association between Modic change and clinical neck-related symptoms. The relationships of disc degeneration and Modic change with neck symptoms are still controversial, depending on the participant population in each study.

Even though Schmorl's nodes can be located at any level of the spine, they were located in the cervical spine in 5.9%, in the thoracic spine in 47.7%, and in the lumbar spine in 46.3%¹³. In the present study, the association with Schmorl's nodes was greater depending on both neck pain and neck symptoms, but not shoulder stiffness. Schmorl's nodes are seen in asymptomatic cases, but they can be a source of pain²⁸. There are not enough reports of evidence of an association between Schmorl's nodes in the cervical spine and clinical symptoms. In addition, the mechanism of different locations is not known; associations of factors with Schmorl's nodes should be investigated. In the previous study, it was found that there was an association between patients with severe neck pain of more than 5 points on the pain numerical rating scale and both cervical curvature and spondylolisthesis independently, but not MRI findings for disc degeneration or Modic change²⁹. On the other hand, it was reported that cervical disc degeneration was found in 60% of asymptomatic subjects³⁰. In the present study, there was no relationship between disc degeneration in each MRI classification and neck symptoms, however, the degree of neck symptoms was not evaluated in this study. Therefore, the association of be-

tween disc degeneration and severity of clinical symptoms is still uncertain.

The strength of this study is that five different kinds of MRI evaluations for disc degeneration were performed in individual participants. In addition, the distribution of each MRI item with and without clinical symptoms was evaluated, and associations among them were analyzed using a logistic regression model. Therefore, various morphological findings were compared to determine the possible pathogenesis of symptoms. Even though there was no specific classification of disc degeneration, there was no association between disc degeneration and symptoms. The second strength is that the data were obtained from a large community-based population, and various analyses have been performed, including the present study. Therefore, compared to a hospital-based survey, the results of the present study come from a real-world setting and are relevant for establishing the pathogenesis of cervical spine degeneration.

There were some limitations to the present study. First, only relatively healthy subjects were enrolled, and usually only those with any symptoms or more severe symptoms would undergo MRI. However, each possible MRI finding was distributed among all grades, and non-symptomatic participants agreed to undergo MRI. Therefore, compared to a hospital-based study, the benefit of this study was that all grades of morphological changes, including mild and unchanged cases, would be evaluated. Second, since the research location was in a rural and mountainous area, one may not be completely able to extrapolate the findings to the typical Japanese population. Third, the severity of neck symptoms was not examined. Therefore, the relationship between MRI findings and severity of clinical symptoms cannot be evaluated. Finally, this was a cross-sectional study; therefore, causal relationships between morphological changes and symptoms related to the cervical spine could not be determined.

Conclusion

In the present study, there was no difference among the five classifications in reproducibility; therefore, the simple evaluation method with higher accuracy is useful for routine clinical use. In addition, there was no specific classification for evaluating cervical disc degeneration by MRI that showed associations with clinical symptoms. Only the presence of Schmorl's nodes was strongly related to

neck symptoms, but not disc degeneration. In the future, it may be necessary to create a new classification system with simple and objective criteria for image evaluation to investigate cervical disc degeneration.

Acknowledgments

The authors would like to thank Dr. Akira Onda, Dr. Kazuya Yamauchi, Dr. Yoshiaki Takeyachi, Dr. Ichiro Takahashi, Dr. Hisayoshi Tachihara, and Dr. Bunji Takayama for participating in the data collection. The authors would also like to thank five public health nurses (Nobuko Fujita, Nakako Hoshi, Misako Hoshi, Naoko Imada, and Seiko Kanno) for their support in carrying out this study.

Disclosure

The authors declare no conflicts of interest associated with this manuscript.

References

1. Jacobs LJ, Chen AF, Kang JD, Lee JY. Reliable magnetic resonance imaging based grading system for cervical intervertebral disc degeneration. *Asian Spine J*, **10**(1): 70-74, 2016.
2. Peng B, DePalma MJ. Cervical disc degeneration and neck pain. *J Pain Res*, **11**: 2853-2857, 2018.
3. Fujimoto K, Miyagi M, Ishikawa T, *et al.* Sensory and autonomic innervation of the cervical intervertebral disc in rats: The pathomechanics of chronic discogenic neck pain. *Spine (Phila Pa 1976)*, **37**: 1357-1362, 2012.
4. Miyazaki M, Hong SW, Yoon SH, Morichita Y, Wang JC. Reliability of a Magnetic Resonance Imaging-based Grading System for Cervical Intervertebral Disc Degeneration. *J Spinal Disord Tech*, **21**(4): 288-292, 2008.
5. Suzuki A, Daubs MD, Hayashi T, *et al.* Patterns of Cervical Disc Degeneration: Analysis of Magnetic Resonance Imaging of Over 1000 Symptomatic Subjects. *Glob Spine J*, **8**(3): 254-259, 2018.
6. Nouri A, Martin AR, Mikulis D, Fehlings MG. Magnetic resonance imaging assessment of degenerative cervical myelopathy: a review of structural changes and measurement techniques. *Neurosurg Focus*, **40**(6): E5, 2016.
7. Nakashima H, Yukawa Y, Suda K, *et al.* Cervical disc protrusion correlates with the severity of cervical disc degeneration: A cross-sectional study of 1211 relatively healthy volunteers. *Spine (Phila Pa 1976)*, **40**(13): E774-779, 2015.

8. Matsumoto M, Fujimura Y, Suzuki N, *et al.* MRI of cervical intervertebral discs in asymptomatic subjects. *J Bone Joint Surg [Br]*, **80**(1) : 19-24, 1998.
9. Hirai T, Otani K, Sekiguchi M, *et al.* Epidemiological study of cervical cord compression and its clinical symptoms in community-dwelling residents. *PLoS ONE*, **16**(8) : e0256732, 2012.
10. Suzuki A, Daubs MD, Hayashi T, *et al.* Magnetic resonance classification system of cervical intervertebral disk degeneration. *Clin Spine Surg*, **30**(5) : E547-553, 2017.
11. Kawaguchi Y, Kanamoti M, Ishihara H, *et al.* The association of lumbar disc disease with vitamin D receptor gene polymorphism. *J Bone Joint Surg Am*, **84**(1) : 2022-2028, 2002.
12. Modic MT, Masaryk TJ, Ross JS, Cartter JR. Imaging of degenerative disk disease. *Radiology*, **168**(1) : 177-186, 1988.
13. Moustarhfir M, Bresson B, Koch P, *et al.* MR imaging of Schmorl's nodes : Imaging characteristics and epidemio-clinical relationships. *Diagn Intterv Imaging*, **97**(4) : 411-417, 2016.
14. Landis JR, Koch GG. The measurement of observer agreement for categorical data. *Biometrics*, **33**(1) : 159-174, 1977.
15. Yang X, Karis DSA, Vleggeert-Lankamp CLA. Association between Modic changes, disc degeneration, and neck pain in the cervical spine : a systematic review of literature. *Spine J*, **20**(5) : 754-764, 2020.
16. Kerttula L, Kurunlahti M, Jauhiainen J, *et al.* Apparent diffusion coefficients and T2 relaxation time measurements to evaluate disc degeneration. *Acta radiologica*, **42**(6) : 585-591, 2001.
17. Marinelli NL, Haughton VM, Anderson PA. T2 relaxation times correlated with stage of lumbar intervertebral disk degeneration and patient age. *Am J Neuroradiol*, **31**(7) : 1278-1282, 2010.
18. Niu G, Yang J, Wang R, *et al.* MR imaging assessment of lumbar intervertebral disk degeneration and age-related changes : Apparent diffusion coefficient versus T2 quantitation. *Am J Neuroradiol*, **32**(9) : 1617-1623, 2011.
19. Yu HJ, Bahri S, Gardner V, Muftuler LT. In vivo quantification of lumbar disc degeneration : assessment of ADC value using a degenerative scoring system based on Pfirrmann framework. *Eur Spine J*, **24**(11) : 2442-2448, 2014.
20. Savadjiev P, Chong J, Dohan A, *et al.* Demystification of AI-driven medical image interpretation : past, present and future. *European Radiology*, **29**(3) : 1616-1624, 2019.
21. Martín Noguerol T, Paulano-Godino F, Martín-Valdivia MT, Menias CO, Luna A. Strengths, Weaknesses, Opportunities, and Threats Analysis of Artificial Intelligence and Machine Learning Applications in Radiology. *J Am Coll Radiol*, **16**(9) : 1239-1247, 2019.
22. Peng B, DePalma MJ. Cervical disc degeneration and neck pain. *J Pain Res*, **11** : 2853-2857, 2018.
23. Jensen RK, Jensen TS, Gron S, *et al.* Prevalence of MRI findings in the cervical spine in patients with persistent neck pain based on quantification of MRI reports. *Chiropr Man Therap*, **27** : 13, 2019.
24. Hogg-Johnson S, van der Velde G, Carroll LJ, *et al.* The burden and determinants of neck pain in the general population : Results of the Bone and Joint Decade 2000-2010 Task Force on neck pain and its associated disorders. *Spine (Phila Pa 1976)*, **33**(4 Suppl) : S39-51, 2008.
25. Kanna RM, Shanmuganathan R, Rajagopalan VR, *et al.* Prevalence, patterns, and genetic association analysis of Modic vertebral endplate changes. *Asian Spine J*, **11**(4) : 594-600, 2017.
26. Tsuji T, Fujiwara H, Nishiwaki Y, *et al.* Modic changes in the cervical spine : prospective 20-year follow-up study in asymptomatic subjects. *J Orthop Sci*, **24**(4) : 612-617, 2019.
27. Yang X, Donk R, Arts MP, Vleggeert-Lankamp CLA. Are Modic vertebral end-plate signal change associated with degeneration clinical outcomes in the cervical spine? *World Neurosurg*, **129** : e881-889, 2019.
28. Kyere KA, Than KD, Wang AC, *et al.* Schmorl's nodes. *Eur Spine J*, **21**(11) : 2115-2121, 2012.
29. Kong L, Tian W, Cao P, *et al.* Predictive factor associated with neck pain in patients with cervical disc degeneration. *Medicine*, **96**(43) : 1-7, 2017.
30. Boden SD, McCowin PR, Davis DO, *et al.* Abnormal magnetic-resonance scans of the cervical spine in asymptomatic subjects. A prospective investigation. *J Bone Joint Surg*, **72**(8) : 1178-1184, 1990.