


# A case report of successful intravascular shockwave lithotripsy and *ad hoc* directional venous atherectomy of extensive chronic femoral deep venous thrombosis

Yashwant Agrawal<sup>1</sup>, Pramod Ponna<sup>1</sup>, Dominika M. Zoltowska <sup>2\*</sup>, and Abdul R. Halabi<sup>1</sup>

<sup>1</sup>St. Joseph Mercy Oakland Hospital, Pontiac, MI 48341, USA; and <sup>2</sup>University of Florida College of Medicine, Cardiovascular Disease Fellowship, Jacksonville, FL 32209, USA

Received 23 August 2020; first decision 29 September 2020; accepted 28 February 2021

## Background

Conventional treatment for chronic deep venous thrombosis (DVT) is anticoagulation. However, limited interventional endovascular options exist for patients with non-healing venous ulcers secondary to chronic DVT.

## Case summary

We present a case of 67-year-old man with severely symptomatic post-thrombotic syndrome (PTS) with persistent high-grade femoral DVT despite prior compressive therapy and chronic oral anticoagulation. It has been successfully treated with intravascular shockwave lithotripsy and *ad hoc* directional venous atherectomy facilitating subsequent mechanical thrombectomy and venoplasty. The procedure was without complication and resulted in significant clinical improvement.

## Discussion

We believe our novel endovascular interventional approach represents a unique modality of intervention for patients with chronic DVT and PTS resistant to conventional venoplasty.

## Keywords

Case report • Deep venous thrombosis • Thrombus • Intravascular ultrasound • Doppler ultrasound

## Learning points

- To understand the clinical presentation and the intravascular imaging features of chronic high-grade deep venous thrombosis (DVT) burden.
- To understand the role of intravascular shockwave lithotripsy and *ad hoc* 'venous atherectomy' as novel modalities to facilitate treatment of chronic high-grade DVT burden resistant to anticoagulation in the setting of post-thrombotic syndrome.

\* Corresponding author. Tel: 949-572-9669, Fax: 904-244-3629, Email: [dmzoltowska@gmail.com](mailto:dmzoltowska@gmail.com)

Handling Editor: Marco De Carlo

Peer-reviewers: Ivan Ilic and Ali Nazmi Calik

Compliance Editor: Kajaluxy Ananthan

Supplementary Material Editor: Deepti Ranganathan

© The Author(s) 2021. Published by Oxford University Press on behalf of the European Society of Cardiology.

This is an Open Access article distributed under the terms of the Creative Commons Attribution Non-Commercial License (<http://creativecommons.org/licenses/by-nc/4.0/>), which permits non-commercial re-use, distribution, and reproduction in any medium, provided the original work is properly cited. For commercial re-use, please contact [journals.permissions@oup.com](mailto:journals.permissions@oup.com)

## Introduction

Conventional treatment for chronic deep venous thrombosis (DVT) is anticoagulation. Nevertheless, about 50% of patients with iliofemoral DVT develop post-thrombotic syndrome (PTS) despite medical therapy.<sup>1</sup> Limited interventional endovascular options exist for patients with non-healing venous ulcers secondary to PTS. We present resolution of high-grade femoral DVT with intravascular shockwave lithotripsy and *ad hoc* directional venous atherectomy facilitating subsequent mechanical thrombectomy and venoplasty associated with significant clinical improvement.

## Timeline

|   |   |
|---|---|
| Initial presentation                    | Evaluation of chronic bilateral deep venous thrombosis (DVT) with progressive symptoms of lower extremity oedema and venous ulcers despite aggressive medical management.   |
| Diagnostic work up                      | Lower extremity USN: chronic DVTs involving bilateral proximal, mid and distal femoral, popliteal, and left peroneal veins. Normal arterial flow.   |
| Intervention                            | <p>Venogram with intravascular ultrasound (IVUS): complete occlusion of proximal and mid femoral vein.</p> <p>High pressure venoplasty with 10.0 × 40 mm Dorado Balloon and 6.0 × 40 mm angiosculpt.</p> <p>Intravascular lithotripsy via 7.0 × 60 mm balloon at the level of mid left femoral vein with total of 180 pulses.</p> <p>TurboHawk LX 'venous atherectomy'.</p> <p>Venoplasty with 7.0 × 20 mm cutting balloon finally yielded the lesion</p> <p>IVUS evaluation showed patency of left femoral vein.</p> <p>Mechanical thrombectomy with Inari device.</p> <p>Final excellent venographic results.</p> |
| Follow-up (2 weeks, 1, 3, and 6 months) | Progressive resolution of oedema and venous ulcers. Repeat USN with patent veins.   |

## Case presentation

A 67-year-old man was referred to our facility for extensive left lower extremity (LLE) venous ulcers. He reported an increase in the size and number of LLE venous ulcers, which initially developed 6 months prior. He failed previous wound and compressive management with plastic surgery as well as multiple oral and intravenous antibiotic regimens. He was Clinical-Etiology-Anatomical-Pathophysiology (CEAP) Class 6 upon referral. Initial vitals were

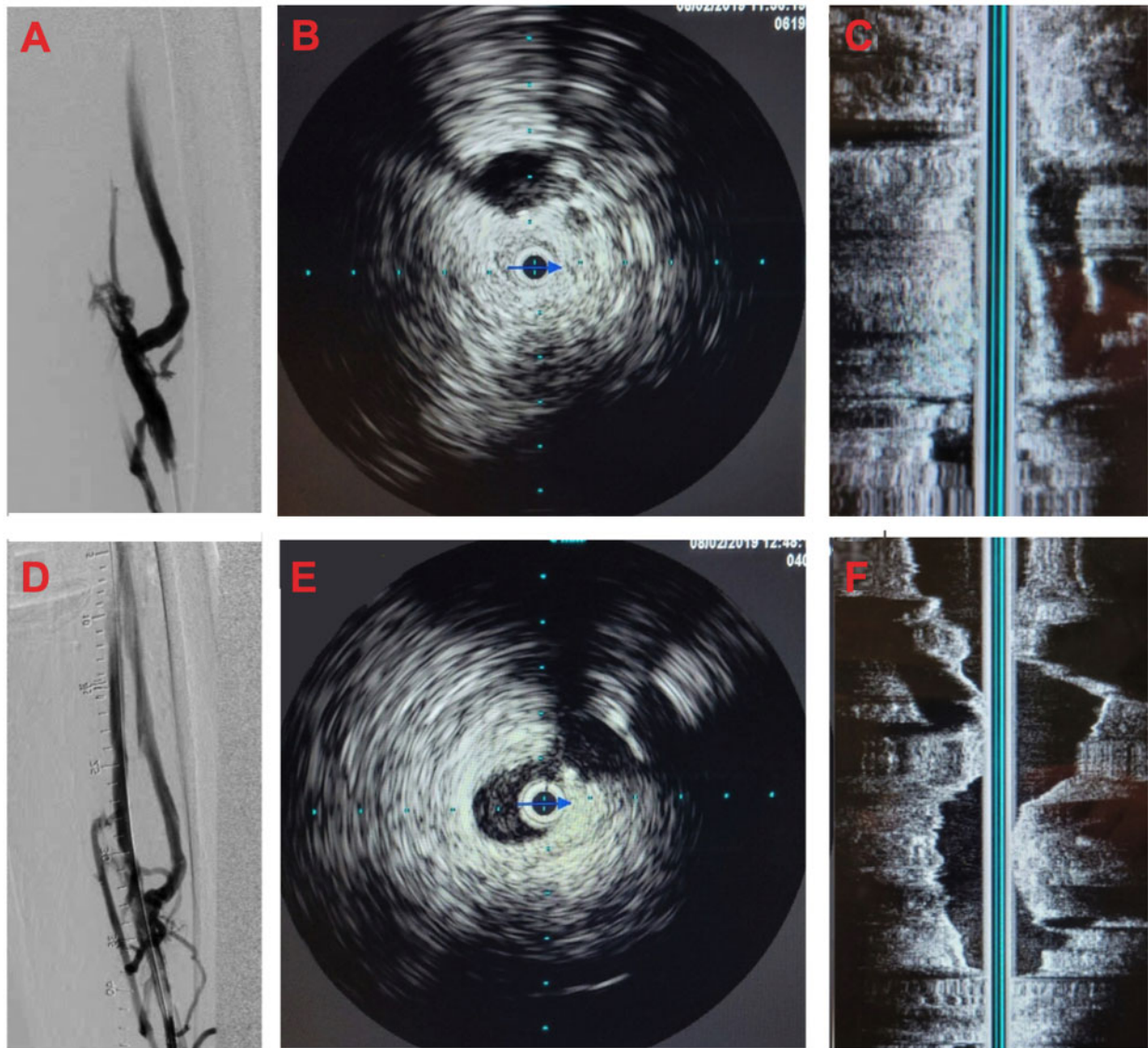
normal. Physical exam revealed significant bilateral leg oedema, with purple discoloration and increased skin pigmentation on both sides, most pronounced in the calf area. Findings were worse on the left side with 4+ LLE oedema and multiple large ulcers with diameter up to 7 cm involving the anterior, posterior, and medial aspects of the left calf with associated warmth to touch and tenderness. The right lower extremity (LE) was asymptomatic and without venous ulcers. Peripheral pulses in the bilateral LE were 2+. The remainder of the physical exam was normal. He denied chest pain, dyspnoea, claudication, trauma, palpitations, syncope and any history of pulmonary embolism, pulmonary artery hypertension, chronic heart failure, and smoking.

The patient has a history of hypertension, sleep apnoea on continuous positive airway pressure therapy (CPAP), hyperlipidaemia, obesity, chronic atrial fibrillation on apixaban 5 mg BID, chronic venous insufficiency (CEAP Class 6), and bilateral chronic femoral DVT.

Initial labs were unremarkable (Hgb 14.2 g/dL, WBC  $7.9 \times 10^9$  per L, Plt  $329 \times 10^3$  per  $\mu$ L, Na 142 mEq/L, K 4.5 mEq/L, Glu 94 mg/dL, Cr 0.95 mg/dL, INR 1.2, CRP 2.5 mg/L). Lower extremity venous ultrasound (US) revealed evidence of chronic DVTs involving the bilateral proximal, mid and distal femoral (FV), popliteal (PV), and left peroneal veins (PerV). He had evidence of reflux within the common FVs and the PVs. Lower extremity arterial US showed no significant peripheral artery disease with normal toe-brachial indices.

With non-healing LLE venous ulcers related to severe venous hypertension exacerbated by chronic DVT involving the LFs and LPVs, we suspected PTS with superimposed left leg venous stenosis/compression. We considered Left femoral vein (LFV) and left popliteal vein (LPV) mechanical thrombectomy as an option during catheterization, keeping in mind that this intervention in this context is technically difficult with mixed odds of success given his chronic thrombus burden. He was taken to the catheterization lab where US-guided LPV access was undertaken.

Selective LFV venogram revealed extensive organized thrombus within the LFV below the left common FV (LCFV) confluence with the saphenous and profunda veins. There was complete occlusion of the proximal and mid-LFV (*Figure 1A*) (*Video 1*). Furthermore, the proximal and mid-LFV demonstrated chronic thrombus and PTS changes. Thereafter, intravascular ultrasound (IVUS) Visions PV.035 Digital IVUS Catheter (Philips, Amsterdam, the Netherlands) of the left iliofemoral vein (ILV) confirmed its patency without evidence of compression, stenosis, or DVT. It demonstrated significant scarring and a 'rubbery' appearance of the venous walls throughout the LFV. Using IVUS imaging, the superior and mid-distal portions of the LFV appeared most impacted with chronic thrombus (*Figure 1B and C*). Subsequently, he underwent high pressure venoplasty of the LCFV and entire LFV with 10 × 40 mm Dorado balloon (Bard, Tempe, AZ, USA). The mid-LFV had an area of very high-grade stenosis that would not yield. AngioSculpt balloon 6 × 40 mm (AngioScore, Brandin Court Fremont, CA, USA) was used similarly without success. The high-grade LFV occlusion demonstrated a persistent 'dog-bone/waist' appearance (*Figure 2A*). We then decided to perform intravascular shockwave lithotripsy (IVSL) empirically. Shockwave balloon 7 × 60 mm (Shockwave Medical, Fremont, CA, USA) was therefore positioned at the level of the mid-LFV and 180 pulses at 2,



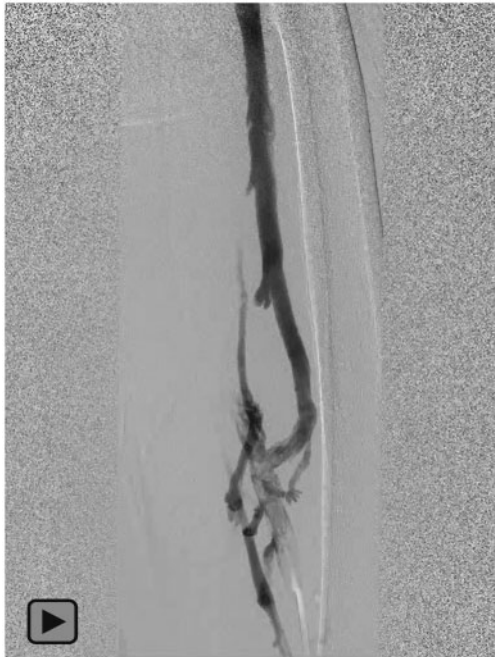
**Figure 1** Initial venogram (A) with extensive organized chronic thrombus with significant scarring on intravascular ultrasound imaging (B, C). Post-intervention venogram (D) with improved and patent lumen (E, F).

4, and 6 atmospheres were delivered to prime the lesion for further intervention. Subsequently, TurboHawk LX extended tip device (Medtronic, Minneapolis, MN, USA) was empirically used for multiple passes of *ad hoc* 'venous atherectomy' along the affected segment, resulting in retrieval of a significant amount of red, rubbery organized material suggestive of chronic DVT. Venoplasty with 7 × 20 mm cutting balloon (Boston Scientific, Marlborough, MA, US) finally yielded the mid-LFV culprit lesion successfully (Figure 2B).

Post-intervention venogram revealed improved flow, but with high-grade stenosis at the level of the LCFV and superior portion of the LFV. Therefore, further venoplasty was performed using 10 × 40 mm Dorado balloon.

Subsequent IVUS demonstrated patent LCFV and LFV with significantly improved luminal diameter and gain. However, we

visualized both residual organized and fragmented thrombus. Mechanical thrombectomy with FlowTriever device (Inari Medical, Irvine, CA, USA) then yielded the thrombus fragment. Intravascular ultrasound-guided venoplasty using Cook Advance 12 × 40 mm balloon (Cook Medical LLC, Bloomington, IN, USA) was performed on the affected superior portion of the LFV at the level of the initially occlusive cap and within the mid-LFV at the level of the aforementioned high-grade occlusive stenosis. Final post-intervention IVUS and venogram demonstrated patent LFV with improved lumen and recovered antegrade LFV flow throughout, and towards the LCFV (Figure 1D–F, Video 2). He tolerated the procedure well without complications and received aspirin and IV heparin with activated clotting time maintained at therapeutic levels.

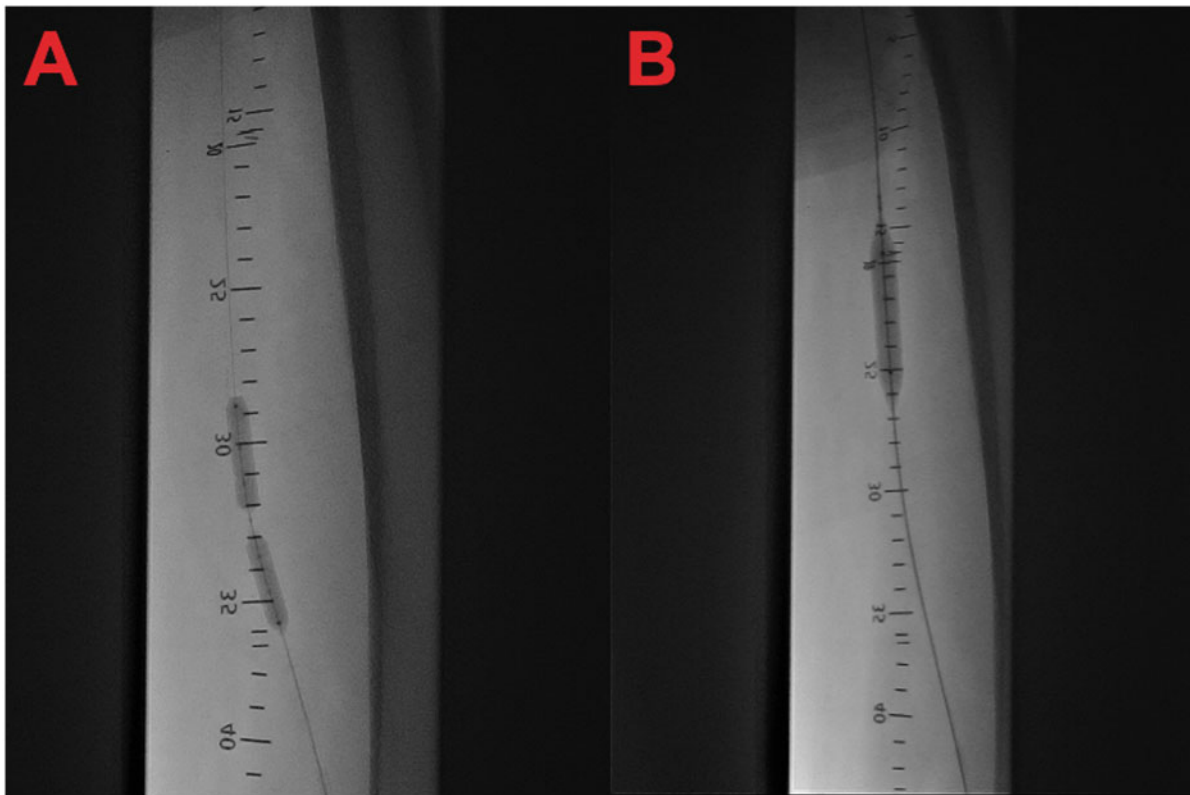


**Video 1** Initial pre-intervention venogram. One hundred per cent occlusion of the proximal and mid-LFV.

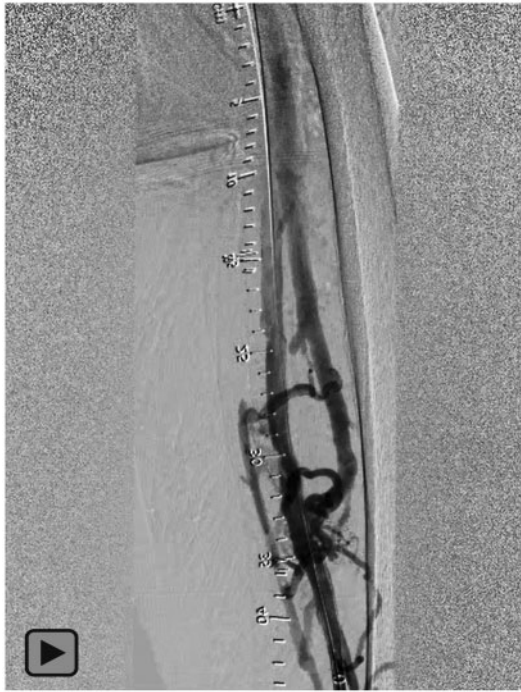The patient was seen in an office visit at 2, 8, and 12 weeks post-intervention. Symptoms had improved with resolution of LE oedema to +1 and resolution of venous ulcers. He continued wound care, chronic anticoagulation, and compressive therapy. Repeat US at every follow-up showed no re-occlusion of the LFV.

## Discussion

Traditionally, anticoagulation is the mainstay of medical therapy for proximal DVTs involving the PVs, FVs, and ILVs in the absence of contraindications.<sup>2</sup> The 10th Edition of the Antithrombotic Guideline recommends novel anticoagulant over vitamin K inhibitor for treatment of DVT based on results of randomized clinical trials.<sup>3</sup> In cases of proximal DVT, the impetus to begin anticoagulation therapy is greater than in patients with distal DVTs with complication rates cited at 8% vs. 4%, respectively.<sup>2</sup> Furthermore, patients with chronic DVTs are at risk of developing PTS.<sup>4,5</sup> Symptoms of PTS include leg pain, venous dilatation, oedema, skin pigmentation, and venous ulceration. These are the result of increased venous pressures causing transudation secondary to thrombus burden decreasing or occluding venous outflow.<sup>4,5</sup> Incidence of PTS is reported as ~50% in the 1st year in chronic DVT patients despite anticoagulation.<sup>5</sup> Recurrent ipsilateral DVT formation is strongly associated with the risk of developing PTS.<sup>6</sup> Treatment with catheter-directed thrombolysis (CDT) and percutaneous venous intervention (PEVI) as the adjunct to standard



**Figure 2** Venoplasty. (A) High pressure venoplasty with 'dog-bone/waist' appearance. (B) Cutting balloon venoplasty yielding the thrombus.



**Video 2** Final post-intervention venogram. Recovered LFBV flow.

anticoagulation has been investigated. Study results were implying that combine therapy can result in reduced number of PTS, DVT recurrence, and increased venous patency in short-term follow-up at the expense of increased risk of bleeding.<sup>6</sup> However, more recent multicentre randomized clinical trial, the ATTRACT, did not confirm the advantage of CDT in the treatment of acute DVT.<sup>7</sup> Current guidelines recommend against routine CDT in acute proximal DVT and do not comment on PEVI.<sup>3</sup>

Treatment for PTS and associated chronic extremity changes includes exercise, extremity elevation, compression therapy, skin, and ulcer care in addition to guideline-directed anticoagulation. In patients with chronic DVTs and PTS resistant to conservative guideline-directed management endovascular intervention is an option.<sup>8–10</sup> Nayak *et al.*<sup>8</sup> described endovascular intervention with ILV stenting and laser ablation in patients with established PTS to be associated with complete or partial symptom relief in 80% of patients at short-term follow-up.<sup>6</sup> Furthermore, Rollo *et al.* report acceptable 1-year patency rates, healing of ulcers, and significant reductions in CEAP scores with ilio caval and infrainguinal venous stenting for treatment of chronic DVT. However, Attaran *et al.* discuss chronic FV and PV DVT treatment in the PTS context to be limited to venoplasty, which itself can be restricted by resistant organized thrombus and chronic luminal changes causing recoil and/or re-occlusion.<sup>10</sup> There is limited literature on an IVSL approach in patients with chronic and extensive femoro-popliteal DVT burden resistant to anticoagulation and venoplasty in the setting of PTS. Currently, the major limitation for expansive use of percutaneous intravenous intervention is lack of evidence for sustained long-term improvement. There is also limited literature on an IVSL approach in patients with

chronic and extensive femoro-popliteal DVT burden resistant to anticoagulation and venoplasty in the setting of PTS.

## Conclusion(s)

We present a case of successful IVSL-facilitated *ad hoc* 'venous atherectomy', mechanical thrombectomy and venoplasty of high-grade chronic DVT burden in the setting of PTS for the treatment of worsening CEAP Class 6 ulcers failing non-invasive conventional management. We believe our novel endovascular interventional approach represents a unique modality of intervention for patients with chronic DVT and PTS resistant to conventional venoplasty.

## Lead author biography



Yashwant Agrawal is a current Interventional Cardiology Fellow at Borgess Medical Center, MI. He graduated from Medicine Pediatrics Programme at Western University of Michigan in Kalamazoo and completed his training in General Cardiology at St Joseph Mercy Oakland Hospital in Pontiac. His special area of interest includes acute myocardial infarction with cardiogenic shock.

## Supplementary material

[Supplementary material](#) is available at *European Heart Journal - Case Reports* online.

**Slide sets:** A fully edited slide set detailing this case and suitable for local presentation is available online as [Supplementary data](#).

**Consent:** The authors confirm that written consent for the submission and publication of this case, including images, has been obtained from the patient in line with COPE guidance

**Conflict of interest:** None declared.

**Funding:** None declared.

## References

1. Enden T, Haig Y, Klow NE, Slagsvold C-E, Leiv Sandvik L, Ghanima W, CaVenT Study Group *et al.* Long-term outcome after additional catheter-directed thrombolysis versus standard treatment for acute iliofemoral deep vein thrombosis (the CaVenT study): a randomised controlled trial. *Lancet* 2012;**379**:31–38.
2. Galanaud JP, Sevestre-Pietri MA, Bosson JL, Laroche JP, Righini M, Brisot D, The OPTIMEV-SFMV Investigators *et al.* Comparative study on the risk factors and early outcome of symptomatic distal versus proximal deep vein thrombosis: Results from the OPTIMEV study. *Thromb Haemost* 2009;**102**:493–500.
3. Kearon C, Akl EA, Ornelas J, Blaivas A, Jimenez D, Bounameaux H *et al.* Antithrombotic therapy for VTE disease: CHEST guideline and expert panel report. *Chest* 2016;**149**:315–352.
4. Nicolaides AN, Hussein MK, Szendro D, Christopoulos D, Vasdekis S, Clarke H. The relation of venous ulceration with ambulatory venous pressure measurements. *J Vasc Surg* 1993;**17**:414–419.

5. Roumen-Klappe EM, den Heijer M, Jansen MC, van der Vleuten C, Thien T, Wollersheim H. The post-thrombotic syndrome: incidence and prognostic value of non-invasive venous examinations in a six-year follow-up study. *Thromb Haemost* 2005;**94**:825–830.
6. Labropoulos N, Jen J, Jen H, Gasparis AP, Tassiopoulos AK. Recurrent deep vein thrombosis: long-term incidence and natural history. *Ann Surg* 2010;**251**:749–753.
7. Vedantham S, Goldhaber SZ, Julian JA, Kahn SR, Jaff MR, Cohen DJ et al. Pharmacomechanical catheter-directed thrombolysis for deep-vein thrombosis. *N Engl J Med* 2017;**377**:2240–2252.
8. Nayak L, Hildebolt CF, Vedantham S. Postthrombotic syndrome feasibility of a strategy of image-guided endovascular intervention. *J Vasc Interv Radiol* 2012;**23**:1165–1173.
9. Rollo JC, Farley SM, Jimenez JC, Woo K, Lawrence PF, DeRubertis BG. Contemporary outcomes of elective ilio caval and infrainguinal venous intervention for post-thrombotic chronic venous occlusive disease. *J Vasc Surg Venous Lymphat Disord* 2017;**5**:789–799.
10. Attaran R, Abdelghany M, Mena-Hurtado C. Lower extremity venoplasty with the shockwave lithotripsy balloon. *Cath Lab Digest* 2019;**27**:783–784.