

# 2-Mm Diameter Operative Tendoscopy of the Tibialis Posterior, Peroneal, and Achilles Tendons: A Cadaveric Study

Foot & Ankle International<sup>®</sup>  
2020, Vol. 41(4) 473–478  
© The Author(s) 2019



Article reuse guidelines:  
sagepub.com/journals-permissions  
DOI: 10.1177/1071100719895504  
journals.sagepub.com/home/fai

Tobias Stornebrink, MD<sup>1,2,3</sup> , Sjoerd A. S. Stufkens, MD, PhD<sup>1,2,3</sup>,  
Daniel Appelt, PhD<sup>4</sup>, Coen A. Wijdicks, PhD<sup>4</sup>,  
and Gino M. M. J. Kerkhoffs, MD, PhD<sup>1,2,3</sup>

## Abstract

**Background:** Technical innovation now offers the possibility of 2-mm-diameter operative tendoscopy with disposable arthroscopes and tablet-like control units. The promises of new technology should be critically scrutinized. Therefore, this study assessed whether 2-mm-diameter operative tendoscopy of the tibialis posterior, peroneal, and Achilles tendons was safe and effective in a cadaveric model.

**Methods:** A 2-mm-diameter arthroscopic system was used to perform a tendoscopic procedure in 10 nonpaired, fresh-frozen, human ankles. Standard tendoscopic portals were utilized. Visual examination and operative reach with tailored tendoscopic instruments within the tendon sheaths were recorded and documented. Adhesiolysis and vincula resections were performed. After dissection, distances between portal tracts and neurovascular structures were measured and the tendons were inspected for signs of iatrogenic damage.

**Results:** The entire tendon sheath and tendon of the tibialis posterior, peroneus brevis, and Achilles tendons were visualized and reached with tailored operative instruments. The proximal part of the peroneus longus tendon was visible and reachable from proximally up to the cuboid bone distally. Adhesiolysis and vincula resections were successfully performed in all specimens. The mean distances between portal tracts and local neurovascular structures ranged between 9.4 and 19.2 mm and there were no cases of contact. None of the tendons showed signs of iatrogenic damage.

**Conclusion:** Two-millimeter-diameter operative tendoscopy provided safe and effective visualization and operative reach of the tibialis posterior, peroneal, and Achilles tendons.

**Clinical Relevance:** Compared with current practice, 2-mm-diameter operative tendoscopy has the potential to make tendoscopy around the ankle less invasive and more accessible. Diagnostic, interventional, and second-look procedures might be performed at substantially reduced risk, time, and costs.

**Keywords:** tendoscopy, nanoscope, ankle, tibialis posterior, peroneals, Achilles, innovation, safety, efficacy

## Introduction

Endoscopic pathways to tendons around the ankle have been described since the 1990s.<sup>3,17,22</sup> Since then, tendoscopy has been shown to be of help in both the diagnosis and treatment of tendon pathology. It directly visualizes tendon defects, which is of important extra value in addition to conventional imaging modalities such as magnetic resonance imaging (MRI), especially in the case of subtle disease.<sup>2,12,13</sup> Several case series suggest that tendoscopic operative intervention results in a lower complication rate and faster recovery compared with open surgery.<sup>4,18,19</sup>

Despite its advantages compared with open surgery, there is still room for improvement in the practice of tendoscopy. Tendoscopy, for example, is still a relatively invasive

<sup>1</sup>Department of Orthopedic Surgery, Amsterdam Movement Sciences, Amsterdam UMC, University of Amsterdam, Amsterdam, The Netherlands

<sup>2</sup>Academic Center for Evidence Based Sports Medicine (ACES), Amsterdam, The Netherlands

<sup>3</sup>Amsterdam Collaboration for Health and Safety in Sports (ACHSS), International Olympic Committee (IOC) Research Center, Amsterdam UMC, Amsterdam, The Netherlands

<sup>4</sup>Department of Orthopedic Research, Arthrex GmbH, Munich, Bayern, Germany

### Corresponding Author:

Gino M. M. J. Kerkhoffs, MD, PhD, Department of Orthopedic Surgery, Amsterdam Movement Sciences, Amsterdam UMC, Location AMC, University of Amsterdam, Meibergdreef 9, Room K1-207, Amsterdam, 1105 AZ, The Netherlands.

Email: g.m.kerkhoffs@amsterdamumc.nl

procedure that most often requires general or spinal anesthesia and an operating room, along with its large staff. In addition, the currently available conventional rod-lens arthroscopes with a small diameter that are most convenient for tendoscopy are more prone to breakage than their larger-bore peers.<sup>5</sup> All these downsides decrease the appeal of tendoscopy, especially for purely diagnostic indications.

A more durable, less invasive, and more convenient technology may benefit the accessibility of tendoscopy. For this purpose, needle arthroscopy was introduced in the 1990s as an alternative to conventional rod-lens arthroscopes. However, its inferior image quality and lack of tailored surgical tools limited diagnostic accuracy and restricted its use for operative indications.<sup>9</sup> In addition, needle arthroscopic control units often consisted of large, cumbersome devices.<sup>6</sup> Consequently, needle arthroscopy was never adopted in daily practice and never used in tendons.

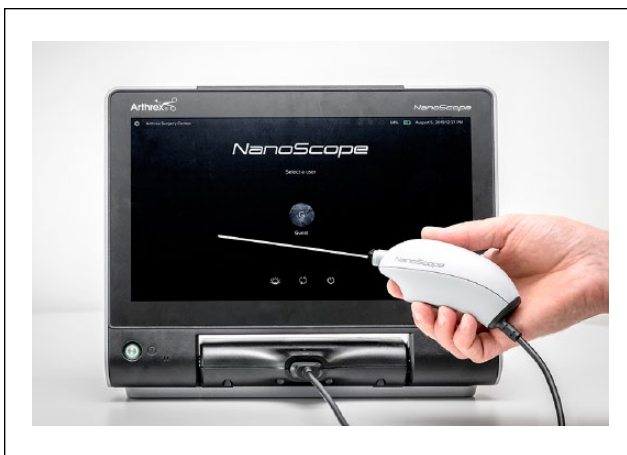In this study, we introduce tendoscopy with a newly released alternative to rod-lens arthroscopy that uses a disposable, chip-on-tip camera. This technology could facilitate tendoscopy with a semirigid, durable combination of arthroscope and cannula, with its total diameter just over 2 mm. Compared with the needle arthroscopes of the past, this new system uses a substantially improved image quality, while its control unit has decreased to a tablet-like dimension. With tailored 2-mm-diameter operative instruments, 2-mm-diameter operative tendoscopy seems to be possible.

New technology requires a new body of scientific evidence. This evidence should scrutinize the claims that are made by the technology in order to ensure safe and effective use for surgeons and the patients they treat. Although 2-mm-diameter operative tendoscopy seems to hold the potential to improve the accessibility of tendoscopy, its suitability for this purpose has not yet been evaluated. Therefore, the aim of this study was to assess whether 2-mm-diameter operative tendoscopy could safely visualize and operatively reach all important structures in the sheath of the tibialis posterior, peroneal, and Achilles tendons.

## Methods

### Specimens

Ten nonpaired, fresh-frozen, human lower leg specimens without a known or apparent history of surgery to the ankle or its tendons were selected (4 male, 6 female; mean age, 72 years). Specimens were amputated at the level of the proximal tibia for fixation purposes. The study was conducted in agreement with the 1964 Helsinki Declaration and its later amendments. Specimens were obtained through the Science Care donation program and donated with consent for use in medical science.



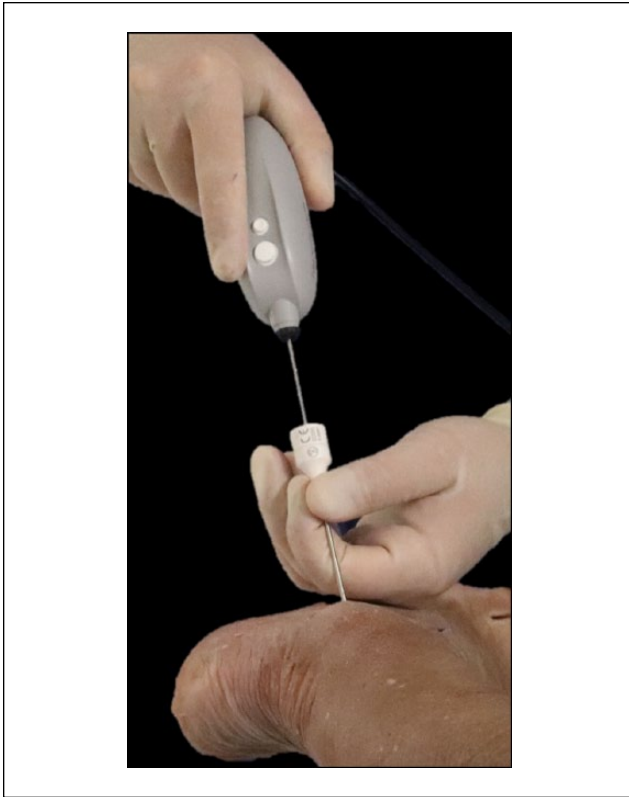
**Figure 1.** The arthroscopic system that was used in this study consists of a tablet-like, medical-grade control unit and a separate, disposable handpiece.

### Tendoscope

An arthroscopic system (NanoScope; Arthrex, Naples, FL) was used for the tendoscopic procedures. This system consisted of 2 main components: a disposable handpiece and a tablet-like, medical-grade control unit (Figure 1). The handpiece contained a LED light source, an illumination system, and a detection system. The detection system was located at the distal end (chip-on-tip technology) of the 9.5-cm-long, semirigid handpiece tube, which had a 1.9-mm outer diameter. It had a 0-degree direction of view with a 120-degree field of view. The sensor chip had a pixel number of  $400 \times 400$ . The system came with accessories such as tailored cannulas and custom arthroscopic instruments for interventional use. With a diameter of 2.0 mm, the custom arthroscopic instruments were designed to allow for 2-mm-diameter operative arthroscopy. The system's cannula (2.26-mm outer diameter) was used for scope insertion and to maintain joint access. Distention systems could be connected to the cannula, and distention media passed between the scope and inner cannula wall.

### Procedure

A sports medicine and ankle fellowship-trained orthopedic surgeon (G.M.M.J.K.) with extensive experience in tendoscopies performed a protocol procedure in each specimen. The specimens were rigidly fixated to a workbench, with the ankle in prone position. For each tendon, standard tendoscopic portals were used. For tendoscopy of the tibialis posterior and peroneal tendons, portals were created according to Reilingh et al,<sup>11</sup> with a proximal and a distal portal placed directly over each tendon. For tendoscopy of the Achilles tendon, portal descriptions by Vega et al<sup>19</sup> were followed, with a distal portal at the lateral margin of the



**Figure 2.** Outside view during a 2-mm-diameter tendoscopic procedure. The camera is introduced through its tailored cannula.

tendon and a proximal portal in the midline. Portal placement started with 2-mm skin incisions parallel to the tendons, as recommended.<sup>20</sup> The 2.26-mm-diameter cannula was inserted with help of a 1.9-mm-diameter blunt obturator, again parallel to the tendon. The obturator was removed and the arthroscope was introduced through the cannula (Figure 2). Portals were interchangeably used as a visualization portal and a working portal. A laparoscopic insufflator (Arthrex, Naples, FL) provided distention with carbon dioxide.

Two ankle fellowship-trained, experienced orthopedic surgeons (G.M.M.J.K., S.A.S.S.) systematically recorded the visualization and operative reach in each tendon. They were instructed to visualize and reach the entire inner tendon sheath, from proximal to distal, and the entire course of the tendon in its sheath. Successful visualization, limits to visualization, and any additional portals required for proper visualization were documented. The system's 2-mm-diameter retractable probe (NanoProbe; Arthrex, Naples, FL) was used as a proxy for operative instruments. This probe was advanced to the most proximal and most distal points in the synovial sheaths as safely as possible. In addition, adhesiolysis was performed where necessary, and, if present, vincula resections were performed in each

tendon of each specimen. The arthroscope itself and the probe were used for adhesiolysis, and the system's 2-mm-diameter arthroscopic biter (NanoBiter; Arthrex, Naples, FL) was used for vincula resections. The success of operative procedures, limits to operative procedures, and additional portals required for operative procedures were critically documented.

At the end of the tendoscopic procedures, the portal tracts were replaced with 1.8-mm-diameter Kirschner wires, and detailed anatomic dissection was performed. Dissection protocols were derived from previous literature and focused on the posterior neurovascular bundle in relation to the tibialis posterior portals.<sup>11</sup> The focus was on the sural nerve in relation to the peroneal and Achilles tendons.<sup>1,20</sup> A calibrated dial caliper with 0.01-mm precision was used to measure the distance between these structures and the portal tracts. In addition, both orthopedic surgeons visually inspected each tendon for macroscopically apparent iatrogenic damage.

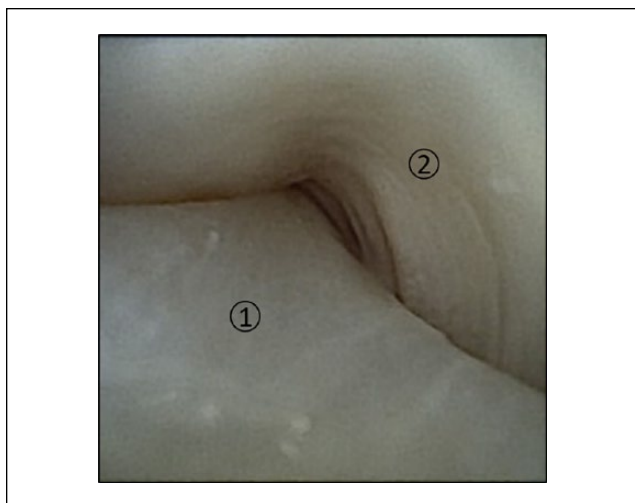
### Analysis

A Shapiro-Wilk test determined the normality of the distribution of each set of distances between a portal and its surrounding tissue. Mean distances and confidence intervals were presented in the case of normal distributions. Otherwise, medians and interquartile ranges were reported. All analyses were performed in StataSE 15 (StataCorp, College Station, TX).

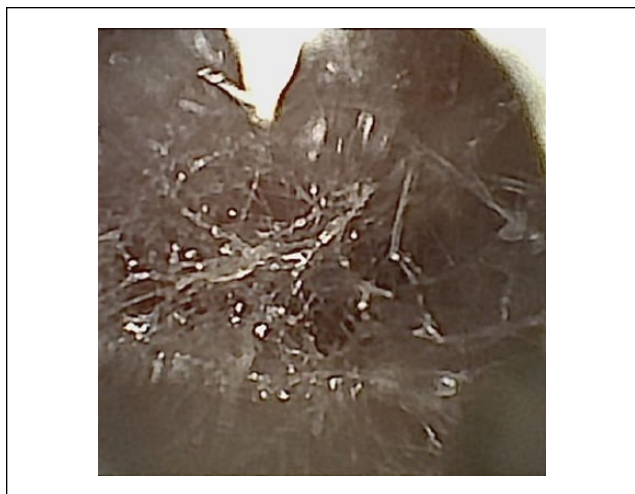
### Results

In all specimens, the inner tendon sheath of the tibialis posterior tendon was successfully visualized on all sides from its proximal to distal ends (Figure 3). There was a vinculum present at the proximal end in all specimens. For the peroneal tendons, it was possible to visualize the proximal end of the common tendon sheath in all specimens, with a constant proximal vinculum present in all cases. More distally, both peroneal tendons were successfully inspected on all sides in their own tendon sheath. While the peroneus brevis tendon was distally successfully inspected up to its insertion, visualization of the peroneus longus tendon was distally restricted from the point where it curves beneath the cuboid. The Achilles tendon was easily visualized along its entire course from its insertion at the calcaneus to its proximal trajectory. Visual reach here depended on portal placement, with more proximally located portals needed for the inspection of more proximal areas, and vice versa for more distal parts.

The boundaries of reach with operative instruments in all tendons were similar to the boundaries of visualization described above. Insufflation with carbon dioxide to some extent often caused adhesiolysis (Figure 4). In general,



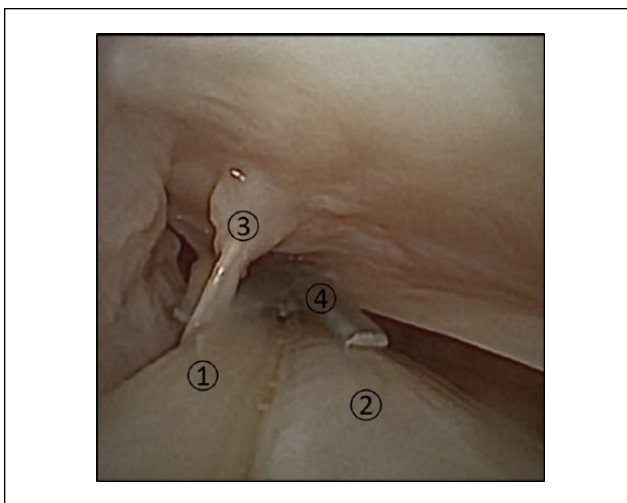
**Figure 3.** Visualization of the tibialis posterior tendon during 2-mm-diameter tendoscopy. (1) Tibialis posterior tendon. (2) Tendon sheath.



**Figure 4.** Adhesions between the peritenon and Achilles tendon, visualized during insufflation with carbon dioxide. Hence, a successful adhesiolysis is well possible with 2-mm-diameter tendoscopy.

removal of obstructing adhesions was possible with the scope itself. Where needed, the probe and biter provided assistance and made complete adhesiolysis possible in all cases. With the biter, vincula resections were successfully performed in each tendon, in all specimens (Figure 5).

None of the portal tracts were in contact with neurovascular structures, and the mean separating distances ranged from 9.4 to 19.2 mm (Tables 1 and 2). There were no signs of iatrogenic damage to the tendons in any of the specimens. However, in 1 specimen, insufflation of the peroneal tendons resulted in localized subcutaneous gas collection.



**Figure 5.** Visualization of a vinculum in the peroneal tendon sheet. If impingement complaints arise, a vinculum resection can be performed well through 2-mm-diameter operative tendoscopy. (1) Peroneus brevis tendon. (2) Peroneus longus tendon. (3) Vinculum. (4) Tailored arthroscopic biter, ready for vinculum release.

## Discussion

The aim of this study was to evaluate the safety and efficacy of 2-mm operative tendoscopy, an alternative to tendoscopy with conventional, rod-lens cameras. With a 2-mm-diameter arthroscopic system, it was possible to visualize and operatively reach all structures relevant for tendoscopy of the tibialis posterior, peroneal, and Achilles tendons, without causing iatrogenic damage to surrounding tissue or the tendons themselves.

The image quality was high and all relevant structures were easily examined. This confirms the significant increase of 2-mm-diameter arthroscopy's image quality compared with previous alternatives to conventional rod-lens cameras.<sup>9</sup> It was possible to visually inspect and operatively reach the entire tibialis posterior tendon and its sheath, the peroneus brevis tendon and its sheath, the better part of the peroneus longus tendon, and the entire Achilles tendon. Conventional tendoscopy of these tendons generally offers a similarly wide visual and operative reach, especially with smaller-diameter cameras.<sup>11,17</sup> With large-bore systems, movement inside the tendon sheath can be restricted, which may hamper examination.<sup>5</sup> However, conventional rod-lens cameras become prone to breakage as their diameter is decreased.<sup>5</sup> With chip-on-tip technology, there was no need for rod-lenses inside the camera tube, making it semirigid and durable, despite its small diameter.

None of the portal tracts came in contact with local neurovascular structures, and distances between portals and such tissue were sufficiently high. This demonstrated the safety of endoscopic tendon surgery. During open surgery,

**Table 1.** Distances Between Tendoscopic Portals and the Sural Nerve.

Portal	Shapiro-Wilk W (P Value)	Mean Distance, mm	95% CI	Cases of Contact
Peroneals, proximal	0.85 (.061)	14.5	11.4-17.7	0
Peroneals, distal	0.93 (.486)	9.4	4.6-14.2	0
Achilles, proximal	0.92 (.343)	13.4	9.1-17.6	0
Achilles, distal	0.95 (.637)	17.7	12.2-23.3	0

**Table 2.** Distances Between Tendoscopic Portals and the Posterior Neurovascular Bundle.

Portal	Shapiro-Wilk W (P Value)	Mean Distance, mm	95% CI	Median Distance, mm	Interquartile Range	Cases of Contact
Tibialis posterior, proximal	0.79 (.012)	—	—	11.6	11.3-16.3	0
Tibialis posterior, distal	0.95 (.655)	19.2	15.6-22.9	—	—	0

the posterior neurovascular bundle medially and the sural nerve laterally are in close proximity to the operating field. In addition, due to relatively limited vascularization of the hindfoot,<sup>10</sup> open surgery can result in high rates of wound healing problems and symptomatic scar tissue.<sup>5</sup> Conventional endoscopic surgery of tendons around the ankle already substantially decreased complication rates.<sup>4,14,16</sup> Nonetheless, distances between conventional tendoscopic portals and neurovascular structures are not frequently reported in the literature. In a cadaveric study, Marmotti et al<sup>8</sup> found an average distance of 3.9 mm between the distal peroneal portal and the sural nerve, which seems to be of higher risk than the 9.4 mm in the present study. Likewise, Appy-Fedida et al<sup>1</sup> found an average distance of 12.3 mm between the distal-lateral Achilles portal and the sural nerve, which seems to be of higher risk than the 17.7 mm in the present study. While an increase in safety could be considered, these differences, as well as the wide confidence intervals of the mean distances found in the present study, might also merely reflect the high variability in the distribution of the sural nerve, as reported elsewhere.<sup>15</sup> This would emphasize the need for careful portal placement during each tendoscopic procedure. The 2-mm-diameter arthroscope and its operative instruments did not cause macroscopically apparent damage to the tendons, as visually inspected by the 2 orthopedic surgeons. This might be a result of careful portal placement,<sup>20</sup> but the large freedom of movement of the small-diameter camera in the tendon sheaths and its semirigid frame may have additionally attributed to the low risk of damage, as the semirigid frame is more compliant than the conventional rigid frames.

As with previous alternatives to rod-lens arthroscopes, the minimally invasive nature of 2-mm-diameter tendoscopy might better enable tendoscopic procedures under local anesthesia and eliminate the need for an operating room.<sup>6,7</sup> The results of this study indicate that in contrast to these previous systems, 2-mm-diameter tendoscopy additionally

makes proper diagnostic examination and therapeutic intervention feasible. This way, 2-mm-diameter operative tendoscopy may make the practice of tendoscopy more accessible than ever. The barrier to diagnostic procedures and small interventions such as vincula resections and adhesiolysis may become substantially lower and new indications for tendoscopy might arise. Tendon tears can be located more easily, and although they cannot be directly fixed, with the tailored tools it should be possible to perform debridement. In addition, if an operating room and its staff are no longer needed, small-diameter tendoscopy might make orthopedic practice more cost-efficient.<sup>21</sup>

This study must be considered in the light of its limitations. The study was conducted in a small number of donor ankles. Image quality was remarkably good, and the small-diameter arthroscope allowed for great mobility in the narrow tendon sheaths. The true diagnostic and therapeutic value of 2-mm-diameter operative tendoscopy, however, cannot be derived from such a limited cadaveric setting. In clinical practice, visualization might, for example, be hampered as saline inflow is limited by the narrow scope and sheath, which could cause blood, debris, and synovial tissue to obscure vision. Nonetheless, the results of the current study do indicate that there is sufficient reason to further test the merits of 2-mm-diameter operative tendoscopy in clinical practice.

## Conclusion

In a cadaveric setting, 2-mm-diameter operative tendoscopy provided excellent visualization and safe operative reach of the tibialis posterior, peroneal, and Achilles tendons.

## Declaration of Conflicting Interests

The author(s) declared the following potential conflicts of interest with respect to the research, authorship, and/or publication of this

article: Daniel Appelt, PhD, and Coen A. Wijdicks, PhD, are employed by Arthrex. ICMJE forms for all authors are available online.

### Funding

The author(s) disclosed receipt of the following financial support for the research, authorship, and/or publication of this article: The Department of Orthopedic Surgery from the Amsterdam UMC was supported with an unrestricted research grant from Arthrex GmbH.

### ORCID iD

Tobias Stornebrink, MD,  <https://orcid.org/0000-0002-7630-7645>

### References

1. Appy-Fedida B, Vernois J, Krief E, Gouron R, Mertl P, Havet E. Risk of sural nerve injury during lateral distal Achilles tendinosis: a cadaver study. *Orthop Traumatol Surg Res.* 2015;101(1):93-96.
2. Barr C, Bauer JS, Malfair D, et al. MR imaging of the ankle at 3 tesla and 1.5 tesla: protocol optimization and application to cartilage, ligament and tendon pathology in cadaver specimens. *Eur Radiol.* 2007;17(6):1518-1528.
3. Barrett SL, Day SV. Endoscopic plantar fasciotomy: two portal endoscopic surgical techniques—clinical results of 65 procedures. *J Foot Ankle Surg.* 1993;32(3):248-256.
4. Bulstra GH, Olsthoorn PG, van Dijk CN. Tendoscopy of the posterior tibial tendon. *Foot Ankle Clin.* 2006;11(2):421-427.
5. Christensen JC, Lanier TD. Tendoscopy of the ankle. *Clin Podiatr Med Surg.* 2011;28(3):561-570.
6. Deirmengian CA, Dines JS, Vernace JV, Schwartz MS, Creighton RA, Gladstone JN. Use of a small-bore needle arthroscope to diagnose intra-articular knee pathology: comparison with magnetic resonance imaging. *Am J Orthop (Belle Mead NJ).* 2018;47(2):1-5.
7. Gill TJ, Safran M, Mandelbaum B, Huber B, Gambardella R, Xerogeanes J. A prospective, blinded, multicenter clinical trial to compare the efficacy, accuracy, and safety of in-office diagnostic arthroscopy with magnetic resonance imaging and surgical diagnostic arthroscopy. *Arthroscopy.* 2018;34(8):2429-2435.
8. Marmotti A, Cravino M, Germano M, et al. Peroneal tendoscopy. *Curr Rev Musculoskelet Med.* 2012;5(2):135-144.
9. Meister K, Harris NL, Indelicato PA, Miller G. Comparison of an optical catheter office arthroscope with a standard rigid rod-lens arthroscope in the evaluation of the knee. *Am J Sports Med.* 1996;24(6):819-823.
10. Morag G, Maman E, Arbel R. Endoscopic treatment of hind-foot pathology. *Arthroscopy.* 2003;19(2):E13.
11. Reilingh ML, de Leeuw PA, van Sterkenburg MN, van Dijk CN. Tendoscopy of posterior tibial and peroneal tendons. *Tech Foot Ankle Surg.* 2010;9(2):43-47.
12. Rockett MS, Waitches G, Sudakoff G, Brage M. Use of ultrasonography versus magnetic resonance imaging for tendon abnormalities around the ankle. *Foot Ankle Int.* 1998;19(9):604-612.
13. Sammarco VJ. Peroneal tendoscopy: indications and techniques. *Sports Med Arthrosc Rev.* 2009;17(2):94-99.
14. Scholten PE, van Dijk CN. Tendoscopy of the peroneal tendons. *Foot Ankle Clin.* 2006;11(2):415-420.
15. Solomon LB, Ferris L, Tedman R, Henneberg M. Surgical anatomy of the sural and superficial fibular nerves with an emphasis on the approach to the lateral malleolus. *J Anat.* 2001;199(Pt 6):717-723.
16. Steenstra F, van Dijk CN. Achilles tendoscopy. *Foot Ankle Clin.* 2006;11(2):429-438.
17. van Dijk CN, Kort N, Scholten PE. Tendoscopy of the posterior tibial tendon. *Arthroscopy.* 1997;13(6):692-698.
18. Vega J, Batista JP, Golano P, Dalmau A, Viladot R. Tendoscopic groove deepening for chronic subluxation of the peroneal tendons. *Foot Ankle Int.* 2013;34(6):832-840.
19. Vega J, Cabestany JM, Golano P, Perez-Carro L. Endoscopic treatment for chronic Achilles tendinopathy. *Foot Ankle Surg.* 2008;14(4):204-210.
20. Vega J, Golano P, Batista JP, Malagelada F, Pellegrino A. Tendoscopic procedure associated with peroneal tendons. *Tech Foot Ankle Surg.* 2013;12(1):39-48.
21. Voigt JD, Mosier M, Huber B. Diagnostic needle arthroscopy and the economics of improved diagnostic accuracy: a cost analysis. *Appl Health Econ Health Policy.* 2014;12(5):523-535.
22. Wertheimer SJ, Weber CA, Loder BG, Calderone DR, Frascone ST. The role of endoscopy in treatment of stenosing posterior tibial tenosynovitis. *J Foot Ankle Surg.* 1995;34(1):15-22.