

CASE REPORT

Isolated tuberculosis of the spleen presenting with fever of unknown origin in a vaccinated child

Ameer Kakaje^{1,*†}, Yousef Mahmoud¹, Osama Hosam Aldeen¹ and Othman Hamdan²

¹Faculty of Medicine, Damascus University, Damascus Syria, ²Department of Haematology, Children's University Hospital, Damascus University, Damascus, Syria

*Correspondence address. Damascus University, Faculty of Medicine, Damascus, Syria. E-mail: ameer.kakaje@hotmail.com

Abstract

Tuberculosis (TB) is one of the top 10 causes of death worldwide and is more common in developing countries. Isolated splenic TB is typically found in trauma, miliary TB and immunocompromised status. We present a very rare case of an immunocompetent child with an isolated primary TB in the spleen. The child only had fever of unknown origin (FUO), and mild anaemia. The diagnosis was not made until splenectomy was performed. The patient took the quadruple therapy for TB, and follow-ups showed no recurrence. This case is unique because this child was immunocompetent with no history of trauma or active TB. TB diagnosis should never be ignored in FUO as this might prevent unnecessary procedures to the patient. Although the child was vaccinated with Bacillus Calmette–Guérin that usually protects against severe TB in first 5 years of life, it did not prevent from affecting the spleen.

INTRODUCTION

Around 20% of tuberculosis (TB) cases have extra pulmonary manifestations which can involve almost any organ, with the nervous and lymphatic systems being the most common [1]. However, isolated cases of TB in the spleen are very rare in immunocompetent patients [1, 2]. We present a young girl with fever of unknown origin (FUO) that lasted for 2 months. The patient had an isolated splenomegaly, and mild anaemia. When the spleen was surgically removed, she was found to have TB.

CASE REPORT

A 5-year-old girl complained of a continuous fever for 2 months. She did not suffer from a cough, rigour, chills, night sweats or any pain. She did not have any gastric complaints either. She did not miss any of her vaccinations, including Bacillus Calmette–Guérin (BCG) vaccine. The patient had a family of a low socio-economic

status. Family history was unremarkable. On examination, she had pallor, and an enlarged spleen. Her height and development were normal according to her age, but the weight was low below the 1st percentile. The patient visited the doctor multiple times and was prescribed antibiotics, and paracetamol but without any improvement.

Her labs showed moderate hypochromic microcytic anaemia with normal platelet and white cell counts, while the lymphocytic cells percentile was (51%). Thick and thin blood smears did not provide additional findings. Liver and kidney function tests were normal, whereas erythrocyte sedimentation rate (ESR) was 41 mm/hour. However, bone marrow aspiration, haemoglobin electrophoresis, fragility test and direct and indirect Coombs' tests were normal. Blood culture and human immunodeficiency viruses (HIV) serology test were negative. Mantoux test showed a 7 mm induration, which was speculated to be a false positive from the TB vaccine. However, QuantiFERON-TB gold test (QFT) was not performed.

†Ameer Kakaje, <http://orcid.org/0000-0002-3949-6109>

Received: June 10, 2020; Revised: July 30, 2020; Accepted: August 24, 2020

© The Author(s) 2020. Published by Oxford University Press. All rights reserved. For Permissions, please email: journals.permissions@oup.com

This is an Open Access article distributed under the terms of the Creative Commons Attribution Non-Commercial License (<http://creativecommons.org/licenses/by-nc/4.0/>), which permits non-commercial re-use, distribution, and reproduction in any medium, provided the original work is properly cited.

For commercial re-use, please contact journals.permissions@oup.com

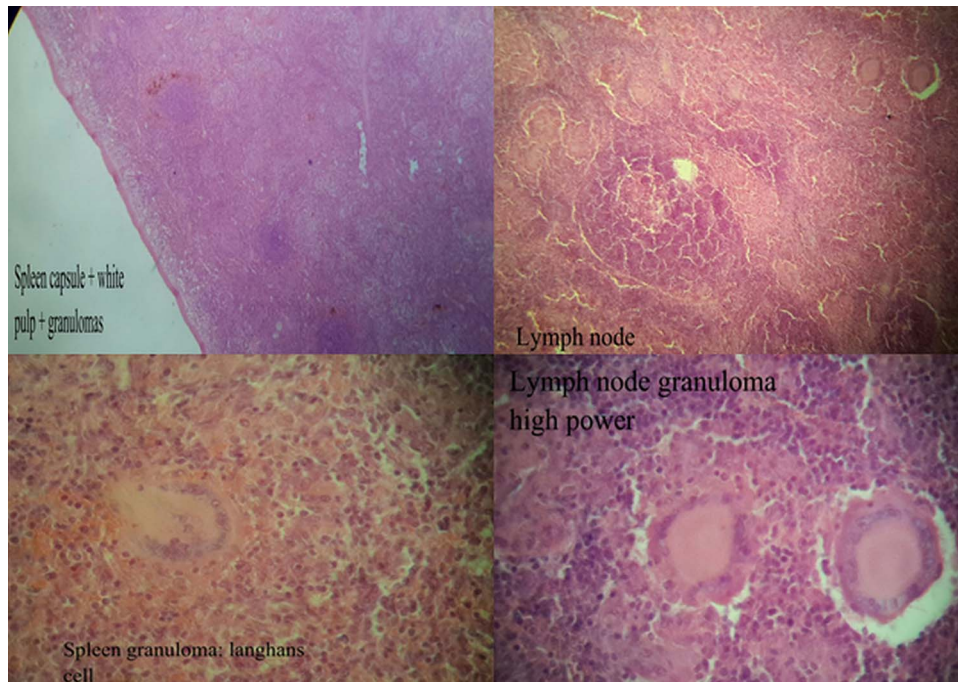


Figure 1: Histology of the lesion in the spleen and its hilar lymph nodes.

Chest X-ray (CXR) was normal. Ultrasonography (US) showed a homogeneous and moderately enlarged spleen. Thoracic and abdominal computed tomography (CT) scans with contrast showed normal lymph nodes, and the splenomegaly was 15 x 5 cm in size and homogeneous in density. No other abnormalities were detected on the US or CT. The patient was diagnosed with FUO with splenomegaly as no causes were found. The differential diagnosis included leishmaniasis, malaria, infarctions and infections.

An open splenectomy was performed to determine the underlying cause of the sizable lesion of the spleen as spleen biopsies are generally avoided in this hospital. Pentaxim, Pneumovax 23, influenza and meningococcal ACWY vaccines were also given prior the surgery. In pathology, caseation necrosis was observed in the granulomas in the hilar lymph nodes (Fig. 1). Acid-fast bacteria (AFB) staining was negative, but AFB culture was positive which showed TB. For the next 9 months, the patient was given 10 mg/kg isoniazid, and 15 mg/kg rifampicin, including 2 months of 20 mg/kg ethambutol, and 30–40 mg/kg pyrazinamide. Doses were adjusted during follow-ups when gaining weight. CXRs of the family members were normal, and they had normal Mantoux tests. After treatment was stopped, the patient came for follow-ups every 6 months by CXRs, US, ESR and blood tests, which showed no recurrence, and the patient weight went back to normal.

DISCUSSION

TB is more common in developing countries like Syria, and has one of the top 10 highest mortality rates in the world [1, 3]. Spleen TB is commonly found in immunocompromised patients [2]. Trauma, and hematogenous spread from the lungs in miliary TB and from adjacent organs are the methods of infecting the spleen in immunocompetent patients [1, 2]. In endemic areas, FUO could be the only symptom of a sporadic TB of the spleen

[1, 4], and the diagnosis can be misleading as symptoms can be unspecific or absent [5].

BCG vaccination can prevent having a severe disease in children such as miliary TB, and meningitis. The vaccination can also prevent around 40 000 cases every year before reaching the age of 5 years [3, 6]. Diagnosis in our case was made by pathology, the gold standard method of diagnosis [7]. BCG vaccine can lead to misinterpretation with Mantoux test but not with QFT. In our case, a biopsy should have been taken prior the surgery as it is an effective methods for diagnosis, and splenectomy could have been avoided [2].

We hypothesis that TB vaccination might have prevented a more severe form of TB in this patient, but it did not prevent hematogenous spread to the spleen. No QFT was conducted due to the financial hurdles that the patient had, and TB diagnosis was thought to be highly unlikely. Most procedures and medications in the hospital such as surgeries, drug regiments, AFB staining and culture, and the hospital admission are provided for free in Syria, while specific tests such as QFT are not provided for free, and they can be very expensive. This is not the first case to report financial hurdles in Syria that prevented proper diagnosis and management [8]. Although Children's University Hospital is considered the best centre for children in Syria, especially for haematological disorders [9], biopsy from the spleen is avoided in this hospital due to high rates of complications and a lack of experience with this procedure.

Despite splenectomy being rarely required in spleen TB, it may be necessary when an abscess is formed or there is no response to treatment. Furthermore, treatment can continue up to 24 months in some cases [1]. The differential diagnosis of splenomegaly with FUO can be leishmaniasis, malaria, an infarct from endocarditis, leukaemia, sickle cell disease, lymphoma and myelofibrosis. Infarcts can be difficult to distinguish with imaging alone [4]. Malaria is very rare in Syria, and is mainly in the northern provinces where risk is still low. Cutaneous and visceral leishmaniasis, has are endemic in Syria, and their incidence

increased in the last years from the internal displacement from the war [10]. Moreover, diagnosis is mainly made by demonstrating the parasite in stains [10] which were all normal in our study.

CONCLUSION

Our patient had fever of unknown origin with an isolated splenomegaly, which was not diagnosed with TB until splenectomy. TB should always be suspected in endemic areas when having FUO, and proper diagnostic tests should never be skipped. A biopsy should be performed when having FUO with a splenomegaly. BCG vaccination can cause confusion with Mantoux test, and it did not protect from hematogenous infection of the spleen in a 5-year-old child. However, it might have protected from a severe form of the TB.

ACKNOWLEDGEMENT

We would like to thank Professor Lina Khoury for her help and support throughout this work.

FUNDING

No funding was received for this study.

DECLARATIONS OF INTEREST

This work was approved by the ethical committee of Damascus University Faculty of Medicine.

CONFLICT OF INTERESTS

We have no conflict of interest to declare.

PATIENT PERSPECTIVE

The patient's caregivers thanked the hospital staff for their help and hospitality, and understood the hurdles that faced this case.

ETHICS APPROVAL AND CONSENT TO PARTICIPATE

Informed consent was taken for this research. Our study ethical aspects were reviewed and approved by Damascus University deanship, Damascus, Syria.

CONSENT FOR PUBLICATION

Consent for using and publishing the data was taken before participating in the research.

GUARANTOR

Othman Hamdan is the guarantor for the images and the case.

REFERENCES

1. Hamizah R, Rohana AG, Anwar SA, Ong TZ, Hamzaini AH, Zulkarnaen AN. Splenic tuberculosis presenting as pyrexia of unknown origin. *Med J Malaysia* 2007;**62**: 70–1.
2. Ray S, Goswami M, Saha M, Kundu S, Sarkar D. Isolated tubercular splenic abscess: can we defer splenectomy? Our single experience with anti-tuberculous therapy alone. *Indian J Med Microbiol* 2012;**30**.
3. Siroka A. 2017 *Global Tuberculosis Report*. 2018. World Health Organization.
4. Joazlina ZY, Wastie ML, Ariffin N. Computed tomography of focal splenic lesions in patients presenting with fever. *Singapore Med J* 2006;**47**:37–41.
5. Udgaonkar U, Kulkarni S, Shah S, Bhave S. Asymptomatic, isolated tubercular splenic abscess, in an immunocompetent person. *Indian J Med Microbiol* 2010;**28**: 172.
6. Trunz BB, Fine PEM, Dye C. Effect of BCG vaccination on childhood tuberculous meningitis and miliary tuberculosis worldwide: a meta-analysis and assessment of cost-effectiveness. *The Lancet* 2006;**367**:1173–80.
7. Maher M, Crush L, Twomey M, Sammon J, O'Connor O. Image-guided percutaneous splenic biopsy and drainage. *Semin Intervent Radiol* 2012;**29**:301–10.
8. Ghareeb A, Kakaje A, Ghareeb A, Nahas MA. An enormous arteriovenous malformation presenting in a child in sacro-gluteal region and managed successfully by recurrent embolisation and surgery. *Int J Surg Case Rep* 2020;**71**: 244–9.
9. Kakaje A, Alhalabi MM, Ghareeb A, Karam B, Mansour B, Zahra B, et al. Rates and trends of childhood acute lymphoblastic leukaemia: an epidemiology study. *Sci Rep* 2020;**10**.
10. Youssef A, Harfouch R, El Zein S, Alshehabi Z, Shaaban R, Kanj SS. Visceral and cutaneous Leishmaniases in a City in Syria and the effects of the Syrian conflict. *Am J Trop Med Hyg* 2019;**101**:108–12.