

Acute toxic encephalopathy induced by occupational exposure to 1,2-dichloropropane

Kyeong Min KWAK^{1,2}, Kyoung Sook JEONG³, Dong Hoon SHIN⁴,
Won-Jun CHOI⁵, Hyun Soo KIM⁶ and Seong-Kyu KANG^{5*}

¹Department of Occupational and Environmental Medicine, Gachon University Gil Medical Center, Republic of Korea

²Department of Environmental Sciences, Seoul National University Graduate School of Public Health, Republic of Korea

³Department of Occupational and Environmental Medicine, Hallym University Sacred Heart Hospital, Republic of Korea

⁴Department of Neurology, Gachon University College of Medicine, Republic of Korea

⁵Department of Occupational and Environmental Medicine, Gachon University College of Medicine, Republic of Korea

⁶Woo-Ri Industrial Health Center, Republic of Korea

Received June 8, 2018 and accepted June 25, 2018

Published online in J-STAGE July 3, 2018

Abstract: 1,2-Dichloropropane (1,2-DCP) is used widely in Korea as a substitute for trichloroethylene or methylene chloride. Some companies mistakenly consider that 1,2-DCP is an eco-friendly detergent because its use is not regulated, but 1,2-DCP is known to inhibit the central nervous system in animals; a few cases of accidental exposure have been reported in humans. We present a case of acute encephalopathy caused by exposure to 1,2-DCP. A 41 yr-old male presented with dizziness, headache, and diplopia after exposure to the detergent without protective equipment. Brain magnetic resonance imaging suggested metabolic encephalopathy, but the patient had no thiamine deficiency and no other metabolic disorder. As the symptoms had commenced after exposure to a large amount of solvent while skimming rust from the surface, and as the symptoms were more severe during the work week, improved on weekends, and disappeared after solvent exposure ceased, the toxic encephalopathy was likely induced by inhalation of the detergent.

Key words: Solvent-induced encephalopathy, Toxic encephalopathy, 1,2-Dichloropropane, Propylene chloride, Metabolic encephalopathy

Introduction

1,2-Dichloropropane (1,2-DCP) or propylene chloride is a colorless volatile liquid used as a detergent. Recently,

1,2-DCP has become employed widely in Korea as a substitute for trichloroethylene (TCE) or methylene chloride (MC). Occupational exposure limit is in place, but use of the chemical does not trigger workplace environment monitoring or require special health screening of workers, unlike the use of TCE or MC. Although some companies mistakenly consider 1,2-DCP to be an eco-friendly industrial detergent, the chemical is known to cause hepatic and

*To whom correspondence should be addressed.

E-mail: sk.kang@gachon.ac.kr

©2018 National Institute of Occupational Safety and Health

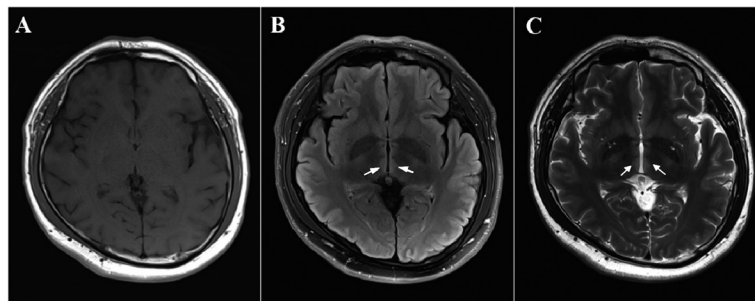


Fig. 1. Brain MRI images.

Although no signal change is evident on the T1 image (A), high signal intensities (arrows) in the bilateral medial thalami are evident on FLAIR (B) and T2 (C) images.

renal dysfunction, inhibition of the central nervous system (CNS), hemolytic anemia, and thrombosis^{1–4}). Many cases of cholangiocarcinoma occurred in workers at offset printing plants in Osaka, Japan, where 1,2-DCP was used in large quantities^{5–12}). The IARC designated 1,2-DCP as a group 1 carcinogen in 2014¹³). In animals, 1,2-DCP causes neurological complications (lethargy, CNS depression, and decreased activity)^{14, 15}). CNS overexposure (ingestion or inhalation) caused dizziness, disorientation, and coma in humans exposed to 1,2-DCP by accident or when attempting suicide^{2, 16}). To our knowledge, this report is the first to describe a case of toxic encephalopathy caused by occupational 1,2-DCP exposure (in an automotive accessory manufacturing plant).

Case Report

In June 2017, a 41-yr-old male visited our clinic with dizziness, headache, severe nausea, and vomiting. He worked at an automotive accessory manufacturing plant, and had manually skimmed rust off the surface of detergent (after the detergent had been used to clean automotive parts) without protective equipment. His symptoms developed after the cleaning work had finished. A physician at a local clinic had treated him conservatively (vitamins B₁, B₆, B₁₂, and Hartmann solution), but the symptoms did not improve. Five days later, on Monday morning, June 26, 2017, while skimming detergent, the worker complained of diplopia, dizziness, and ataxia. He visited a neurological physician in a university hospital.

The patient had worked for 9 yr in a gas station and for 5 yr as a driver, and had joined his present company in August 2014, working in pressing for 2 yr and in cleaning since August 2016. He sustained a right-knee tibial crush fracture in a traffic accident in 2002, but had no underly-

ing disease. He was a social drinker (1–2 bottles of beer a wk). All laboratory tests were normal except the serum ketone level (181 $\mu\text{mol/l}$, reference range 28–120 $\mu\text{mol/l}$). Initial blood tests revealed a white blood cell (WBC) count of 4,450/ mm^3 , hemoglobin concentration of 15.1 g/dl, platelet count of 136,000/ mm^3 , aspartate aminotransferase (AST) level of 33 IU/l, alanine aminotransferase (ALT) level of 48 IU/l, serum creatinine level of 0.69 mg/dl, and normal electrolyte levels. Brain magnetic resonance imaging (MRI) performed on June 27, 2017 revealed abnormal findings in the bilateral thalami, raising suspicion of metabolic encephalopathy (Fig. 1). The blood thiamine (vitamin B₁) level was measured, and vitamin B₁ was prescribed under suspicion of Wernicke's encephalopathy. However, the patient did not drink significant amounts of alcohol or exhibit an eating imbalance, and his thiamine level was normal (197.5 nmol/l, reference range 66.1–200.6 nmol/l); thus, Wernicke's encephalopathy was excluded. His clinical symptoms improved before thiamine was prescribed, and he was discharged on June 29, 2017. He returned to work and the company re-assigned him to pressing; he was no longer exposed to detergents or organic solvents, and the CNS symptoms did not recur.

We strongly suspected that the disease was caused by occupational exposure, as the symptoms developed on detergent exposure and improved when exposure ceased. The patient had started work with the company in August 2014, and had been assigned to pressing. In August 2016, he was reassigned to cleaning using an ultrasonicator. As the machine was not completely sealed (Fig. 2), he was exposed to organic solvent as automotive parts were placed in the cleaner and removed. Also, he moved the parts inside the cleaner by manually opening a window. The machine had three cleaning trays (Fig. 3): the left (A) collected grease, the center held the parts being cleaned (B),

and the right held parts that were drying (C). One week before the patient complained of symptoms, rust, which had not been encountered before, often floated on the surface of the detergent (Fig. 4A). He was in the habit of opening the window to directly remove the rust using a metal scoop (Fig. 4B), and was thus directly exposed to solvent. Local ventilation was inadequate; the fan was at the rear of the machine. Although a gas mask was provided, most workers did not wear protective equipment during summer because the workplace was not air conditioned.

1,2-DCP had been used as a detergent since February 2017, replacing MC. In December 2016, the MC exposure level in the workplace was 41.32 ppm (occupational exposure limit 50 ppm). The employer was concerned, as the levels were consistently above the action level (half the exposure limit), and thus replaced MC with 1,2-DCP. During the first 4 months, cleaning was performed in a closed environment without any problem. In June 2017, rust began to appear daily, and the worker opened the door and removed the rust without using protective equipment. After about 7 d, he developed dizziness and headache. In July 2017, the 1,2-DCP level was measured for the first time; it was 8.40 ppm, below the exposure limit (75 ppm as dictated by the Ministry of Employment and Labor, 10 ppm according to the American Conference of Governmental Industrial Hygienists), but the level during rust removal was not measured. In September 2017, by the Korean Occupational Safety and Health Agency measured the 1,2-DCP level again (twice on the same day); the time-weighted averages were 26.9 and 41.5 ppm, and the short-term exposure limits were 49.8 and 76.6 ppm when re-etching rust removal over 15 min (Table 1).

Discussion

The patient reported dizziness, diplopia, and ataxia, and both medial thalami exhibited high signal intensity on MRI. Although vitamin B₁ was administered empirically, the possibility of Wernicke's encephalopathy caused by thiamine deficiency was very low, considering the patient's drinking habits and nutritional status. In terms of differential diagnosis, the MRI data suggested viral encephalitis, cerebral venous thrombosis, cerebral infarction, and osmotic demyelination. However, as the symptoms commenced only after major exposure to organic solvent while removing rust, and were more severe during the working week than on weekends, we diagnosed toxic encephalopathy induced by detergent inhalation¹⁷. Such encephalopathy may be acute or chronic, depending on the exposure period. The




Fig. 2. Ultrasonic cleaning machine.

Automotive parts enter the cleaning machine through port A and is washed and dried inside. When cleaning is finished, the parts emerge through port B. Three trays in the cleaner contain detergent. The worker opens the window and moves the parts between the trays.

clinical manifestations of acute encephalopathy depend on the intensity of exposure. The earliest manifestations are behavioral (mood alterations, typically disinhibition). Headache and seizures may also develop relatively early; the greater the exposure, the more severe the impairment of cerebral function and suppression of consciousness¹⁸. Treatment is primarily supportive, commencing with cessation of exposure. Acute toxic encephalopathy is not specific; it may be caused by any organic solvent¹⁷.

The patient inhaled a large amount of organic solvent during rust removal; CNS symptoms occurred, but symptoms did not recur after removal of exposure (as of March 2018, the patient had no symptoms). Acute toxic encephalopathy induced by exposure to 1,2-DCP is thus a reasonable diagnosis. Although no such case has been previously reported, toxic encephalopathy is non-specific, caused by any organic solvent that affects the CNS. As several cases of toxic encephalopathy caused by other chlorinated organic solvents (TCE and 1,2-dichloroethane) have been reported¹⁹, we can reasonably conclude that toxic encephalopathy can be caused by 1,2-DCP.

1,2-DCP dissolves undesired materials effectively and evaporates quickly in air. Therefore, when the cleaning




Fig. 3. Interior of the ultrasonic cleaner.

The cleaner contains three trays. Grease collects in A, ultrasonic cleaning is performed in B, and drying occurs in C.




Fig. 4. Removal of rust from detergent.

(A) Rust (arrows), which had never been encountered before, floated on the surface of the detergent. (B) The worker opened the window and removed it directly using a metal scoop.

tank was uncovered, the worker was exposed to organic vapor. The final step of cleaning (drying) involved heating; 1,2-DCP is volatile at $\geq 96^{\circ}\text{C}^{20}$). Therefore, the patient was very likely exposed to higher levels of 1,2-DCP than the measured data suggest, as he opened the window during detergent pumping.

This report is the first to describe human CNS toxicity induced by 1,2-DCP, which is used widely as a substitute for strictly regulated detergents, such as TCE and MC. Although 1,2-DCP occupational exposure limits are in force, neither workplace environment monitoring nor worker health examination is required. Wholesalers advertise 1,2-DCP as eco-friendly because legal restrictions are lacking; use of 1,2-DCP is thus likely to be unmanaged, as in the present case, causing unreported effects on health. As toxic encephalopathy is non-specific, chemicals not previously reported to cause neurotoxicity should be considered in terms of possible CNS effects.

Table 1. Workplace environmental monitoring and exposure assessment

	Measured value (ppm)	
	TWA	STEL
OEL in Korea	75*	110
ACGIH TLV	10	-
Measurement 1 (June 2017)	8.4	-
Measurement 2 (September 2017)	26.9/41.5	49.8
Measurement 3 (September 2017)	-	76.6

TWA: time-weighted average; STEL: short-term exposure limit; OEL: occupational exposure limit; ACGIH: American Conference of Governmental Industrial Hygienists.

*Changed to 10 ppm since March 20, 2018.

Ethics Statement

The authors obtained approval from the Institutional Review Board (IRB) of Gachon University Gil Medical Center (IRB No. GBIRB2018-182), and the need for informed patient consent was waived.

Acknowledgements

The Korean Occupational Safety and Health Agency (KOSHA) assessed workplace levels of 1,2-DCP; we used these data. We thank the KOSHA.

References

- 1) Amoore JE, Hautala E (1983) Odor as an aid to chemical safety: odor thresholds compared with threshold limit values and volatilities for 214 industrial chemicals in air and water dilution. *J Appl Toxicol* **3**, 272–90. [[Medline](#)] [[CrossRef](#)]
- 2) Pozzi C, Marai P, Ponti R, Dell’Oro C, Sala C, Zedda S, Locatelli F (1985) Toxicity in man due to stain removers containing 1,2-dichloropropane. *Br J Ind Med* **42**, 770–2. [[Medline](#)]
- 3) Perbellini L, Zedde A, Schiavon R, Franchi GL (1985) [Disseminated intravascular coagulation (DIC) caused by 1,2-dichloropropane (commercial trielin). Description of 2 cases]. *Med Lav* **76**, 412–7 (In Italian). [[Medline](#)]
- 4) Kubo S, Matsuzaki K, Seki T, Ohsawa M, Kumagai S, Endo G (2015) Severe acute hepatitis in a printing company worker: a case study. *J Occup Health* **57**, 87–90. [[Medline](#)] [[CrossRef](#)]
- 5) Kubo S, Nakanuma Y, Takemura S, Sakata C, Urata Y, Nozawa A, Nishioka T, Kinoshita M, Hamano G, Terajima H, Tachiyama G, Matsumura Y, Yamada T, Tanaka H, Nakamori S, Arimoto A, Kawada N, Fujikawa M, Fujishima H, Sugawara Y, Tanaka S, Toyokawa H, Kuwae Y, Ohsawa M, Uehara S, Sato KK, Hayashi T, Endo G (2014) Case series of 17 patients with cholangiocarcinoma among young adult workers of a printing company in Japan. *J Hepatobiliary Pancreat Sci* **21**, 479–88. [[Medline](#)] [[CrossRef](#)]
- 6) Kubo S, Takemura S, Tanaka S, Shinkawa H, Kinoshita M, Hamano G, Ito T, Koda M, Aota T, Yamamoto T, Terajima H, Tachiyama G, Yamada T, Nakamori S, Arimoto A, Fujikawa M, Tomimaru Y, Sugawara Y, Nakagawa K, Unno M, Mizuguchi T, Takenaka K, Kimura K, Shirabe K, Saiura A, Uesaka K, Taniguchi H, Fukuda A, Chong JM, Kuwae Y, Ohsawa M, Sato Y, Nakanuma Y (2016) Outcomes after resection of occupational cholangiocarcinoma. *J Hepatobiliary Pancreat Sci* **23**, 556–64. [[Medline](#)] [[CrossRef](#)]
- 7) Kumagai S, Kurumatani N, Arimoto A, Ichihara G (2013) Cholangiocarcinoma among offset colour proof-printing workers exposed to 1,2-dichloropropane and/or dichloromethane. *Occup Environ Med* **70**, 508–10. [[Medline](#)] [[CrossRef](#)]
- 8) Kumagai S (2014) Two offset printing workers with cholangiocarcinoma. *J Occup Health* **56**, 164–8. [[Medline](#)] [[CrossRef](#)]
- 9) Kumagai S, Sobue T, Makiuchi T, Kubo S, Uehara S, Hayashi T, Sato KK, Endo G (2016) Relationship between cumulative exposure to 1,2-dichloropropane and incidence risk of cholangiocarcinoma among offset printing workers. *Occup Environ Med* **73**, 545–52. [[Medline](#)] [[CrossRef](#)]
- 10) Yamada K, Kumagai S, Nagoya T, Endo G (2014) Chemical exposure levels in printing workers with cholangiocarcinoma. *J Occup Health* **56**, 332–8. [[Medline](#)] [[CrossRef](#)]
- 11) Yamada K, Kumagai S, Endo G (2015) Chemical exposure levels in printing workers with cholangiocarcinoma (second report). *J Occup Health* **57**, 245–52. [[Medline](#)] [[CrossRef](#)]
- 12) Yamada K, Kumagai S, Kubo S, Endo G (2015) Chemical exposure levels in printing and coating workers with cholangiocarcinoma (third report). *J Occup Health* **57**, 565–71. [[Medline](#)] [[CrossRef](#)]
- 13) International Agency for Research on Cancer (2017) Some chemicals used as solvents and in polymer manufacture. *IARC Monogr Eval Carcinog Risks Hum* **110**, 141–75.
- 14) Sidorenko GI, Tsulaya VR, Korenevskaya EI, Bonashevskaya TI (1976) Methodological approaches to the study of the combined effect of atmospheric pollutants as illustrated by chlorinated hydrocarbons. *Environ Health Perspect* **13**, 111–6. [[Medline](#)] [[CrossRef](#)]
- 15) Herr DW, Boyes WK (1997) A comparison of the acute neuroactive effects of dichloromethane, 1,3-dichloropropane, and 1,2-dichlorobenzene on rat flash evoked potentials (FEPs). *Fundam Appl Toxicol* **35**, 31–48. [[Medline](#)] [[CrossRef](#)]
- 16) Rubin DF (1988) Occupational health implications of a toxic spill of propylene dichloride. *West J Med* **148**, 78–9. [[Medline](#)]
- 17) Firestone JA, Longstrength WT (2004) Neurologic and psychiatric disorders. In: *Textbook of clinical occupational and environmental medicine*, 4th Ed., Rosenstock L, Cullen M, Brodtkin C, Redlich C (Eds.), 645–60, WB Saunders, Philadelphia.
- 18) Kim Y, Kim JW (2012) Toxic encephalopathy. *Saf Health Work* **3**, 243–56. [[Medline](#)] [[CrossRef](#)]
- 19) Liu JR, Fang S, Ding MP, Chen ZC, Zhou JJ, Sun F, Jiang B, Huang J (2010) Toxic encephalopathy caused by occupational exposure to 1,2-Dichloroethane. *J Neurol Sci* **292**, 111–3. [[Medline](#)] [[CrossRef](#)]
- 20) Riddick JA, Bunger WB, Sakano TK (1986) *Organic solvents: physical properties and method of purification*, 4th Ed., 449–50, John Wiley and Sons, New York.