

## CASE REPORT

# The use of Apixaban for the treatment of an LV thrombus

Sadie Bennett BSc MSc, Duwarakan Satchithananda FRCP and Gareth Law BSc

Heart & Lung Centre, Royal Stoke, University Hospitals of the North Midlands, Stoke-On-Trent, UK

Correspondence should be addressed to S Bennett: [Sadie.Bennett@UHNM.nhs.uk](mailto:Sadie.Bennett@UHNM.nhs.uk)

### Summary

A 42-year-old male was admitted with shortness of breath secondary to suspected heart failure and chest infection. An echocardiogram revealed a dilated and impaired left ventricle; ejection fraction 29%, with a large, mobile thrombus within the left ventricular apex. Due to the presence of liver dysfunction, vitamin K antagonists were deemed inappropriate; thus, the decision was taken to use the novel anticoagulation agent Apixaban. After 6 days of receiving Apixaban, a cardiac magnetic resonance scan was performed, which showed complete resolution of the LV apical thrombus.

### Key Words

- ▶ Apixaban
- ▶ left ventricular thrombus
- ▶ LV thrombus resolution
- ▶ thrombus

### Learning points:

- Patients with a dilated and impaired LV are at an increased risk of developing LV thrombus.
- A large and mobile LV thrombus is associated with an increased risk of embolic events.
- Vitamin K antagonists (VKAs) are often the first-line therapy for LV thrombus; however, these may be inappropriate in some patients.
- NOACs are advantageous in comparison to VKAs and are used to treat: non-valvular atrial fibrillation, pulmonary embolisms and used in the prevention of recurrent deep vein thrombosis in adults.
- To date, NOACs are not licensed for the treatment of an LV thrombus; however, there are growing evidence whereby their use has shown promise in reducing the risk of embolic events and demonstrate rapid reduction in size/full resolution of an LV thrombus.
- Large, randomised research trials comparing NOACs and VKAs in the treatment of LV thrombus are needed, which may lead to a change in standard clinical practice that could benefit patients.

### Background

A left ventricular (LV) thrombus is a rare but known entity, which is commonly associated with dilated cardiomyopathy and acute anterior myocardial infarction (1). The presence of a mobile LV thrombus, atrial fibrillation and heart failure symptoms are thought to be associated with an increased risk of embolic events (2). Therefore, timely initiation of appropriate treatment is of vital importance. Current first-line therapy includes the

use of vitamin K antagonists (VKAs) for up to 6 months (3). However, the efficacy of VKAs is debatable and along with their limitations, it can mean that in a small subgroup of patients, the use of VKAs may be inappropriate and thus other pharmacological agents may be needed.

The use of novel anticoagulation agents (NOACs) have been shown to have superior effectiveness in preventing stroke and systemic embolism in comparison

to VKAs (4). Other advantages of NOACs include a lower incidence of major bleeding, a wider therapeutic international normalised ratio range, fewer food and drug interactions and improved cost effectiveness (5). As such, NOACs have recently received NICE recommendation for the treatment of non-valvular atrial fibrillation, known pulmonary embolisms and in the prevention of recurrent deep vein thrombosis in adults.

Here, we present a patient who was subsequently found to have a large, mobile LV apical thrombus, which completely resolved within 6 days of initiating Apixaban.

### Case presentation

A 42-year-old male presented to A&E with shortness of breath. Background history included liver dysfunction. A 12-lead ECG found the patient to be in atrial fibrillation; rate approximately 100–110bpm. On admission, the patient was initially diagnosed with a chest infection and suspected heart failure. He was transferred to the Coronary Care Unit where IV diuretics, antibiotics, Digoxin and Bisoprolol were initiated.

### Investigation

A transthoracic echocardiogram (echo) revealed mild LV dilatation with severe LV systolic impairment; estimated Simpson's Biplane: 29%. Also present was a large, mobile LV apical thrombus measuring approximately 3.0cm by 1.6cm. The possibility of some laminar thrombus with the LV apex was also noted (see Videos 1 and 2).

#### Video 1

Apical four chamber with a large, mobile thrombus. View Video 1 at <http://movie-usa.glencoesoftware.com/video/10.1530/ERP-18-0036/video-1>.

#### Video 2

Apical 2 chamber with a large, mobile thrombus. View Video 2 at <http://movie-usa.glencoesoftware.com/video/10.1530/ERP-18-0036/video-2>.

Treatment for the LV thrombus was complicated due to the patients' low output heart failure status and thus subsequent liver dysfunction, alanine transaminase on admission: 800U/mL (normal range <40U/mL). This meant the standard therapy approach with VKAs was contra-indicated. After discussion with haematology

department, a joint decision was taken to follow the NICE 2015 pulmonary embolism management protocol (6) using Apixaban.

Four days after the initiation of Apixaban, a repeat echo showed the large, mobile LV thrombus was still present and had not significantly altered in size. The patient remained stable with no clinical signs of an embolic event. Screening for asymptomatic cerebral embolic events is not routinely undertaken in clinical practice within the United Kingdom and as such was not undertaken for this patient. Six days after initiating Apixaban, a cardiac magnetic resonance study was undertaken. The report concluded there to be a dilated cardiomyopathy with a small apical myocardial infarction and complete resolution of the LV thrombus (see Fig. 1). A third echo carried out 2 days after the cardiac magnetic resonance study also showed complete LV thrombus resolution (see Videos 3 and 4).

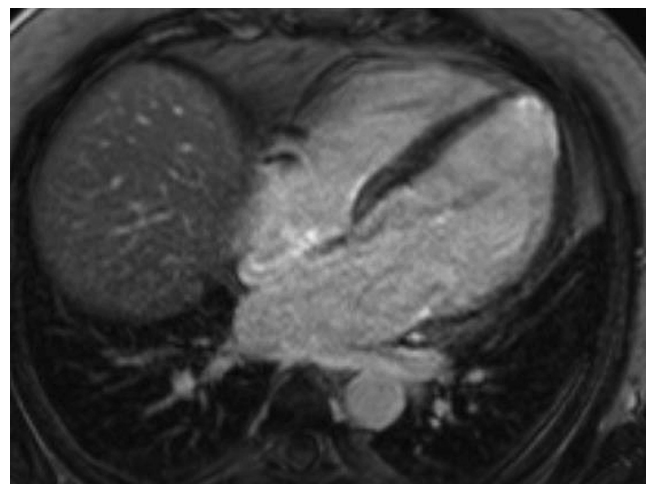
#### Video 3

Apical 2 chamber with no LV thrombus. View Video 3 at <http://movie-usa.glencoesoftware.com/video/10.1530/ERP-18-0036/video-3>.

#### Video 4

Apical four chamber with no LV thrombus. View Video 4 at <http://movie-usa.glencoesoftware.com/video/10.1530/ERP-18-0036/video-4>.

It was deemed that this patient had sufficient risk factors to satisfy Virchow's triad of thrombosis including hypercoagulability and endothelial dysfunction secondary



**Figure 1**  
CMR apical four chamber with no LV thrombus.

to an apical infarction and the presence of increase blood status secondary to severe LV systolic impairment. As such, the presence of the LV thrombus was deemed to be more likely consistent with *de novo* LV thrombus rather than a differential diagnosis of a paradoxical embolism, there was also no clinical indication of a deep vein thrombus or an intra-cardiac shunt was detected.

The patient was discharged on full heart failure medication and lifelong Apixaban. At the latest follow-up, the patient was well with no clinical signs of subsequent embolic events having occurred. LV systolic function had also improved with an estimated ejection fraction of 38% and no further evidence of LV thrombus.

## Discussion

There is evidence to suggest that a large LV thrombus, which protrudes into the LV cavity or which demonstrates independent mobility are associated with an increased risk of embolic events. Current guidelines recommend the use of VKAs; however, as shown here, there are instances where the use of VKAs is inappropriate.

To date, NOACs are not licensed for the treatment of LV thrombus; however, there are a growing number of recently published case studies where their use in the presence of an LV thrombus has shown impressive results. These case studies include different pathologies including LV non-compaction, hypertrophic cardiomyopathy and Chagas disease, all of which showed no embolic complications and complete LV thrombus resolution from day 7 to 2 months after initiating the chosen NOAC (7, 8, 9). To our knowledge, the patient presented here demonstrates the largest LV thrombus to show complete and rapid resolution within 6 days from starting treatment with Apixaban. From the growing number of case studies, there is a suggestion that NOACs are as effective as VKAs in reducing LV thromboembolic events and may even be superior to VKAs in their ability to allow complete and rapid LV thrombus resolution, an outcome which is still in debate regarding the use of VKAs.

Data regarding NOACs and LV thrombus is, at present, limited to individual case studies and one retrospective analysis of data from a single centre (10). The small number of patients who are found to have an LV thrombus may make large randomised studies challenging, but given the clear advantage of NOACs over VKAs in other clinical settings and their ability to completely resolve LV thrombus in different cardiac pathologies, there is a clear need for further research into the use of NOACs as

a treatment option for LV thrombus. There is currently a small, ongoing randomised study comparing Apixaban to Warfarin in the treatment of LV thrombus. The results, when available, will provide a discussion for further research.

### Declaration of interest

The authors declare that there is no conflict of interest that could be perceived as prejudicing the impartiality of this case report.

### Funding

This work did not receive any specific grant from any funding agency in the public, commercial or not-for-profit sector.

### Patient consent

Written consent was gained from the patient for publication of the article and the accompanying images.

### Author contribution statement

S B: Wrote the case study. D S: Consultant in charge of the patient and reviewed the case study. G L: Performed echocardiography imaging and reviewed the images included in the case study.

## References

- 1 Stokman PJ, Nandra CS & Asinger RW. Left ventricular thrombus. *Current Treatment Options in Cardiovascular Medicine* 2001 **3** 515–521. (<https://doi.org/10.1007/s11936-001-0025-6>)
- 2 Esposito R, Raia R, De Palma D, Santoro C & Galderisi M. The evolving role and use of echocardiography in the evaluation of cardiac source of embolism. *Journal of Cardiovascular Echography* 2017 **27** 33–44. ([https://doi.org/10.4103/jcecho.jcecho\\_1\\_17](https://doi.org/10.4103/jcecho.jcecho_1_17))
- 3 Steg G, James SK, Atrá D, Badano LP, Lundqvist CB, Borger MA, Di Mario C, Dickstein K, Fernandez-Aviles GDF, Gershlick AH, *et al.* ESC Guidelines for the management of acute myocardial infarction in patients presenting with ST-segment elevation: The Task Force on the management of ST-segment elevation acute myocardial infarction of the European Society of Cardiology. *European Heart Journal* 2012 **33** 2569–2619. (<https://doi.org/10.1093/eurheartj/ehs215>)
- 4 Miller CS, Grandi SM, Shimony A, Filion KB & Eisenberg MJ. Meta-analysis of efficacy and safety of new oral anticoagulants (dabigatran, rivaroxaban, apixaban) versus warfarin in patients with atrial fibrillation. *American Journal of Cardiology* 2012 **110** 453–460. (<https://doi.org/10.1016/j.amjcard.2012.03.049>)
- 5 Mekaj YH, Mekaj AY, Duci SB & Miftari EI. New oral anticoagulants: their advantages and disadvantages compared with vitamin K antagonists in the prevention and treatment of patients with thromboembolic events. *Therapeutics and Clinical Risk Management* 2015 **11** 967–977. (<https://doi.org/10.2147/TCRM.S84210>)

- 6 National Institute for Health and Care Excellence. Pulmonary embolism. Scenario: Managing confirmed pulmonary embolism. London, UK: NICE, 2015. (available at: <https://cks.nice.org.uk/pulmonary-embolism#!scenario:1>)
- 7 Sun H, Zhao Q, Wang Y, Lakin R, Feng H, Fan Z, Luo H, Gao D, Liu L, He Y, *et al.* Daily 10mg rivaroxaban as a therapy for ventricular thrombus related to left ventricular non-compaction cardiomyopathy. A case report. *Medicine* 2018 **97** 9670. (<https://doi.org/10.1097/MD.0000000000009670>)
- 8 Kaya A, Hayiroğlu MI, Keskin M, Tekkeşin AI & Alper AT. Resolution of left ventricular thrombus with apixaban in a patient with hypertrophic cardiomyopathy. *Turk Kardiyoloji Dernegi Arsivi* 2016 **44** 335–337. (<https://doi.org/10.1016/j.ijcac.2015.12.004>)
- 9 Las Casas AA Jr, Las Casas AA, Marco Borges MAF & Melo-Souza SE. Rivaroxaban for treatment of intraventricular thrombus in Chagas disease. *Journal of Cardiology Cases* 2016 **12** 75–77. (<https://doi.org/10.1016/j.jccase.2015.10.010>)
- 10 Bahmaid R, Ammar S, Al-Subaie S, Soofi M, Mhish, H & Yahia M. Efficacy of Target Specific Oral Anticoagulants on the resolution of left ventricular thrombus. *Surgical Case Report Review* 2018. (<https://doi.org/10.15761/SCRR.1000107>)

Received in final form 2 July 2018

Accepted 24 July 2018

Accepted Preprint published online 26 July 2018