

Atezolizumab-related encephalitis in the intensive care unit: Case report and review of the literature

SAGE Open Medical Case Reports
Volume 6: 1–4
© The Author(s) 2018
Article reuse guidelines:
sagepub.com/journals-permissions
DOI: 10.1177/2050313X18792422
journals.sagepub.com/home/sco



Andrés Laserna¹ , Sudhakar Tummala², Neel Patel²,
Diaa Eldin Mohamed El Hamouda² and Cristina Gutiérrez¹

Abstract

Atezolizumab is a monoclonal antibody that targets programmed death ligand-1. Treatments with this drug may cause immune-related adverse events by creating an exaggerated inflammatory response. The most common side effects are fatigue, rash, and gastrointestinal symptoms. Cases of central nervous system toxicity such as encephalitis and encephalopathy are uncommon. We present the case of a 53-year-old female with metastatic squamous cell carcinoma of the cervix who presented to the emergency room 13 days after receiving atezolizumab with altered mental status, headache, and meningeal signs. She was admitted to the intensive care unit. Infectious, anatomical, and neoplastic etiologies were ruled out. Auto-immune meningoencephalitis was diagnosed and treated with high-dose steroids. Within 10 days of the diagnosis, she had clinical, radiological, and laboratory improvement. Given the increasing use of novel immunotherapies and life-threatening side effects associated with them, healthcare providers in the intensive care unit should be aware of their diagnosis and management.

Keywords

Atezolizumab, encephalitis, critical care, immune checkpoint inhibitors

Date received: 25 April 2018; accepted: 9 July 2018

Introduction

By expressing PDL-1 (programmed death ligand-1), malignant cells can avoid destruction by the immune system. Immunotherapies targeting this ligand have shown promising results in the treatment of patients with advanced metastatic disease.¹ Atezolizumab, an immune checkpoint inhibitor that targets PDL-1,² is approved for the treatment of urothelial carcinoma, non-small cell lung cancer, and is currently under study for the treatment of gynecological, breast, lymphoma, melanoma, urological, and colorectal malignancies.^{1,3,4} Treatments with this drug may cause immune-related adverse events as they generate an exaggerated inflammatory response. The most common side effects are fatigue, pruritus, rash, and gastrointestinal symptoms.^{3,5} Cases of central nervous system (CNS) toxicity such as encephalitis and encephalopathy are uncommon.^{6,7} We present a case of a life-threatening immune-related meningoencephalitis and neuro-myopathy that developed after treatment with atezolizumab.

Case presentation

A 53-year-old Hispanic woman with history of cervical squamous cell carcinoma and progression of disease despite aggressive therapy, without CNS metastasis, was treated with intravenous atezolizumab and bevacizumab per a clinical trial in our institution. Thirteen days after the first dose of atezolizumab, she presented to the emergency room with acute onset altered mental status (AMS), headache, and meningeal signs. Physical exam disclosed tachycardia,

¹Department of Anesthesiology and Critical Care, Division of Critical Care, The University of Texas MD Anderson Cancer Center, Houston, TX, USA

²Department of Neuro-Oncology, Division of Cancer Medicine, The University of Texas MD Anderson Cancer Center, Houston, TX, USA

Corresponding Author:

Andrés Laserna, Department of Anesthesiology and Critical Care, Division of Critical Care, The University of Texas MD Anderson Cancer Center, 1515 Holcombe Blvd, Houston TX, USA.
Email: aflaserna@mdanderson.org



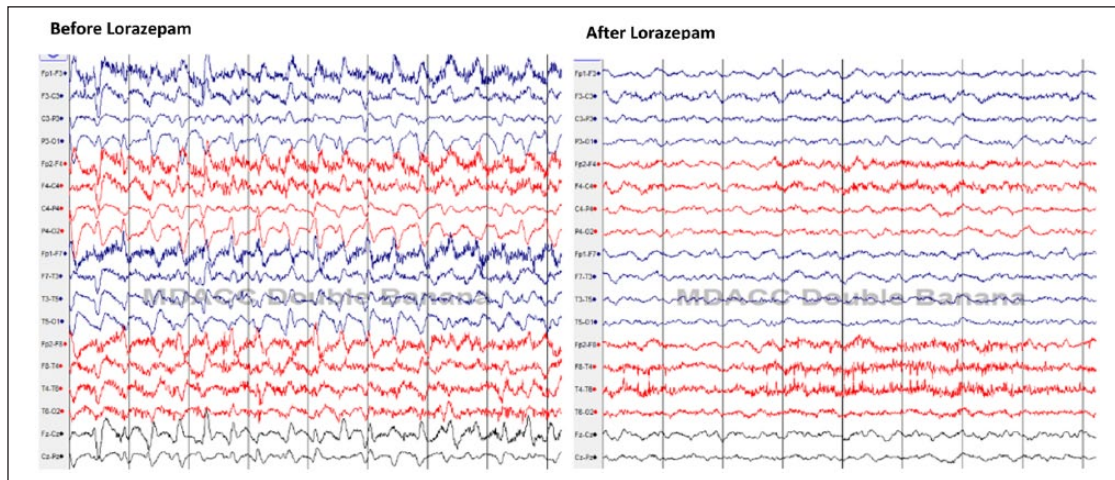


Figure 1. Electroencephalogram findings: (filter, HFF-70 Hz, LFF-1 Hz). At the beginning of the study, no clear posterior dominant rhythms were seen. There were generalized continuous frontal predominant sharp transients of biphasic and triphasic morphology at 2.5–3 Hz. After administration of lorazepam 1 mg (right image), there was resolution of the sharp transients with better organized slow background-low amplitude 4–5 Hz showing variability. There was no immediate significant improvement in the mental status; however, the eyelid flutter resolved and patient grimaced more easily to jaw stimulation. Findings were suggestive of non-convulsive status epilepticus patterns that responded adequately to intravenous lorazepam.

normal temperature, and comatose state. Empiric antibiotics and corticosteroids (dexamethasone 2 mg/12 h) were started to treat bacterial and viral meningitis. She was admitted to the intensive care unit (ICU) where she was intubated for airway protection.

Initial head CT scan and electro-encephalogram (EEG) showed no acute abnormalities. Lumbar puncture (LP) showed remarkable inflammatory findings suggestive of meningitis (leukocytes: 553 mcL, neutrophils: 91%, RBC: 114 mcL, proteins: >600 mg/dL, glucose: 92 mg/dL, no malignant cells). Cerebrospinal fluid (CSF) cultures remained negative, viral serological, and CSF quantitative tests (varicella-zoster virus DNA, John Cunningham virus DNA, human herpesvirus-6 DNA, cytomegalovirus DNA, adenovirus DNA, enterovirus RNA, herpes simplex-1/2 DNA, West Nile virus antibodies), toxoplasma, and cryptococcal antigen were negative. Serological paraneoplastic autoantibodies available at our institution (ANNA-1, Striated Muscle Ab N-type AChR binding Ab, AChR Gng Nrl Ab, neuronal (V-G) k + Ab, P/Q-type, ANNA-2, ANNA-3Mayo, AGNA-1, PCA-1-Ab, PCA-2-Ab, PCA-type Tr, Amphiphysin-Ab, CRMP-5-IgG) were negative. Other CSF paraneoplastic antibodies for anti-gliar nuclear Ab, type 1, anti-neuronal nuclear Ab, type 1, anti-neuronal nuclear Ab, type 1, anti-neuronal nuclear Ab, type 2, anti-neuronal nuclear Ab, type 3, CRMP-5-IgG, CSF, Purkinje cell cytoplasmic Ab type 1, Purkinje cell cytoplasmic Ab type 2, Purkinje cell cytoplasmic Ab type 3 were negative. Immunofluorescence patterns did not suggest presence of NMDA/AMPA-R, GABA-B-R, LGI111-IgG, CASPAR2-IgG antibodies. Other inflammatory markers in CSF such as IgG synthesis rate, IgG/albumin ratio, myelin basic

protein, and beta-2 microglobulin were elevated with no oligo-clonal bands. The EEG was repeated and showed non-convulsive status epilepticus which was controlled with one dose of 1 mg lorazepam followed by levetiracetam (see Figure 1). There was some clinical improvement with resolution of eyelid flutter with patient able to grimace more easily to jaw stimulation following administration of lorazepam. A magnetic resonance imaging (MRI) of the brain showed diffuse leptomeningeal enhancement (Figure 2(a)). An auto-immune inflammatory reaction was considered after negative CSF cultures, and dexamethasone dosage was increased to 6 mg/every 8 h.

After 7 days of treatment with steroids, there was minimal clinical improvement, but the CSF showed a remarkable favorable change (leukocytes: 9 mcL, protein: 302 mg/dL, IgG/albumin ratio and IgG synthesis rate had normalized). MRI on day 8 showed resolution of the previous findings (Figure 2(b)), and EEG showed no further seizures. In the following days, the patient's mental status improved with spontaneous eye openings and following of simple commands. She was found to have weakness, preserved reflexes, and reduced tone in all four extremities. Spinal MRI with and without contrast was unremarkable. Creatine kinase and aldolase levels were normal. She was considered to have a component of critical illness myopathy and possible immune-mediated inflammatory polyradiculoneuropathy. Electromyography was not performed as the patient and family declined consent for it. Given her further improvement and normalization of CSF on day 15, steroids were tapered over 19 days.

Her ICU course was prolonged due to complications such as pneumonia, prolonged ventilator support requiring tracheostomy, and tracheoesophageal fistula. After 35 ICU days,

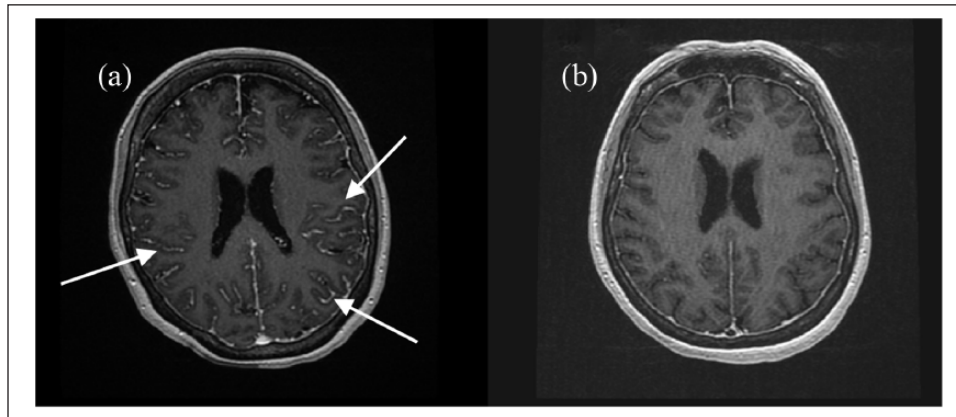


Figure 2. MRI, 3D axial T1 post contrast: (a) pre-steroid, diffuse leptomeningeal enhancement (white arrows); (b) post-steroids. Resolution of meningeal enhancement.

the patient was discharged to hospice due to her overall prognosis and non-eligibility for further treatment for her malignancy. At discharge, the patient was oriented, able to sit and communicate, and tolerated weaning from mechanical ventilation on trach collar. Her motor examination showed decreased tone, proximal and distal muscle weakness, and preserved reflexes.

Discussion

Innate and acquired immunity play key roles in controlling tumor proliferation. For instance, cytotoxic T-lymphocytes (CTLs) can recognize and lyse malignant cells, in some cases achieving disease control.^{8,9} Unfortunately, cancer cells evolve and have developed ways to elude the immune system surveillance such as expressing PDL-1.¹⁰ Developing immunotherapies such as atezolizumab, a human-derived monoclonal antibody that blocks PDL-1 and enhances the effectiveness of CTL against tumors, has shown outstanding results;^{1,4} however, numerous side effects have been described.^{3,11}

Severe CNS compromise is seldom seen, and to our knowledge, only two articles have been published. The first was a case report of a patient with advanced metastatic bladder cancer who developed encephalitis after receiving atezolizumab. Her clinical presentation was similar to our patient, but was treated with higher doses of dexamethasone (40 mg daily), and her symptoms improved faster. Her MRI showed focal enhancement in the frontal lobe area, while our patient had diffuse meningeal enhancement suggestive of a more severe process which could explain the prolonged clinical course.⁶ The second document is a Food and Drug Administration (FDA) review in which 523 patients treated with atezolizumab for advanced urothelial carcinoma were analyzed. In this study, only eight patients developed Grade 3–4 confusion, and one case of posterior reversible encephalopathy was described.

Other neurologic toxicities observed included peripheral neuropathy, optic neuritis, seizure disorders, myasthenia gravis, Guillain–Barré syndrome, demyelinating disorders, and paralysis; no cases with meningoencephalitis as severe as ours were described.⁷

Discontinuation of immune checkpoint inhibitors and rapid immunosuppression with glucocorticoids are the main line of treatment in CNS toxicities. Severe refractory patients might need additional immunosuppressant strategies like plasma exchange, intravenous immunoglobulins, or infliximab.³ In our patient, once all infectious, anatomical, neoplastic etiologies were ruled out, auto-immune meningoencephalitis was considered and treated with high-dose steroids. Clinical, radiological, and laboratory improvement were also suggestive of the diagnosis. The etiology of the extremity weakness remains unclear given the limitations of testing. This patient was appropriately treated by a multidisciplinary team that was essential given the complexity of the case.

Conclusion

With the evolution of cancer therapies, the likelihood of finding patients with serious adverse events requiring ICU admission may increase. Therefore, healthcare providers should be able to identify and treat these toxicities in a timely manner. A complete history should include the patients' use of newer immunotherapy agents, and discussions with oncologists to debate possible related complications are imperative. Increasing awareness of immune-related adverse events in the ICU has to be a priority, and further understanding of these toxicities might be determinant for better patient outcomes.

Acknowledgements

The authors appreciate the writing assistance of Mrs Mary Ann Oler, education program coordinator of the Critical Care Department at the University of Texas MD Anderson Cancer Center.

Consent for publication

The patient and her next of kin agreed with the case report and signed the respective informed consent for publication. They authorized the use and disclosure to the public of all medical information, including radiologic images for educational purposes (both in person and online).

Declaration of conflicting interests

The author(s) declared no potential conflicts of interest with respect to the research, authorship, and/or publication of this article.

Ethical approval

Our institution does not require ethical approval for reporting individual cases or case series.

Funding

The author(s) received no financial support for the research, authorship, and/or publication of this article.

ORCID iD

Andrés Laserna  <https://orcid.org/0000-0002-2071-3142>

References

1. Powles T, Eder JP, Fine GD, et al. MPDL3280A (anti-PD-L1) treatment leads to clinical activity in metastatic bladder cancer. *Nature* 2014; 515: 558–562.
2. Mittendorf EA, Philips AV, Meric-Bernstam F, et al. PD-L1 expression in triple-negative breast cancer. *Cancer Immunol Res* 2014; 2: 361–370.
3. Postow MA, Sidlow R and Hellmann MD. Immune-related adverse events associated with immune checkpoint blockade. *N Engl J Med* 2018; 378: 158–168.
4. Heong V, Ngoi N and Tan DSP. Update on immune checkpoint inhibitors in gynecological cancers. *J Gynecol Oncol* 2017; 28: e20.
5. Li Y, Li F, Jiang F, et al. A mini-review for cancer immunotherapy: Molecular understanding of PD-1/PD-L1 pathway & translational blockade of immune checkpoints. *Int J Mol Sci* 2016; 17: 1–22.
6. Levine JJ, Somer RA, Hosoya H, et al. Atezolizumab-induced encephalitis in metastatic bladder cancer: a case report and review of the literature. *Clin Genitourin Cancer* 2017; 15: e847–e849.
7. Ning Y, Zhang L and Suzman D. Clinical and statistical reviews: BLA 761034 for atezolizumab for second-line use in advanced urothelial carcinoma. Application no. 761034Orig1s000, Center for Drug Evaluation and Research, https://www.accessdata.fda.gov/drugsatfda_docs/nda/2016/761034Orig1s000MedR.pdf
8. Coley WB. The treatment of malignant tumors by repeated inoculations of erysipelas. With a report of ten original cases. 1893. *Clin Orthop Relat Res* 1991; 262: 3–11.
9. Adam JK, Odhav B and Bhoola KD. Immune responses in cancer. *Pharmacol Ther* 2003; 99: 113–132.
10. Pardoll DM. The blockade of immune checkpoints in cancer immunotherapy. *Nat Rev Cancer* 2012; 12: 252–264.
11. Chen TW, Razak AR, Bedard PL, et al. A systematic review of immune-related adverse event reporting in clinical trials of immune checkpoint inhibitors. *Ann Oncol* 2015; 26: 1824–1829.