

Spontaneous Closure of a Cavernous Sinus Dural Arteriovenous Fistula with Spinal Perimedullary Drainage (Cognard V) during Attempted Transvenous Embolization

Abstract

The authors describe a patient with spontaneous closure of a spontaneous cavernous sinus dural arteriovenous fistula (CSDAVF), Cognard type V, during transvenous attempt. A 39-year-old woman experienced mild proptosis, redness of the left eye, and diplopia. Four months later, she developed left retro-orbital pain and left-sided headache. Cerebral angiography revealed the left CSDAVF exclusively draining into the superior petrosal sinus with subsequent drainage into the veins surrounding the medulla oblongata, and finally into the perimedullary spinal veins, classified as Cognard type V. The feeders arise from the dural branches of both the left external and internal carotid arteries. Following 2 h period of attempted transvenous embolization, the fistula disappeared spontaneously. Follow-up angiography obtained 6 months later confirmed complete resolution of the CSDAVF. At 2-year follow-up, the patient has remained clinically asymptomatic. The mechanism of thrombosis in this fistula related to the endovascular procedure. We speculated that putting the wire tip in the draining vein may induce the spontaneous thrombosis in the venous side. In addition, precipitating factors may include small, low-flow fistula, and pre-existing thrombosis.

Keywords: Cavernous sinus, Cognard type V, dural arteriovenous fistula, spontaneous closure, thrombosis, transvenous embolization

**Prasert
Iampreechakul,
Korrapakc
Wangtanaphat,
Punjama
Lertbutsayanukul¹,
Yodkhwon
Wattanasen¹,
Somkiet
Siriwimonmas²**

Departments of Neurosurgery and ¹Neuroradiology, Prasat Neurological Institute, ²Department of Radiology, Bumrungrad International Hospital, Bangkok, Thailand

Introduction

Intracranial dural arteriovenous fistulas (DAVFs) are abnormal arteriovenous connections located within the dura matter, commonly near the venous sinuses. The arterial supply usually arises from dural or meningeal arteries. Dural branches from the pial arteries are rare. Venous drainage may occur into the dural sinuses, meningeal veins, osteodural veins, and/or retrogradely leptomeningeal veins. These fistulas are an acquired disease.^[1] Symptoms of the patients usually relate to location of the fistulas and venous drainage patterns.^[2,3]

The cavernous sinus (CS) is the second-most common location of intracranial DAVFs.^[4,5] The etiology of most CSDAVFs, abnormal communications between dural arteries and the CS, remains unclear. As explained by Newton and Hoyt,^[6] the occurrence of the fistulas may be caused by rupture of the thin-walled dural arteries traversing the CS, predisposed by vascular disease, straining, or trauma. Spontaneous CSDAVFs, low

flow and low pressure, usually appear in middle-aged females. The symptoms and signs of the fistulas located at the CS are usually insidious in onset and often mild and less severe than direct carotid-cavernous fistulas (CCFs), including redness of the eye, proptosis, chemosis, bruit, retro-orbital pain, unilateral headache, diplopia, dilated conjunctival veins, transient sixth-nerve palsy, elevated intraocular pressure (IOP), and/or diminished visual acuity.^[6-8] Feeding vessels may arise from dural branches of the cavernous segment of the internal carotid artery (ICA), i.e., the meningohypophyseal trunk and/or inferolateral trunk, and/or the external carotid artery (ECA), i.e., the middle meningeal artery, accessory meningeal artery, artery of foramen rotundum, and/or ascending pharyngeal artery.^[6,8-10]

Based on the pattern of venous drainage by Cognard *et al.*,^[4] intracranial DAVFs were classified into five types, including type I: fistulas drain into the main sinus with antegrade flow; type IIa: fistulas drain

Address for correspondence:
Dr. Prasert Iampreechakul,
312 Rachawithi Road,
Khwaeng Thung Phaya Thai,
Bangkok 10400, Thailand.
E-mail: bangruad@hotmail.com

Access this article online

Website: www.asianjns.org

DOI: 10.4103/ajns.AJNS_277_19

Quick Response Code:



How to cite this article: Iampreechakul P, Wangtanaphat K, Lertbutsayanukul P, Wattanasen Y, Siriwimonmas S. Spontaneous closure of a cavernous sinus dural arteriovenous fistula with spinal perimedullary drainage (Cognard V) during attempted transvenous embolization. *Asian J Neurosurg* 2019;14:1268-74.

This is an open access journal, and articles are distributed under the terms of the Creative Commons Attribution-NonCommercial-ShareAlike 4.0 License, which allows others to remix, tweak, and build upon the work non-commercially, as long as appropriate credit is given and the new creations are licensed under the identical terms.

For reprints contact: reprints@medknow.com

retrograde flow into the sinus(es) only; type IIb: fistulas drain retrograde flow to cortical vein(s) only; type IIa + b: fistulas drain retrograde flow into sinus(es) and cortical vein(s); type III: fistulas drain direct cortical venous drainage; type IV: fistulas drain direct cortical venous drainage with venous ectasia; and type V: fistulas drain into the spinal perimedullary veins.

Spontaneous closure of intracranial DAVFs is rare and usually occurs in benign fistulas, i.e., Cognard type I and IIa. The occurrence of spontaneous regression in cranial DAVFs with cortical venous reflux or higher type of Cognard classification is extremely rare.^[11,12]

The authors reported a patient with spontaneous disappearance of CSDAVF predominately draining into spinal perimedullary veins, i.e., Cognard V, during attempted transvenous embolization.

Case Report

A 39-year-old woman with a medical history of migraine for 1 year, noticed mild proptosis, redness of the left eye, and diplopia. There was no history of trauma. She went to the local hospital and was diagnosed of conjunctivitis, treated by medical treatment without improvement. Four months later, she developed left retro-orbital pain and left-sided headache. The patient was sent to another local hospital and obtained magnetic resonance imaging (MRI). The study showed abnormal bulging of the left CS with dilated left superior ophthalmic vein (SOV) [Figure 1]. Provisional diagnosis was the left CSDAVF. She was transferred to Prasat Neurological Institute for further investigation and treatment. On neurological examination, there was only mild hyperreflexia of both extremities without muscle weakness. Ophthalmic examination revealed mild proptosis, dilated episcleral veins, and a slight abducens nerve paresis of the left eye. Visual acuity was 20/20 in both eyes. Fundoscopic examination showed venous stasis retinopathy in the left eye. IOP was 8.6 mmHg in

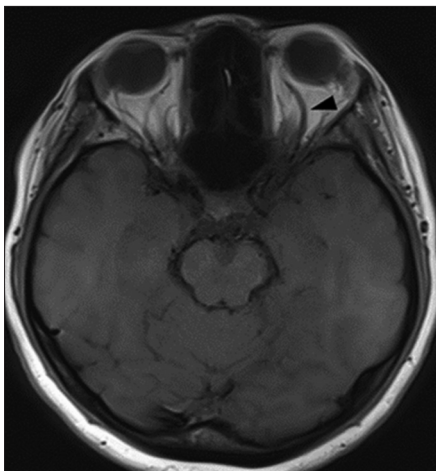


Figure 1: Axial T1-weighted magnetic resonance imaging of the brain shows an enlarged left superior ophthalmic vein (arrowhead)

the right eye and 13.2 mmHg in the left eye. Left internal carotid angiography with angiographic computerized tomography in maximum intensity projection-reformatted images revealed a DAVF shunting into the posterior CS, draining exclusively into the enlarged left superior petrosal sinus (SPS), left petrosal vein, left lateral medullary vein, enlarged anterior spinal vein, contralateral lateral medullary vein, right petrosal vein, right SPS, and finally into the right transverse sinus and inferior petrosal sinus (IPS). There was no opacification of the posterior segment of the left SPS. The reflux of venous outflow into the anterior portion of the left CS and SOV was seen on the late venous phase, probably representing partially thrombosed left CS and SOV [Figures 2-4]. Also, late arterial phase of the left ICA injection disclosed the cervical perimedullary veins draining into the epidural veins at the level of C1 and C3. There was also the venous drainage into cerebellar veins [Figure 5]. In addition, the fistula received blood supply from the right ICA, i.e., the meningo-hypophyseal trunk, and the left ECA, i.e., the artery of foramen rotundum and middle meningeal branches [Figure 6]. Due to a large volume of an interventional neuroradiology service at our tertiary referral center, endovascular treatment was scheduled in the next 3 months. Cerebral angiography obtained 3 months later disclosed the existence of the fistula which remained unchanged. Under general anesthesia, the first transvenous embolization via the left IPS without heparinization was unsuccessful because of the inability to deliver the microcatheter into the left CS. The patient refused further surgical treatment. Four months later, another transvenous embolization via the same route was performed again under general anesthesia. Furthermore, it was difficult to navigate the microcatheter into the left CS. We could deliver the microguidewire into the left petrosal vein coming from the IPS, but the microcatheter could not follow the microguidewire to the CS [Figure 7a]. Cerebral angiography, obtained 2 h after attempting embolization, revealed the absence of early opacification of the venous drainage of the left CS with only prominent dural arterial supply from the cavernous segment of the left internal carotid, middle meningeal, and internal maxillary arteries [Figure 7b and c]. There was no hypotension during the procedure.

On 6-month follow-up after spontaneous disappearance of the left CSDAVF, the patient no longer had headache. Proptosis and cranial nerve dysfunction had completely resolved. Follow-up IOP was 7.6 mmHg in the right eye and 8.9 mmHg in the left eye. Fundoscopic examination revealed complete resolution of venous stasis retinopathy. Cerebral angiography also confirmed complete resolution of the fistula [Figure 8]. At 2-year follow-up, the patient has remained clinically asymptomatic.

Discussion

Spontaneous CSDAVFs often have been initially misdiagnosed, especially caused by the absence of a

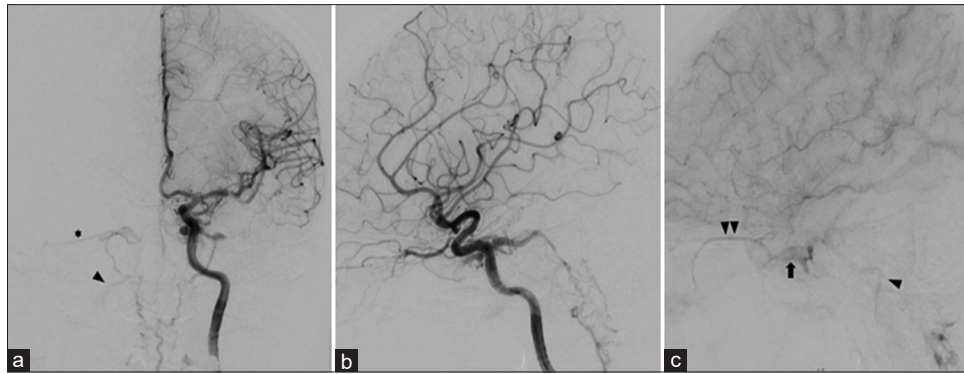


Figure 2: Cerebral angiography obtained 4 months after initial symptoms. Anteroposterior (a) and lateral in the arterial (b) and late venous (c) phase views of the left internal carotid artery injection reveal a left-sided dural arteriovenous fistula shunting into the posterior cavernous sinus, draining exclusively into an enlarged left superior petrosal sinus, left petrosal vein, left lateral medullary vein, enlarged anterior spinal vein, contralateral lateral medullary vein, right petrosal vein, right superior petrosal sinus (asterisk), and finally into the right transverse sinus and inferior petrosal sinus (arrowhead). There is no opacification of the posterior segment of the left superior petrosal sinus. The reflux of venous outflow into the posterior portion of the left cavernous sinus (arrow) and superior ophthalmic vein (double arrowheads) is seen on the late venous phase, probably representing partially thrombosed left cavernous sinus and superior ophthalmic vein

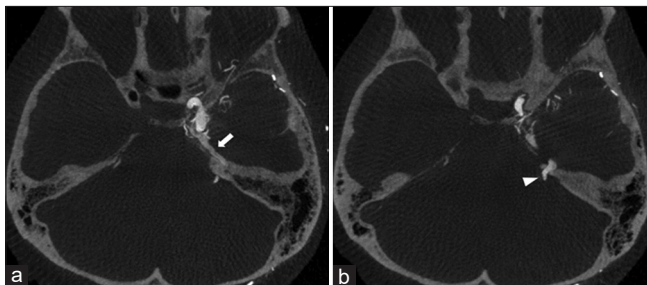


Figure 3: Axial maximum intensity projection-reformatted sequential images of angiographic computerized tomography of the brain (a and b) clearly show venous drainage of the left cavernous sinus dural arteriovenous fistula into an enlarged left superior petrosal sinus (arrow) along the superior angle of the petrous part of the left temporal bone, directly draining into a left petrosal vein (arrowhead)

bruit.^[13] In addition, our case presented with mild proptosis, redness of the left eye, and diplopia without bruit, leading to misdiagnosis from the previous hospital.

The findings of incomplete opacification of the CS and abnormal retrograde venous drainage are highly suspicious of partial thrombosis of the CS.^[9] The angiography of our case showed no filling of the SOV in early arterial phase incompatible with her symptoms, probably representing preexisting thrombosis. Headache may be the sign of partial thrombosis of the CS.^[10] It is possible that her subsequently developing headache may be the sign of CS thrombosis.

The CSDAVFs can cause venous congestion of the brainstem, leading to catastrophic consequences.^[14-17] Hypoplasia or occlusion of posterior segment of the SPS, divided into anterior and posterior segments, may accelerate the venous reflux into the petrosal vein and subsequent drainage into the veins of brainstem and posterior fossa.^[14,18,19] Retrograde venous drainage into the brainstem and cerebellum from the CSDAVFs may result in venous infarction and/or intracranial hemorrhage.^[20]

The CSDAVF in our case was supplied by dural branches of both the ICA and ECA with predominantly drainage into the perimedullary veins via SPS and petrosal vein, corresponding with a classification of a Cognard type V DAVF.

Cognard type V accounts for 5.9% of all intracranial DAVFs and may experience myelopathy, bulbar palsy, and respiratory dysfunction, if left untreated.^[4,21] Regarding the study of relation between clinical presentation and angiographic findings of intracranial DAVFs with spinal venous drainage by Brunereau *et al.*,^[22] the authors found that patients without myelopathy had the venous drainage limited to the cervical region, whereas the venous drainage in patients with myelopathy descended toward the conus medullaris. Due to the perimedullary veins draining into the epidural veins through a medullary–radicular vein, the occurrence of spinal cord congestion or hypertension was prevented. Similarly, our case had no myelopathic symptoms probably due to the drainage of the perimedullary veins into the epidural veins and the contralateral transverse and IPS. We previously reviewed and elucidated the venous drainage of the spine and spinal cord in other interesting case reports.^[23,24]

Spontaneous CSDAVFs have a relatively high incidence of spontaneous regression.^[10,13,25-27] Then, management of these type of fistulas should be conservative unless the patients have progressive loss of vision. Thrombosis of venous outlet of a DAVF may either reroute drainage into cortical veins, leading to hemorrhagic complications, or induce spontaneous regression of DAVFs. However, it is difficult to predict which DAVF will regress or transform into a more dangerous type.^[2] van Dijk *et al.*^[11] reported two patients harboring CSDAVFs with long-term persistent cortical venous reflux, i.e., Cognard type IIa + b. Without treatment, spontaneous cure occurred in one patient after 14.5-year follow-up. Another patient had moderate disability 9.1 years later.

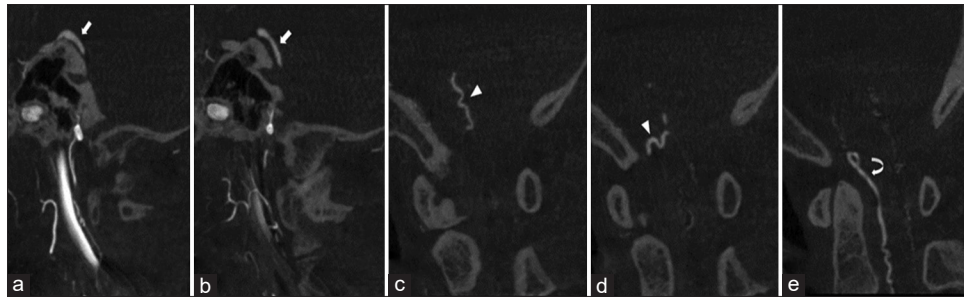


Figure 4: Sagittal maximum intensity projection-reformatted sequential images, from the left side to the midline, of angiographic computerized tomography of the craniocervical junction (a-e) demonstrate an enlarged left petrosal vein (arrow) caudally draining into the lateral medullary vein (arrowhead), and finally joining with a dilated anterior median spinal vein (curve arrow)

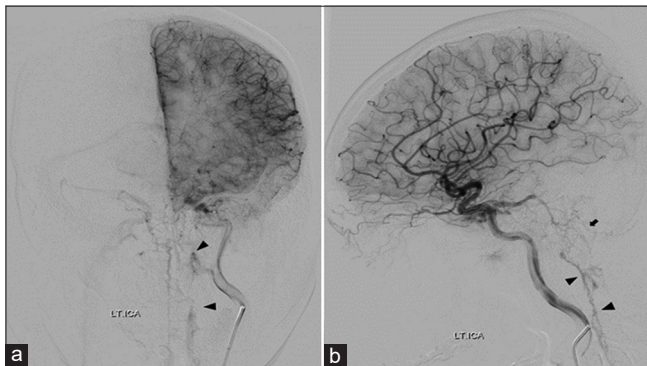


Figure 5: Cerebral angiography obtained 4 months after initial symptoms. Anteroposterior (a) and lateral (b) views of the left internal carotid artery angiography, late arterial phase, reveal the perimedullary veins draining into the epidural veins (arrowheads) at the level of C1 and C3. There is also the venous drainage into cerebellar veins (arrow)

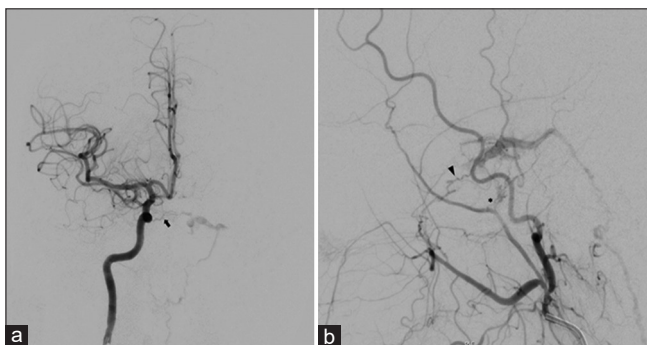


Figure 6: Cerebral angiography obtained 4 months after initial symptoms. (a) Anteroposterior view of the right internal carotid artery injection shows a left-sided dural carotid-cavernous fistula supplied by medial clival branch (arrow) of the right meningo-hypophyseal trunk of the cavernous segment of the right internal carotid artery via midline anastomotic branches. (b) Lateral view of the left external carotid artery injection reveals additional blood supply from the artery of foramen rotundum (arrowhead) and middle meningeal branches (asterisk)

The goal of treatment of Cognard type V DAVFs must be complete occlusion.^[4] Incomplete treatment allows recruitment of collateral vessels and persistent risk of aggressive symptoms.^[3] Without approaches for transarterial or transvenous embolization, direct embolization with embolic materials through open surgery may be another option.^[17] The most effective treatment option of CSDAVFs is primarily endovascular treatment

by transarterial or transvenous approach.^[28] Due to the risk of embolic complications associated with transarterial embolization of CSDAVFs, transvenous approach through the IPS using coils and/or liquid embolic materials is the preferred method.^[3,8,9,27,29] Even though IPS is not opacified by angiography, transvenous catheterization into the CS can be performed successfully through occluded venous segment.^[8,29,30]

Due to a high incidence of spontaneous obliteration, patients with CSDAVFs showing signs of venous thrombosis at angiography should be treated by conservative management.^[7] In our case, however, subsequent diversion of venous drainage into perimedullary veins may be aggravated following complete occlusion or thrombosis of the SOV. Thus, we decided to treat our patient due to a possibility of developing unpredictable aggressive neurological symptoms. Despite the absence of ipsilateral IPS drainage, we preferred to use transvenous embolization with coiling because we have more experience on this technique and considered surgery as the last option. Fortunately, the fistula disappeared spontaneously during difficult endovascular procedure.

Endovascular procedure-related spontaneous closure of intracranial AVFs has been scarcely reported. In the large series of Lewis *et al.*^[31] the authors reported spontaneous closure of three direct CCFs after unsuccessful attempts to place a detachable balloon. Similarly, closure of the fistula during attempted embolization without placement of a balloon was reported in previous studies.^[32,33] In addition, Uchino *et al.*^[34] reported spontaneous obliteration of small traumatic direct CCF following unsuccessful transarterial balloon embolization. They demonstrated that the shunt flow reduced significantly during the procedure and speculated that repeated transient reduction and stagnancy of the blood flow may promote secondary thrombosis in this patient. This concept was demonstrated by the report of Whang *et al.*^[35] presenting incidentally formed thrombus during difficult navigation of microcatheter and microguidewire through the small-sized fistula, which induced sudden closure of the fistula. In addition, Berenstein and Lasjaunias^[36] showed spontaneous closure of the vertebro-vertebral fistula occurred while attempting

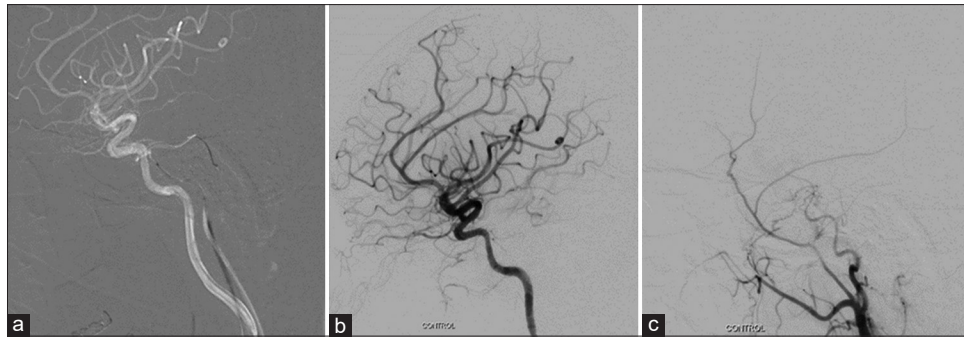


Figure 7: (a) During superselective transvenous catheterization of the left cavernous sinus. Lateral view of the left internal carotid artery injection during angiographic road-mapping demonstrates the microguidewire navigated into the left petrosal vein through the left superior petrosal sinus and the microcatheter remaining in a left inferior petrosal sinus. Lateral views of the left internal (b) and external (c) carotid artery angiography, obtained 2 h after attempting embolization, reveal the absence of early opacification of the venous drainage of the left cavernous sinus with only prominent dural arterial supply from the cavernous segment of the left internal carotid, middle meningeal, and internal maxillary arteries

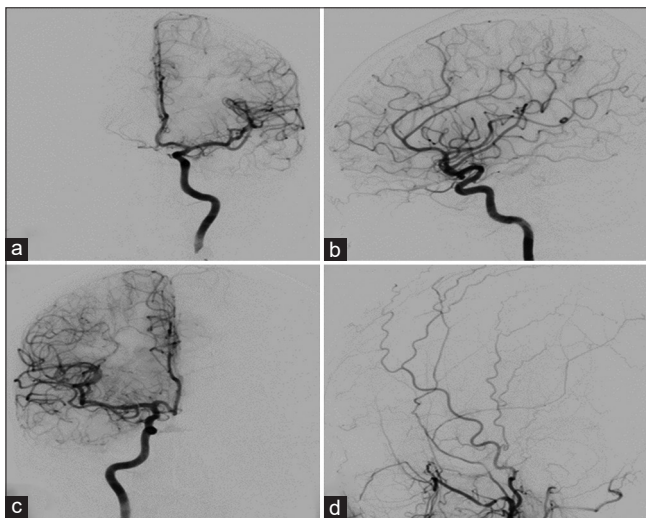


Figure 8: Cerebral angiography obtained 6 months after the second attempt of transvenous embolization. Anteroposterior (a) and lateral (b) views of the left internal carotid artery, anteroposterior view of the right internal carotid artery (c), and lateral view of the left external carotid artery (d) injections confirm complete resolution of the left cavernous sinus dural arteriovenous fistula

balloon embolization. Direct CCFs closed spontaneously not only after a failed transarterial approach, but also following an attempted transvenous approach.^[37]

There are several possible mechanisms, in which the DAVFs close spontaneously, proposed in previous studies. Luciani *et al.*^[38] reviewed the literature of spontaneous closure of DAVFs and divided into two types, i.e., posttraumatic and spontaneous. Most of the posttraumatic DAVFs were Cognard type I small fistulas, probably more likely to occlude spontaneously. In addition, posttraumatic vessels tend to develop scar tissue during the healing process, while spontaneous group has two mechanisms of spontaneous closure, including sinus thrombosis and intracranial hemorrhage. All Cognard type III DAVFs were diagnosed following intracranial hemorrhage. Regarding literature review from published data of spontaneous closure of intracranial DAVFs by Al-Afif *et al.*,^[12] this situation can occur in the fistulas classified

as Cognard type I, IIa, IIa + b, IIb, III, and IV. The most common spontaneously resolving lesions were type I. Warren *et al.*^[39] reported another rare precipitating factor, i.e., spontaneous resolution of Cognard type IIa DAVF following spontaneous recanalization of the occluded sinus. Voormolen *et al.*^[40] reported spontaneous closure of Cognard type IV intracranial DAVFs, draining directly into the cortical venous drainage with several ectasias in its course, in two middle-aged women. They speculated that the predisposing factors were small fistula, single-dilated cortical vein, and the specific contrast agent used during diagnostic angiography. Spontaneous resolution of Cognard type IIb and III intracranial DAVFs, with cortical venous drainage, may be caused by hemorrhage and the mass effect related to hematoma.^[41] Vasospasm may also be a potential mechanism related to bleeding. To the best of our knowledge, there was no previous case report of spontaneous closure of Cognard type V intracranial DAVF.

Spontaneous obliteration of low-flow CSDAVFs may result from partial or complete thrombosis of the CS and/or its tributaries.^[7] Patients harboring CSDAVFs without cortical venous drainage may achieve complete obliteration by external manual carotid compression. Simultaneous compression of the carotid artery and jugular vein may temporarily equalize the pressure between the carotid inflow to the fistula and the CS outflow, leading to stasis and thrombosis.^[42] CSDAVFs may resolve shortly following diagnostic cerebral angiography.^[43] The injection of contrast media may exaggerate the adhesion to and invasion of the venous wall by leukocytes and possibly contribute to thrombus formation.^[44] Furthermore, cervical carotid angiography can produce complications, including arterial spasm or dissection. In addition, some patients underwent angiography under general anesthesia, leading to lowering systemic blood pressure, resulting in reduction of the flow in the fistula.^[45] Spontaneous cure of the CSDAVFs may relate to pregnancy or delivery due to changes in blood coagulation and direct effect of estrogens on the vascular wall.^[46] Single venous drainage is another predisposing factor of complete remission.^[10]

In the present case, spontaneous disappearance of the fistula seems to correlate with endovascular procedure, i.e., putting the wire tip in the draining may induce the spontaneous thrombosis in the venous side. In addition, precipitating factors may include small, low-flow fistula, and preexisting thrombosis. However, contrast agents may not play an important role in the spontaneous closure of the fistula in our case due to the persistence of the fistula 7 months following the first angiography. To confirm the durability of complete cure of the fistula, long-term follow-up is necessary.

El Asri *et al.*^[47] conducted a systemic review of literature on patients with intracranial DAVFs with perimedullary drainage; they found that the poor outcomes were correlated to the presence of abnormal hyperintensity of the brainstem on T2-weighted imaging. Fortunately, there was no this finding on MRI in our case.

Conclusion

The authors reported endovascular procedure-related spontaneous closure of a Cognard type V CSDAVF in a young adult woman. During transvenous attempt via the IPS, putting the wire tip in the draining vein can even induce the spontaneous thrombosis in the venous side. In addition, precipitating factors may include small, low-flow fistula, and preexisting thrombosis.

Consent

The patient has given consent to be enrolled and has her data published.

Declaration of patient consent

The authors certify that they have obtained all appropriate patient consent forms. In the form, the patient has given her consent for her images and other clinical information to be reported in the journal. The patient understands that her name and initials will not be published, and due efforts will be made to conceal identity, but anonymity cannot be guaranteed.

Financial support and sponsorship

Nil.

Conflicts of interest

There are no conflicts of interest.

References

- Lasjaunias P, Berenstein A, Ter Brugge KG. Surgical Neuroangiography. Vol. 2.2. New York: Springer-Verlag; 2004.
- Lasjaunias P, Chiu M, ter Brugge K, Tolia A, Hurth M, Bernstein M. Neurological manifestations of intracranial dural arteriovenous malformations. *J Neurosurg* 1986;64:724-30.
- Gandhi D, Chen J, Pearl M, Huang J, Gemmete JJ, Kathuria S. Intracranial dural arteriovenous fistulas: Classification, imaging findings, and treatment. *AJNR Am J Neuroradiol* 2012;33:1007-13.
- Cognard C, Gobin YP, Pierot L, Bailly AL, Houdart E, Casasco A, *et al.* Cerebral dural arteriovenous fistulas: Clinical and angiographic correlation with a revised classification of venous drainage. *Radiology* 1995;194:671-80.
- Baltsavias G, Valavanis A. Endovascular treatment of 170 consecutive cranial dural arteriovenous fistulae: Results and complications. *Neurosurg Rev* 2014;37:63-71.
- Newton TH, Hoyt WF. Dural arteriovenous shunts in the region of the cavernous sinus. *Neuroradiology* 1970;1:71-81.
- Seeger JF, Gabrielsen TO, Giannotta SL, Lotz PR. Carotid-cavernous sinus fistulas and venous thrombosis. *AJNR Am J Neuroradiol* 1980;1:141-8.
- Meyers PM, Halbach VV, Dowd CF, Lempert TE, Malek AM, Phatouros CC, *et al.* Dural carotid cavernous fistula: Definitive endovascular management and long-term follow-up. *Am J Ophthalmol* 2002;134:85-92.
- Viñuela F, Fox AJ, Debrun GM, Peerless SJ, Drake CG. Spontaneous carotid-cavernous fistulas: Clinical, radiological, and therapeutic considerations. Experience with 20 cases. *J Neurosurg* 1984;60:976-84.
- Liu HM, Wang YH, Chen YF, Cheng JS, Yip PK, Tu YK. Long-term clinical outcome of spontaneous carotid cavernous sinus fistulae supplied by dural branches of the internal carotid artery. *Neuroradiology* 2001;43:1007-14.
- van Dijk JM, terBrugge KG, Willinsky RA, Wallace MC. Clinical course of cranial dural arteriovenous fistulas with long-term persistent cortical venous reflux. *Stroke* 2002;33:1233-6.
- Al-Afif S, Nakamura M, Götz F, Krauss JK. Spontaneous closure of a dural arteriovenous fistula. *BMJ Case Rep* 2014;7:1-6.
- Taniguchi RM, Goree JA, Odom GL. Spontaneous carotid-cavernous shunts presenting diagnostic problems. *J Neurosurg* 1971;35:384-91.
- Takahashi S, Tomura N, Watarai J, Mizoi K, Manabe H. Dural arteriovenous fistula of the cavernous sinus with venous congestion of the brain stem: Report of two cases. *AJNR Am J Neuroradiol* 1999;20:886-8.
- Shintani S, Tsuruoka S, Shiigai T. Carotid-cavernous fistula with brainstem congestion mimicking tumor on MRI. *Neurology* 2000;55:1929-31.
- Uchino A, Kato A, Kuroda Y, Shimokawa S, Kudo S. Pontine venous congestion caused by dural carotid-cavernous fistula: Report of two cases. *Eur Radiol* 1997;7:405-8.
- Kai Y, Hamada JI, Morioka M, Yano S, Ushio Y. Brain stem venous congestion due to dural arteriovenous fistulas of the cavernous sinus. *Acta Neurochir (Wien)* 2004;146:1107-11.
- Iampreechakul P, Tanpun A, Lertbusayanukul P, Siritwimonmas S. Contralateral extensive cerebral hemorrhagic venous infarction caused by retrograde venous reflux into the opposite basal vein of rosenthal in posttraumatic carotid-cavernous fistula: A case report and literature review. *Interv Neuroradiol* 2018;24:546-58.
- Shimada R, Kiyosue H, Tanoue S, Mori H, Abe T. Superior petrosal sinus: Hemodynamic features in normal and cavernous sinus dural arteriovenous fistulas. *AJNR Am J Neuroradiol* 2013;34:609-15.
- Miyamoto N, Naito I, Takatama S, Shimizu T, Iwai T, Shimaguchi H. Clinical and angiographic characteristics of cavernous sinus dural arteriovenous fistulas manifesting as venous infarction and/or intracranial hemorrhage. *Neuroradiology* 2009;51:53-60.
- Haryu S, Endo T, Sato K, Inoue T, Takahashi A, Tominaga T. Cognard type V intracranial dural arteriovenous shunt: Case reports and literature review with special consideration

- of the pattern of spinal venous drainage. *Neurosurgery* 2014;74:E135-42.
22. Brunereau L, Gobin YP, Meder JF, Cognard C, Tubiana JM, Merland JJ. Intracranial dural arteriovenous fistulas with spinal venous drainage: Relation between clinical presentation and angiographic findings. *AJNR Am J Neuroradiol* 1996;17:1549-54.
 23. Iampreechakul P, Lertbusayanukul P, Wattanasen Y, Siriwiwimonmas S. Progressive medullary congestion resulting in life-threatening condition caused by lower cervical dural arteriovenous fistula successfully treated with endovascular treatment: A case report and literature review. *Clin Med Rev Case Rep* 2019;6:1-11.
 24. Iampreechakul P, Liengudom A, Wangtanaphat K, Lertbusayanukul P, Wattanasen Y, Siriwiwimonmas S. Progressive cervical myelopathy caused by bilateral spontaneous high-flow vertebro-vertebral arteriovenous fistulas associated with fibromuscular dysplasia successfully treated by endovascular V2 segments sacrifice using fibered coils: A case report. *Clin Med Rev Case Rep* 2018;5:1-12.
 25. Barrow DL, Spector RH, Braun IF, Landman JA, Tindall SC, Tindall GT, *et al.* Classification and treatment of spontaneous carotid-cavernous sinus fistulas. *J Neurosurg* 1985;62:248-56.
 26. Kim DJ, terBrugge K, Krings T, Willinsky R, Wallace C. Spontaneous angiographic conversion of intracranial dural arteriovenous shunt: Long-term follow-up in nontreated patients. *Stroke* 2010;41:1489-94.
 27. Gemmete JJ, Chaudhary N, Pandey A, Ansari S. Treatment of carotid cavernous fistulas. *Curr Treat Options Neurol* 2010;12:43-53.
 28. Lucas CP, Zabramski JM, Spetzler RF, Jacobowitz R. Treatment for intracranial dural arteriovenous malformations: A meta-analysis from the English language literature. *Neurosurgery* 1997;40:1119-30.
 29. Halbach VV, Higashida RT, Hieshima GB, Hardin CW, Pribram H. Transvenous embolization of dural fistulas involving the cavernous sinus. *AJNR Am J Neuroradiol* 1989;10:377-83.
 30. Lekkhong E, Pongpech S, Ter Brugge K, Jiarakongmun P, Willinsky R, Geibprasert S. Transvenous embolization of intracranial dural arteriovenous shunts through occluded venous segments: Experience in 51 patients. *AJNR Am J Neuroradiol* 2011;32:1738-44.
 31. Lewis AI, Tomsick TA, Tew JM Jr. Management of 100 consecutive direct carotid-cavernous fistulas: Results of treatment with detachable balloons. *Neurosurgery* 1995;36:239-44.
 32. Berthelsen B, Svendsen P. Treatment of direct carotid-cavernous fistulas with detachable balloons. *Acta Radiol* 1987;28:683-91.
 33. Brosnahan D, McFadzean RM, Teasdale E. Neuro-ophthalmic features of carotid cavernous fistulas and their treatment by endoarterial balloon embolisation. *J Neurol Neurosurg Psychiatry* 1992;55:553-6.
 34. Uchino A, Takase Y, Koizumi T, Kudo S. Spontaneous thrombosis of a high-flow carotid-cavernous fistula after failed transarterial balloon occlusion. *Interv Neuroradiol* 2004;10:253-6.
 35. Whang K, Lee MS, Kim MS, Lee JY, Kwon W. Occlusion of traumatic carotid cavernous fistula by incidentally formed thrombus during the interventional procedure: A case report. *Korean J Radiol* 2006;7:215-7.
 36. Berenstein A, Lasjaunias P. *Surgical Neuroangiography*. Vol. 2. New York, NY: Springer-Verlag; 1987.
 37. Kendall B. Results of treatment of arteriovenous fistulae with the Debrun technique. *AJNR Am J Neuroradiol* 1983;4:405-8.
 38. Luciani A, Houdart E, Mounayer C, Saint Maurice JP, Merland JJ. Spontaneous closure of dural arteriovenous fistulas: Report of three cases and review of the literature. *AJNR Am J Neuroradiol* 2001;22:992-6.
 39. Warren DJ, Craven I, Romanowski CA, Coley SC. Spontaneous closure of a type 2a dural arteriovenous fistula following late recanalization of the occluded sinus. *Interv Neuroradiol* 2010;16:282-5.
 40. Voormolen V, Geens K, Van Den Hauwe L, Parizel PM. Spontaneous closure of cerebral dural arteriovenous fistulas with direct cortical venous drainage. A case report. *Interv Neuroradiol* 2009;15:359-62.
 41. Clarençon F, Biondi A, Sourour NA, Di Maria F, Iosif C, Nouet A, *et al.* Spontaneous closure of intracranial dural arteriovenous fistulas: A report of 3 cases. *Clin Neurol Neurosurg* 2013;115:971-5.
 42. Kai Y, Hamada J, Morioka M, Yano S, Kuratsu J. Treatment of cavernous sinus dural arteriovenous fistulae by external manual carotid compression. *Neurosurgery* 2007;60:253-7.
 43. Voigt K, Sauer M, Dichgans J. Spontaneous occlusion of a bilateral carotid-cavernous fistula studied by serial angiography. *Neuroradiology* 1971;2:207-11.
 44. Ritchie WG, Lynch PR, Stewart GJ. The effect of contrast media on normal and inflamed canine veins. A scanning and transmission electron microscopic study. *Invest Radiol* 1974;9:444-55.
 45. Iampreechakul P, Tirakotai W, Tanpun A, Wattanasen Y, Lertbusayanukul P, Siriwiwimonmas S. Spontaneous resolution of direct carotid-cavernous fistulas: Case series and literature review. *Interv Neuroradiol* 2019;25:71-89.
 46. Hirata Y, Matsukado Y, Takeshima H, Seto H. Postpartum regression of a spontaneous carotid-cavernous fistula – Case report. *Neurol Med Chir (Tokyo)* 1988;28:673-6.
 47. El Asri AC, El Mostarchid B, Akhaddar A, Naama O, Gazzaz M, Boucetta M. Factors influencing the prognosis in intracranial dural arteriovenous fistulas with perimedullary drainage. *World Neurosurg* 2013;79:182-91.