



Tissue glue for management of large iris cyst

Chandni Duphare^{a,*}, Naveen R. Ambati^b, Yevgeniy Shildkrot, M.D.^a

^a University of Virginia Department of Ophthalmology, 1300 Jefferson Park Ave, Charlottesville, VA, 22903, USA

^b University of Virginia School of Medicine, 200 Jeanette Lancaster Way, Charlottesville, VA, 22903, USA

ARTICLE INFO

Keywords:

Iris cyst
Fibrin glue
Tissue glue
Ocular oncology

ABSTRACT

Purpose: To present a novel technique utilizing fibrin glue-assisted adhesion as adjuvant to fine needle aspiration for management of post-surgical peripheral iris stromal cyst.

Observations: A 61 year-old male presented with a 4.20 × 7.56 × 8.22 mm well-circumscribed, fluid-filled peripheral cystic lesion involving the central visual axis with local posterior displacement of the intraocular lens. Surgical drainage was performed with the adjuvant use of fibrin glue to enhance the annealing of cyst walls. The patient tolerated the procedure without significant complications. At final post-operative visit, vision improved to 20/30 and there was no recurrence of the cyst.

Conclusions and importance: To our knowledge, this is the first report describing the use of fibrin glue to successfully treat a post-surgical peripheral iris stromal cyst. Fibrin glue may serve as an effective alternative to ethanol and sclerosing agents in the management of iris cysts.

1. Introduction

Large, visually significant cysts of the iris are rare. A rapidly expanding cyst in a child or adolescent is typically of stromal origin while secondary post-traumatic or surgical cysts can present with rapid growth in adults with complications related to angle occlusion, glaucoma and lens displacement.^{1–3} Posterior pigment epithelial cysts, while more common, are typically small, asymptomatic and require no intervention.^{1,2}

Treatment approach to large cysts frequently involves drainage with adjuvant use of dehydrated alcohol or antimetabolite agents.¹ Given commercial unavailability of dehydrated alcohol and potential toxicity of other agents, novel adjunctive agents are needed. Fibrin glue has been used for corneal perforations and appears to be well tolerated, even with intracameral extension of the glue.⁴

We describe a novel technique demonstrating safety and near-term efficacy of using fibrin glue-assisted adhesion as an adjuvant to fine needle aspiration to treat a large post-surgical peripheral iris stromal cyst.

2. Case report

A 61 year old male presented with a visually significant post-surgical peripheral iris stromal cyst. He had a history of cataract extraction six

years prior with no known antecedent penetrating trauma, uveitis or chronic use of miotic agents or topical prostaglandin inhibitors. Visual acuity was 20/200, with an intraocular pressure (IOP) of 15 mmHg. Clinical examination revealed a large bullous cyst originating from inferior iris (Fig. 1a), obscuring the central visual axis with no view of angle structures on gonioscopy. There was no abnormal pigmentation or vascularity noted. Ultrasound biomicroscopy ruled out a solid component or malignancy, demonstrating a well-circumscribed, fluid-filled cystic lesion (Fig. 1b) with local posterior displacement of the intraocular lens. Approximately 50% of the anterior surface of the cyst was adherent to the endothelium, sparing central cornea. The cyst was deemed to be secondary to cataract surgery. Surgical drainage was recommended with the use of fibrin glue to enhance the annealing of cyst walls.

The surgical procedure was performed under monitored anesthesia care with retrobulbar block (see Video 1).

A supplementary video related to this article can be found at <https://doi.org/10.1016/j.ajoc.2022.101742>.

TISSEEL VH Fibrin Sealant (Baxter Healthcare Corporation, Glendale CA) was reconstituted according to the manufacturing instructions and passed to the sterile field as separate syringes. The thrombin component was diluted 1 to 10 in a tuberculin syringe with balanced salt solution (BSS) to slow down the reaction.

Two paracenteses of 1 × 1 mm were created with a 15° super-sharp

* Corresponding author. University of Virginia Department of Ophthalmology, 1300 Jefferson Park Avenue, Charlottesville, VA, 22903, USA.

E-mail addresses: cd2kx@virginia.edu (C. Duphare), nra4jd@virginia.edu (N.R. Ambati), shildkrot@gmail.com (Y. Shildkrot).

blade at 5 o'clock adjacent to the cyst and at 12 o'clock. Viscoelastic was used to form the anterior chamber and to gently visco-dissect the cyst wall from the corneal endothelium. The cyst wall was entered through a paracentesis with a 30g needle on a tuberculin syringe and cyst contents were aspirated. The fluid was diluted with RPMI and sent to cytology for further analysis. The cyst cavity was nearly collapsed, appearing as an atrophic, corrugated area inferiorly with some residual iris tissue present at its posterior edge.

Filtered air was then injected into the cyst through the same opening in the cyst wall to partially re-inflate it and help localize the tissue glue. The fibrinogen was injected using a 30g needle into the cyst cavity. Diluted thrombin was then injected with a 30g needle, following which the air bubble was aspirated, allowing the cyst to collapse. Overall <0.15 cc of fibrinogen and thrombin were injected. Viscoelastic cannula was used to smooth out the collapsed cyst. Two minutes were set on the timer to ensure the setting of the glue. Viscoelastic was washed out of the eye with balanced salt solution (BSS) and the anterior chamber was filled with filtered air, leaving some viscoelastic inferiorly to prevent adherence of the iris and anterior cyst wall to the cornea. The paracenteses were closed with fibrinogen and undiluted thrombin over the wound. Subconjunctival dexamethasone and cefazolin were injected at the conclusion of the case.

3. Follow up

The next day, residual glue was noted within and on the surface of the cyst as white-gray material. IOP was elevated to 41 mmHg but quickly improved to 21 mmHg with topical medications and was felt to be related to the residual viscoelastic material. Patient was started on topical pressure lowering medications along with prednisolone acetate taper. Cytologic evaluation of aspirated cyst fluid revealed no evidence of malignancy with only hemosiderin-laden macrophages present. Three months later, at the last post-operative visit before the patient left the country, he was off all drops with his vision improved to 20/30, IOP 12 mmHg and there was no evidence of cyst recurrence or accumulation (1c, 1d).

4. Discussion

To our knowledge, we present the first case describing the adjuvant use of tissue fibrin glue for sealing of a large post-surgical peripheral iris stromal cyst. This treatment appears to be well tolerated, safe and successful in the short follow-up of 3 months.

Treatment approaches for large iris cysts have evolved to less invasive techniques over time. Fine needle aspiration has the dual benefit of providing fluid contents for cytologic analysis and of collapsing large cysts. Performing aspiration in the operating room allows for visco-dissection and separation of iris and the cornea in cases of extensive irido-corneal contact. However, due to high risk of cyst recurrence with aspiration alone, adjuvant cryotherapy, endodiathermy, and sclerosing agents such as 5-fluoro-uracil (5FU), Mitomycin (MMC) and absolute alcohol have been increasingly used off-label.¹ These agents, however, carry a risk of local toxicity.

Dehydrated ethanol irrigation of cysts is a well-documented procedure for iris cyst management, with the majority of cases resolving after one irrigation.⁵ Complications include need for further surgical intervention, corneal decompensation, IOP elevation, and localized inflammation. Currently, dehydrated ethanol is unavailable for clinical use.

Another approach involves laser treatment with Nd:YAG that may allow perforation and permanent damage to the cyst wall in smaller cysts. However high recurrence rates have been seen with larger cysts treated with Nd:YAG alone.⁶

Tissue adhesives are used with increasing frequency for ocular surface surgeries. Fibrin glue mimics the final stage of the coagulation cascade, and is biocompatible and biodegradable.⁷ Theoretically, the complications of fibrin glue in the anterior chamber include cytotoxicity, anterior chamber inflammation, and elevated IOP.⁴ Early experimental data demonstrated minimal if any cytotoxicity when corneal and iris cells were exposed to fibrin glue.⁴ Several authors have reported on safety and efficacy of tissue adhesive for corneal perforations up to 3 mm, where it provides faster healing with less corneal vascularization and no tissue necrosis compared to synthetic glue without evidence of

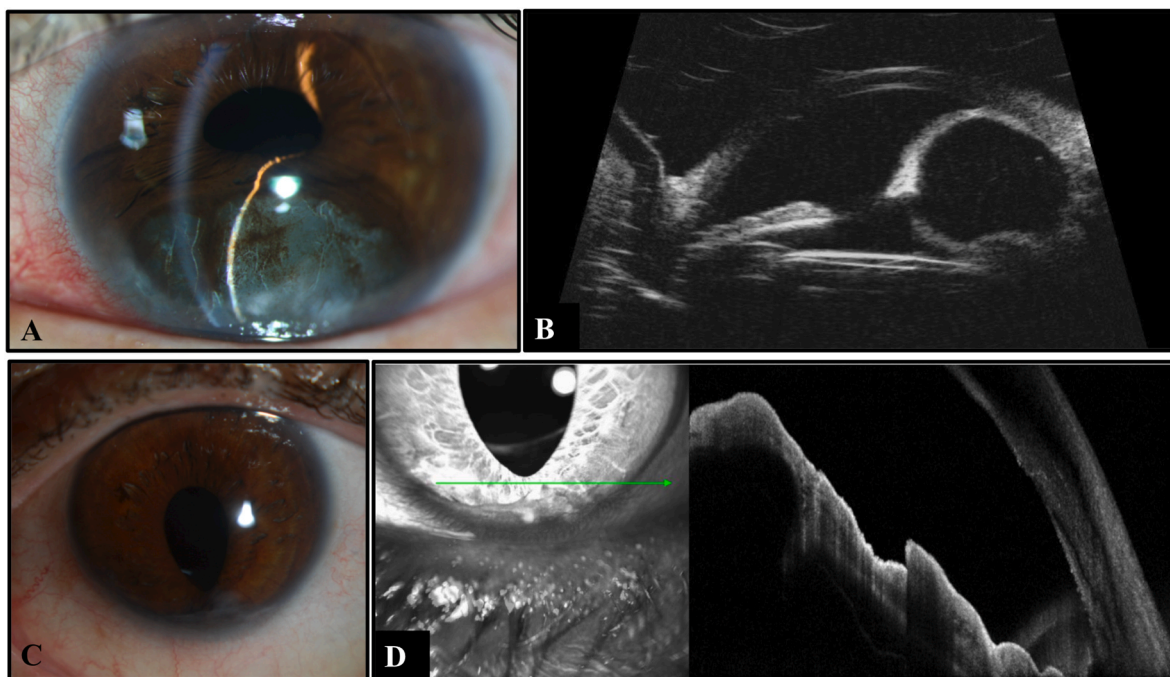


Fig. 1. Post-surgical peripheral iris stromal cyst (A) slit lamp photograph demonstrates no pigmentation or abnormal vascularity. (B) Ultrasound biomicroscopy reveals 4.20 x 7.56 x 8.22 mm well-circumscribed fluid-filled cystic lesion. (C) Slit lamp photograph of apparent involuted cyst three months postoperatively. (D) Anterior segment OCT of collapsed cyst cavity three months postoperatively.

adverse effects in patients with intracameral spread of glue.^{7,8} While the tissue fibrin glue may have lower tensile strength for corneal or conjunctival applications than other glues, it appears to be sufficient for the purpose of annealing of iris cyst walls, where it is entirely enclosed by the cyst capsule with no exposure to significant shearing forces. Our patient did not experience any adverse effects from the glue on corneal clarity or iris tissues.

There is a potential risk of vitreous spread, when glue is administered at the iris plane, especially in a pseudophakic patient. Wang et al. used tissue glue for creating retino-choroidal adhesions in patients with retinal detachment without significant inflammatory reaction or proliferative vitreoretinopathy (PVR) noted.⁹ Hou et al. noted fibrin glue as a feasible material to use in the suprachoroidal space, with no obvious toxic reactions observed.¹⁰ The risks from potential vitreous extension of the glue was felt to be minimal and none was observed in our case.

The fibrin glue appears to be safe and efficacious, at least in the short term, as an adjuvant to fine needle aspiration of post-surgical peripheral iris stromal cysts.

Patient consent

The patient(s)/patient's legal guardian consented to publication of the case in writing/orally.

Disclosures

No funding or grant support.

All authors attest that they meet the current ICMJE criteria for Authorship.

Declaration of competing interest

None.

Acknowledgements

No acknowledgments.

References

- Georgalas I, Petrou P, Papaconstantinou D, Brouzas D, Koutsandrea C, Kanakis M. Iris cysts: a comprehensive review on diagnosis and treatment-. *Surv Ophthalmol.* 2018;63(3):347–363. <https://doi.org/10.1016/j.survophthal.2017.08.009>.
- Shields CL, Shields PW, Manalac J, Jumroendararasame C, Shields JA. Review of cystic and solid tumors of the iris. *Oman J Ophthalmol.* 2013;6(3):159–164. <https://doi.org/10.4103/0974-620X.122269>.
- Shields JA, Kline MW, Augsburger JJ. Primary iris cysts: a review of the literature and report of 62 cases. *Br J Ophthalmol.* 1984;68(3):152–166. <https://doi.org/10.1136/bjo.68.3.152>.
- Chew ACY, Tan DTH, Poh R, HM H, Beuerman RW, Mehta JS. Effect of intracameral injection of fibrin tissue sealant on the rabbit anterior segment. *Mol Vis.* 2010;16:1087–1097.
- Behrouzi Z, Khodadoust A. Epithelial iris cyst treatment with intracystic ethanol irrigation. *Ophthalmology.* 2003 Aug;110(8):1601–1605. [https://doi.org/10.1016/s0161-6420\(03\)00543-8](https://doi.org/10.1016/s0161-6420(03)00543-8). PMID: 12917180.
- Gupta V, Rao A, Sinha A, Kumar N, Sihota R. Post-traumatic inclusion cysts of the iris: a longterm prospective case series. *Acta Ophthalmol Scand.* 2007 Dec;85(8):893–896. <https://doi.org/10.1111/j.1600-0420.2007.00975.x>. Epub 2007 Sep 5. PMID: 17822446.
- Siatiri H, Moghimi S, Malihi M, Khodabande A. Use of sealant (HFG) in corneal perforations. *Cornea.* 2008 Oct;27(9):988–991. <https://doi.org/10.1097/ICO.0b013e31817780e6>. PMID: 18812759.
- Sharma A, Kaur R, Kumar S, et al. Fibrin glue versus N-butyl-2-cyanoacrylate in corneal perforations. *Ophthalmology.* 2003 Feb;110(2):291–298. [https://doi.org/10.1016/S0161-6420\(02\)01558-0](https://doi.org/10.1016/S0161-6420(02)01558-0). PMID: 12578769.
- Wang Q, Zhao J, Xu Q, Han C, Hou B. Intraocular application of fibrin glue as an adjunct to pars plana vitrectomy for rhegmatogenous retinal detachment. *Retina.* 2020;40(4):718–724. <https://doi.org/10.1097/IAE.0000000000002584>.
- Hou J, Tao Y, Jiang Y-R, Wang K. In vivo and in vitro study of suprachoroidal fibrin glue. *Jpn J Ophthalmol.* 2009;53(6):640–647. <https://doi.org/10.1007/s10384-009-0725-0>.