

Temporary Efficacy of Pyrimethamine in Juvenile-Onset Tay-Sachs Disease Caused by 2 Unreported HEXA Mutations in the Indian Population

Anaita Udwadia-Hegde, MD, DCH, MRCPCH¹
and Omkar Hajirnis, MD, DNB, MRCPCH²

Abstract

Background: Juvenile Tay-Sachs disease is rarer than other forms of Tay-Sachs disease and is usually seen in children between the age of 2 and 10 years. Pyrimethamine as a pharmacological chaperone was used to increase β -hexosaminidase A activity in this patient. **Patient:** We describe a patient with Tay-Sachs disease from the Indian population, a juvenile case who presented with developmental regression starting at the age of three, initially with motor followed by language regression. She is currently incapacitated with severe behavioral issues. **Conclusion:** This brief communication gives an insight into the efficacy of pharmacological chaperones. It also describes two unreported mutations in hexosaminidase A gene from the Indian population. After commencing Pyrimethamine, though initial benefits with increase in levels corresponded with briefly halting the motor regression, the observed increase was only transient and not associated with discernible beneficial neurological or psychiatric effects.

Keywords

juvenile Tay-Sachs disease, hexosaminidase A, compound heterozygous, pyrimethamine, India

Received September 10, 2016. Received revised November 4, 2016. Accepted for publication November 9, 2016.

Tay-Sachs disease or GM2 gangliosidosis variant B is an autosomal recessive neurodegenerative disorder due to β -N-acetyl-hexosaminidase A (Hex A) deficiency.

Juvenile or subacute GM2 gangliosidosis is an uncommon presentation characterized by gait disturbances, incoordination, speech problems, and intellectual impairment. Behavior or psychiatric disturbances, proximal and distal weakness, and muscle wasting tend to appear later in the disease course.¹ Spasticity and seizures are present by the end of the first decade of life. Loss of vision occurs much later than in the acute infantile form of the disease, and a cherry-red spot is not consistently observed. Instead, optic atrophy and retinitis pigmentosa can be seen late in the course. A vegetative state with decerebrate rigidity develops by age 10 to 15 years, followed within a few years by death, usually from infection. In some cases, the disease pursues a particularly aggressive course, culminating in death in 2 to 4 years.^{1,2}

The age spectrum of juvenile-onset GM2 gangliosidosis is not always clear. The severity of the disease inversely correlates

with the level of hexosaminidase A activity. The age of onset of earliest symptoms, rather than the age at diagnosis, is generally considered to distinguish patients with juvenile gangliosidosis, and many would restrict the diagnosis to patients who show the onset of symptoms between 2 and 10 years of age.²

Although patients with Tay-Sachs disease have been diagnosed in India, most have been the classical infantile onset ones. In the present case, the authors report the clinical,

¹ Pediatric Neurology, Jaslok Hospital and Research Centre, Mumbai, Maharashtra, India

² Pediatric Neurology, Bhaktivedanta Hospital and Research Centre, Thane, Maharashtra, India

Corresponding Author:

Anaita Udwadia-Hegde, MD, DCH, MRCPCH, Pediatric Neurology, Jaslok Hospital and Research Centre, 106, Doctor's House, Opposite Jaslok Hospital, Peddar Road, Mumbai, Maharashtra 400026, India.
Email: anaitahegde@gmail.com



biochemical, and molecular genetic characterization of a case of juvenile Tay-Sachs disease in the Indian population.

Case Report

The patient is an Indian Gujarati girl who presented at the age of 3 years, when she was noted to have developmental regression in her motor milestones. She is the first child of healthy nonconsanguineous parents. Prenatal and perinatal history is reportedly normal. Initial concerns arose at 3 years due to frequent falls, clumsiness, and deteriorating handwriting suggestive of poor fine motor skills. Thereafter for the following year, she gradually appeared clumsier, developing an unsteady gait. She also started with slurring of speech and gradually over the year lost her ability to speak and communicate. Furthermore, she appeared to develop hyperactivity with a limited attention span affecting her learning. No history of seizures was noted. Also no impairment of vision was seen. A brain magnetic resonance imaging (MRI) showed subtle altered signal intensity in the subcortical white matter of the anterior temporal lobes along with mild cortical and cerebellar atrophy. Her urine and plasma metabolic screen did not reveal any abnormality except for elevated plasma lactate on 1 occasion. Ophthalmological examination was normal.

On examination at 8 years of age when the patient presented to our clinic, the patient's head circumference, height, and weight were around average. There were no dysmorphic features. She was drooling excessively and had feeding difficulties. She could walk a few steps unaided, but her gait was unsteady and stiff. Her deep tendon reflexes were slightly increased (3+) with a negative Babinski reflex. She was excessively restless and became easily agitated, upset with inconsolable crying. Cardiovascular and the remainder of her examination were unremarkable with no evidence of organomegaly.

Her repeat brain MRI with spectroscopy showed mild progression of global cortical atrophy, cerebellar atrophy, and ill-defined diffuse white matter T2 hyperintensities along with signal alterations in the dentatorubral pathways. Based on these imaging findings, a diagnosis of late infantile- or juvenile-onset neuronal ceroid lipofuscinosis was in fact considered higher in the list. Ophthalmological examination did not reveal retinal cherry-red spots or optic atrophy. Evoked potentials, visual and auditory, were normal. Her flash electroretinogram showed borderline prolonged latencies. An electroencephalogram study showed independent frontocentral spike-wave discharges with no abnormality with photic stimulation at 1 Hz/s. Her repeat basic metabolic screen was again normal. In view of the above features, a neurology genetic panel was sent followed by advanced metabolic testing confirming a diagnosis of juvenile-onset Tay-Sachs disease and will be described in detail subsequently.

In general, currently, she seems to be troubled by frequent behavioral alterations usually seen as suddenly getting up from sleep followed by inconsolable crying lasting for hours together and not responding to multiple medications. Her sleep remains interrupted. She cannot speak and communication is

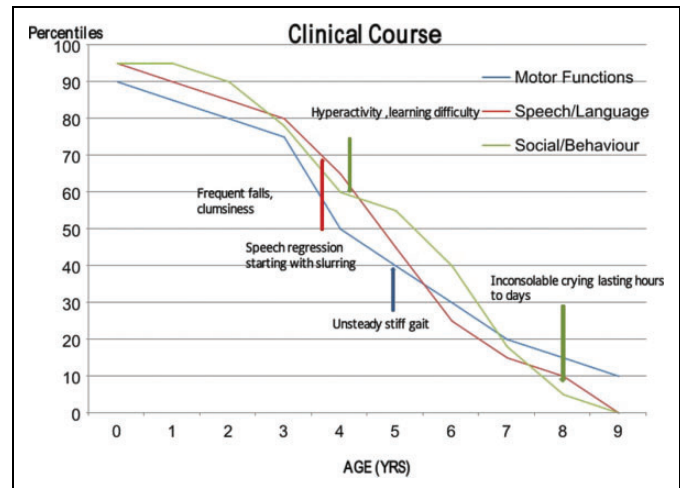


Figure 1. Pictorial summary of developmental regression over the years.

very limited. She is on sodium valproate, clonazepam, and risperidone but with very little effect (Figure 1).

The parents were expecting twins, 2 years after the birth of the index child. However, one of the twins spontaneously aborted in the second trimester. The other twin was delivered normally at full-term gestation but unfortunately died on day 14 of life due to an undiagnosed illness that started with seizures on day 4. His MRI of the brain at day 12 of life showed diffuse swelling with restricted diffusion. His metabolic screening revealed no abnormality. His findings, however, neither suggest nor refute a diagnosis of any lysosomal storage disorder, particularly neonatal-onset Tay-Sachs disease.

Methods

Molecular Analysis of the HEXA Gene

DNA isolated from blood was used to perform targeted region capture using Agilent SureSelectXT capture kit (Agilent Technologies, Santa Clara, CA). The libraries were sequenced to 80 to 100× coverage on Illumina sequencing platform (Illumina, Inc., San Diego, CA). The sequences obtained were aligned to human reference genome (GRCh37/hg19) using BWA program and analyzed using Picard and GATK-Lite toolkit to identify variants in whole exome relevant to clinical indication.

Measurement of β -Hexosaminidase Activity

β -Hexosaminidase activity was measured in leukocytes using artificial fluorogenic substrates, and test results were obtained for total (A + B) and β -hexosaminidase A levels separately.

Results

The diagnosis was established with the genetic sequencing of the *HEXA* gene and measurement of hexosaminidase A activity.

Sequencing the *HEXA* gene resulted in the identification of 2 previously unreported mutations. (1) Heterozygous 4 base

Table 1. Correlation of Genetics and Enzyme Levels in Index Patient and Parents.

	Hexosaminidase A Levels (nmol/h/mg)	Normal	Genetic Reports
		Range	
Index case	2.8	62-310	Mutations in exon 11 and 13 of HEXA gene
Father	105	62-310	Heterozygous missense variation in exon 13 of HEXA gene
Mother	39	62-310	Heterozygous 4 base insertion in exon 11 of HEXA gene

insertion in exon 11 of the *HEXA* gene (chr 15:72638921_72638924; insGATA), which resulted in a frame shift and premature truncation of the protein 5 amino acids downstream to codon 427 (p.Y427ifsX5; ENST00000566304). This same mutation was found to be present in the mother and absent in the father. (2) Heterozygous missense variation in exon 13 of the *HEXA* gene (chr 15: 72637817; C> C/T), which resulted in an amino acid substitution of histidine for arginine at codon 510 (p.R510H; ENST00000566304). This variation was seen in the father and absent in the mother.

Thus, these variations that were earlier classified as likely compound heterozygous variants of unknown significance now showed that each parent was one of the carriers of the above-mentioned *HEXA* variations, which were hence found in a compound heterozygous state in their daughter. Also, they could be correlated with the clinical symptoms in the patient.

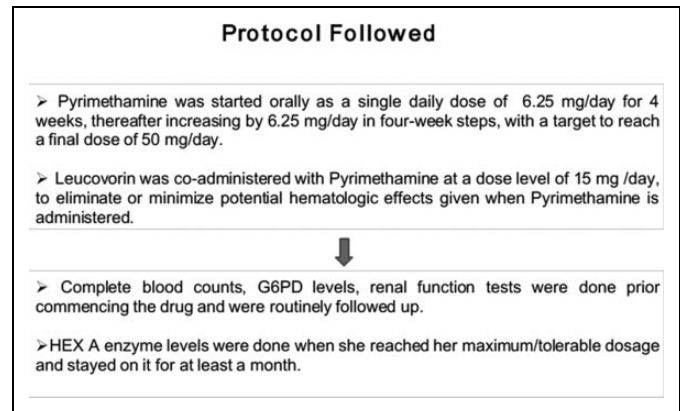
The diagnosis was confirmed with the measurement of hexosaminidase A activity. A low percentage of hexosaminidase A activity was obtained in the leukocytes (2.8 nmol/h/mg, reference range: 62-310 nmol/h/mg). The total β -hexosaminidase (A + B) was normal ruling out Sandhoff disease (Table 1).

Treatment Rendered

The treatment for Tay-Sachs disease is largely supportive and directed to providing adequate nutrition and hydration, managing infectious disease, protecting the airway, controlling seizures, and preventing secondary complications.

Early experimental intravenous enzyme replacement trials were unsuccessful, as the large molecular weight enzyme did not cross the blood-brain barrier.³ A clinical trial used hexosaminidase A inhibitors to reduce the biosynthesis of glycosphingolipid precursors to GM2 ganglioside, which though was promising in mouse models was found unsatisfactory in humans.^{4,5}

A group of researchers explored the possibility that pharmacological chaperones can augment hexosaminidase A.⁶ Chaperones are small molecules that can assist the folding of mutant misfolded proteins retaining partial catalytic function and thus allow better access of such partially functional enzymes to the lysosome, resulting in an increase in total

**Figure 2.** Protocol followed using pyrimethamine as a pharmacological chaperone.

enzyme activity. Following extensive screening of candidate molecules, pyrimethamine—an United States Food and Drug Administration–approved antimalarial/antitoxoplasmosis agent already used in humans, which is capable of entering the central nervous system—was shown to enhance hexosaminidase A activity in vitro in human fibroblasts.⁷ Several trials were conducted, which proved the efficacy of pyrimethamine in late-onset Tay-Sachs disease, and it is becoming clear that pyrimethamine therapy can increase hexosaminidase A activity in late-onset Tay-Sachs disease in vivo. Optimal doses should be tailored individually to avoid loss of biochemical effects.^{8,9}

Considering the positive response in various trials around the world, after counseling the parents and obtaining necessary consent, we put this patient on a gradual stepping dose of pyrimethamine from 6.25 mg/d (0.5 mg/kg/d) attempting to reach a maximum of 50 mg/d (3 mg/kg/d) by doubling the dose every 4 weeks along with daily folinic acid (15 mg/d). Her complete blood counts, G6PD levels, and renal function tests were done prior commencing the drug and were routinely followed up. Her hexosaminidase A enzyme levels were done when she reached her maximum dosage and stayed on it for at least a month (Figure 2).

Results of Treatment and Follow-Up Studies

She was noted to develop pallor and apathy with generalized weakness when her pyrimethamine dosage was increased to 31.25 mg/d. Complete blood count was suggestive of pancytopenia, which responded rapidly on increasing the dose of leucovorin to 30 mg/d and reducing pyrimethamine back to 25 mg/d. Apart from the above, no adverse effects were noted.

After continuing her on pyrimethamine 25 mg/d for further 1 month, her hexosaminidase A enzyme levels were repeated. It was found that her hexosaminidase A levels increased from 2.6 to 4.4 nmol/h/mg. It looked like the patient's increase in leukocyte hexosaminidase A enzyme activity was a true biochemical response to pyrimethamine as the laboratory reconfirmed the levels taking into consideration the variation in

enzyme activity expected with the leukocyte counts. More importantly, apart from the biochemical increase in enzyme levels, clinically she restarted independent walking for few steps, which she had lost briefly before commencing pyrimethamine. Although the normal reference range of hexosaminidase A enzyme activity is 62 to 310 nmol/h/mg, the increase to 4.4 nmol/h/mg was highly encouraging as it nudged toward the theoretical value of 10 nmol/h/mg, which if achieved may halt the progression of the disease further. In spite of motor improvement, her behavioral and neuropsychiatric complaints showed no respite and continued unabated.

However, after continuing the same dosage of 25 mg/d, we repeated levels 3 months later, which showed a drop from 4.4 to 3.8 nmol/h/mg. As her levels dropped, her regression in motor milestones returned and finally due to no further benefit, we decided to discontinue pyrimethamine soon thereafter. The total duration of treatment was 8 months, with 6 months on the maximum tolerable dose of 25 mg/d.

Discussion

The patient described is a case of juvenile-onset Tay-Sachs disease from the Indian population where the prevalence is much rarer. The clinical features of the patient are similar to those reported for other juvenile Tay-Sachs disease cases.¹ The B1 variant associated with individuals with juvenile or chronic and adult-onset forms of hexosaminidase A deficiency are usually compound heterozygotes for a null allele and an allele that results in residual but low activity of the hexosaminidase A enzyme toward GM2 ganglioside or 2 alleles that result in low-residual hexosaminidase A activity. This patient was proved to be a compound heterozygote.

The mutations leading to Tay-Sachs disease in India are yet largely unknown. One study from India done on infantile onset disease concluded that mutations responsible for Tay-Sachs disease in Indian population are unique. According to this study, patients originating from Gujarat state could be screened for a founder mutation, namely, p.E462V. However, except for this mutation, the rest of the mutations in this study were found to be nonrecurrent.¹⁰ Apart from this review, there has been a scarcity of reported mutations from India. This patient though belonging from Gujarat did not have the above-reported mutation. The mutations found in our case can thus help increasing the database from India.

As we know, enzyme replacement therapy for lysosomal storage disorders is available for only few disorders and is expensive and out of reach for most people from developing countries. Pharmacological chaperone therapy is emerging as an alternative therapy and appears advantageous when compared to enzyme replacement therapy, as the chaperones are better distributed in tissues, including the brain, and also because therapy may be administered orally. Limitations are that only patients with chaperone responsive mutations will be amenable to this therapy. The combination of enzyme replacement therapy and pharmacological chaperone therapy can

result in a synergistic effect in few disorders, which would be helpful in patients responding poorly to enzyme replacement therapy and in tissues where corrective levels of recombinant enzymes are difficult to obtain. The number of chaperone molecules will increase in the next few years—studies with high-throughput screenings represent an efficient way of identifying new compounds for new diseases.^{11,12}

Several aspects of the present case outcome should be particularly noteworthy. First, the increase in hexosaminidase A activity and then decrease in activity corresponded with the improvement and regression in her motor milestones, respectively. As with other case reports and trials, we also did not have any discernible neuropsychiatric benefits seen with pyrimethamine. This effect still fell short of reaching the theoretically desirable increase in hexosaminidase A to “10% of normal hexosaminidase A,” above which a disease-free phenotype has been documented despite the presence of mutations.^{13,14}

Second, although the induced rise in hexosaminidase A was temporary, the levels continued to be above the initial baseline levels indicating a biochemical benefit without any clinical benefit. A new study shows that cyclic low dose of pyrimethamine can increase hexosaminidase A activity in patients with late-onset Tay-Sachs disease.¹⁵ Although we discussed this option with our patient’s parents, considering her rapidly deteriorating condition, they declined to try this option.

Finally, although pharmacological chaperones are a promising therapeutic tool in lysosomal storage diseases, the present report is only an example of limited success in their application and much needs to be discerned about this mode of therapeutics.

Authors’ Note

Guarantor of Submission: The corresponding author is the guarantor of submission.

Author Contributions

AUH and OH are the first authors who contributed to this work. AUH is the leading physician of the presented case, and OH assisted the lead physician and contributed to the writing of the manuscript.

Declaration of Conflicting Interests

The authors declared no potential conflicts of interest with respect to the research, authorship, and/or publication of this article.

Funding

The authors received no financial support for the research, authorship, and/or publication of this article.

Ethical Approval

Informed consent of the parents of the presented case was taken before the preparation of this case report. All of the work meets the ethical guidelines.

References

1. Maegawa GH, Stockley T, Tropak M, et al. The natural history of juvenile or subacute GM2 gangliosidosis: 21 new cases and

- literature review of 134 previously reported. *Pediatrics*. 2006; 118(5): e1550-e1562.
2. Gravel R, Kaback M, Proia P, Sandhoff K, Suzuki K, Suzuki K. The GM2 gangliosidosis. Scriver C, Beaudet A, Sly W, Valle D, eds. *The Metabolic and Molecular Bases of Inherited Diseases*. New York, NY: McGraw-Hill; 2001:3827-387.
 3. Desnick RJ, Schuchman EH. Enzyme replacement and enhancement therapies: lessons from lysosomal disorders. *Nat Rev Genet*. 2002;3(12):954-966.
 4. Jeyakumar M, Butters TD, Cortina-Borja M, et al. Delayed symptom onset and increased life expectancy in Sandhoff disease mice treated with N-butyldeoxynojirimycin. *Proc Natl Acad Sci U S A*. 1999;96(11):6388-6393.
 5. Shapiro BE, Pastores GM, Gianutsos J, Luzy C, Kolodny EH. Miglustat in late onset Tay-Sachs disease: a 12-month, randomized, controlled clinical study with 24 months of extended treatment. *Genet Med*. 2009;11(6):425-433.
 6. Tropak MB, Mahuran D. Lending a helping hand, screening chemical libraries for compounds that enhance beta-hexosaminidase A activity in GM2 gangliosidosis cells. *FEBS J*. 2007;274(19):4951-4961.
 7. Maegawa GH, Tropak M, Buttner J, et al. Pyrimethamine as a potential pharmacological chaperone for late-onset forms of GM2 gangliosidosis. *J Biol Chem*. 2007;282(12): 9150-9161.
 8. Clarke JT, Mahuran DJ, Sathe S, et al. An open-label phase I/II clinical trial of pyrimethamine for the treatment of patients affected with chronic GM2 gangliosidosis (Tay-Sachs or Sandhoff variants). *Mol Genet Metab*. 2011; 102(1):6-12.
 9. Osher E, Fattal-Valevski A, Sagie L, et al. Pyrimethamine increases β -hexosaminidase A activity in patients with late onset Tay Sachs. *Mol Genet Metab*. 2011;102(3):356-363.
 10. Mistri M, Tamhankar PM, Sheth F, et al. Identification of novel mutations in HEXA gene in children affected with Tay Sachs disease from India. *PLoS One*. 2012;7(6): e39122. doi:10.1371/journal.pone.0039122.
 11. Parenti G, Pignata C, Vajro P, Salerno M. New strategies for the treatment of lysosomal storage diseases (review). *Int J Mol Med*. 2013;31(1):11-20.
 12. Parenti G, Andria G, Valenzano KJ. Pharmacological chaperone therapy: preclinical development, clinical translation, and prospects for the treatment of lysosomal storage disorders. *Mol Ther*. 2015;23(7):1138-1148. doi:10.1038/mt.2015.62.
 13. Neudorfer O, Pastores GM, Zeng BJ, Gianutsos J, Zaroff CM, Kolodny EH. Late-onset Tay-Sachs disease: phenotypic characterization and genotypic correlations in 21 affected patients. *Genet Med*. 2005;7(2):119-123.
 14. Leinekugel P, Michel S, Conzelmann E, Sandhoff K. Quantitative correlation between the residual activity of beta-hexosaminidase A and arylsulfatase A and the severity of the resulting lysosomal storage disease. *Hum Genet*. 1992;88(5):513-523.
 15. Osher E, Fattal-Valevski A, Sagie L, et al. Effect of cyclic, low dose pyrimethamine treatment in patients with late onset Tay Sachs: an open label, extended pilot study. *Orphanet J Rare Dis*. 2015;10:45. doi:10.1186/s13023-015-0260-7.