Case Report

Journal of INTERNATIONAL MEDICAL RESEARCH

Journal of International Medical Research
48(8) 1–7
© The Author(s) 2020
Article reuse guidelines:
sagepub.com/journals-permissions
DOI: 10.1177/0300060520936445
journals.sagepub.com/home/imr
SAGE

Prolonged thrombocytopenia in a neonate with Noonan syndrome: a case report

Meng Li, Jinghui Zhang and Nianzheng Sun

Abstract

We report a case of a Chinese neonate who was diagnosed with Noonan syndrome and had persistent, self-limited thrombocytopenia. The neonate was admitted to the Neonatology Department 20 minutes after birth because of respiratory distress. From birth until 2 months of age, platelet values fluctuated between approximately 6 and 30×10^9/L. There was no intracranial hemorrhage. However, the child had a transient hypocalcemic seizure and fever. We excluded thrombocytopenia caused by perinatal asphyxia, immune thrombocytopenia, fetomaternal alloimmune thrombocytopenia, juvenile myelomonocytic leukemia, and chromosome 13, 18, and 21 trisomy syndromes. Despite treatment with anti-infective agents and transfusion of platelets and immunoglobulin, the platelet count did not return to the normal range. Genetic testing confirmed a *PTPN11* gene mutation, which led to the diagnosis of Noonan syndrome. At 3 months of age, the platelet count gradually increased without intervention and returned to the normal range by 6 months. We speculate that the thrombocytopenia in this case was closely related to Noonan syndrome.

Keywords

Thrombocytopenia, dysmorphism, neonate, hypocalcemic seizure, Noonan syndrome, platelets

Date received: 7 January 2020; accepted: 2 June 2020

Introduction

Noonan syndrome (NS) is a relatively common autosomal dominant disease and its incidence ranges from 1/1000 to 1/2500.[1] The main clinical characteristics of NS include facial dysmorphology, congenital heart disease, delayed development, short

Department of Pediatrics, Qilu Hospital of Shandong University, Jinan, Shandong, China

Corresponding author:
Nianzheng Sun, Department of Pediatrics, Qilu Hospital of Shandong University, No. 107 Cultural West Road, Jinan 250012, Shandong, China.
Email: ewbf@sina.com

Creative Commons Non Commercial CC BY-NC: This article is distributed under the terms of the Creative Commons Attribution-NonCommercial 4.0 License (https://creativecommons.org/licenses/by-nc/4.0/) which permits non-commercial use, reproduction and distribution of the work without further permission provided the original work is attributed as specified on the SAGE and Open Access pages (https://us.sagepub.com/en-us/nam/open-access-at-sage).

stature, urinary tract malformations, and bleeding diatheses. The diagnosis of NS is currently based on clinical manifestations, as proposed by Dutch clinicians in 1994.[2]

The characteristic facial dysmorphology and musculoskeletal system features of NS are essential for its diagnosis. Facial dysmorphology is most common in infants and becomes increasingly atypical with growth.[3] The most common features in boys include cryptorchidism (90%) and special facial features (86%). The most common type of heart defect of NS is pulmonary valve stenosis (67%).[4]

Among NS-associated genes, hemorrhagic tendency is more common in *PTPN11* gene mutations.[5] Although there is a relatively low platelet count, coagulation factor activity and protein C have been observed in patients with NS and *PTPN11* gene mutations.[5] Definitive diagnosis of thrombocytopenia or coagulation disorder is rarely established in NS. Prolonged thrombocytopenia originating from the neonatal period has been reported in several cases, but most were preterm[6] or small for gestational age[7] neonates. In one term *PTPN11* gene mutation-positive neonate with NS, thrombocytopenia was definitively induced by a fetomaternal alloimmune reaction.[8]

We report here a term and macrosomic neonate with NS and a *PTPN11* gene mutation. In this neonate, there was prolonged, but fluctuating, thrombocytopenia. We also suggest the possible genetic basis of NS.

Case report

CARE guidelines were followed for this case report. We report a proband who was a Chinese female infant. She was the second child of healthy non-consanguineous parents and presented to our hospital with a history of persistent thrombocytopenia 26 days after birth. The details of this patient were de-identified so that the identity of the patient could not be ascertained. Therefore, signed patient consent was not required. This study was approved by the ethics committee of Qilu Hospital. The neonate was born at 38 and 4/7 weeks' gestation with Apgar scores of 10, 10, and 10 at 1, 5, and 10 minutes, respectively. Her birth weight was 4500 g. The neonate was transferred to another hospital 20 minutes after birth because of respiratory distress. Routine blood testing the next day showed thrombocytopenia (platelet count: 9×10^9/L). Polyhydramnios was diagnosed at 20 weeks of gestation and increased nuchal translucency was noted on ultrasonography. Prenatal screening showed a low risk for trisomies 13, 18, and 21. Platelet antigens (HPA1a, HPA5b, and HPA15b) were negative in the mother, father, and newborn.

On a physical examination (Figure 1), the neonate was irritable with multiple skinfolds and enlarged superficial lymph nodes. The neonate had a dysmorphic face with a high forehead, low-set posteriorly rotated ears, a short, webbed neck, and a barrel chest. A systolic cardiac murmur was auscultated. A dysplastic aortic valve and an atrial sept defect were observed on transthoracic echocardiography. An abdominal examination showed an enlarged liver and spleen. The neonate had bilateral hyperflexion of the wrist joints and hyperabduction of the elbow joints.

Blood test results on day 27 of life were as follows: white blood cell (WBC) count, 10.64×10^9/L; neutrophils, 35.8%; lymphocytes, 40.1%; red blood cell (RBC) count, 3.93×10^{12}/L; hemoglobin, 106.0 g/L; and platelet count, 27×10^9/L. A peripheral blood smear showed that the proportion of poorly differentiated cells was 8% and there were nucleated RBCs and thrombocytopenia. The procalcitonin level was 0.103 ng/mL (<0.1 ng/mL). Serology was negative for toxoplasma, rubella, cytomegalovirus, and herpes simplex virus II infections.

Figure 1. Photographs showing particular symptoms of the neonate taken at approximately 51 to 54 days after birth. The symptoms include a dysmorphic face with a high forehead, low-set posteriorly rotated ears, a protruded navel, and hyperflexion of the wrist.

Because of the possibility of an infection and immunodeficiency, the infant was treated with anti-infective agents and an infusion of gamma globulin and platelets. Platelet transfusion was performed five times within 2 months after birth. The platelet level was not restored (30–60 $\times 10^9$/L). The infant had a convulsion on day 36 of life, and this was characterized by sweating, crying, dysphoria, and a transient upward ocular gaze, followed by a fever of 39.4°C and persistent opisthotonos (2–8 minutes). Six hours later, the heart rate was 210 beats/minute at rest. Blood test results on the day of the seizure were as follows: WBC count, 34.13 $\times 10^9$/L; neutrophils, 47.9%; lymphocytes, 12.91%; RBC count, 3.51 $\times 10^{12}$/L; hemoglobin, 100.0 g/L; platelet count, 16 $\times 10^9$/L; and calcium, 0.98 mmol/L. Intracranial hemorrhage was excluded on the basis a craniocerebral computed tomographic scan. Therefore, the infant was treated with intravenous calcium, myocardial nutrition, intensive anti-infective agents, and sedation. The hypocalcemia persisted for 9 days. On day 52 of life, routine blood testing showed the following: WBC count, 14.99 $\times 10^9$/L; neutrophils, 47.2%; lymphocytes, 35.1%; RBC count, 3.55 $\times 10^{12}$/L; hemoglobin, 104.0 g/L; and platelet count, 32 $\times 10^9$/L. She received another platelet transfusion, after which the platelet count was 142 $\times 10^9$/L. Therefore, she was discharged

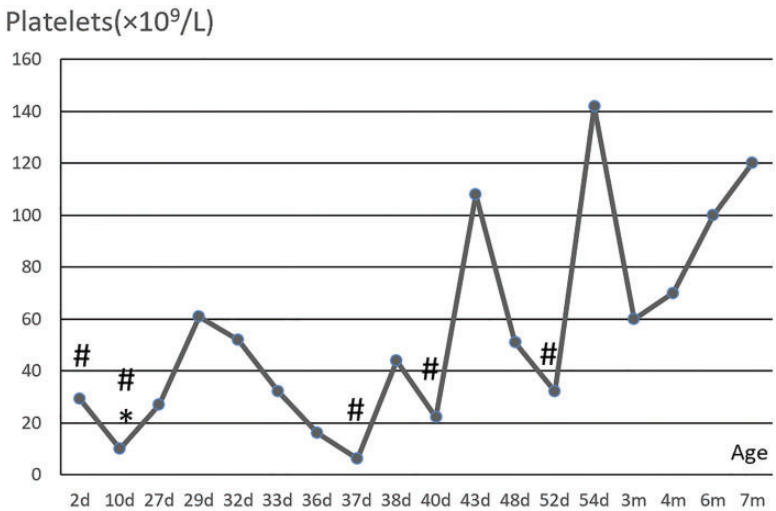

Figure 2. Bone marrow smear. a: Bone marrow at day 35 after birth. b: Bone marrow at day 56 after birth.

home 2 days later. At the 3- and 6-month follow-up evaluations, the platelet count fluctuated between 60 and 70×10^9/L and 100 and 120×10^9/L, respectively (Figure 2).

A bone marrow biopsy (Figure 3) on day 34 of life showed 5% poorly differentiated lymphocytes, 3% megakaryocytes, and platelets were rarely observed. The corresponding peripheral blood smear showed an elevated WBC count, a high mononuclear cell ratio, occasional poorly differentiated lymphocytes, and platelets were rare. A repeat bone marrow biopsy on day 57 of life was normal. The corresponding peripheral blood smear showed a high mononuclear cell ratio. The prothrombin time and activated partial thromboplastin time remained normal. Further analysis showed normal levels of clotting factors VIII, XI, and XII. Cardiac sonography on day 48 of life showed an atrial septal defect and mild-moderate pulmonary stenosis. No obvious renal, ureteral, or bladder abnormalities were noted on ultrasonography of the urinary tract. Whole-exon gene sequencing was performed because of the multiple congenital malformations and persistent thrombocytopenia. This technique showed a mutation (c.1517A>C (p. Q506P]) in exon 13 of the *PTPN11* gene, which corroborated the diagnosis of NS.

Discussion

Genes that are involved in NS mutations include *PTPN11*, *SOS1*, *RAF1*, *BRAF*, *KRAS*, *NRAS*, *SHOC2*, *CBL*, and *MEK1*. Among the NS-associated genes, a *PTPN11* gene mutation is the most common, accounting for approximately 50% of mutations.[2,5,9] The human *PTPN11* gene is located on 12q24.13 and contains 16 exons.[10] The most common mutation involving the *PTPN11* gene is a missense mutation and the mutation sites are distributed in exons 3, 4, 7, 8, 12, and 13. Children with exon 8 mutations tend to have mild mental retardation, and those with exon 3, 4, and 13 mutations are at increased risk of developing to juvenile myelomonocytic leukemia (JMML).[3,5,9,11]

NS with abnormal hematological findings include thrombocytopenia, platelet dysfunction, decreased coagulation factors,

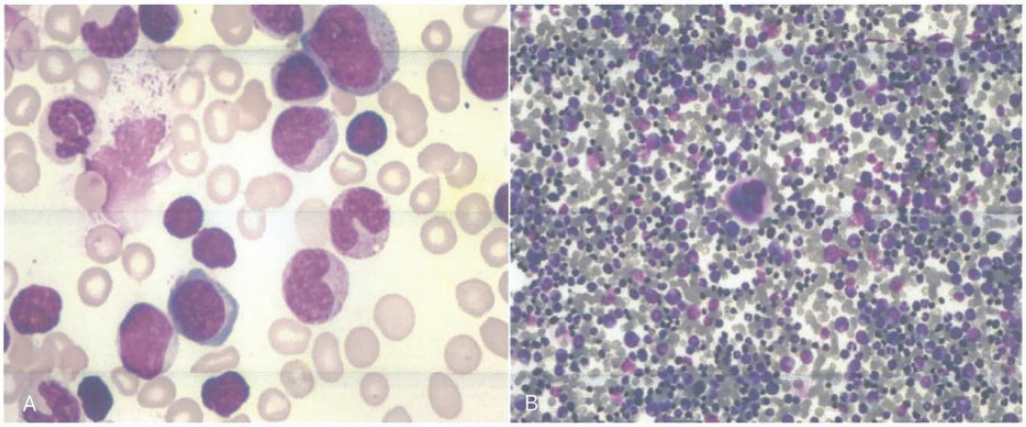

Figure 3. Platelet counts of this patient over 7 months since birth. #Platelet transfusion on 2, 10, 37, 40, and 52 days after birth. *Immunoglobulin transfusion on the 2nd day after birth.

von Willebrand factor-based hemophilia, JMML, and myelodysplasia. The mechanism involved in the thrombocytopenia of our proband is unclear. Derbent et al.[4] described a case of a *PTPN11* mutation in an infant with NS and the c.1517A>C mutation, as in our proband. However, their case only had low protein C activity without thrombocytopenia. Because JMML has a close relationship with *PTPN11* mutations,[11] we initially speculated that JMML may have accounted for the thrombocytopenia in our patient. *De novo* JMML cases have shown that c.1517A>C and c.218C>T mutations can develop into JMML, and c.218C>A is a mutation hotspot. The most common *PTPN11* mutation in *de novo* JMML is c.226G>A in patients with NS.[4,12] JMML is more likely to occur in patients with amino acid mutation sites at 61, 71, 72, and 76.[13] Despite NS accompanied by JMML having a tendency to undergo spontaneous remission,[14,15] a low platelet count ($<40 \times 10^9$/L), fetal hemoglobin values >40%, and monosomy 7 at the time of diagnosis may be associated with a poor prognosis.[12] In patients with *PTPN11*-associated NS accompanied by thrombocytopenia, the reported mutation sites include c.218C>T and c.181G>A, both of which are in exon 3.[8,16] However, in our case, the mutation site was c.1517A>C, which is located in exon 13, and bone marrow cytology did not show dyshematopoiesis. Additionally, our proband had a good prognosis of recovered platelet levels, which could not be explained by JMML.

Nunes et al[16] proposed that the causes of thrombocytopenia in children with NS include a reduction in megakaryocytes, early clinical features of JMML, and sequestration of platelets in an enlarged and/or myelodysplastic spleen. Our proband also had a reduced level of megakaryocytes in bone marrow, which indicated that thrombocytopenia may have been attributable to a reduction in production of megakaryocytes. The mechanism involved in thrombocytopenia associated with the *PTPN11* gene may include encoding the SHP-2 domain structure, which contains the two non-transmembrane protein-tyrosine phosphatases (PTPs) Shp1 and Shp2. Shp1 is expressed in hematopoietic and epithelial cells and Shp2 has a wide range of expression. Shp1 and Shp2 have major roles in the development of

megakaryocytes, and platelet production and functional maturation,[17] including regulating signaling from a variety of tyrosine kinase-linked receptors. The mutated amino acid Q506P found in our case is located in the PTP domain of SHP-2. Therefore, thrombocytopenia may be a result of Shp1 and/or Shp2 inactivation after *PTPN11* mutation.

Other factors should be ruled out in patients with early-onset thrombocytopenia (in the first 72 hours of life), including infections, autoimmune thrombocytopenia, intrauterine distress, intrauterine growth restriction, and chromosomal and non-chromosomal factors. The most common cause of severe thrombocytopenia immediately after birth in healthy newborns is immune thrombocytopenia, in which the mother transfers anti-platelet antibodies to the fetus.[18] NS should be considered in neonates with an abnormal blood system combined with facial dysmorphology and abnormal skeletal and muscle systems. The prenatal diagnosis of NS should not only rely on a genetic examination, but also rely on antenatal ultrasonic examinations.[19] When patients with NS require surgery, preoperative examinations should include blood routine testing, including the prothrombin time and activated partial thromboplastin time, and the bleeding time. If the results are normal, the risk of coagulation complications is low and further testing is not necessary.[5] A study of 297 Dutch patients with NS showed that those with a *PTPN11* mutation had a 3.5-fold higher risk of cancer than healthy counterparts.[20] The severity of cardiovascular malformations directly determines the prognosis of patients, especially hypertrophic cardiomyopathy.[21]

Declaration of conflicting interest

The authors declare that there is no conflict of interest.

Funding

This work was supported by the Key Research and Development Project of Shandong Province (No. 2019GSF1082).

ORCID iD

Nianzheng Sun https://orcid.org/0000-0002-6485-1758

References

1. Sharland M, Burch M, McKenna et al. A clinical study of Noonan syndrome. *Dis Child*. 1992 Feb; 67(2):178–83.
2. Van Der Burgt I, Berends E, Lommen E, et al. Clinical and molecular studies in a large Dutch family with Noonan syndrome. *Am J Med Genet* 1994; 53: 187–191.
3. Romano AA, Allanson JE, Dahlgren J, et al. Noonan syndrome: clinical features, diagnosis, and management guidelines. *Pediatrics* 2010; 126: 746–759.
4. Jongmans M, Otten B, Noordam K, et al. Genetics and variation in phenotype in Noonan syndrome. *Horm Res* 2004; 62: 56–59.
5. Derbent M, Öncel Y, Tokel K, et al. Clinical and hematologic findings in Noonan syndrome patients with PTPN11 gene mutations. *Am J Med Genet A* 2010; 152A: 2768–2774.
6. Schönfeld M, Selig M, Russo A, et al. Rapid detection by hydrops panel of Noonan syndrome with PTPN11 mutation (p.Thr73Ile) and persistent thrombocytopenia. *Mol Genet Genomic Med* 2020; 8: e1174.
7. Christensen RD, Yaish HM, Leon EL, et al. A de novo T73I mutation in PTPN11 in a neonate with severe and prolonged congenital thrombocytopenia and Noonan syndrome. *Neonatology* 2013; 104: 1–5.
8. Salva I, Batalha S, Maia R, et al. Prolonged thrombocytopenia in a child with severe neonatal alloimmune reaction and Noonan syndrome. *Platelets* 2016; 27: 381–382.
9. Atik T, Aykut A, Hazan F, et al. Mutation spectrum and phenotypic features in Noonan syndrome with PTPN11 mutations: definition of two novel mutations. *Indian J Pediatr* 2016; 83: 517–521.

10. Dechert U, Duncan AM, Bastien L, et al. Protein-tyrosine phosphatase SH-PTP2 (PTPN11) is localized to 12q24.1–24.3. *Hum Genet* 1995; 96: 609–15
11. Briggs BJ and Dickerman JD. Bleeding disorders in Noonan syndrome. *Pediatr Blood Cancer* 2012; 58: 167–172.
12. Satwani P, Kahn J and Dvorak CC. Juvenile myelomonocytic leukemia. *Pediatr Clin North Am* 2015; 62: 95–106.
13. Niihori T, Aoki Y, Ohashi H, et al. Functional analysis of PTPN11/SHP-2 mutants identified in Noonan syndrome and childhood leukemia. *J Hum Genet* 2005; 50: 192–202.
14. Kasongo L and Nicolescu R. Neonatal haematological complication in Noonan syndrome: future concerns about growth hormone therapy. Poster Session On Line. com.822-P1.
15. Hutin C, May S and Prestidge T. Juvenile myelomonocytic leukaemia and Noonan syndrome: a case study. *N Z J Med Lab Sci* 2016; 70: 110–112.
16. Nunes P, Aguilar S, Prado SN, et al. Severe congenital thrombocytopaenia–first clinical manifestation of Noonan syndrome. *BMJ Case Rep* 2012; 2012: bcr1020114940. doi: 10.1136/bcr.10.2011.4940.
17. Mazharian A, Mori J, Wang YJ, et al. Megakaryocyte-specific deletion of the protein-tyrosine phosphatases Shp1 and Shp2 causes abnormal megakaryocyte development, platelet production, and function. *Blood* 2013; 121: 4205–4220.
18. Sola MC. Evaluation and treatment of severe and prolonged thrombocytopenia in neonates. *Clin Perinatol* 2004; 31: 1–14.
19. Bouchghoul H, Colmant C, Senat M, et al. EP12.01: Noonan syndrome: new features. *Ultrasound Obstet Gynecol* 2016; 48: 317.
20. Jongmans MCJ, Van Der Burgt I, Hoogerbruggep PM, et al. Cancer risk in patients with Noonan syndrome carrying a PTPN11 mutation. *Eur J Hum Genet* 2011, 19: 870–874.
21. Khorgami MR, Moradian M, Omidi N, et al. Management of cardiovascular disorders in patients with Noonan Syndrome: a case report. *J Tehran Heart Cent* 2017; 12: 184–187.