

## Feasibility and outcomes of laparoscopic enucleation for pancreatic neoplasms

Kyu Sung Choi, Jun Chul Chung, Hyung Chul Kim

*Department of Surgery, Soonchunhyang University Bucheon Hospital, Soonchunhyang University College of Medicine, Bucheon, Korea*

**Purpose:** With the advancement of laparoscopic techniques and instruments, laparoscopic approach for pancreatic lesions has become an increasingly used procedure. But, there are few and limited studies about laparoscopic enucleation (LE) for pancreatic lesions. Therefore, the purpose of this study was to present our experience and to evaluate the clinical outcome of LE for pancreatic benign or borderline malignant tumors.

**Methods:** Between May 2005 and December 2011, 11 patients who underwent LE were analyzed. Candidates for LE met the following criteria: benign or borderline malignant pancreatic tumor, no involvement of main pancreatic duct, and outwardly growing tumor with small tumor bed.

**Results:** All 11 patients (10 women and 1 man with a mean age of  $43.1 \pm 11.9$  years) who underwent LE were completed laparoscopically without conversion. The mean diameter of tumor was  $4.0 \pm 3.3$  cm and all cases had benign tumors at the final pathologic diagnosis. One patient (9%) developed pancreatic fistula and mean postoperative hospital stay was  $5.5 \pm 1.7$  days. During follow-up period (mean,  $44.3 \pm 23.9$  months), all patients were alive with no recurrence or new onset of diabetes.

**Conclusion:** LE is a safe and effective procedure, and should be considered as a treatment option for pancreatic lesions that do not involve the main pancreatic duct and have an outgrowing aspect with small tumor bed.

[Ann Surg Treat Res 2014;87(6):285-289]

**Key Words:** Pancreatic neoplasm, Enucleation, Laparoscopic surgery, Laparoscopy

### INTRODUCTION

Traditionally, benign or borderline malignant pancreatic tumors have been treated by major standard resections such as pancreaticoduodenectomy (PD) and distal pancreatectomy (DP) with or without splenectomy [1]. Although these procedures can be performed with low morbidity and mortality rate, resection of a large amount of normal pancreas can be associated with an increased risk of endocrine or exocrine insufficiency [2]. In this matter, some authors reported that enucleation can be considered as an alternative surgical procedure [3-5]. Compared with major resections, enucleation is characterized by extensive parenchymal preservation, less operation time, and faster

recovery [6]. With the advancement of laparoscopic techniques and instruments, laparoscopic approach for pancreatic lesions has become an increasingly used procedure. Although prospective randomized controlled study is absent, several reports documented the feasibility, safety, and effectiveness of laparoscopic enucleation (LE) in benign or borderline malignant pancreatic tumors [1,5,7,8]. However, these reports included case reports and small series. Therefore, the purpose of this study was to present the surgical experience in our institution and to analyze the postoperative outcome of LE for benign or borderline malignant tumors of the pancreas.

In particular, there is very limited information on the outcomes of LE compared with laparoscopic distal pancreatectomy

Received April 21, 2014, Revised June 9, 2014, Accepted July 1, 2014

**Corresponding Author: Jun Chul Chung**

Department of Surgery, Soonchunhyang University Bucheon Hospital, 170 Jomaru-ro, Wonmi-gu, Bucheon 420-767, Korea

**Tel:** +82-32-621-5255, **Fax:** +82-32-621-5016

**E-mail:** [capcjc@schmc.ac.kr](mailto:capcjc@schmc.ac.kr)

Copyright © 2014, the Korean Surgical Society

© Annals of Surgical Treatment and Research is an Open Access Journal. All articles are distributed under the terms of the Creative Commons Attribution Non-Commercial License (<http://creativecommons.org/licenses/by-nc/3.0/>) which permits unrestricted non-commercial use, distribution, and reproduction in any medium, provided the original work is properly cited.

(LDP). Therefore, we investigated clinical outcomes to evaluate the safety and efficacy of LE compared with LDP in benign or borderline malignant tumors of the pancreas.

## METHODS

After Soonchunhyang University Bucheon Hospital Institutional Review Board's approval, from May 2005 to December 2011, 11 consecutive patients who underwent LE for benign or borderline malignant tumors of the pancreas were recruited into the current study. We retrospectively analyzed the medical records and this study conformed to the ethical guidelines of the Declaration of Helsinki.

In all cases, ultrasonography (USG), CT, and MRI including magnetic resonance cholangiopancreatography (MRCP) were routinely performed before operation. The indications of LE were followed: (1) preoperative evaluations strongly suggesting benign or borderline malignant nature tumor, (2) no involvement of the main pancreatic duct, and (3) outwardly growing tumor with small tumor bed. For small benign or borderline malignant lesions (less than 2 cm), we recommended close observation. However, if the lesion had solid portion or if the patient strongly wanted surgery, we performed operation. Complete tumor removal with clear margins was the management principle in each case. The following characteristics were collected and analyzed on each patient: age, sex, body mass index (BMI), presentation, preoperative pancreatitis, preoperative diagnosis, tumor location, tumor size, final pathology, complication, and recent follow-up details. In addition, the perioperative outcomes such as operation time, blood loss, return to normal bowel movement, return to adequate oral intake, length of postoperative hospital stay, pancreatic fistula rate, overall postoperative mortality, and recurrence rate were analyzed. According to the International Study Group of Pancreatic Fistula (ISGPF) criteria, pancreatic fistula was defined as any measurable drainage from an operatively placed drain on or after postoperative day 3, with an amylase content greater than 3 times the upper limit of normal serum amylase levels [9].

All patients underwent regular follow-up examinations postoperatively every 6 months for 5 years and annually thereafter. The mean follow-up period was  $44.3 \pm 23.9$  months. This included a clinical examination, blood tests, CT of the abdomen, and chest radiography. Medical records and survival data were obtained for all patients.

### LE procedure

After general anesthesia patients were placed in a right semilateral decubitus position. Under preparing and draping in the usual sterile manner, the surgeon, the camera assistant, and the scrub nurse were positioned to the right side of the

patient, and the first assistant stood to the left side of the patient. A 12-mm balloon trocar (telescope route) was first inserted through an infraumbilical minilaparotomy wound and pneumoperitoneum (12 mmHg) was achieved by CO<sub>2</sub> insufflation. Under the laparoscopy-providing vision, three other trocars were inserted into the following locations: the epigastrium (5 mm) for the left hand of the surgeon; the midclavicular line below the costal arch (12 mm) for the right hand of the surgeon; the left flank (5 mm) for assistance (Fig. 1).

The gastrocolic ligament was divided for entrance to the pancreas using harmonic scalpel (Ethicon, Cincinnati, OH, USA) and electrocautery. Laparoscopic USG probe was used through a 12-mm trocar and applied directly to the anterior surface of the pancreas to confirm the location of the tumor and identify its relationship to the splenic vessels and main pancreatic duct. Pancreatic dissection was performed using harmonic scalpel and bleeding between tumor and normal parenchyma was controlled by a 5-mm bipolar electrocoagulation instrument (Ethicon).

The specimen was then placed in a LapBag (SJM, Paju, Korea) and removed through a minimally extended umbilical port incision. One closed suction drain was placed in the site of the enucleation.

### Statistical analysis

Data are presented as the mean  $\pm$  standard deviation. Comparisons among the groups were performed using the Mann-Whitney U test or chi-square test where appropriate. Statistical evaluation was performed using the SPSS ver. 14.0 (SPSS Inc., Chicago, IL, USA) program for Windows. A P-value less than 0.05 was considered statistically significant.

## RESULTS

During the study period, 11 patients underwent LE (Table 1). There were 10 women (91%) and 1 man (9%) with a mean age of  $43.1 \pm 11.9$  years, and the mean BMI was  $25.1 \pm 6.4$  kg/m<sup>2</sup>.

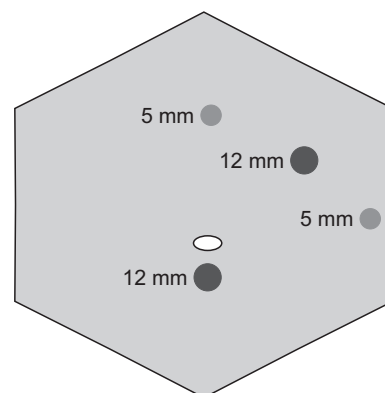


Fig. 1. Trocar placement for laparoscopic enucleation.

**Table 1.** Clinical feature and characteristics of the laparoscopic enucleation group

Case	Sex	Age (yr)	BMI (kg/m <sup>2</sup> )	Presentation	Pancreatitis	Preoperative diagnosis
1	M	35	23.3	Incidental finding	No	Mucinous cystic tumor
2	F	40	23.9	Incidental finding	No	Mucinous cystic tumor
3	F	36	22.5	Incidental finding	No	Mucinous cystic tumor
4	F	61	25.9	Incidental finding	No	Intraductal papillary mucinous neoplasm
5	F	61	26.3	Incidental finding	No	Intraductal papillary mucinous neoplasm
6	F	28	32.2	Incidental finding	No	Mucinous cystic tumor
7	F	32	24.2	Abdominal pain	No	Mucinous cystic tumor
8	F	29	23.5	Incidental finding	No	Mucinous cystic tumor
9	F	53	27.3	Abdominal pain	No	Intraductal papillary mucinous neoplasm
10	F	44	22.1	Incidental finding	No	Solid pseudopapillary neoplasm
11	F	55	24.2	Abdominal mass	No	Solid pseudopapillary neoplasm

BMI, body mass index.

**Table 2.** Pathologic summary and follow-up data of the laparoscopic enucleation group

Case	Location	Size (cm)	Final pathology	Complication	Status
1	Tail	2.2	Mucinous cystadenoma		NED at 78 months
2	Body	2.5	Serous cystadenoma		NED at 72 months
3	Tail	1.7	Serous cystadenoma		NED at 65 months
4	Tail	3.0	Mucinous cystadenoma		NED at 62 months
5	Body	3.2	Mucinous cystadenoma		NED at 62 months
6	Tail	1.3	Serous cystadenoma		NED at 50 months
7	Tail	12.5	Simple cyst		NED at 27 months
8	Body	1.2	Serous cystadenoma		NED at 26 months
9	Tail	8.5	Mucinous cystadenoma		NED at 22 months
10	Body	2.3	Castleman's disease		NED at 14 months
11	Body	5.8	Solid pseudopapillary neoplasm	Fistula	NED at 9 months

NED, no evidence of disease.

The most common presentation was incidental finding (n = 8, 73%), followed by abdominal pain (n = 2, 18%), and abdominal mass (n = 1, 9%). Also, there were no patients with preoperative pancreatitis. The tumors that had no symptoms (incidental finding) were detected by routine health checkup. All 11 patients who underwent LE were completed laparoscopically without conversion. In two patients (case 7 and case 9), cystic fluid was spilled during operation. The tumors were located in the body (n = 5, 45%) and tail (n = 6, 55%) of the pancreas. The mean operation time was 97.4 ± 16.6 minutes, and mean blood loss was 35.9 ± 11.9 mL. The final histopathological diagnoses included 4 mucinous cystadenomas, 4 serous cystadenomas, 1 solid pseudopapillary neoplasm (SPN), 1 simple cyst, and 1 Castleman disease. The mean diameter of the resected tumors was 4.0 ± 3.3 cm. One patient (9%) developed postoperative complication. This patient had pancreatic fistula and recovered with conservative management. The mean length of postoperative hospital stay was 5.5 ± 1.7 days, and the mean follow-up period was 44.3 ± 23.9 months. All of the patients are alive and disease-free (Table 2).

## DISCUSSION

With the introduction of newer sophisticated abdominal imaging techniques, benign or borderline pancreatic tumors such as pancreatic cystic neoplasms are being detected with increasing frequency [4]. Although most of these lesions are tumors benign in nature, they have malignant potential [3]. Thus, many surgeons have been performing major standard resections such as PD and DP with or without splenectomy [1]. Although these procedures can now be performed with low morbidity and mortality rates, resection of a large amount of normal pancreas can be associated with increasing risk of endocrine or exocrine insufficiency [2]. Especially, DP can induce diabetes when pancreatic resection exceeds 75% [1]. For these reasons, parenchyma-sparing procedures such as enucleation or central pancreatectomy have been performed with increasing frequency [1,3-6].

Enucleation of pancreatic tumors is a well established parenchyma-sparing and function-preserving surgical procedure for pancreatic lesions such as endocrine tumors, serous or

mucinous cystadenomas, and SPN [3-8]. Moreover, several reports documented the feasibility, safety, and effectiveness of LE in benign or borderline malignant pancreatic tumors [1,7,8]. The current study included 4 mucinous cystadenomas, 4 serous cystadenomas, 1 SPN, 1 simple cyst, and 1 Castleman disease. All 11 patients who underwent LE were completed laparoscopically without conversion and no recurrences were recorded after surgery. Although further evaluation should be conducted, our study shows that LE is a clinically safe and effective procedure for benign or borderline malignant pancreatic tumors.

Preoperatively and intraoperatively, the following factors should be considered for performing LE: localization of the tumor, malignancy potential of the tumor, distance between a lesion and the main pancreatic duct, and growing pattern of the tumor.

One of the most important concerns during LE is the localization of the tumor. With the advancement of preoperative imaging techniques and intraoperative localization with laparoscopic USG, open exploration with bimanual palpation of the pancreas may not be absolutely necessary [8]. Recent reports on the use of laparoscopic USG have shown a success rate of 80% to 100% in localizing and outlining the margins of pancreatic tumors [10,11]. In our study, laparoscopic USG was routinely performed and pancreatic lesions were localized in all 11 cases.

The malignant potency of pancreatic cystic tumors is another issue of concern. Preoperative noninvasive imaging techniques such as USG, CT, and MRI are unreliable to accurately distinguish among the different pancreatic cysts [4]. Recently, endoscopic ultrasound (EUS) guided fine-needle aspiration (FNA) has been suggested as a method to differentiate between benign and malignant lesions [3,4,12]. However, EUS guided FNA has the risk of malignant cell spillage into the peritoneum with subsequent seeding and reduced survival [4]. For these reasons, our institution does not recommend preoperative EUS guided FNA. Intraoperative frozen-section examination is an important method to obtain the information on the nature

of cystic mass [5]. So, in our institution, we routinely used frozen-section examination to clarify a preoperative confusing diagnosis.

The distance between a lesion and the main pancreatic duct has been considered to affect the risk of main duct damage and pancreatic leak [1,5,6]. Some authors suggested that, for enucleation to be performed safely, the lesion should be at least 2–3 mm from the main pancreatic duct and not too deep in the parenchyma [1,5]. Preoperative MRCP can measure the distance between a lesion and the main pancreatic duct and assists in the decision to perform enucleation. In the current study, MRCP was routinely performed and the patients were considered candidates for enucleation if their lesion did not involve the main pancreatic duct and had a pattern of growing outwardly with a small tumor bed.

Pancreatic fistula is the most serious complication in all pancreatic surgeries. The incidence of pancreatic fistula after open enucleation has been reported to range from 18.2% to 50% [3-6]. However, the reported incidence of pancreatic fistula after LE was lower (range, 9.1%–13%) than that reported after open enucleation [1,13]. Dedieu et al. [1] suggested that this improvement in pancreatic duct control could be explained by the slower and more meticulous pancreatic enucleation. In the current study, 1 patient (9%) had pancreatic fistula according to the definition of ISGPF, and this patient recovered with conservative management. This results in precise selection of patients, which includes a superficial lesion that does not involve the main pancreatic duct and has an outgrowing aspect with small tumor bed.

Short operation time, less blood loss, and more rapid recovery are often cited as the prominent advantages of enucleation [6]. Especially, extensive preservation of the normal pancreatic tissues is another merit of enucleation. Reported data show that pancreatic enucleation preserve pancreatic exocrine and endocrine function [5]. In our study, there was no evidence of new-onset exocrine and endocrine insufficiency. Also, when compared to LDP group (from July 2007 to February 2012, 41 patients underwent LDP in our institution for benign or

**Table 3.** Comparison of perioperative outcomes between LE and LDP group

Variable	LE (n = 11)	LDP (n = 41)	P-value
Operation time (min)	97.4 ± 16.6	194.6 ± 49.4	0.021
Blood loss (mL)	35.9 ± 11.9	272.7 ± 134.8	0.003
Time to first flatus (day)	2.2 ± 1.6	2.4 ± 0.5	0.515
Time to oral intake (day)	3.3 ± 1.8	3.4 ± 1.6	0.412
Postoperative hospital stay (day)	5.5 ± 1.7	9.4 ± 6.9	0.045
Pancreatic fistula	1 (9.1)	10 (22.4)	0.098
Mortality	0	0	NS
Recurrence rate (%)	0	0	NS

Values are presented as mean ± standard deviation or number (%).

LE, laparoscopic enucleation; LDP, laparoscopic distal pancreatectomy; NS, not significant.

borderline malignant tumor of the pancreas), the LE group had statistically significant shorter postoperative hospital stays with short operation time and less blood loss (Table 3).

In conclusion, the results of this study show that LE in patients with a benign or borderline malignant tumor of the pancreas is a safe and effective procedure. On the basis of our results and considering the general advantages of laparoscopic surgery, LE should be considered as a treatment option for benign or borderline malignant pancreatic lesions that do not involve the main pancreatic duct and have an outgrowing aspect with small tumor bed. But, our study has some limitations. It was a retrospective study and LE group was only 11 patients, which is relatively small. So, further evaluation, including

prospective randomized clinical trials are needed to confirm these results.

## CONFLICTS OF INTEREST

No potential conflict of interest relevant to this article was reported.

## ACKNOWLEDGEMENTS

This work was supported by Soonchunhyang University Research Fund. This work was supported by IN-SUNG Foundation for Medical Research.

## REFERENCES

1. Dedieu A, Rault A, Collet D, Masson B, Sa Cunha A. Laparoscopic enucleation of pancreatic neoplasm. *Surg Endosc* 2011;25:572-6.
2. Kahl S, Malfertheiner P. Exocrine and endocrine pancreatic insufficiency after pancreatic surgery. *Best Pract Res Clin Gastroenterol* 2004;18:947-55.
3. Talamini MA, Moesinger R, Yeo CJ, Poulouse B, Hruban RH, Cameron JL, et al. Cystadenomas of the pancreas: is enucleation an adequate operation? *Ann Surg* 1998;227:896-903.
4. Kiely JM, Nakeeb A, Komorowski RA, Wilson SD, Pitt HA. Cystic pancreatic neoplasms: enucleate or resect? *J Gastrointest Surg* 2003;7:890-7.
5. Crippa S, Bassi C, Salvia R, Falconi M, Butturini G, Pederzoli P. Enucleation of pancreatic neoplasms. *Br J Surg* 2007;94:1254-9.
6. Ge C, Luo X, Chen X, Guo K. Enucleation of pancreatic cystadenomas. *J Gastrointest Surg* 2010;14:141-7.
7. Fernandez-Cruz L, Blanco L, Cosa R, Rendon H. Is laparoscopic resection adequate in patients with neuroendocrine pancreatic tumors? *World J Surg* 2008; 32:904-17.
8. Singh N, Lo CY, Chan WF. Laparoscopic enucleation of a nonfunctioning neuroendocrine tumor at the head of the pancreas. *JSLs* 2006;10:259-62.
9. Bassi C, Dervenis C, Butturini G, Fingerhut A, Yeo C, Izbicki J, et al. Postoperative pancreatic fistula: an international study group (ISGPF) definition. *Surgery* 2005;138:8-13.
10. Iihara M, Kanbe M, Okamoto T, Ito Y, Obara T. Laparoscopic ultrasonography for resection of insulinomas. *Surgery* 2001;130:1086-91.
11. Lo CY, Chan WF, Lo CM, Fan ST, Tam PK. Surgical treatment of pancreatic insulinomas in the era of laparoscopy. *Surg Endosc* 2004;18:297-302.
12. Sand JA, Hyoty MK, Mattila J, Dagorn JC, Nordback IH. Clinical assessment compared with cyst fluid analysis in the differential diagnosis of cystic lesions in the pancreas. *Surgery* 1996;119:275-80.
13. Mabrut JY, Fernandez-Cruz L, Azagra JS, Bassi C, Delvaux G, Weerts J, et al. Laparoscopic pancreatic resection: results of a multicenter European study of 127 patients. *Surgery* 2005;137:597-605.