

Usefulness of C-stopper Coil for Neurointervention

Kentaro HAYASHI,¹ Nobutaka HORIE,¹ Minoru MORIKAWA,² and Izumi NAGATA¹

Departments of ¹Neurosurgery and ²Radiology, Nagasaki University School of Medicine, Nagasaki, Nagasaki

Abstract

C-stopper coil (CSC) which are available for 0.018-inch inner diameter microcenter have been used for neurointervention such as transarterial embolization (TAE) of feeding artery. Although various shapes of pushable microcoils have been developed, microcoils are usually short to embolize the lesion and require lots of coils. The most specific feature of CSC is the extended length of 18 cm. To evaluate the usefulness of CSC, we reviewed our experience of CSC. Neurointervention using CSC was performed for 28 patients (31 treatments). Intervention procedures were TAE for dural arteriovenous fistula (AVF) (n = 15), transvenous embolization for dural AVF (n = 4), parent artery occlusion for cerebral aneurysm, dissection and carotid-cavernous fistula (n = 8), TAE for epistaxis (n = 2), and preoperative embolization for tumor (n = 2). CSCs were deployed with push technique through microcatheter. CSCs were successfully placed into the lesion namely feeding artery, venous sinus, parent artery of aneurysm, or dissection. There were no major technical complications resulting in morbidity. Postoperative course was uneventful. No recanalization of the occluded vessel occurred during follow-up. Use of CSCs was safe and feasible for embolization of cerebrovascular lesion.

Key words: neurointervention, coil, embolization, transarterial embolization, transvenous embolization

Introduction

Various types of coils have been available for neurointervention.^{1–3)} According to the progression of the embolization materials, the indication of endovascular treatment has been widely spread.^{4–6)} Among embolization coils, detachable coils are employed for delicate lesion such as cerebral aneurysm.⁷⁾ Needless to say, the advantage of the detachable coils is retrieval when they do not fit for the lesion. However, detachable coils are expensive and embolization with detachable coils resulted in extremely high cost treatment.

Pushable microcoils are generally favored for occluding arteries and veins of the body over electrolytic detachable coils because of ease of use.^{8,9)} Additionally, the price of the pushable coils is approximately 10% of electrical detachable coil. Although many shapes of coils namely “Flat spiral”, “Complex”, “Vortex”, “Diamond” etc. are available, the extended length are relatively shorter and required lots of coils to achieve complete occlusion.¹⁰⁾ We have reported the usefulness of MicroNester® coil (Cook Medical, Bloomington, Indiana, USA), long

fibered coil for neurointervention¹¹⁾ and it was confirmed by another institute.¹²⁾

C-stopper coil (CSC; Solution, Yokohama, Kanagawa) is a kind of pushable coils (Fig. 1). It is bare platinum coil and flexible wave-shape that enables tight packing. Several lengths of coils (30 mm, 60 mm, 100 mm, 140 mm, 180 mm) are prepared. Employing longer coils, effective embolization is possible.¹³⁾ The aim of this study was to review our experience of CSC to treat cerebrovascular disease and assess the usefulness of CSC.

Materials and Methods

I. Patient demographics

From April 2009 to March 2012, 28 patients (12 female, 16 male; median age: 62.4 years; range 21 to 87) were treated by endovascular embolization using CSC. Totally 31 treatments were performed. The details of neurointervention were as follows: transarterial embolization (TAE) for dural arteriovenous fistula (AVF) (n = 15), transvenous embolization (TVE) for dural AVF (n = 4), parent artery occlusion for cerebral aneurysm, dissection and carotid-cavernous fistula (n = 8), TAE for epistaxis (n = 2), and preoperative embolization for tumor

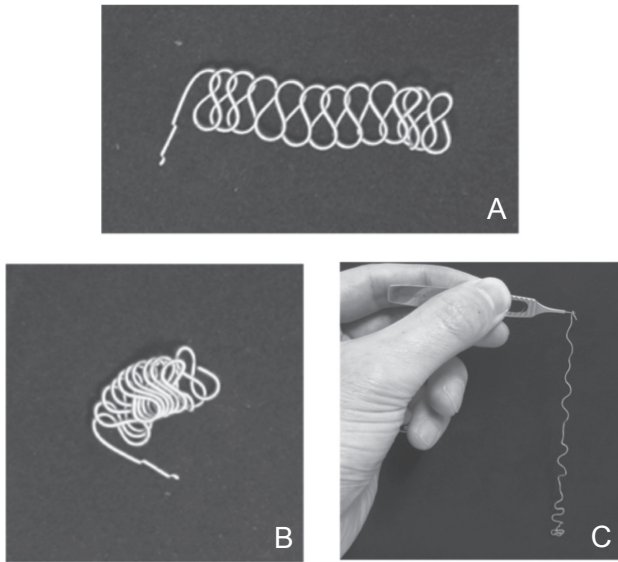


Fig. 1 Photograph of c-stopper coil (CSC). Without anchor type. **A:** Neutral status of CSC, **B:** Nest of CSC, **C:** Lifted CSC against gravity showing its softness.

($n = 2$). Patient selection for coil embolization was determined by a multidisciplinary fashion. The procedure with the highest possibility of success and the least risk to the patient was recommended.

II. Coil embolization procedure

The coil embolization procedures were usually performed under local anesthesia. All the procedures were performed on a biplane C-arm angiographic system with 3-dimensional reconstruction. Access was achieved via right femoral artery in TAE and right femoral vein in TVE. A 6-French guide catheter was placed in the carotid artery, vertebral artery, or internal jugular vein depending on the lesion location. A 6-French balloon-guide catheter was employed for parent artery occlusion to control luminal blood flow. After placing the guide catheter the patients were systemically heparinized, and activated clotting times were checked hourly. Using a coaxial technique, the 0.018-inch microcatheter was navigated into lesion over a micro guide wire. The fragile or important part of the lesion such as cerebral aneurysm or draining vein were embolized with detachable coils, then CNCs were deployed to the lesion by push technique. For the TAE of feeding artery, shorter fibered coils were placed and CSCs were employed, if necessary. A 180-mm length CSC was mainly used in this series. After successful deployment of coils, an angiographic image was obtained to check coil placement. Additional CNCs or standard microcoils were used until

obliteration of the lesion was achieved. After the treatment, patients were followed for 32 months (mean; range 15 to 51) neurologically and for 28 months (mean; range 12 to 42) radiologically. The recurrence of treated lesion was evaluated carefully.

Results

The summary of the patient's characteristics and treatments are listed in Table 1. CSCs were successfully placed into the lesion namely venous sinus (cavernous sinus; $n = 1$, transverse-sigmoid sinus; $n = 3$), feeding artery (occipital artery, superficial temporal artery, internal maxillary artery, middle meningeal artery, ascending pharyngeal artery; $n = 20$), and parent artery of aneurysm or dissection (internal carotid artery; $n = 5$, vertebral artery; $n = 2$). The number of CNCs employed was from 1 to 33 according to the lesion. Because better "nests" of CSCs was obtained by push technique rather than squirt technique, we employed only push technique in this series. The feeling of pushing CSCs was smooth comparing with that of fibered coils. Satisfactory obliteration of the lesion was achieved. No coil stuck in the microcatheter and no coil migration was observed during the procedure. No complication occurred related to CNC delivery. In one case of cavernous sinus dural AVF, abducens nerve palsy worsened temporary after the treatment. In another case of internal carotid artery dissection, hemiparesis due to the occlusion of the anterior choroidal artery occurred, that was not associated with CSCs placement. No recanalization of the occluded vessel occurred during follow-up.

Illustrative Cases

I. Case 15

A 62-year-old man presented with tinnitus due to anterior condylar confluence dural AVF fed by bilateral ascending pharyngeal artery (Fig. 2A). A microcatheter was advanced into distal portion of the left ascending pharyngeal artery and several shorter pushable fibered coils were inserted. Then, three CSCs were deployed from distal to proximal part. The CSCs migrated to the branch of the artery without handling of the microcatheter (Fig. 2B). The left ascending pharyngeal artery was embolized entirely (Fig. 2C, D). Subsequently, right occipital artery was embolized by using similar procedure. No complication occurred and his symptoms improved postoperatively.

Table 1 Summary of patients' characteristics and treatments including type of coils

Case	Age	Sex	Disease	Lesion	Treatment	DC	CSC	Other PC
1.	74	M	TS-SS dural AVF	Feeder	TAE	0	9	18
2.	74	F	TS-SS dural AVF	Feeder	TAE	0	4	13
3.	68	M	TS-SS dural AVF	Feeder	TAE	0	7	2
4.	68	M	TS-SS dural AVF	Feeder	TAE	1	6	0
5.	68	F	TS-SS dural AVF	Feeder	TAE	0	5	13
6.	85	M	TS-SS dural AVF	Feeder	TAE	0	3	6
7.	72	F	CS dural AVF	Feeder	TAE	0	10	10
8.	60	F	CS dural AVF	Feeder	TAE	0	2	8
9.	61	M	CS dural AVF	Feeder	TAE	0	1	19
10.	68	F	CS dural AVF	Feeder	TAE	0	2	11
11.	84	M	CS dural AVF	Feeder	TAE	0	2	21
12.	83	M	SSS dural AVF	Feeder	TAE	0	33	2
13.	62	M	SSS dural AVF	Feeder	TAE	6	6	9
14.	58	F	Tentorial dural AVF	Feeder	TAE	2	3	10
15.	62	M	ACC dural AVF	Feeder	TAE	0	7	14
16.	58	F	Meningioma	Feeder	TAE	0	5	2
17.	40	M	Cervical tumor	Feeder	TAE	1	2	9
18.	21	F	Epistaxis	Feeder	TAE	0	4	4
19.	58	M	Epistaxis	Feeder	TAE	0	4	5
20.	84	M	CS dural AVF	Sinus	TVE	2	5	0
21.	68	M	TS-SS dural AVF	Sinus	TVE	3	4	17
22.	74	M	TS-SS dural AVF	Sinus	TVE	1	3	18
23.	87	F	TS-SS dural AVF	Sinus	TVE	5	13	1
24.	57	F	ICA giant AN	Parent artery	PAO	3	2	52
25.	72	F	ICA giant AN	Parent artery	PAO	3	2	19
26.	73	F	ICA giant AN	Parent artery	PAO	6	1	12
27.	21	M	Traumatic CCF	Parent artery	PAO	6	3	10
28.	68	M	ICA dissection	Parent artery	PAO	1	12	20
29.	54	F	ICA dissection	Parent artery	PAO	7	5	0
30.	46	M	VA dissection	Parent artery	PAO	10	5	0
31.	45	F	VA dissection	Parent artery	PAO	9	6	0

ACC: anterior chondylar confluence, AN: aneurysm, AVF: arteriovenous fistula, CCF: carotid-cavernous fistula, CS: cavernous sinus, CSC: c-stopper coil, DC: detachable coil, F: female, ICA: internal carotid artery, M: male, PAO: parent artery occlusion, PC: pushable coil, SSS: superior sagittal sinus, TAE: transarterial embolization, TS-SS: transverse sinus-sigmoid sinus, TVE: transvenous embolization, VA: vertebral artery.

II. Case 20

An 84-year-old man presented with chemosis of the left eye and diplopia due to the left abducens nerve palsy. Angiography showed cavernous sinus dural AVF fed by meningeal branches of the left external carotid artery and the left internal carotid artery (Fig. 3A). The drainage routes were left superior and inferior ophthalmic vein. He underwent TAE

with some improvement of the symptom. Then, TVE was planned. A microcatheter was advanced into cavernous sinus through the left inferior petrosal sinus, and the left ophthalmic vein was initially embolized with detachable coils. In the anterior part of cavernous sinus including the shunting site, five CSCs were deployed by push technique. Complete occlusion of the lesion was confirmed on

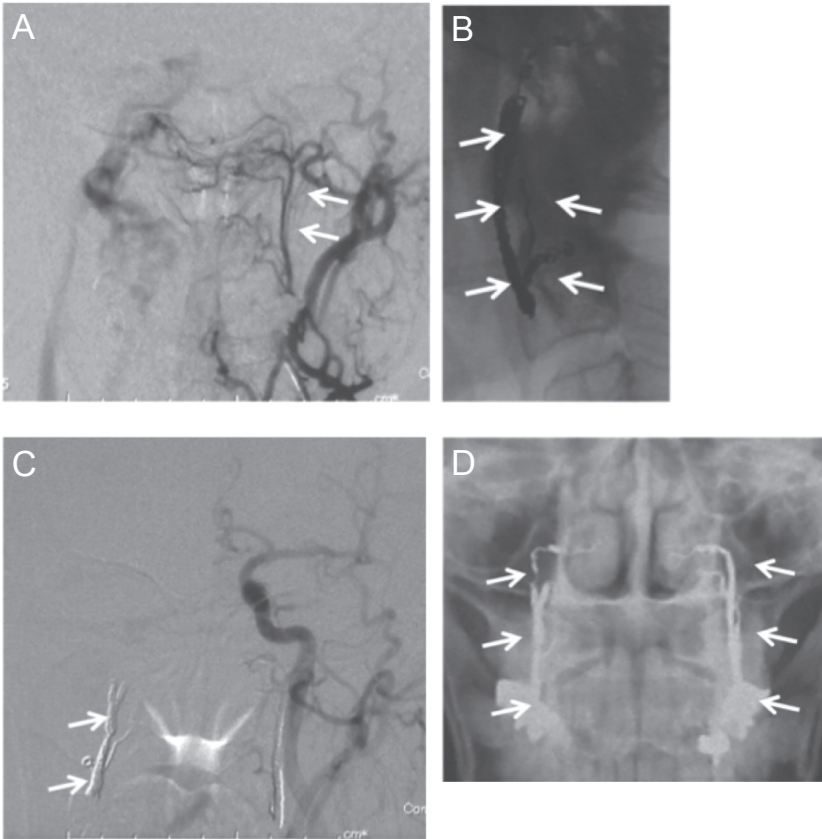


Fig. 2 A 62-year-old man with anterior condylar confluence dural AVF treated by transarterial embolization. **A:** Anterior-posterior view of left external carotid angiography showed anterior condylar confluence dural AVF fed by the left ascending pharyngeal artery (*arrow*), **B:** Lateral view of unsubtracted image during embolization. Three CSCs were placed to the left ascending pharyngeal artery (*arrow*), **C:** Postoperative control angiography showed CSCs (*arrow*) and obliteration of the dural AVF, **D:** Skull X-ray showing coil nest in the bilateral ascending pharyngeal arteries (*arrow*). AVF: arteriovenous fistula, CSC: c-stopper coil.

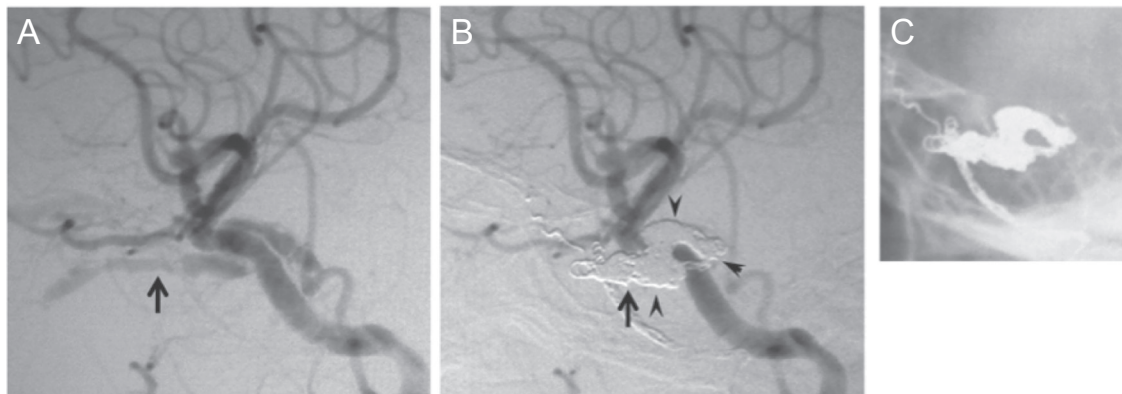


Fig. 3 An 84-year-old man with cavernous sinus dural arteriovenous fistula (AVF) underwent transvenous embolization. **A:** Lateral view of left common carotid angiography showed cavernous sinus dural AVF fed by meningeal branches of the left internal carotid artery. The drainage routes was right superior and inferior ophthalmic vein (*arrow*), **B:** Ophthalmic vein was embolized with detachable coils (*arrow*). At the shunting compartment of cavernous sinus, five c-stopper coils (CSCs) were deployed by push technique (*arrow head*). The dural AVF was completely obliterated, **C:** Skull X-ray showing the coil mass.

postprocedural angiography (Fig. 3B, C). Although left abducens nerve palsy worsened after the treatment, it disappeared 3 months later.

III. Case 23

An 87-year-old woman presented with sensory aphasia. Angiography revealed left transverse-sigmoid

sinus dural AVF with massive cortical reflux (Fig. 4A). Microcatheter was navigated to the vein of Labbe, which was the main cortical venous drainage. And it was first occluded with electrical detachable coil. Then, sigmoid sinus was packed with 13 CSCs and 1 fibered coil (Fig. 4B, C). Post-operative course was uneventful. And her sensory aphasia was improved.

Discussion

I. C-stopper coil

CSC, a 0.018-inch platinum coil with an extended length of 18 cm, permits tight packing (nesting) and immediate cross-sectional vessel occlusion due to its flexibility and wave-shape. The usefulness of CSC for visceral arteries has been reported.¹³⁾ The purpose of this report is to assess our first usage of this long microcoil to the cerebrovascular disease. In the thoracic or abdominal vessels embolization, anchor technique, placing a part of coil to the branch for fixation, and scaffold technique, placing coil to the formed cage, are introduced.^{14,15)} For anchor technique, specially designed CSC with whirlpool-shaped portion (diameter ranging from 3 mm to 7 mm) is available. The front portion of the whirlpool serves as a functional anchor while the soft wave-shaped portion is the actual occluder. However, first, detachable coils were used in neurointervention because accurate coil placement is required. Thus, the part of anchor is firm due to the coaxial inner coil; therefore, we used only CSCs without anchor portion. Several lengths of CSCs are prepared. A variety of fibered 0.018-inch platinum microcoils,

with varying diameters, are available from many manufacturers.¹⁶⁾ Among shorter coil, we tend to use fibered pushable coil because of its increased thrombogenesis as compared to bare platinum coil. That is why, we use only longer CSCs. CSCs were deployed to the lesion passing easily through microcatheters with 0.018-inch inner diameter. Thus, the use of a pusher wire to advance and deploy the CSC through the end hole while gently moving the microcatheter back and forth allowed tight packing in approximately 1–2 cm coil mass according to the vessel size. Satisfactory obliteration of the lesion was achieved and no complication occurred related to CSC embolization. Fewer coils are required in embolization with CNCs and that finally result in saving cost for the treatment. Needless to say, CSC is not retrieval and not suitable for intracranial lesion such as cerebral aneurysm.

II. Transarterial embolization

CSC was frequently employed in feeding artery embolization. Most of the detachable coils produced are suitable for embolization of cerebral aneurysm and not good for feeding artery embolization. In the TAE of dural AVF, the feeding artery should be embolized entirely because proximal occlusion induces recanalization due to the collateral flow from other arteries. Longer coil is effective to occlude long segment of vessels. Although tortuosity of feeding artery usually disturbs deployment of long coil, CSC preserves easy pushability through microcatheter. We have reported the usefulness of Micronester coil for neurointervention.¹¹⁾ However, the smallest diameter of the coil (4 mm) is still relatively large for some

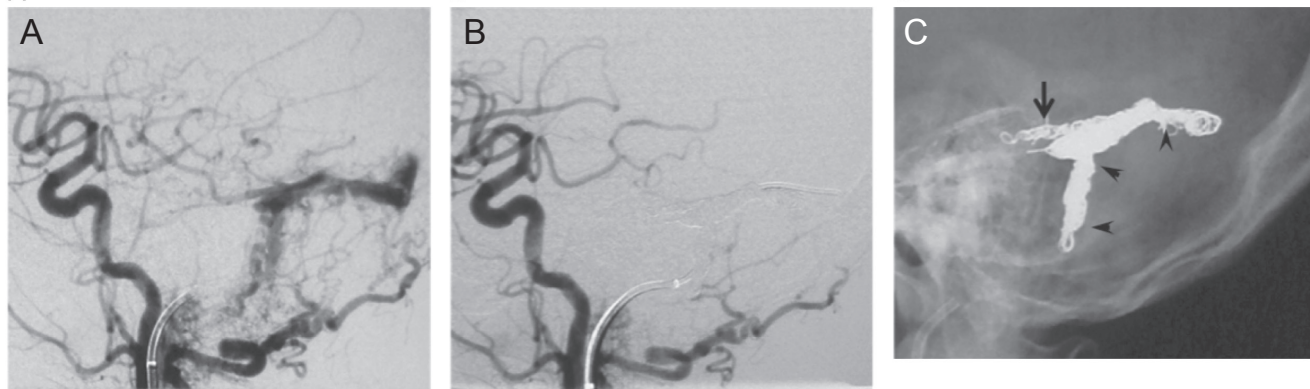


Fig. 4 An 87-year-old woman with left transverse-sigmoid sinus dural AVF underwent transvenous embolization. A: Lateral view of left common carotid angiography showed transverse-sigmoid sinus dural AVF fed by meningeal branches of the left occipital carotid artery. The drainage routes was vein of Labbe or other cortical vein, B: Vein of Labbe was embolized with detachable coils. Subsequently sinus packing was performed using 13 CSCs and one fibered coil. The dural AVF was completely obliterated, C: Skull X-ray showing detachable coils (*arrow*) and CSCs (*arrowhead*). AVF: arteriovenous fistula, CSC: c-stopper coil.

feeding artery such as ascending pharyngeal artery and middle meningeal artery. CSCs fit for almost all feeding arteries of head and neck. Thus, CSC seeks less resistant part such as branch of vessels without handling microcatheter, and resulted complete vessel occlusion including branch as shown in Fig. 2. In high-flow feeding artery, CSC may be placed beyond the tip of microcatheter according to its flexibility.

III. Transvenous embolization

The major target lesion of TVE was cavernous sinus and transverse to sigmoid sinus. Venous sinuses are large among cerebral vasculature and longer coils are preferable to fill the lesion. The over packing of cavernous sinus causes oculomotor nerve palsy or abducens nerve palsy. To avoid it, softer coil should be selected. CSC is flexible because of its unique shape. And it is considered that filling with CSC may be less stress to the vascular wall or surrounded structure. In this series, after TVE for cavernous sinus, abducens nerve palsy developed, which improved 3 months later. In case of transverse sinus or sigmoid sinus embolization, Micronester coil is a choice of coil since fragile structure such as cranial nerve does not exist. CSC is useful to fill the inside space of Micronester coil. The catheter tip may locate inside the nest of coil after placement of numbers of coils. To overcome this difficulty, a second marker is settled 3 cm from the tip of the pusher wire as delivery wire of detachable coil. Using two marker catheters, position of the pusher wire is recognized with relation to second markers.

IV. Parent artery occlusion

Detachable balloons were often used for parent artery occlusion until they were removed from the market in 2003. Since that time, coil embolization has replaced balloons. Occluding major artery requires a lot of coil due to its hemodynamics and may result in high cost. In this series, detachable coils were firstly placed to the aneurysm or dissection, which are fragile and have risk of rupture and pushable coils were secondary employed to the proximal portion. It is reported that in long-term follow up, recanalization occurs 5–10% of parent artery occlusion.¹¹⁾ We have here reported two cases on recanalization of internal carotid artery occlusion using fibered pushable coil.¹¹⁾ The high-flow or high-pressure of major artery is considered as a cause of the recanalization. According to these experiences, when we perform parent artery occlusion, microcatheter was advanced into the nest of long fibered coil and CSCs were added into the nest to achieve tight packing. As a result, recanalization has not occurred.

Conclusion

CSC was well compact in the artery or the vein, and showed sufficient clinical efficacy, ease of deployment, and good occlusive capability.

Conflicts of Interest Disclosure

All authors have no conflicts of interest. In addition, authors who are members of The Japan Neurosurgical Society state that all authors have registered online self-reported conflicts of interest disclosure statement forms through the website for The Japan Neurosurgical Society members.

Authors did not receive any support from the manufacture.

References

- 1) Bendszus M, Solymosi L: Cerecyte coils in the treatment of intracranial aneurysms: a preliminary clinical study. *AJNR Am J Neuroradiol* 27: 2053–2057, 2006
- 2) Halbach VV, Dowd CF, Higashida RT, Balousek PA, Urwin RW: Preliminary experience with an electrolytically detachable fibered coil. *AJNR Am J Neuroradiol* 19: 773–777, 1998
- 3) Yang PJ, Halbach VV, Higashida RT, Hieshima GB: Platinum wire: a new transvascular embolic agent. *AJNR Am J Neuroradiol* 9: 547–550, 1998
- 4) Khayata MH, Dean BL, Spetzler RF: Materials and embolic agents for endovascular treatment. *Neurosurg Clin N Am* 5: 475–484, 1994
- 5) Linfante I, Wakhloo AK: Brain aneurysms and arteriovenous malformations: advancements and emerging treatments in endovascular embolization. *Stroke* 38: 1411–1417, 2007
- 6) Molyneux AJ, Kerr RS, Yu LM, Clarke M, Sneade M, Yarnold JA, Sandercock P; International Subarachnoid Aneurysm Trial (ISAT) Collaborative Group: International subarachnoid aneurysm trial (ISAT) of neurosurgical clipping versus endovascular coiling in 2143 patients with ruptured intracranial aneurysms: a randomised comparison of effects on survival, dependency, seizures, rebleeding, subgroups, and aneurysm occlusion. *Lancet* 366: 809–817, 2005
- 7) Guglielmi G, Viñuela F, Sepetka I, Macellari V: Electrothrombosis of saccular aneurysms via endovascular approach. Part 1: Electrochemical basis, technique, and experimental results. *J Neurosurg* 75: 1–7, 1991
- 8) Jansen O, Dörfler A, Forsting M, Hartmann M, von Kummer R, Tronnier V, Sartor K: Endovascular therapy of arteriovenous fistulae with electrolytically detachable coils. *Neuroradiology* 41: 951–957, 1999

- 9) Tsai CW, Lin TH, Ko CT, Chen MF, Lee YT: Transcatheter embolization of a coronary arteriovenous fistula with a complex, helical-fibered platinum coil. *J Formos Med Assoc* 95: 558–561, 1996
 - 10) Dutton JA, Jackson JE, Hughes JM, Whyte MK, Peters AM, Ussov W, Allison DJ: Pulmonary arteriovenous malformations: results of treatment with coil embolization in 53 patients. *AJR Am J Roentgenol* 165: 1119–1125, 1995
 - 11) Hayashi K, Kitagawa N, Morikawa M, Hiu T, Morofuji Y, Suyama K, Nagata I: MicroNester coil for neurointervention. *J Neurosurg* 110: 40–43, 2009
 - 12) Daugherty WP, Kallmes DF, Cloft HJ, Lanzino GL: MicroNester coils as an adjunct to endovascular embolization. *World Neurosurg* 73: 390–394, 2010
 - 13) Irie T: New embolization microcoil consisting of firm and flexible segments: preliminary clinical experience. *Cardiovasc Intervent Radiol* 29: 986–990, 2006
 - 14) Guven K, Rozanes I, Ucar A, Poyanli A, Yanar H, Acunas B: Pushable springcoil embolization of pseudoaneurysms caused by gluteal stab injuries. *Eur J Radiol* 73: 391–395, 2010
 - 15) White RI: Pulmonary arteriovenous malformations: how do I embolize? *Tech Vasc Interv Radiol* 10: 283–290, 2007
 - 16) Barr JD, Lemley TJ: Endovascular arterial occlusion accomplished using microcoils deployed with and without proximal flow arrest: results in 19 patients. *AJNR Am J Neuroradiol* 20: 1452–1456, 1999
-

Address reprint requests to: Kentaro Hayashi, MD, Department of Neurosurgery, Nagasaki University School of Medicine, Sakamoto 1-7-1, Nagasaki, Nagasaki 852-8501, Japan.
e-mail: kenkuni@nagasaki-u.ac.jp