



Since January 2020 Elsevier has created a COVID-19 resource centre with free information in English and Mandarin on the novel coronavirus COVID-19. The COVID-19 resource centre is hosted on Elsevier Connect, the company's public news and information website.

Elsevier hereby grants permission to make all its COVID-19-related research that is available on the COVID-19 resource centre - including this research content - immediately available in PubMed Central and other publicly funded repositories, such as the WHO COVID database with rights for unrestricted research re-use and analyses in any form or by any means with acknowledgement of the original source. These permissions are granted for free by Elsevier for as long as the COVID-19 resource centre remains active.



IgM-enriched immunoglobulin in COVID-19: Case series of 15 severely ill SARS-CoV-2-infected patients

Payam Tabarsi^a, Seyed Mohammad Reza Hashemian^b, Artur Bauhofer^c, Ali Amir Savadkoobi^d, Somayeh Ghadimi^a, Sara Haseli^b, Farzaneh Dastan^{b,e,*}

^a Clinical Tuberculosis and Epidemiology Research Center, National Research Institute of Tuberculosis and Lung Diseases (NRITLD), Masih Daneshvari Hospital, Shahid Beheshti University of Medical Sciences, Tehran, Iran

^b Chronic Respiratory Diseases Research Center, National Research Institute of Tuberculosis and Lung Diseases (NRITLD), Shahid Beheshti University of Medical Sciences, Tehran, Iran

^c Corporate Medical Affairs, Biotest AG, Landsteinerstr. 5, 63303 Dreieich, Germany

^d Anesthesia and Critical Care Department, Chairman of Iranian Critical Care Society, Mehrad Hospital, Tehran, Iran

^e Department of Clinical Pharmacy, School of Pharmacy, Shahid Beheshti University of Medical Sciences, Tehran, Iran

ARTICLE INFO

Keywords:

SARS-CoV-2

COVID-19

IgM-enriched immunoglobulin

Hyperinflammation

Cytokine storm

Intravenous immunoglobulin (IVIG)

ABSTRACT

The healthcare system in Iran, like most around the world, is managing thousands of patients hospitalised with COVID-19. In Iran, in-hospital mortality is in the region of 25%, rising to 50–60% in patients admitted to intensive care. Hyperinflammation, characterised by cytokine storm, appears to be a hallmark of severe COVID-19 and to date only the anti-inflammatory drug dexamethasone has been shown to reduce mortality in those hospitalised with the disease.

There is a sound scientific rationale behind the use of IgM-enriched immunoglobulin in the management of patients with severe COVID-19. It has been used successfully in the management of hyperinflammation in patients with sepsis and has led to improved radiographic scores in patients with severe cases of severe acute respiratory syndrome coronavirus (SARS-CoV) infection. Recently the successful treatment of a patient with COVID-19 with IgM-enriched immunoglobulin was reported. Here we report the outcome of a further 15 patients hospitalised with COVID-19 treated with IgM-enriched immunoglobulin. Improvements in computed tomography (CT) score were observed in nine patients, indicating that further clinical studies into the use of IgM-enriched immunoglobulin in the treatment of severe COVID-19 are warranted.

1. Introduction

The world health organization (WHO) declared COVID-19 a ‘public health emergency of international concern’ on 30 January 2020 [1]. Since its aetiological agent, severe acute respiratory syndrome coronavirus 2 (SARS-CoV-2), was identified, COVID-19 has been associated with the deaths of almost 3 million people around the world [2]. The disease itself has a highly variable clinical course. Although estimates are highly variable, in the general population as many as 75% of infected individuals are asymptomatic [3] but ~15% experience severe pneumonia, accompanied by multisystem failure, that can ultimately lead to death [4].

As the scientific and medical communities expand their understanding of SARS-CoV-2 infection and COVID-19, management

strategies continue to evolve. Several therapies have been applied in clinical settings, including supportive interventions, immunomodulatory agents, antiviral therapy and transfusion of convalescent plasma [5]. Few treatment options have been shown to confer a survival advantage, with the recent SOLIDARITY trial [6] reporting that remdesivir, along with hydroxychloroquine, lopinavir and interferon, had no impact on overall mortality, initiation of ventilation or duration of hospital stay.

The exception to this is the glucocorticoid dexamethasone, which has been shown to improve survival among COVID-19 patients receiving either invasive mechanical ventilation or oxygen [7,8]. Recent studies have shown that the addition of immune modulators, such as the interleukin 6 (IL-6) receptor antagonists tocilizumab or sarilumab, confers an additional survival advantage in critically ill patients [9,10].

* Corresponding author.

E-mail address: fzh.dastan@gmail.com (F. Dastan).

<https://doi.org/10.1016/j.intimp.2021.107998>

Received 3 June 2021; Received in revised form 15 July 2021; Accepted 17 July 2021

Available online 23 July 2021

1567-5769/© 2021 Published by Elsevier B.V.

The overreaction of the body's immune system and hyperinflammation, the so-called 'cytokine storm', is a characteristic feature of COVID-19 in severely affected patients. In these patients there are increased serum levels of inflammatory markers, such as C-reactive protein (CRP) and IL-6 [4]. This potentially fatal hyperinflammation provides a rationale for the use of IgM-enriched immunoglobulin in the treatment of patients infected with SARS-CoV-2. Sepsis patients in a state of hyperinflammation have derived benefit from treatment with IgM-enriched immunoglobulin. In addition to the prevention of hyperinflammatory responses by decreasing proinflammatory cytokines and increasing anti-inflammatory cytokines, IgM-enriched immunoglobulin has a number of mechanisms of action that suggest therapeutic potential in this disease, including phagocytosis of pathogens, neutralisation of bacterial endo- and exotoxins, and immunomodulation via interaction with complement factors [11]. In these patients, adjuvant polyclonal IgM has resulted in an improved clinical course [12], presumably through support of physiological immune defence. In addition, IgM-enriched immunoglobulin, containing 12% IgM, 12% IgA and 76% IgG antibodies against a variety of pathogens, may prevent secondary bacterial infections in COVID-19 patients. Bacterial co-infections and secondary bacterial infections are increasingly observed in COVID-19 patients with severe disease [13,14].

Significant improvements in radiographic scores were observed after IgM-enriched immunoglobulin treatment (Pentaglobin® [Biotest AG, Dreieich, Germany]) of patients with severe SARS-CoV in whom corticosteroid therapy was ineffective [15]. The value of IgM-enriched immunoglobulin in the management of hyperinflammatory septic conditions [11] and the uneventful recovery of the patients with severe SARS-CoV [15] may be considered sufficient reason to consider its use in patients infected with SARS-CoV-2 [16]. Accordingly, the successful treatment of a COVID-19 patient with IgM-enriched immunoglobulin (Pentaglobin®) has been reported [17]. The authors of the report concluded that their experience was compatible with the concept that the early use of intravenous immunoglobulins, such as IgM-enriched immunoglobulin, can slow down hyperinflammation and provide immunological support in COVID-19-related pneumonia. Here we add to this evidence by reporting the outcome of 15 patients with COVID-19-related pneumonia treated with IgM-enriched immunoglobulin in Iran.

2. Methods

2.1. Setting

The current study was conducted on adult COVID-19 patients between June and August 2020, at Masih Daneshvari Hospital, a university-affiliated and selected referral centre for COVID-19 in Tehran, Iran.

2.2. Patients

Patients aged ≥ 18 years with reverse transcriptase polymerase chain reaction (RT-PCR)-confirmed COVID-19 satisfying the following criteria were recruited to the study: acute respiratory distress syndrome ($\text{PaO}_2/\text{FiO}_2 < 300$ mmHg); oxygen saturation $< 94\%$; deteriorating condition after 72 h despite national COVID-19- guideline-recommended medications; bilateral pulmonary infiltration; informed written consent (signed by the patient themselves or their legal representative). Patients with state 4/5 chronic kidney disease, decompensated liver disease (Child–Pugh C), known allergy to human immunoglobulins or a history of IgA deficiency were excluded.

The study was approved by the ethics committee of Shahid Beheshti University of Medical Sciences (ethics code number: IR.SBMU.NRITLD.REC.1399.014) and registered in the Iranian Registry of Clinical Trials with the registration number of IRCT20151227025726N18.

2.3. Intervention

Patients received 5 ml/kg/day Pentaglobin® for three consecutive days 72 h after admission if there were no clinical improvement despite of standard treatment with the standard and supportive care (oxygen therapy and anticoagulation) according to national guidelines for COVID-19.

Patients underwent spiral computed tomography (CT) scanning without contrast on admission to hospital. CT scoring was performed by an expert radiologist with the score (range 0–25) defined as the sum of lung involvement (0: 0%, 1: $< 5\%$, 2: 5–25%, 3: 25–50%, 4: 50–75%, 5: $> 75\%$) of each lobe, including ground glass opacity, crazy paving and consolidation. Subsequent CT scans were performed based on clinical symptoms, with a final follow-up, which was performed after 4 weeks in patients who recovered.

Microbiological identification of SARS-CoV-2 infection was performed using RT-PCR to detect SARS-CoV-2 in clinical samples. Standard clinical and laboratory measurements were taken prior to IgM-enriched immunoglobulin administration and after the course of treatment, on Day 4.

The physicians' overall assessment of patient outcomes was performed after IgM-enriched immunoglobulin treatment and graded as follows: very much improved, improved, no change, worsened, very much worsened after evaluation of pre- and post-treatment lung CT scans.

3. Results

3.1. Patient characteristics

During May and June 2020, 15 patients with confirmed SARS-CoV-2 infection were treated with IgM-enriched immunoglobulin in Masih Daneshvari hospital in Iran. Their demographics and clinical characteristics are given in Table 1. All but two patients were receiving antiviral therapy and remained on this therapy throughout treatment with IgM-enriched immunoglobulin. All patients were receiving antibiotics and corticosteroids. In line with the inclusion criteria all patients had pneumonia and two-thirds had at least one other underlying condition

Table 1
Demographics and patient characteristics.

	Patients (N = 15)
Male sex, n (%)	8 (53.3)
Age, years, mean (SD)	54 (17.2)
Weight, kg, mean (SD)	81.9 (14.4)
Height, cm, mean (SD)	167.8 (9.8)
Blood group, n (%)	
A	6 (40.0)
B	3 (20.0)
AB	2 (13.3)
O	4 (26.7)
Treatment at study entry, n (%)	
Antivirals	13 (86.7)
Favipiravir	8 (53.3)
IFN- β	7 (46.7)
Hydroxychloroquine	1 (6.7)
Remdesivir	1 (6.7)
Antibiotics	15 (100)
Corticosteroids	15 (100)
Other (eg, tocilizumab)	6 (40.0)
Medical history	
Pneumonia, n (%)	15 (100)
Fever, n (%)	10 (67.7)
Underlying disease, n (%)	
With 1 underlying disease	9 (60.0)
With 2 underlying disease	6 (40.0)
Tachycardia or bradycardia*	7 (46.7)

IFN, interferon; SD, standard deviation; bpm, beats per minute.

* Tachycardia: > 200 bpm; bradycardia: < 80 bpm.

(Table 1). CT scores at admission ranged from 9 to 25. At the time of IgM-enriched immunoglobulin administration, five patients were on invasive mechanical ventilation in the intensive care unit (ICU).

3.2. Patient response to treatment and outcomes

All patients received IgM-enriched immunoglobulin at the recommended dose of 5 ml (0.25 g)/kg body weight daily on three consecutive days. Clinical and laboratory parameters before and after administration of IgM-enriched immunoglobulin are shown in Table 2. On Day 4 after treatment with IgM-enriched immunoglobulin, all clinical parameters remained stable.

As expected, immunoglobulin levels of all three classes (IgM, IgA and IgG) were increased after treatment with IgM-enriched immunoglobulin. Of note, CRP levels in five patients improved towards the normal range (Table 3).

Only seven patients had pre- and post-treatment data for the inflammatory marker IL-6. In these patients, pre-treatment values were between 3.9 and 17.8 pg/mL, largely in line with levels expected in healthy adults (5–15 pg/mL). The impact of treatment on these parameters was variable (data not shown). Minimum leucocyte counts ranged from 3.8 to 11.7 × 10³/μl and 3.9 to 19.6 × 10³/μl in patients pre- and post-IgM-enriched immunoglobulin, respectively, and were therefore largely within the normal range for healthy adults (4–11 × 10³/μl).

Five patients (33.3%) died (sepsis + multiorgan failure [Patient 3];

Table 2

Clinical and laboratory measurements before and after administration of IgM-enriched immunoglobulin.

	Before IgM-enriched immunoglobulin (Day 0; N = 15)	After IgM-enriched immunoglobulin (Day 4; N = 15)
Clinical parameters*		
Heart rate, bpm	79–99	72–93
SBP, mmHg	97–127	100–122
MAP, mmHg	77 – 82 ^a	76 – 87 ^c
Body temperature, °C	36.7–37.7	36.7–37.3
Respiratory rate, breaths/min	27–33	22–27
Mean arterial pH	7 ^a	7 ^a
Mean urinary excretion/24 h, mL	2070 ^b	2174 ^{a#}
Laboratory values, mean (SD)		
Serum creatinine, ^ψ mg/dL	1.2 (0.3)	1.1 (0.3)
Glucose, mg/dL	150.7 (56.1)	151.4 (75.9) ^c
CRP, mg/L	33.3 (20.8)	16.5 (21.3) ^f
Minimum leucocyte count, ×10 ³ /μL	7.5 (2.9) ^c	9.5 (4.3) ^g
Platelets, ×10 ³ /μL	210.1 (97.7)	211.8 (107.9) ^f
Haematocrit, ^ψ %	38.2 (4.4)	36.9 (4.1) ^g
IL-6, pg/mL	13.4 (6.7) ^a	10.7 (8.0) ^d
Immunoglobulins, mg/dL		
IgM	94.9 (27.4) ^d	157.0 (47.2) ^h
IgG	794.7 (311.7) ^e	888.4 (153.1) ⁱ
IgA	170.7 (21.4) ^d	220.1 (61.2) ^h

bpm, beats per minute; CRP, C-reactive protein; IL-6; interleukin 6; MAP, mean arterial blood pressure; SBP, systolic blood pressure; SD, standard deviation.

* Range of mean values, unless otherwise stated.

Includes one patient with urinary excretion of 400 ml/24 h.

^ψ Minimum values.

^a n = 13.

^b n = 10.

^c n = 14.

^d n = 7.

^e n = 6.

^f n = 11.

^g n = 12.

^h n = 8.

ⁱ n = 9.

Table 3

CRP levels (mg/L) in patients with pre- and post-treatment data.

Patient	Before IgM-enriched immunoglobulin (Day 0)	After IgM-enriched immunoglobulin (Day 4)
Patient 1	9	ND
Patient 2	33	6 [#]
Patient 3*	29	1 [#]
Patient 4	9	3
Patient 5	41	8 [#]
Patient 6	1	1
Patient 7*	45	1 [#]
Patient 8	25	ND
Patient 9	59	ND
Patient 10	47	32
Patient 11	66	66
*		
Patient 12	50	49
Patient 13	59	ND
*		
Patient 14	26	10 [#]
*		
Patient 15	1	5

Some individuals with values up to 10 mg/L remain in good health).

CRP, C-reactive protein; ND, no data.

* Patient died.

Patient improved towards normal CRP value (normal CRP in adults is 0.8–3.0 mg/L).

sepsis + shock [Patient 11]; sepsis + pulmonary thromboembolism [Patient 13]; respiratory failure [Patient 14]; cardiac arrest [Patient 7]]. Four of these five patients had been on invasive mechanical ventilation at the time of IgM-enriched immunoglobulin administration. The five patients in ICU spent an average of 6.2 (2.0) days in ICU out of a mean total stay in hospital of 7.6 (4.1) days.

Patient outcome, assessed by the treating physician and based on comparison of CT scores before and 4 weeks after treatment with IgM-enriched immunoglobulin, improved in the remaining 9/10 patients ('very much improved', n = 5 [50.0%]; 'improved', n = 4 [40.0%]) and

Table 4

Lung CT scoring of patients (0–25).

Patient	Outcome	Score on admission	Last score in patients who died	Score after 4 weeks in patients who were discharged	Magnitude of change in patients who were discharged [#]
1	Discharged	13	–	2	1
2	Discharged	16	–	3	1
3	Died	24	24	–	–
4	Discharged	18	–	8	2
5	Discharged	18	–	8	2
6	Discharged	18	–	17	3
7	Died	24	ND	–	–
8	Discharged	10	–	0	2
9	Discharged	17	–	4	1
10	Discharged	15	–	6	2
11	Died	20	15	–	–
12	Discharged	25	–	5	1
13	Died	9	25	–	–
14	Died	16	22	–	–
15	Discharged	20	–	5	1

CT, computed tomography; ND, no data.

* In patients who died, the last CT scan was performed approximately 2–3 days prior to death as their condition worsened.

Change defined as percent improvement or progression: score on admission minus score after 4 weeks/25 × 100 and categorised as follows: 1, very much improved (>40% improvement in lung infiltration); 2, improved (11–40% improvement in lung infiltration); 3, no change (≤10% change in lung infiltration); 4, worse (11–40% progression in lung infiltration); 5, very much worse (>40% progression in lung infiltration).

they were able to be discharged (Table 4). Despite no apparent improvement in CT score Patient 6 was discharged with consent, for personal reasons. Representative CT scans from Patient 1 and Patient 2, before and after treatment with IgM-enriched immunoglobulin, are shown in Figs. 1 and 2, respectively. One of the patients who died (Patient 11) had shown an improvement in CT score (Table 4).

4. Discussion

The variable clinical presentation of patients with SARS-CoV-2 infection, and the unpredictable course of COVID-19, suggests that optimal management will vary between patients and that multiple treatment options will be required [18]. Dexamethasone has been shown to have a positive impact on mortality when used as monotherapy in some patient populations [7,8] and tocilizumab has been shown to confer a survival advantage in critically ill patients already receiving corticosteroids, including dexamethasone [10]. These therapies, together with the antiviral remdesivir, are the only interventions recommended currently in international guidelines for the management of patients hospitalised with COVID-19 [19].

Hyperinflammation, characterised by the ‘cytokine’ storm, is a feature of severe COVID-19. In addition to prevention of hyper-inflammatory responses by decreasing proinflammatory cytokines and increasing anti-inflammatory cytokines, IgM-enriched immunoglobulin has a number of mechanisms of action that suggest therapeutic potential in this disease, including phagocytosis of pathogens, neutralisation of bacterial endo- and exotoxins, and immunomodulation via interaction with complement factors [11]. In support of this, IgM-enriched immunoglobulin has improved the clinical course of patients with sepsis, especially those in a stage of hyperinflammation [11] and may reduce associated mortality [12]. In addition, experience of the use of IgM-enriched immunoglobulin in the treatment of SARS-CoV has been promising [15]. Together, this provides a sound rationale for the use of IgM-enriched immunoglobulin in patients with severe COVID-19.

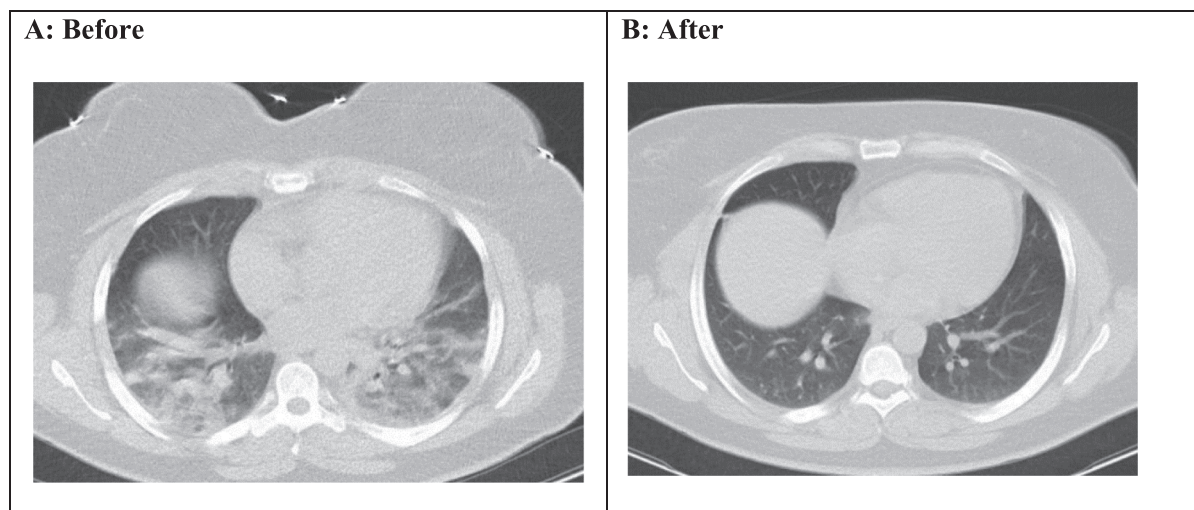
We treated 15 patients hospitalised with severe COVID-19 with the

recommended regimen of IgM-enriched immunoglobulin. In line with the recognised variable and unpredictable course of SARS-CoV-2 infection and COVID-19, the response to treatment varied between patients. Previous studies have reported in-hospital mortality rates in Iran in the region of 25% [20], rising to ~60% in intensive care [21]. In our study, 5/15 patients with severe COVID-19 died (33%), including 3/5 patients (60%) admitted to ICU.

In our study, overall assessment of response was based on lung CT scoring (0–25) and our results were largely consistent with the findings of Francone et al. [22] who demonstrated that, on multivariate analysis, patients with a lung CT score of ≥ 18 had an almost 4-fold increased risk of death versus those with lower scores. In our study, 4/5 patients who died had CT scores ≥ 18 at the last measurement. The last CT score in the fifth patient who died was 15. The study by Francone et al. also reported a significant correlation with CRP levels ($p < 0.001$; $r = 0.6625$). In our study, this correlation is unclear.

To our knowledge there is only one other case report in the literature of a patient with severe COVID-19 treated with IgM-enriched immunoglobulin [17]. The patient in this study was treated with the same treatment protocol as our current case series. Although this case report does not include data on lung CT scoring and CRP values were substantially lower than reported here, lung CT scans showed marked improvements 10 days after administration of IgM-enriched immunoglobulin, in line with observations reported in the discharged patients in our study.

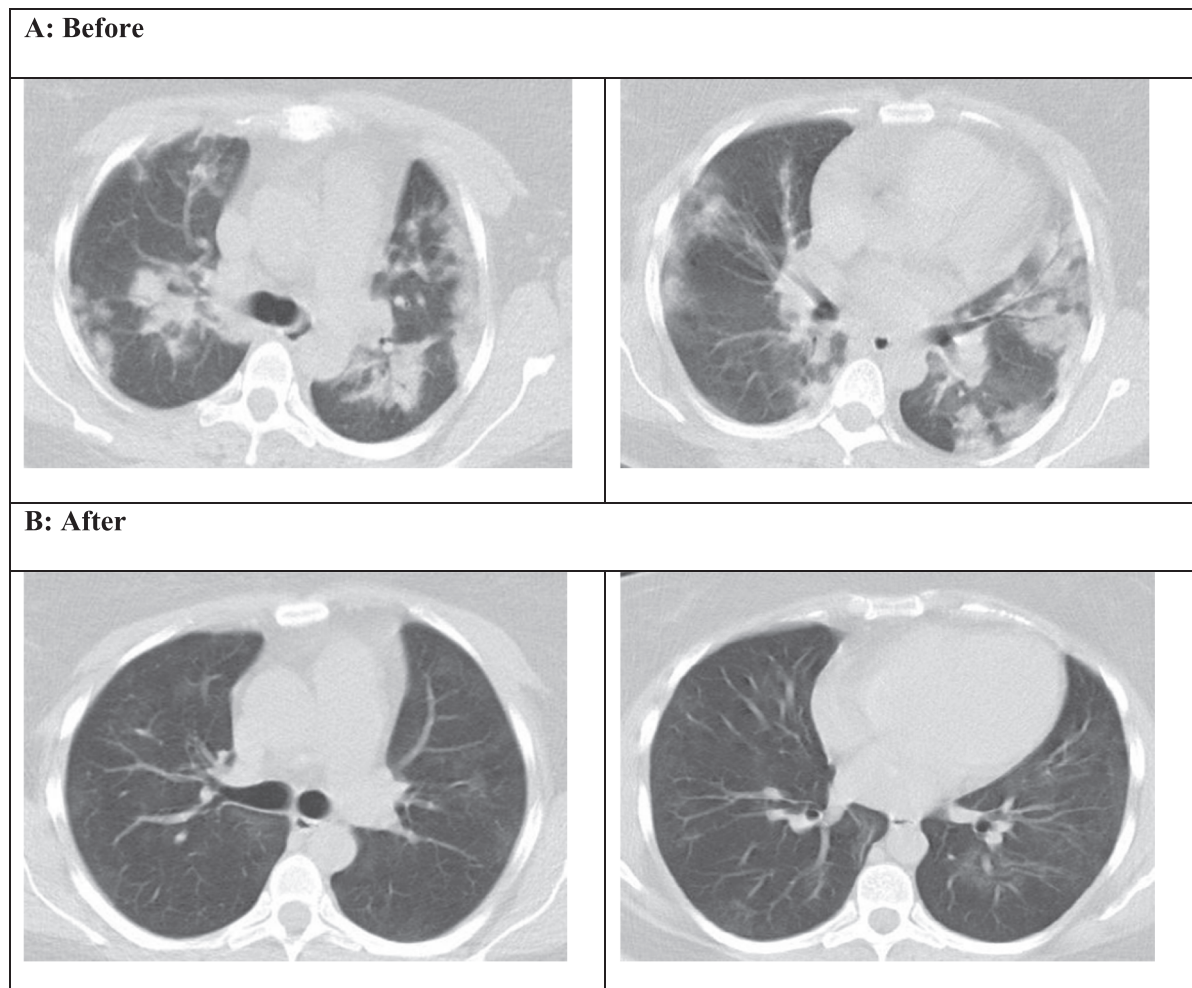
Our study has limitations associated with isolated case reports. Data are incomplete for several variables, including CT scans and CRP measurements. Although in patients with pre- and post-IgM-enriched immunoglobulin measurements CRP levels largely decreased, improving towards normal in five patients, two patients in whom decreases had been most dramatic died. Details of CRP levels at time of death are not available. In patients with data available, IL-6 levels were only increased marginally versus normal values prior to treatment with decreases of one order of magnitude observed in two patients after treatment. A lack of a control group is another limitation of the study



Panel A shows the CT scan of Patient 1, a 30-year-old woman with severe COVID-19-related pneumonia and severe hypoxia on admission (CT score: 13/25). Panel B shows a CT scan of the same patient performed 4 weeks later showing marked improvement (CT score: 2/25). This patient was designated ‘very much improved’ based on physician assessment.

CT, computed tomography

Fig. 1. Spiral lung CT scan without contrast of Patient 1 before (A) and after (B) treatment with IgM-enriched immunoglobulin. Panel A shows the CT scan of Patient 1, a 30-year-old woman with severe COVID-19-related pneumonia and severe hypoxia on admission (CT score: 13/25). Panel B shows a CT scan of the same patient performed 4 weeks later showing marked improvement (CT score: 2/25). This patient was designated ‘very much improved’ based on physician assessment. CT, computed tomography.



Panel A shows CT scans of Patient 2, a 37-year-old woman with severe/critical COVID-19 on admission (CT score: 16/25).

Panel B shows CT scans of the same patient performed 4 weeks later (Day 30 post-admission), showing resolution of previous ground-glass opacity and consolidation (CT score: 3/25). This patient was designated ‘very much improved’ based on physician assessment.

CT, computed tomography

Fig. 2. Spiral lung CT scans without contrast of Patient 2 before (A) and after (B) treatment with IgM-enriched immunoglobulin. Panel A shows CT scans of Patient 2, a 37-year-old woman with severe/critical COVID-19 on admission (CT score: 16/25). Panel B shows CT scans of the same patient performed 4 weeks later (Day 30 post-admission), showing resolution of previous ground-glass opacity and consolidation (CT score: 3/25). This patient was designated ‘very much improved’ based on physician assessment. CT, computed tomography. Side effects commonly associated with administration of IgM-enriched immunoglobulin, including haemolytic anaemia and kidney failure were not reported.

due to the shortage of the study medication and the ethical issues.

5. Conclusion

The administration of IgM-enriched immunoglobulin seems to have a beneficial effect on the hyperinflammation observed in some patients with COVID-19 and associated outcomes evidenced by improved CT scores, but results are variable. Its use in patients with SARS-CoV-2 infection warrants further investigation to evaluate the true impact of IgM-enriched immunoglobulin on the clinical course of COVID-19 and to ascertain whether there is a particular subpopulation of patients that are likely to derive most benefit from treatment.

6. Funding statement

This research did not receive any specific grant from funding agencies in the public, commercial, or not-for-profit sectors.

7. Availability of data and materials

The datasets used and/or analyzed during the current study are available from the corresponding author on reasonable request.

CRediT authorship contribution statement

Payam Tabarsi: Investigation, Project administration, Writing - review & editing. **Seyed Mohammad Reza Hashemian:** Investigation. **Artur Bauhofer:** Funding acquisition, Resources, Writing - review &

editing, Validation, Visualization, Formal analysis. **Ali Amir Savadkoochi**: Investigation. **Somayeh Ghadimi**: Investigation, Project administration, Writing - review & editing. **Sara Haseli**: Data curation, Methodology. **Farzaneh Dastan**: Conceptualization, Methodology, Investigation, Supervision, Project administration, Writing - review & editing, Data curation.

Declaration of Competing Interest

The authors declare the following financial interests/personal relationships which may be considered as potential competing interests: 'Dr Artur Bauhofer is an employee of Biotest AG. All other authors declare no conflict of interest'.

Acknowledgements

Writing support was provided by Julia Heagerty, PhD, of Obsidian Healthcare Group, and funded by Biotest AG.

References

- [1] WHO. Statement on the second meeting of the International Health Regulations (2005) Emergency Committee regarding the outbreak of novel coronavirus (2019-nCoV). Available at: [https://www.who.int/news/item/30-01-2020-statement-on-the-second-meeting-of-the-international-health-regulations-\(2005\)-emergency-committee-regarding-the-outbreak-of-novel-coronavirus-\(2019-ncov\)](https://www.who.int/news/item/30-01-2020-statement-on-the-second-meeting-of-the-international-health-regulations-(2005)-emergency-committee-regarding-the-outbreak-of-novel-coronavirus-(2019-ncov)). Accessed April 2021.
- [2] WHO coronavirus (COVID-19) dashboard. Available at: <https://covid19.who.int/>. Accessed April 2021.
- [3] M. Yanes-Lane, N. Winters, F. Fregonese, et al., Proportion of asymptomatic infection among COVID-19 positive persons and their transmission potential: a systematic review and meta-analysis, *PLoS One* 15 (2020), e0241536.
- [4] L.F. García, Immune response, inflammation, and the clinical spectrum of COVID-19, *Front. Immunol.* 11 (2020) 1441.
- [5] J.M. Sanders, L.M. Monogue, T. Jodlowski, et al., Pharmacologic treatments for coronavirus disease 2019 (COVID-19): a review, *JAMA* 323 (2020) 1824–1836.
- [6] WHO Solidarity Trial Consortium, Repurposed antiviral drugs for COVID-19 – interim WHO Solidarity trial results, *New Engl. J. Med.* 384 (2021) 497–511.
- [7] B.M. Tomazini, I.S. Maia, A.B. Cavalcanti, et al., Effect of dexamethasone on days alive and ventilator-free in patients with moderate or severe acute respiratory distress syndrome and COVID-19. The CoDEX randomized clinical trial, *JAMA* 324 (2020) 1307–1316.
- [8] RECOVERY Collaborative Group, Dexamethasone in Hospitalized Patients with COVID-19, *N. Engl. J. Med.* 384 (2021) 693–704.
- [9] The REMAP-CAP Investigators, Interleukin-6 receptor antagonists in critically ill patients with COVID-19 – preliminary report, *N. Engl. J. Med.* (2021), <https://doi.org/10.1056/NEJMoa2100433>. Epub ahead of print.
- [10] RECOVERY Collaborative Group. Tocilizumab in patients admitted to hospital with COVID-19 (RECOVERY): preliminary results of a randomised, controlled, open-label, platform trial. *Med Rxiv*. Available at: <https://www.medrxiv.org/content/10.1101/2021.02.11.21249258v1.full>. Accessed April 2021.
- [11] A. Nierhaus, G. Berlot, D. Kindgen-Milles, et al., Best-practice IgM- and IgA-enriched immunoglobulin use in patients with sepsis, *Ann. Intensive Care* 10 (2020) 132.
- [12] J. Cui, X. Wei, H. Lv, et al., The clinical efficacy of intravenous IgM-enriched immunoglobulin (pentaglobin) in sepsis or septic shock: a meta-analysis with trial sequential analysis, *Ann. Intensive Care* 9 (2019) 27.
- [13] M. Vaillancourt, P. Jorth, The unrecognized threat of secondary bacterial infections with COVID-19, *mBio* 4 (2020) e018-6-20.
- [14] M.J. Cox, N. Loman, D. Bogaert, et al., Co-infections: potentially lethal and unexplored in COVID-19, *Lancet Microbe* 1 (2020), e11.
- [15] J.C. Ho, A.Y. Wu, B. Lam, et al., Pentaglobin in steroid-resistant severe acute respiratory syndrome, *Int. J. Tuberc. Lung Dis.* 8 (2004) 1173–1179.
- [16] T. Alsuliman, L. Alasadi, B. Alkharat, et al., A review of potential treatments to date in COVID-19 patients according to the stage of the disease, *Curr. Res. Transl. Med.* 68 (2020) 93–104.
- [17] N. Carannante, G. Fiorentino, A. Corcione, et al., Administration of immunoglobulins in SARS-CoV2-positive patient is associated with fast clinical and radiological healing: case report, *Front. Med.* 7 (2020) 388.
- [18] J.H. Beigel, K.M. Tomashek, L.E. Dodd, et al., Remdesivir for the treatment of COVID-19—final report, *N. Engl. J. Med.* 2020 (383) (2020) 1813–1826.
- [19] NIH, Therapeutic management of adults with COVID-19. Available at: <https://www.covid19treatmentguidelines.nih.gov/therapeutic-management/>. Accessed April 2021.
- [20] M. Jalili, P. Payandemehr, A. Saghaei, et al., Characteristics and mortality of hospitalized patients with COVID-19 in Iran: a national retrospective cohort study, *Ann. Intern. Med.* 174 (2021) 125–127.
- [21] A. Zali, S. Gholamzadeh, G. Mohammadi, et al., Baseline characteristics and associated factors of mortality in COVID-19 patients; an analysis of 16000 cases in Tehran, Iran, *Arch. Acad. Emerg. Med.* 8 (2020), e70.
- [22] M. Francone, F. Iafrate, G. Maria Masci, et al., Chest CT score in COVID-19 patients: correlation with disease severity and short-term prognosis, *Eur. Radiol.* (2020), <https://doi.org/10.1007/s00330-020-07033-y>. Epub ahead of print.