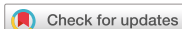

Review Article



Multidisciplinary perspectives on newly revised 2018 FIGO staging of cancer of the cervix uteri

Jonathan S. Berek ¹, Koji Matsuo ^{2,3}, Brendan H. Grubbs ⁴, David K. Gaffney ⁵,
Susanna I. Lee ⁶, Aoife Kilcoyne ⁶, Gi Jeong Cheon ⁷, Chong Woo Yoo ⁸,
Lu Li ^{9,10}, Yifeng Shao ¹¹, Tianhui Chen ¹², Miseon Kim ¹³, Mikio Mikami ¹⁴

OPEN ACCESS

Received: Dec 23, 2018

Accepted: Dec 23, 2018

Correspondence to

Mikio Mikami

Department of Obstetrics and Gynecology,
Tokai University School of Medicine, 143
Shimokasuya, Isehara, Kanagawa 259-1193,
Japan.

E-mail: mmikami@is.icc.u-tokai.ac.jp

Copyright © 2019. Asian Society of
Gynecologic Oncology, Korean Society of
Gynecologic Oncology

This is an Open Access article distributed
under the terms of the Creative Commons
Attribution Non-Commercial License ([https://
creativecommons.org/licenses/by-nc/4.0/](https://creativecommons.org/licenses/by-nc/4.0/))
which permits unrestricted non-commercial
use, distribution, and reproduction in any
medium, provided the original work is properly
cited.

ORCID iDs

Jonathan S. Berek
<https://orcid.org/0000-0002-8734-1961>
Koji Matsuo
<https://orcid.org/0000-0002-6232-8701>
Brendan H. Grubbs
<https://orcid.org/0000-0002-1963-4922>
David K. Gaffney
<https://orcid.org/0000-0002-5752-1611>
Susanna I. Lee
<https://orcid.org/0000-0003-2195-2943>
Aoife Kilcoyne
<https://orcid.org/0000-0002-9278-170X>
Gi Jeong Cheon
<https://orcid.org/0000-0002-1360-5186>
Chong Woo Yoo
<https://orcid.org/0000-0002-5221-4516>
Lu Li
<https://orcid.org/0000-0002-9746-050X>

¹Stanford Women's Cancer Center, Stanford Cancer Institute, Stanford University School of Medicine, Stanford, CA, USA

²Division of Gynecologic Oncology, Department of Obstetrics and Gynecology, University of Southern California, Los Angeles, CA, USA

³Norris Comprehensive Cancer Center, University of Southern California, Los Angeles, CA, USA

⁴Division of Maternal-Fetal Medicine, Department of Obstetrics and Gynecology, University of Southern California, Los Angeles, CA, USA

⁵Department of Radiation Oncology, Huntsman Cancer Hospital, University of Utah, Salt Lake City, UT, USA

⁶Department of Radiology, Massachusetts General Hospital, Harvard Medical School, Boston, MA, USA

⁷Department of Nuclear Medicine, Seoul National University College of Medicine, Seoul, Korea

⁸Department of Pathology, National Cancer Center, Goyang, Korea

⁹College of Basic Medical Sciences, Zhejiang Chinese Medical University (ZCMU), Hangzhou, China

¹⁰Department of Obstetrics & Gynaecology, The Chinese University of Hong Kong, Hong Kong, China

¹¹Department of Obstetrics and Gynecology, 1st affiliated hospital, Zhejiang Chinese Medical University, Hangzhou, China

¹²Group of Molecular Epidemiology & Cancer Precision Prevention (GMECPP), Zhejiang Academy of Medical Sciences (ZJAMS), Hangzhou, China


¹³Department of Obstetrics and Gynecology, CHA Gangnam Medical Center, CHA University School of Medicine, Seoul, Korea

¹⁴Department of Obstetrics and Gynecology, Tokai University School of Medicine, Kanagawa, Japan

Recent developments in imaging technology, radiotherapeutic approaches, biological target therapy, and increased use of minimally invasive surgery have drastically changed the paradigm for management of women with cervical cancer. Until now, the International Federation of Gynecology and Obstetrics (FIGO) staging system was based primarily on clinical examination with limited additional diagnostic procedures allowed by the FIGO staging system. In 2018, the prior 2014 FIGO staging system was revised to incorporate imaging and pathological findings, when available, into the new staging system (Table 1) [1]. Multidisciplinary perspectives on newly revised 2018 FIGO staging of cancer of the cervix uteri are discussed by gynecologic oncologists, radiation oncologists, radiologists, pathologists, and epidemiologists in this manuscript (Table 2).

GYNECOLOGIC ONCOLOGISTS' PERSPECTIVES: FOR WHOM THIS PLATFORM IS?

One of the major changes from the prior FIGO staging system is that the updated staging system now includes 3 subgroups for stage IB disease rather than 2. In the former system, stage IB disease was defined as (1) clinically and macroscopically visible lesions limited to the uterine cervix, or (2) microscopic lesions greater in size than stage IA disease. Tumors measuring less than or equal to 4 cm were classified as stage IB1, while those greater than

Yifeng Shao 
<https://orcid.org/0000-0002-7981-7042>

 Tianhui Chen 
<https://orcid.org/0000-0003-4677-0361>

 Miseon Kim 
<https://orcid.org/0000-0002-5118-9275>

 Mikio Mikami 
<https://orcid.org/0000-0002-7496-3518>

Conflict of Interest

No potential conflict of interest relevant to this article was reported.

Author Contributions

Project administration: M.K.; Supervision: J.S.B., M.M.; Writing - original draft: J.S.B., K.M., B.H.G., D.K.G., S.I.L., A.K., G.J.C., C.W.Y., L.L., Y.S., T.C., M.M.; Writing - review & editing: J.S.B., K.M., D.K.G., S.I.L., G.J.C., C.W.Y., T.C., M.M.

Table 1. FIGO staging of cancer of the cervix uteri (2018) [1]

Stage	Description
I	The carcinoma is strictly confined to the cervix (extension to the uterine corpus should be disregarded)
IA	Invasive carcinoma that can be diagnosed only by microscopy, with maximum depth of invasion <5 mm*
IA1	Measured stromal invasion <3 mm in depth
IA2	Measured stromal invasion ≥3 mm and <5 mm in depth
IB	Invasive carcinoma with measured deepest invasion ≥5 mm (greater than stage IA), lesion limited to the cervix uteri†
IB1	Invasive carcinoma ≥5 mm depth of stromal invasion, and <2 cm in greatest dimension
IB2	Invasive carcinoma ≥2 cm and <4 cm in greatest dimension
IB3	Invasive carcinoma ≥4 cm in greatest dimension
II	The carcinoma invades beyond the uterus, but has not extended onto the lower third of the vagina or to the pelvic wall
IIA	Involvement limited to the upper two-thirds of the vagina without parametrial involvement
IIA1	Invasive carcinoma <4 cm in greatest dimension
IIA2	Invasive carcinoma ≥4 cm in greatest dimension
IIIB	With parametrial involvement but not up to the pelvic wall
III	The carcinoma involves the lower third of the vagina and/or extends to the pelvic wall and/or causes hydronephrosis or nonfunctioning kidney and/or involves pelvic and/or para-aortic LNs‡
IIIA	The carcinoma involves the lower third of the vagina, with no extension to the pelvic wall
IIIB	Extension to the pelvic wall and/or hydronephrosis or nonfunctioning kidney (unless known to be due to another cause)
IIIC	Involvement of pelvic and/or para-aortic LNs, irrespective of tumor size and extent (with r and p notations)‡
IIIC1	Pelvic LN metastasis only
IIIC2	Para-aortic LN metastasis
IV	The carcinoma has extended beyond the true pelvis or has involved (biopsy proven) the mucosa of the bladder or rectum. (a bullous edema, as such, does not permit a case to be allotted to stage IV)
IVA	Spread to adjacent pelvic organs
IVB	Spread to distant organs

When in doubt, the lower staging should be assigned.

FIGO, International Federation of Gynecology and Obstetrics; LN, lymph node.

*Imaging and pathology can be used, where available, to supplement clinical findings with respect to tumor size and extent, in all stages; †The involvement of vascular/lymphatic spaces does not change the staging. The lateral extent of the lesion is no longer considered; ‡Adding notation of r (imaging) and p (pathology) to indicate the findings that are used to allocate the case to stage IIIC. Example: If imaging indicates pelvic LN metastasis, the stage allocation would be stage IIIC1r, and if confirmed by pathologic findings, it would be stage IIIC1p. The type of imaging modality or pathology technique used should always be documented.

Table 2. Brief summary of every standpoint on the revised FIGO 2018 stage of cervical cancer

Area of field	Description
Gynecologic oncologists	Distinct characteristics and outcomes of each substage IB1 (<2 cm) and IB2 (2 to <4 cm) justify 2018 staging revision. Prognostic value of LN metastasis, with considering metastasis at para-aortic nodes (IIIC2) separate from pelvic node only (IIIC1) and extrapelvic distant metastasis (IV), is incorporated. Stage IIIC disease is a heterogeneous entity, and local tumor factors remain the primary determinant of survival.
Radiation oncologists	Breaking previous stage IB into 3, not 2, by size criteria and introducing new category of stage IIIC will improve triaging patients between surgery and radiotherapy.
Radiologists	MRI is recommended for measuring tumor size more accurately than CT or physical examination and may be useful for evaluating parametrial involvement in some patients. PET-CT is allowed to denote the stage with the expected advantage of detecting para-aortic lymph node and distant whole body metastases.
Pathologists	Omission of horizontal dimension in stage IA might result in neglecting superficial spreading tumor with possibility of extension to upper vagina.
Epidemiologists	Epidemiological study of the revised staging system with applying pooled national dataset is required to have the correct and valuable judgment and guidance.

CT, computed tomography; FIGO, International Federation of Gynecology and Obstetrics; LN, lymph node; MRI, magnetic resonance imaging; PET, positron emission tomography.

4 cm were classified as stage IB2. In the revised system, substages for stage IB disease increase every 2 cm increments in tumor size: stage IB1 (<2 cm), stage IB2 disease (2 cm to <4 cm), and stage IB3 (\geq 4 cm). Previously designated stage IB1 disease is now further subdivided into 2 groups in the new staging system. Notably, tumor size of >4 cm was staged as IB2 in the former system, and tumor size \geq 4 cm is stage IB3 in the updated system.

Based upon a recent validation analyses of Matsuo et al. [2] using the National Cancer Institute's Surveillance, Epidemiology, and End Results (SEER) program between 1988–2014, the revised FIGO staging system for cervical cancer is useful to distinguish survival groups. Applying the new system, stage IB1 and stage IB2 disease have distinct characteristics and outcomes, e.g., stage IB1 disease is more likely to be low-grade, and have adenocarcinoma histology, whereas stage IB2 disease is more likely to be high-grade and have squamous histology. Patients with stage IB2 disease are more likely to undergo pelvic lymphadenectomy and radical hysterectomy, while women with stage IB1 disease are less likely to have received postoperative radiotherapy. Additionally, patients with stage IB2 disease have a nearly 2-fold increased risk of cervical cancer death compared to those with stage IB1 disease. Based on this new classification, risk-stratification will be very useful when applied to the treatment algorithm for tumors less than 4 cm.

There are several key clinical implications of the FIGO 2018 staging. Fertility-sparing trachelectomy is an acceptable operation for stage IB1 disease, but not stage for IB2 disease as per the National Comprehensive Cancer Network guidelines [3]. Minimally-invasive radical hysterectomy is associated with poorer survival compared to the laparotomy approach in stage IB1–IB2 disease, although stage IB3 disease with tumor size larger than 4 cm was not examined in their studies [4,5]. Subanalyses of their study indicate that stage IB1 disease may not have inferior survival with a minimally-invasive approach.

It will be essential to avoid miscommunication between care providers when applying the new staging system, particularly when referring to stage IB2 disease (>4 cm in the 2014 system vs. 2 to <4 cm in the 2018 system). Until the new FIGO staging criteria are widely recognized, it would be useful to specify tumor size when reporting the FIGO stage (e.g., stage IB2, 2 cm or IB3, 4 cm).

Another major change in the current staging system is incorporation of lymph node (LN) status into stage III disease. Patients who have documented pelvic and/or para-aortic LN metastasis are specifically designated as stage IIIC. Under the revised system, radiographic and/or histological findings are allowed to assign stage IIIC disease. Stage IIIC1 is designated when only pelvic LN metastasis is detected, while stage IIIC2 is designated when para-aortic LN metastasis is documented by either method. Matsuo et al. [2] performed a validation analysis of this new system for classification of stage III disease by utilization of the SEER database. In stage III disease, survival of women with stage IIIC1 disease is greater for those patients with stage IIIA or stage IIIB disease. The analysis showed 5-year cervical cancer-specific survival rates of 46.0% for stage IIIA disease, 42.6% for stage IIIB disease, and 62.1% for stage IIIC1 disease. It is essential to note that stage IIIC1 disease reflects a heterogeneous group of tumors with a wide range of survivals based on local tumor factors: 5-year cervical cancer-specific survival rates were 74.8% for T1, 58.7% for T2, and 39.3% for T3 with a 35.3% difference in absolute survival. Stage IIIC1 cervical cancer is not a single disease entity, and local tumor factors remain the primary determinant of survival. Nishio et al. [6] showed that the prognosis of women with cervical cancer with extra-pelvic metastasis varies based on

metastatic sites outside of the pelvis. Specifically, outcomes for metastatic cervical cancer solely in the para-aortic LNs are superior when compared to cervical cancer metastasized to other extra-pelvic sites. This implies the necessity of distinguishing para-aortic LN metastasis from other metastasis, which is reflected in the 2018 staging system.

RADIATION ONCOLOGISTS' PERSPECTIVES

The addition of a new category in stage IB disease will improve triaging patients between surgery and radiotherapy. Patients with large stage IB tumors are best managed with chemoradiotherapy, and dual-modality therapy is discouraged in patients with cervical cancer [1]. In a trial by Landoni et al. [7] dual modality therapy was required in 54% of patients who had tumors ≤ 4 cm, and 84% of those with tumors > 4 cm. This was associated with greater morbidity resulted compared with surgery or radiotherapy alone [7]. Patients with positive para-aortic nodes are typically managed with concurrent chemoradiotherapy, and these patients would be staged as stage IIIC2 in the new system. One study demonstrates greater than 35% disease-specific survival in this population [8]. Some patients with supraclavicular-only LN metastasis have been shown to achieve long-term disease-free survival. Recent data indicate that some patients who receive external beam radiotherapy and chemotherapy for limited oligo-metastatic disease may also have a prolonged disease-free survival [9].

RADIOLOGISTS' PERSPECTIVES: ADVANCED IMAGING ACQUIRES REPRESENTATION

Prior versions of the FIGO staging system that preceded the current one has included imaging exams: radiographs of the chest and skeleton, intravenous urography and barium enema [10]. These modality choices reflected the demographic reality that nearly 85% of invasive cervical cancer is diagnosed in low resource settings, where advanced imaging techniques such as computed tomography (CT), magnetic resonance imaging (MRI) and positron emission tomography (PET)-CT are unavailable or financially out of reach. However, the former staging systems have been inaccurate, with understaging of 20%–40% of stages IB–IIIB cancers, and overstaging of up to 64% of IIIB cancers [11]. Moreover, the older systems did not account for LN metastases, an important prognostic factor and determinant in treatment planning [12]. Given these limitations, ^{18}F -fluorodeoxyglucose (FDG) PET-CT that allows for noninvasive nodal assessment and pelvic MRI, that accurately depicts the primary tumor, have been readily adopted for cervical cancer management in regions of the world where these technologies are available [13,14]. This pretreatment imaging spares many women with locoregionally advanced cervical cancer the toxic combination of surgery followed by chemoradiotherapy, and instead triages them to one or the other curative and far less morbid treatment options [15]. The overall long-term quality of life for the patient is better and the cost is lower.

The new 2018 FIGO staging system for cervical cancer is notable because advanced imaging is now explicitly allowed to denote the stage [16]. For diagnosis of LN metastases, PET-CT is more sensitive than CT alone, especially for LNs in the para-aortic stations (**Table 3**) [17]. CT and MRI demonstrate comparable but lower sensitivities [18]. PET-CT can often detect metastasis in normal size LNs, because PET-CT images provide metabolic and anatomic

Table 3. PET-CT compared to CT for the detection of LN metastases in cervical cancer

Diagnostic performance	PET-CT	CT	p-value
Abdomen			
Sensitivity	0.50 (CI, 0.44–0.56) 0.45–0.55	0.42 (CI, 0.36–0.48) 0.33–0.48	0.052
Specificity	0.85 (CI, 0.80–0.89) 0.75–0.90	0.89 (CI, 0.84–0.92) 0.832–0.95	0.210
Pelvis			
Sensitivity	0.83 (CI, 0.78–0.87) 0.65–0.90	0.79 (CI, 0.73–0.83) 0.71–0.84	0.150
Specificity	0.63 (CI, 0.54–0.70) 0.54–0.73	0.62 (CI, 0.53–0.69) 0.38–0.73	0.830

Adapted and modified from Atri et al. [17]

CI, confidence interval; CT, computed tomography; LN, lymph node; PET, positron emission tomography.

information. Prognostically, a meta-analysis showed that positive pelvic and para-aortic LNs detected on FDG-PET were associated with higher risk of adverse events or death [19]. Nevertheless, CT and MRI represent reasonable choices when PET-CT is unavailable. Because the range of sensitivities for these imaging modalities is 40%–80%, improvements are still needed. However, the diagnostic performance is still sufficient to spare many women an unnecessary lymphadenectomy. Aside from nodal evaluation, PET-CT has the added advantage of whole-body staging. Unsuspected distant metastasis is detected with PET-CT in 14% of patients with locoregionally advanced cervical cancer (i.e., IB2 tumors, IIA tumors >4 cm, IIB–IVA tumors) [20]. In these patients, subsequent therapy can be customized to be less toxic [21].

More accurate measurement of tumor size is another feature introduced in the 2018 staging system. An additional tumor size cut-off of less than 2 cm has been introduced with imaging and pathological measurements allowed for this assessment. MRI is recommended for measuring tumor size, as it is more accurate than CT or physical exam [22]. If MRI is unavailable, ultrasound (US) using an endovaginal probe is the alternative but lacks the field-of-view to evaluate for lymphadenopathy [23]. For the assessment of tumor extension into the parametria, MRI and US are similar in their accuracy. For the majority of women worldwide diagnosed with cervical cancer, advanced imaging is often unavailable; but for women in developed countries, whole body PET-CT and pelvic MRI will enable more accurate staging, permitting more tailored treatment that has the potential to be less morbid and more curative.

PATHOLOGISTS' PERSPECTIVES

Cancer staging of uterine cervix has been based traditionally on clinical information, but the new staging officially adopts radiological and pathological findings to improve evidence-based decisions. Although omitting the horizontal dimension in stage IA is generally accepted, an issue that needs to be evaluated is the superficial spreading tumor with possibility of extension to upper vagina. While the new size criterion of 2 cm in greatest dimension divides previous IB1 tumor into 2 groups, the accurate measurement of tumor size may be challenging because sometimes it is unclear how much of the cervix is actually invasive disease, but this should improve by using pathological measurements when available [24]. Hopefully, the emphasis on the use of imaging to measure the tumor size will lead to improved radiological criteria.

EPIDEMIOLOGISTS' PERSPECTIVES

In the modified staging system, the additional factors will greatly increase the digital and image data during diagnosis, treatment, and follow-up. When these data are used as factors or standard criteria for diagnosis and guidance for treatment, they need to be accurately analyzed and evaluated, which is essential for epidemiological study and statistical analysis. Because of the variegated levels of resources around the world, it is challenging to collect reliable data, especially in developing countries. Variables that can limit reliable data assessment include variations in image quality, economic and resource issues, storage issues, and the management and sharing of graphic and text information.

In order to better apply cancer epidemiology to the updated staging system, we recommend a prospective epidemiological study that systematically and comprehensively applies pooled national datasets, period analysis, and regional evaluation based on different countries and continents [25-27].

CONCLUSION

The updated FIGO staging system for invasive cervical cancer incorporates imaging and pathological findings. Stage IB disease now includes 3 subgroups with substages every 2 cm increments in tumor size: stage IB1 (<2 cm), stage IB2 disease (2 to <4 cm), and stage IB3 (≥ 4 cm). The revised staging system incorporates LN status into stage III disease, allowing either radiographic or pathological findings of metastasis to the pelvic and/or para-aortic LNs to assign stage IIIC disease. Those patients with documented LN metastasis are designated as stage IIIC1 for patients who have pelvic LN metastasis only, and stage IIIC2 for those who have para-aortic LN metastasis. The hope is that these revisions will improve the accuracy of staging and this will be reflected a more refined understanding of prognostic groups, which will facilitate better treatment for women with invasive cervical cancer.

REFERENCES

1. Bhatla N, Aoki D, Sharma DN, Sankaranarayanan R. Cancer of the cervix uteri. *Int J Gynaecol Obstet* 2018;143 Suppl 2:22-36.
[PUBMED](#) | [CROSSREF](#)
2. Matsuo K, Machida H, Mandelbaum RS, Konishi I, Mikami M. Validation of the 2018 FIGO cervical cancer staging system. *Gynecol Oncol* Forthcoming 2018.
[PUBMED](#)
3. National Comprehensive Cancer Network. Cervical cancer [Internet]. Plymouth Meeting, PA: National Comprehensive Cancer Network; c2018 [cited 2018 Nov 6]. Available from: https://www.nccn.org/professionals/physician_gls/pdf/cervical.pdf.
4. Melamed A, Margul DJ, Chen L, Keating NL, Del Carmen MG, Yang J, et al. Survival after minimally invasive radical hysterectomy for early-stage cervical cancer. *N Engl J Med* 2018;379:1905-14.
[PUBMED](#) | [CROSSREF](#)
5. Ramirez PT, Frumovitz M, Pareja R, Lopez A, Vieira M, Ribeiro R, et al. Minimally invasive versus abdominal radical hysterectomy for cervical cancer. *N Engl J Med* 2018;379:1895-904.
[PUBMED](#) | [CROSSREF](#)
6. Nishio S, Matsuo K, Yonemoto K, Shimokawa M, Hosaka M, Kodama M, et al. Race and nodal disease status are prognostic factors in patients with stage IVB cervical cancer. *Oncotarget* 2018;9:32321-30.
[PUBMED](#) | [CROSSREF](#)

7. Landoni F, Maneo A, Colombo A, Placa F, Milani R, Perego P, et al. Randomised study of radical surgery versus radiotherapy for stage Ib–IIa cervical cancer. *Lancet* 1997;350:535-40.
[PUBMED](#) | [CROSSREF](#)
8. Kidd EA, Siegel BA, Dehdashti F, Rader JS, Mutch DG, Powell MA, et al. Lymph node staging by positron emission tomography in cervical cancer: relationship to prognosis. *J Clin Oncol* 2010;28:2108-13.
[PUBMED](#) | [CROSSREF](#)
9. Zigelboim I, Taylor NP, Powell MA, Gibb RK, Rader JS, Mutch DG, et al. Outcomes in 24 selected patients with stage IVB cervical cancer and excellent performance status treated with radiotherapy and chemotherapy. *Radiat Med* 2006;24:625-30.
[PUBMED](#) | [CROSSREF](#)
10. FIGO Committee on Gynecologic Oncology. FIGO staging for carcinoma of the vulva, cervix, and corpus uteri. *Int J Gynaecol Obstet* 2014;125:97-8.
[PUBMED](#) | [CROSSREF](#)
11. Amendola MA, Hricak H, Mitchell DG, Snyder B, Chi DS, Long HJ 3rd, et al. Utilization of diagnostic studies in the pretreatment evaluation of invasive cervical cancer in the United States: results of intergroup protocol ACRIN 6651/GOG 183. *J Clin Oncol* 2005;23:7454-9.
[PUBMED](#) | [CROSSREF](#)
12. Grigsby PW, Siegel BA, Dehdashti F. Lymph node staging by positron emission tomography in patients with carcinoma of the cervix. *J Clin Oncol* 2001;19:3745-9.
[PUBMED](#) | [CROSSREF](#)
13. Balleyguier C, Sala E, Da Cunha T, Bergman A, Brkljacic B, Danza F, et al. Staging of uterine cervical cancer with MRI: guidelines of the European Society of Urogenital Radiology. *Eur Radiol* 2011;21:1102-10.
[PUBMED](#) | [CROSSREF](#)
14. Siegel CL, Andreotti RF, Cardenes HR, Brown DL, Gaffney DK, Horowitz NS, et al. ACR Appropriateness Criteria® pretreatment planning of invasive cancer of the cervix. *J Am Coll Radiol* 2012;9:395-402.
[PUBMED](#) | [CROSSREF](#)
15. Pandharipande PV, Choy G, del Carmen MG, Gazelle GS, Russell AH, Lee SI. MRI and PET/CT for triaging stage IB clinically operable cervical cancer to appropriate therapy: decision analysis to assess patient outcomes. *AJR Am J Roentgenol* 2009;192:802-14.
[PUBMED](#) | [CROSSREF](#)
16. Bhatla N, Denny L. FIGO cancer report 2018. *Int J Gynaecol Obstet* 2018;143 Suppl 2:2-3.
[PUBMED](#) | [CROSSREF](#)
17. Atri M, Zhang Z, Dehdashti F, Lee SI, Ali S, Marques H, et al. Utility of PET-CT to evaluate retroperitoneal lymph node metastasis in advanced cervical cancer: results of ACRIN6671/GOG0233 trial. *Gynecol Oncol* 2016;142:413-9.
[PUBMED](#) | [CROSSREF](#)
18. Choi HJ, Ju W, Myung SK, Kim Y. Diagnostic performance of computer tomography, magnetic resonance imaging, and positron emission tomography or positron emission tomography/computer tomography for detection of metastatic lymph nodes in patients with cervical cancer: meta-analysis. *Cancer Sci* 2010;101:1471-9.
[PUBMED](#) | [CROSSREF](#)
19. Sarker A, Im HJ, Cheon GJ, Chung HH, Kang KW, Chung JK, et al. Prognostic implications of the SUVmax of primary tumors and metastatic lymph node measured by ¹⁸F-FDG PET in patients with uterine cervical cancer: a meta-analysis. *Clin Nucl Med* 2016;41:34-40.
[PUBMED](#) | [CROSSREF](#)
20. Gee MS, Atri M, Bandos AI, Mannel RS, Gold MA, Lee SI. Identification of distant metastatic disease in uterine cervical and endometrial cancers with FDG PET/CT: analysis from the ACRIN 6671/GOG 0233 multicenter trial. *Radiology* 2018;287:176-84.
[PUBMED](#) | [CROSSREF](#)
21. Ferlay J, Steliarova-Foucher E, Lortet-Tieulent J, Rosso S, Coebergh JW, Comber H, et al. Cancer incidence and mortality patterns in Europe: estimates for 40 countries in 2012. *Eur J Cancer* 2013;49:1374-403.
[PUBMED](#) | [CROSSREF](#)
22. Mitchell DG, Snyder B, Coakley F, Reinhold C, Thomas G, Amendola M, et al. Early invasive cervical cancer: tumor delineation by magnetic resonance imaging, computed tomography, and clinical examination, verified by pathologic results, in the ACRIN 6651/GOG 183 intergroup study. *J Clin Oncol* 2006;24:5687-94.
[PUBMED](#) | [CROSSREF](#)
23. Epstein E, Testa A, Gaurilcik A, Di Legge A, Ameye L, Atstupenaite V, et al. Early-stage cervical cancer: tumor delineation by magnetic resonance imaging and ultrasound - a European multicenter trial. *Gynecol Oncol* 2013;128:449-53.
[PUBMED](#) | [CROSSREF](#)

24. Harvey M. The size of the cervix and its relationship with age and parity. *Urogynaecol Int J* 2016;29:171-4.
[CROSSREF](#)
25. Bray F, Ferlay J, Soerjomataram I, Siegel RL, Torre LA, Jemal A. Global cancer statistics 2018: GLOBOCAN estimates of incidence and mortality worldwide for 36 cancers in 185 countries. *CA Cancer J Clin* 2018;68:394-424.
[PUBMED](#) | [CROSSREF](#)
26. Chen T, Jansen L, Gondos A, Emrich K, Hollecsek B, Luttmann S, et al. Survival of cervical cancer patients in Germany in the early 21st century: a period analysis by age, histology, and stage. *Acta Oncol* 2012;51:915-21.
[PUBMED](#) | [CROSSREF](#)
27. Jiang X, Tang H, Chen T. Epidemiology of gynecologic cancers in China. *J Gynecol Oncol* 2018;29:e7.
[PUBMED](#) | [CROSSREF](#)