

Case report

Prosthetic vascular graft infection and prosthetic joint infection caused by *Pseudomonas stutzeri*



Michael J. Bonares^a, Alon Vaisman^b, Abdu Sharkawy^{c,*}

^a Division of General Internal Medicine, Department of Medicine, University of Toronto, 190 Elizabeth Street, Toronto, ON M5G 2C4, Canada

^b Division of Infectious Diseases, Department of Medicine, University of Toronto, 200 Elizabeth Street, Toronto, ON M5G 2C4, Canada

^c Division of Infectious Diseases, Department of Medicine, University Health Network, 399 Bathurst Street, Toronto, ON M5T 2S8, Canada

ARTICLE INFO

Article history:

Received 20 October 2016

Received in revised form 22 October 2016

Accepted 26 October 2016

Keywords:

Prosthetic vascular graft infection

Prosthetic joint infection

Medical tourism

Hospital-acquired infection

ABSTRACT

Pseudomonas stutzeri is infrequently isolated from clinical specimens, and if isolated, more likely represents colonization or contamination rather than infection. Despite this, there are dozens of case reports which describe clinically significant *P. stutzeri* infections at variable sites. A 69-year-old man had a *P. stutzeri* infection of a prosthetic vascular graft infection, which he received in Panama City. He was successfully treated with a single antipseudomonal agent for 6 weeks and the removal of the infected vascular graft. A 70-year-old man had a *P. stutzeri* infection of a prosthetic joint, which was successfully treated with a single anti-pseudomonal agent for 6 weeks. There is only one other documented case of a prosthetic vascular graft infection secondary to *P. stutzeri*. There are 5 documented cases of *P. stutzeri* prosthetic joint infections. The previous cases were treated with antibiotics and variably, source control with the removal of prosthetic material. Most cases of *P. stutzeri* infection are due to exposure in health care settings. Immunocompromised states such as HIV or hematological and solid tumor malignancies are risk factors for *P. stutzeri* infection. Infections caused by *P. stutzeri* are far less frequent and less fatal than those caused by *P. aeruginosa*. The etiology of a *P. stutzeri* infection could be exposure to soil and water, but also contaminated material in the health care setting or an immunocompromised state. Iatrogenic infections that are secondary to health care tourism are a potential cause of fever in the returned traveler.

© 2016 Published by Elsevier Ltd. This is an open access article under the CC BY-NC-ND license (<http://creativecommons.org/licenses/by-nc-nd/4.0/>).

Introduction

Pseudomonas stutzeri, first discovered by Burri and Stutzer in 1895 [1], is an aerobic, flagellated, gram-negative bacterium that is non-lactose fermenting and oxidase-positive [2]. It is normally found in soil and water [2].

The organism is infrequently isolated from clinical specimens, and if isolated, more likely represents colonization or contamination rather than infection. For example, in a case series of 36 isolates of *P. stutzeri* from 1977 to 1993 in a Kentucky hospital, 33 were thought to be secondary to colonization or contamination [3].

The most recent case series of *P. stutzeri* reported 93 isolates from 2000 to 2010 in an Israeli hospital [4]. During the study period, incidence of isolation increased, with more than a third isolated during the last year of the study period. Despite this

increase, the frequency of its isolation was significantly exceeded by the 9971 isolates of other *Pseudomonas* species detected during the same period, the vast majority of which were *P. aeruginosa*. In the same study, *P. stutzeri* was most frequently isolated from urine (31%), wounds (28%), and blood (19%). Ten deaths (11%) occurred, of which 8 were attributable to a significant comorbidity rather than to the *P. stutzeri* infection itself. In contrast, *P. aeruginosa* bacteremia demonstrated a mortality rate of 39% [5].

Despite its rarity and low risk of mortality, there are dozens of case reports which describe clinically significant *P. stutzeri* infections at a variety of sites. We present here two such *P. stutzeri* infections – one of a prosthetic vascular graft and the other of a prosthetic joint.

Cases

Case 1: prosthetic vascular graft infection

A 69-year-old man with a past medical history significant for atrial fibrillation, asthma, and prior Dengue fever, presented to a Tropical Medicine Clinic in Toronto, Canada with a several-week

* Corresponding author.

E-mail addresses: Michael.Bonares@mail.utoronto.ca (M.J. Bonares), Alon.Vaisman@gmail.com (A. Vaisman), Abdu.Sharkawy@uhn.ca (A. Sharkawy).

history of fatigue and progressive left lower quadrant pain, in the context of having returned from Panama City, Panama about 8 weeks before. In Panama, he was found to have a left internal iliac artery aneurysm and thrombus which required insertion of a 15-cm arterial graft. Investigations for endemic infections, including malaria, typhoid fever, and Dengue fever, were negative. However, two of two blood cultures drawn on presentation were positive for *P. stutzeri* and he was therefore admitted to hospital for further management. Both *P. stutzeri* isolates were susceptible to ceftazidime, ciprofloxacin, gentamicin, piperacillin, and tobramycin, but resistant to trimethoprim-sulfamethoxazole. He was therefore given ceftazidime 2 g intravenously every 8 h as therapy for his bacteremia. CT angiography of his abdomen and pelvis demonstrated significant perigraft soft tissue density attenuation suspicious for infection (Fig. 1A).

He subsequently underwent surgical removal of the vascular graft, embolization of the left internal iliac artery, and insertion of a left to right femoral–femoral bypass graft. All three specimens collected intraoperatively grew *P. stutzeri* with the aforementioned sensitivity profile. A transthoracic echocardiogram demonstrated a 5 mm mobile echodensity on the ventricular side of the aortic valve; however, a transesophageal echocardiogram characterized the echodensity as a degenerative strand. He completed a total of 6 weeks of ceftazidime therapy. At a 6-week follow-up appointment in an Infectious Diseases clinic, there was no evidence of infection. A repeat CT of the abdomen and pelvis did not demonstrate any residual infection (Fig. 1B). A repeat transthoracic echocardiogram did not demonstrate the abovementioned echodensity and there was no significant aortic insufficiency.

Case 2: prosthetic joint infection

A 70-year-old man with a past medical history significant for atrial fibrillation, type 2 diabetes mellitus, and surgically treated renal cell carcinoma, suffered a right lower extremity fracture about 3 years before presentation. The fracture was initially treated with a tibio-talo-calcaneal fusion but was complicated by two hardware infections in the subsequent 2 years, the first of which did not yield a microbiological diagnosis and the second of which was due to coagulase-negative *Staphylococcus* (CNST), requiring hardware removal and prolonged courses of antimicrobial therapy.

About 3 months after his second infection, he experienced recurrent pain and drainage from the incision site. An X-ray of his right foot demonstrated hindfoot arthrodesis with fibular osteotomy. He underwent surgical irrigation and debridement of the infected tibial bone, insertion of a local bone graft, and revision of the previously performed fusions. Intra-operative cultures from

the tibia grew *P. stutzeri* sensitive to ceftazidime, ciprofloxacin, gentamicin, piperacillin, tobramycin, and trimethoprim-sulfamethoxazole. He was treated with ceftazidime 2 g intravenously every 8 h. He completed a total of 6 weeks of antimicrobial therapy and at a 2-month follow-up, his surgical site demonstrated evidence of healing without any sign of drainage or infection.

Discussion

We present here two rare cases of *P. stutzeri* prosthetic device infection in the setting of healthcare facility exposure. Although *P. stutzeri* is a saprophyte found in soil, groundwater, marine water, and salt marshes [2], most cases of *P. stutzeri* infection are due to exposure in health care settings. During the 1970s and 1980s, *P. stutzeri* caused several outbreaks in the health care setting as a consequence of environmental contamination. Namely, 3 cases of bacteremia were secondary to contaminated bottles of intravenous fluids [6]; 6 cases of bacteremia were secondary to contaminated deionized water that constituted the dialysate for hemodialysis [7]; and 24 cases of bacteremia were secondary to contaminated aqueous green soap used to prepare skin for intravenous insertions [8]. Thus it is plausible that our patient with a vascular graft infection acquired a *P. stutzeri* infection in an acute health care facility in Panama. Accordingly, it is important to not only consider endemic, but also nosocomial infections as a cause for fever in a returned traveler. This is especially important considering the increasing rates of health care tourism and expatriates seeking medical care outside of North America [9].

With respect to commonly cited risk factors for *P. stutzeri* infection, several case reports have been documented in patients with immunocompromised states such as HIV or hematological and solid tumor malignancies. For example, a recent report described a patient with Crohn's disease who developed *P. stutzeri* meningitis 10 days after the initiation of vedolizumab, a tumor necrosis factor antagonist [10]. Notably, our patient with a prosthetic joint infection had a history of renal cell carcinoma requiring nephrectomy 1 month prior to his admission and type 2 diabetes mellitus, both of which are known to confer an immunocompromised state. As well, this patient had a preceding CNST infection, which raises the possibility of the *P. stutzeri* infection opportunistically developing in the setting of previous broad spectrum antimicrobial treatment, as is often the case with *Pseudomonas aeruginosa* [11]. Additionally, a recent case of a necrotizing pneumonia caused by *P. stutzeri* developed in a patient with pulmonary tuberculosis [12] and was hypothesized to have been facilitated by parenchymal destruction caused by *Mycobacterium tuberculosis*. This supports the notion that *P. stutzeri*

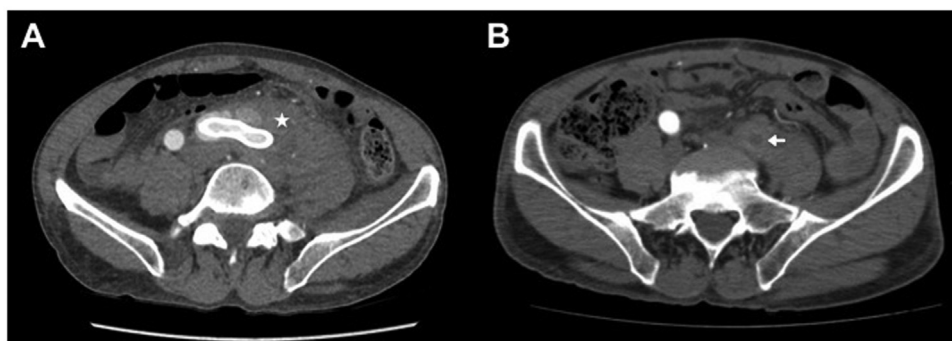


Fig. 1. CT angiography axial slices of the patient with the *Pseudomonas stutzeri* prosthetic left iliac artery graft infection. A. Image before removal of the graft, demonstrating retroperitoneal soft tissue inflammatory changes around the left common iliac prosthetic graft, with extension into the left psoas muscle (star). B. Image after removal of the graft, demonstrating marked reduction of the retroperitoneal inflammatory changes. There is interval thrombosis of the left common iliac artery (arrow).

infection may develop in previously inflamed or infected tissue, although no rigorous data investigating this hypothesis is available.

Our first case is only the second documented case of a prosthetic vascular graft infection secondary to *P. stutzeri*. The first was a 61-year-old woman who received an aorto-bifemoral vascular graft for an abdominal aortic aneurysm [13].

The possibility of infective endocarditis was raised in our patient due to the finding of a possible vegetation on his aortic valve on echocardiography, although he had a low pre-test probability of the disease. There are 2 previous case reports of infective endocarditis secondary to *P. stutzeri* [14,15]. In a patient with *P. stutzeri* bacteremia, we believe that echocardiography is appropriate in patients with risk factors for infective endocarditis. The decision to pursue echocardiography may be clinically significant as it would inform the duration of antimicrobial therapy in cases where shorter courses are sought, and may inform whether cardiac surgery should be pursued.

Our second case is also a rare example of *P. stutzeri* prosthetic joint infection. There are 5 documented cases of *P. stutzeri* joint infections [3,16–19], 3 of which were in native joints and 2 in prosthetic joints. Most of the cases had identifiable risk factors for a joint infection, including a foreign body (1), immunological deficiency (1), and anatomical abnormality (1). In each of two case series of 93 and 114 isolates, respectively, only 2 were from synovial fluid [4,20].

Treatments of the abovementioned *P. stutzeri* joint infections were variable with respect to the identity and duration of antimicrobials, and whether or not surgical intervention was pursued. Definitive therapy included one or a combination of 6 antimicrobials for a duration of 2 to 8 weeks. Of the 3 native joint infections, 1 was treated with surgical intervention (total hip arthroplasty). Of the 2 prosthetic joint infections, 1 was treated with surgical intervention (total hip arthroplasty). Despite the variability in treatment, outcomes were good for all cases, except one case with an infected left prosthetic hip joint treated with antimicrobials and total hip arthroplasty that presented with persistent purulent drainage from the wound. Although there is no literature systematically describing the treatment of joint infections secondary to *P. stutzeri*, ours and previous cases suggest that single anti-pseudomonal coverage is sufficient. The preferential choice of anti-pseudomonal agent is unknown, but should be compatible with the organism's sensitivity profile in addition to the patient's clinical profile, including allergies, kidney function, and QT interval. In prior cases, treatment durations were a minimum of 2 weeks.

Conclusion

Infections caused by *P. stutzeri* are far less frequent and less fatal than those caused by *P. aeruginosa*. However, this organism has been demonstrated to cause clinically significant infections at variable sites. Antimicrobial therapy with an anti-pseudomonal agent should be guided by sensitivity profiles on an individual case basis. Here, we presented two *P. stutzeri* infections, one of a prosthetic vascular graft and another of a prosthetic joint. Our case of *P. stutzeri* prosthetic vascular graft infection was successfully treated with a single anti-pseudomonal agent for 6 weeks and the removal of the infected vascular graft. Based on our and previous cases of *P. stutzeri* joint infections, a single anti-pseudomonal agent for at least 4–6 weeks is likely sufficient. When considering the source of a *P. stutzeri* infection, one should consider not only

exposure to soil and water, but also the importance of immunocompromised states and potentially contaminated material in the health care setting, as demonstrated by our presented cases. Finally, considering the growing trend of health care tourism and patients seeking care outside of North America, clinicians must be aware of this organism and its significant potential as a cause of fever in the returned traveler.

Consent

Written informed consent was obtained from the patients for publication of this case report and accompanying images. A copy of the written consent is available for review by the Editor-in-Chief of this journal on request.

Conflict of interest statement

None.

Acknowledgement

None.

References

- [1] Burri R, Stutzer A. Ueber Nitrat zerstörende Bakterien und den durch dieselben bedingten Stickstoffverlust. Zentralbl Bakteriol Parasitenkd Abt II 1895;1:257–65 350–364, 392–398, 422–432.
- [2] Lalucat J, Bannasar A, Bosch R, Garcia-Valdes E, Palleroni NJ. Biology of pseudomonas stutzeri. Microbiol Mol Biol Rev 2006;70(2):510–47.
- [3] Noble RC, Overman SB. Pseudomonas stutzeri infection. Diagn Microbiol Infect Dis. 1994;19:51–6.
- [4] Bisharat N, Gorlachev T, Keness Y. 10-Years hospital experience in pseudomonas stutzeri and literature review. TOIDJ 2012;6:21–4.
- [5] Kang C-I, Kim S-H, Kim H-B, Park S-W, Choe Y-J, Oh M-d, et al. Pseudomonas aeruginosa bacteremia: risk factors for mortality and influence of delayed receipt of effective antimicrobial therapy on clinical outcome. Clin Infect Dis 2003;37:745–51.
- [6] Felts SK, Schaffner W, Melly MA. Sepsis caused by contaminated intravenous fluids. Ann Intern Med 1972;77:881–90.
- [7] Goetz A, Yu VL, Hanchett JE, Rihs JD. Pseudomonas stutzeri bacteremia associated with hemodialysis. Arch Intern Med 1983;143:1909–12.
- [8] Keys TF, Melton LJ, Maker MD, Ilstrup DM. A suspected hospital outbreak of pseudobacteremia due to pseudomonas stutzeri. J Infect Dis 2010;147:489–93.
- [9] Nelson R. Infectious risks of medical tourism. Lancet Infect Dis 2014;14(8):680–1.
- [10] Boland BS, Dulai PS, Chang M, Sandborn WJ, Levesque BG. Pseudomonas meningitis during vedolizumab therapy for crohn's disease. Am J Gastroenterol 2015;110(11):1631–2.
- [11] Grandsen WR, Leibovici L, Eykyn SJ, Pitlik SD, Samra Z, Konisberger H, et al. Risk factors and a clinical index for diagnosis of Pseudomonas aeruginosa bacteremia. Eur Soc Clin Infect Dis 2007;1(2):119–23.
- [12] Lin K-H, Chen C-M, Wang J-H, Ho M-W. Pseudomonas stutzeri necrotizing pneumonia in pre-existing pulmonary tuberculosis. Intern Med 2014;53:2543–6, doi:http://dx.doi.org/10.2169/internalmedicine.53.2247.
- [13] George LJ, Cunha BA. Pseudomonas stutzeri synthetic vascular graft infection. Heart Lung 1990;19:203–5.
- [14] Grimaldi D, Podglajen I, Aubert A, Buu-Hoi A, Diebold B, Mainardi JL. Case of indolent endocarditis due to pseudomonas stutzeri with genetic evidence of relapse after 4 years. J Clin Microbiol 2009;47:503–4.
- [15] Rosenberg I, Leibovici L, Mor F, Block C, Wysesbeek AJ. Pseudomonas stutzeri causing late prosthetic valve endocarditis. J R Soc Med 1987;80:457–9.
- [16] Bishara J, Robenshtok E, Samra Z, Pitlik S. Prosthetic knee septic arthritis due to Pseudomonas stutzeri. Can J Infect Dis 2000;11:329–32.
- [17] Madhavan T. Septic arthritis with pseudomonas stutzeri. Ann Int Med 1974;80:67–71.
- [18] Miron D, Keness Y, Bor N, Spiegel R, Horowitz Y. Pseudomonas stutzeri knee arthritis in a child: case report and review. J Pediatr Orthop B 2007;16:419–21.
- [19] Thangkhiew I. Pseudomonas stutzeri infection of the hip joint. J Infect 1985;12:183–4.
- [20] Holmes B. Identification and distribution of Pseudomonas stutzeri in clinical material. J Appl Bacteriol 1986;60:401–11.