

Expression Profiles of Inflammatory Cytokines in the Aqueous Humor of Children after Congenital Cataract Extraction

Yinying Zhao¹, Xiaohui Deng¹, Pingjun Chang¹, Man Hu¹, Zhangliang Li¹, Fan Zhang¹, Xixia Ding¹, and Yune Zhao¹

¹The Eye Hospital of Wenzhou Medical University, Hangzhou, China

Correspondence: Yune Zhao, Eye Hospital of Wenzhou Medical University, 618 East Fengqi Road, Hangzhou, Zhejiang, 310000, China. e-mail: zye@mail.eye.ac.cn

Received: December 4, 2019

Accepted: April 21, 2020

Published: July 2, 2020

Keywords: aqueous humor; congenital cataract; immune mediators; aphakic; immunoassay; chemokine; cytokine; proinflammatory factors

Citation: Zhao Y, Deng X, Chang P, Hu M, Li Z, Zhang F, Ding X, Zhao Y. Expression profiles of inflammatory cytokines in the aqueous humor of children after congenital cataract extraction. *Trans Vis Sci Tech.* 2020;9(8):3. <https://doi.org/10.1167/tvst.9.8.3>

Purpose: To investigate the change in cytokine microenvironment of the aqueous humor (AH) after surgery in children with congenital or developmental cataracts.

Methods: AH samples were obtained from 59 eyes diagnosed with a congenital or developmental cataract. Thirty-three of these eyes were aphakic following previous cataract surgery and were scheduled for secondary intraocular lens (IOL) implantation. Additionally, AH samples from 26 eyes that had not undergone surgery were taken. AH samples were then analyzed for 16 different inflammatory immune mediators using multiplex bead immunoassays and enzyme-linked immunosorbent assay (ELISA).

Results: The mean interval between secondary IOL implantation and original cataract surgery was 24.85 months (range, 9–60 months). Levels of IL-6, IP-10 (CXCL10), MCP-1 (CCL2), and IL-2 were significantly elevated in the AH of eyes after surgery compared to eyes that did not undergo surgery ($P < 0.001$, $P = 0.047$, $P = 0.006$, $P = 0.012$, respectively). There was significant correlation between the levels of TGF- β 2 and intraocular pressure (IOP) in postsurgical and nonsurgical eyes ($r = 0.532$, $P = 0.006$; $r = 0.57$, $P = 0.001$). Postsurgical outcomes, such as iris adhesions, capsular fibrosis, and capsular contraction, were found not to be significantly associated with cytokine levels in the AH after surgery; however, IL-6 levels in capsular exposure eyes were significantly higher than those in cortical closure eyes ($P = 0.023$).

Conclusions: To our knowledge, this is the first study to report significantly increased proinflammatory cytokine levels in the AH after congenital cataract extraction in children. Our study also suggests that this proinflammatory state may be maintained for a prolonged period of time. Overall, these results give us insight into the relationship between the inflammatory cytokine microenvironment of the aqueous humor and potential long-term complications following congenital cataract surgery.

Translational Relevance: The inflammatory cytokine microenvironment of the aqueous humor might help explain potential long-term complications after surgery in patients with congenital or developmental cataracts.

Introduction

Congenital or developmental cataracts are a significant source of lifelong visual impairment in children.¹ Currently, cataract extraction surgery is the only effective treatment. Following cataract extraction, postoperative inflammation is inevitable, with the inflammatory response often more pronounced in young

children, particularly in infants. This increase in the incidence of inflammation is often accompanied by complications such as iris adhesion, capsular contraction, and secondary glaucoma, which often directly influence the outcome of a subsequent surgery. The reasons for variability in outcomes are not well understood; however, it has been observed in previous studies that the manner in which an infant's lens capsule and lens cortex behave were much different in a state

of inflammation.² In these studies, the inflammatory response after congenital cataract surgery was assessed only via clinical signs. To our knowledge, characteristic cytokine profiles have not been established in children after congenital cataract surgery, and thus the mechanisms underlying these events are not fully understood.

Several other studies have assessed the change of cytokine levels in the aqueous humor (AH) in ocular disease. Nishi et al.³ reported that IL-1 and IL-6 are produced in vivo by residual lens epithelial cells (LECs), causing postoperative inflammation and LEC proliferation. The expression level of IL-6 has also been shown to be significantly higher in the AH of patients after cataract surgery compared to the AH of normal patients who had not undergone surgery.⁴ Previous work has also demonstrated that inflammatory chemokine levels are elevated in the AH in the contralateral eye, even with uneventful cataract surgery.⁵ Gu et al.⁶ reported that cytokines, such as MCP-1 (CCL2), IL-6, and IFN- γ , were significantly elevated after vitrectomy in adults. Previous studies have similarly shown that aqueous flare can be detected in patients after cataract surgery; however, it is difficult for us to observe aqueous flare in children.

During cataract extraction, after the removal of the anterior and posterior capsule, the AH may flow directly into the capsular space, reaching the inner surface of the anterior capsule containing LECs. It is well known that this surgery breaks down the blood-aqueous barrier, significantly increasing postoperative inflammatory levels in infants and children. It is then reasonable to believe that the inflammatory nature of the microenvironment in the AH may affect the physiology of LECs. As regrowth of the lens from LECs has been suggested as a new potential therapeutic approach for pediatric cataract treatment,⁷ it is even more critical to understand these changes in cytokine levels after surgery.

Thus, the purpose of this study is to assess changes in the inflammatory microenvironment in the AH of children after surgery, with the aim of establishing a potential relationship between these cytokines and clinical findings.

Methods

Patients

Two groups of patients were established. The first group included aphakic eyes of congenital or developmental cataract patients following previous cataract surgery and who were scheduled for secondary intraoc-

ular lens (IOL) implantation. This group was referred to as the postsurgery group. For the second group, congenital or developmental cataract patients without a previous surgery (who were scheduled for lensectomy and anterior vitrectomy) were referred to as the nonsurgery group. All patients were enrolled at the Eye Hospital of Wenzhou Medical University, Hangzhou, between March 2016 and February 2017. The surgical protocols were approved by the institutional ethics review board of Wenzhou Medical University in compliance with the Declaration of Helsinki. Informed consent was obtained from all patients. The study was registered at www.clinicaltrials.gov and the clinical trial access number is NCT04120818.

Patients with eyes that underwent two or more surgeries or required YAG laser procedures were excluded. Eyes with persistent fetal vasculature, secondary glaucoma, uveitis, or any retinal disease were also excluded.

All patients underwent a thorough ophthalmologic examination, including slit-lamp examination, fundus examination, and A-scan and B-scan ultrasonography before surgery. Intraocular pressure (IOP) was evaluated with an iCare (Vantaa, Finland) rebound tonometer under anesthesia.

Data collection included age at cataract surgery and IOP. In postsurgical eyes, the state of iris was evaluated and graded according to the presence of synechiae. The capsule was evaluated according to fibrotic contraction.

Sample Collection and Analyses

AH samples were obtained using a 27-gauge needle at the beginning of the surgery before any incisional procedures had taken place. Care was taken not to touch the iris, the lens, or the corneal endothelium. A total of 50 to 200 μ L AH was gently withdrawn and then stored at -80°C until analyses were performed. Multiplexing technology (xMAP; Luminex, Austin, TX) was used to determine the AH level of cytokines, chemokines, and growth factors, including TNF- α , IL-6, IP-10 (CXCL10), IL-10, MCP-1 (CCL2), VEGF, IL-1, IFN- γ , IL-4, IL-17, IL-2, IL-5, G-CSF (CSF3), IL-12, and IL-15.^{8,9} The concentration of TGF- β 2 was measured by enzyme-linked immunosorbent assay (ELISA) using a kit (R&D Systems, Minneapolis, Minnesota, USA).

There is uncertainty regarding the reliability of four cytokine measurements (TNF- α , IL-5, IL-15, and IL-10) as the value was below the lower sensitivity limit for the immunoassay. These cytokines were excluded from the analysis.

Table 1. Patient Demographics

Parameters	Postsurgical	Nonsurgical	P Value
Number of patients (eyes)	20 (33)	17 (26)	
Sex, n (%)			
Male	23 (69.7)	20 (76.9)	0.535
Female	10 (30.3)	6 (23.1)	
Age, mean ± SD, mo	30.15 ± 12.75	36.92 ± 21.06	0.13
IOP	14.95 ± 2.91	14.01 ± 3.2	0.245

Nonsurgical group: congenital cataract diagnosis without surgery. Postsurgical group: congenital cataract surgery after lensectomy.

Table 2. Cytokine Levels in Postsurgical and Nonsurgical Eyes

Aqueous Cytokine	Postsurgical Eyes		Nonsurgical Eyes		P Value
	Median, pg/mL	IQR, pg/mL	Median, pg/mL	IQR, pg/mL	
TGF-β2	2407.68	2068.24–3455.43	2187.14	1700.53–2891.74	0.139
IL-6	4.81	3.53–9.7	3.26	3.01–3.79	<0.000 ^a
IP10	12.94	5.25–57.07	4.81	3.09–21.48	0.047 ^a
MCP-1	990.42	724.14–1297.94	639.94	430.74–933.96	0.006 ^a
VEGF	47.84	37.17–70.55	68.96	49.81–93.57	0.061
IFN-γ	41.29	39.34–43.28	40.62	39.34–42.28	0.37
IL-1	160.73	97.92–255.73	137.14	67.4–332.28	0.604
IL-4	33.09	31.89–36.22	35.58	31.89–38.15	0.163
IL-17A	10.75	10.32–11.4	10.32	9.8–11.33	0.223
IL-2	265.64	220.86–313.39	215.00	187.87–261.34	0.012 ^a
G-CSF	11.64	11.64–12.52	12.08	11.64–12.52	0.547
IL-12	100.17	91.49–109.13	100.17	94.71–104.61	0.056

^aP < 0.05.

Statistical Analysis

The data were analyzed using the Statistical Package for Social Sciences (SPSS Version 18.0 for Windows; SPSS, Inc, Chicago, IL). The Shapiro-Wilk test was used to evaluate the normality of distribution for all variables. The Mann-Whitney *U* test was used to evaluate the difference between postsurgical and nonsurgical eye groups. The difference in iris posterior synechiae, capsule contraction, and cortical exposure from the capsular bag was evaluated by the Mann-Whitney *U* test. The relationship between IOP and TGF-β2 was analyzed by Spearman's test. A two-tailed *P* < 0.05 was considered statistically significant.

were enrolled in the nonsurgical group. The demographic data of these patients are presented in Table 1. In the postsurgical group, the mean age was 30.15 ± 12.75 months (range, 15–72 months). In the nonsurgical group, the mean age was 36.92 ± 21.06 months (range, 10–72 months). There was no statistically significant difference in sex distribution ($\chi^2 = 0.384$, *P* = 0.535) or age ($\chi^2 = 0.578$, *P* = 0.13) between nonsurgical and postsurgical groups.

Cytokine Levels in AH of Postsurgical and Nonsurgical Eyes

Levels of IL-6, IP-10, MCP-1, and IL-2 were significantly elevated in postsurgical eyes compared to the nonsurgical eyes (*P* = 0.000, *P* = 0.047, *P* = 0.006, and *P* = 0.012, respectively) (Table 2).

Furthermore, there was significant correlation between the levels of TGF-β2 and IOP in postsurgical and nonsurgical eyes (*r* = 0.532, *P* = 0.006; *r* = 0.57, *P* = 0.001).

Results

Patients

Twenty patients (33 eyes) were enrolled in the postsurgical group, and 17 patients (26 eyes)

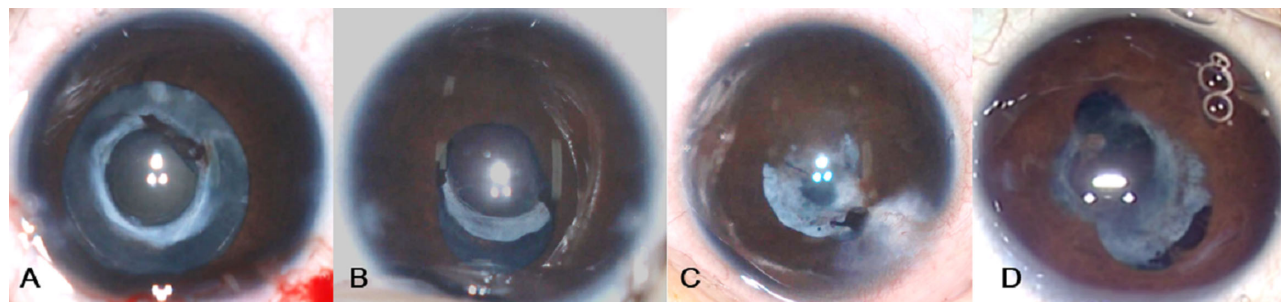


Figure 1. Classification of iris posterior synechiae. (A) Grade 1, iris synechiae in less than one quadrant; (B) grade 2, iris synechiae in less than two quadrants; (C) grade 3, iris synechiae in less than three quadrants; and (D) grade 4, iris synechiae in over three quadrants.

Table 3. Demographics of Aphakic Children with Congenital Cataract Who Underwent Cataract Surgery

Characteristic	Mean \pm SD
Age at first surgery, mo	5.30 \pm 2.46
Age at the IOL implantation, mo	30.15 \pm 12.75
Time between the two surgeries, mo	24.85 \pm 13.72

Analysis of AH in Aphakic Congenital or Developmental Cataract Patients after Lensectomy

In a total of 33 aphakic eyes of 20 children, the median age at cataract extraction was 5.30 \pm 2.46 months (range, 2–13 months), and the mean age at secondary implantation was 30.15 \pm 12.75 months (range, 15–72 months). The time between the two surgeries was 24.85 \pm 13.72 months (range, 9–60 months). The pupil could not be dilated due to posterior iris synechiae in 6 of the 33 eyes, preventing observation of the capsule. The capsular bag status was evaluated in only 27 eyes (Table 3).

Evaluating AH Cytokine Levels in Relation to Iris Synechiae

Iris posterior synechiae severity was defined as grade 1 to 4 by the extent of the area in which iris posterior synechiae was present. Grade 1 indicated iris posterior synechiae that were observed in less than one quadrant; grade 2, in less than two quadrants; grade 3, in less than three quadrants; and grade 4, in over three quadrants (Fig. 1). Iris synechiae were evaluated in 33 postsurgical eyes. Iris posterior synechiae scores were as follows: 17 (51.52%) eyes resulted in grade 1, 6 (18.18%) eyes showed grade 2, 4 (12.12%) eyes showed grade 3, and 6 (18.18%) eyes showed grade 4; however, there was no indication of a statistically significant relationship between inflammatory immune mediators and the level of iris synechiae ($P > 0.05$).

Evaluating AH Cytokine Levels in Relation to Contraction of Capsule

The 27 aphakic eyes were divided into two groups according to grading of the condition of capsule fibrosis and contraction. Grade 1 had no or slight fibrosis and contraction of the capsule, and grade 2 had moderate to severe fibrosis and contraction of the capsule (Fig. 2). Seven (25.9%) eyes revealed grade 1, while 20 (74.1%) eyes revealed grade 2. The state of capsule fibrosis and contraction was not significantly associated with AH cytokine levels ($P > 0.05$).

Evaluating AH Cytokine Levels in Relation to Cortical Exposure from Capsular Bag

We considered that cortical exposure to AH may influence the levels of inflammatory factors. To address this, we divided the 27 aphakic eyes into two groups: group 1 (cortical exposure) and group 2 (cortical closure) (Fig. 3). IL-6 in the capsular exposure group was significantly higher than in the cortical closure group (Table 4).

Discussion

The results suggest that the levels of IL-6, MCP-1, IP-10, and IL-2 increase significantly in aphakic eyes after the primary surgery compared to eyes without previous surgery. Furthermore, it was found that the expression of IL-6 was significantly elevated in postsurgical eyes with cortical exposure compared to eyes with cortical closure.

It is well known that inflammation is the main complication after cataract surgery. Kruger et al.¹⁰ report that flare and cells in the AH increase after phacoemulsification and return to baseline levels two months postsurgery; however, Jakobsson et al.¹¹ observed that inflammatory mediators remain elevated for many months or even years after cataract surgery,

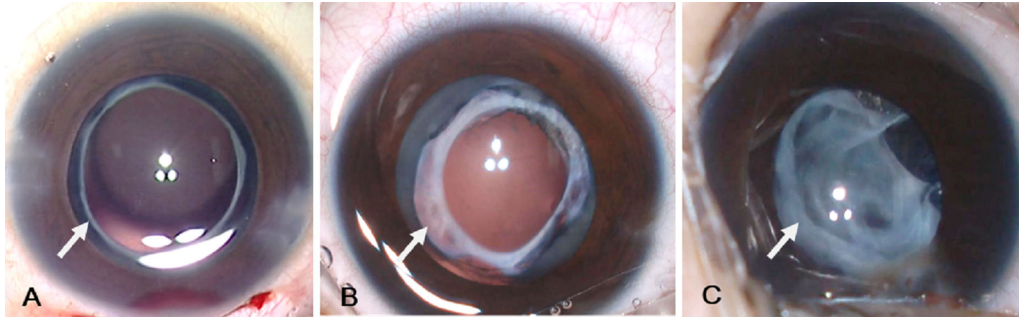


Figure 2. Classification of capsule fibrosis and contraction grade. (A) Grade 1, no or slight fibrosis and contraction of capsule; (B) grade 2, moderate fibrosis and contraction of capsule; and (C) grade 3, severe fibrosis and contraction of capsule.

Table 4. Cytokine Levels in Eyes between Cortical Exposure and Cortical Closure Eyes

Aqueous Cytokine No. of eyes	Cortical Exposure		Cortical Closure		P Value
	Median, pg/mL	IQR, pg/mL	Median, pg/mL	IQR, pg/mL	
TGF-β2	3459.83	2129.89–4974.72	2282	1671.9–2590.09	0.187
IL-6	10.08	4.93–20.09	4.00	3.3–7.98	0.023 ^a
IP10	20.64	11.91–57.07	9.27	5–61.13	0.187
MCP-1	1060.86	852.62–1635.76	1146.1	705.85–1366.85	0.928
VEGF	37.17	31.34–70.55	59.16	39.72–79.2	0.187
IFN-γ	40.62	39.34–44.63	41.95	40.62–43.28	0.996
IL-1	154.53	122.01–443.53	167.2	90.23–277.4	0.744
IL-4	33.09	31.89–35.58	33.10	31.3–37.51	0.928
IL-17A	11.27	10.45–12.08	10.75	9.8–11.59	0.996
IL-2	265.64	203.58–326.39	275.18	252.7–322.57	0.928
G-CSF	11.64	11.64–13.45	12.08	11.64–12.63	0.928
IL-12	100.17	91.49–109.13	102.41	90.43–109.13	0.744

^aP < 0.05.

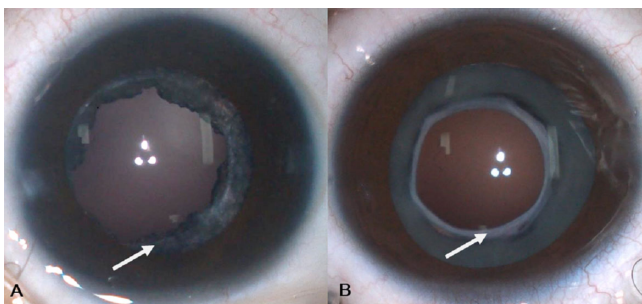


Figure 3. Classification of cortical exposure status. (A) Capsular exposure and (B) capsular closure.

suggesting the possibility of subclinical and prolonged inflammatory responses after cataract surgery.

Sometimes a child can fail to be diagnosed at an early stage in underdeveloped regions, where medical resources are in short supply, or children can't tolerate

general anesthesia because of poor general health condition (pneumonia or bronchitis), which may have their initial surgery delayed. It has been reported that the mean delay of presentation for surgery is 35.7 ± 32.2 months in patients with congenital cataract in China.¹² Pediatric cataract surgeons routinely carry out primary IOL implantation when performing cataract surgery in children over 2 years of age.¹³ These patients in turn yielded the control group (nonsurgery group) within this study, allowing the appropriate opportunity to compare these inflammatory mediators at approximately the same age. For children with cataract on a normal schedule, the secondary implantation of an IOL is generally scheduled when the growth of the eye is appropriate or when contact lens intolerance occurs after cataract extraction. After implantation, outcomes are associated with more frequent postoperative adverse events, particularly lens repopulation into

the visual axis, pupillary membrane formation, and secondary glaucoma. Few studies have investigated the status of inflammatory cytokine levels in the AH of pediatric cataract patients after primary surgery. To the best of our knowledge, the present study is the first to provide evidence of long-term increased levels of proinflammatory cytokines in congenital or developmental cataract eyes after lensectomy.

This leads to the consideration that changes within the balance of cytokines may lead to complications. Previous studies have supported this suggestion, reporting that the expression levels of cytokines in AH vary significantly between different eye conditions, including high myopia,¹⁴ glaucoma,⁹ diabetic retinopathy,^{15,16} and endophthalmitis.¹⁷ In this study, we reported that MCP-1 (CCL2) and IL-6 levels were significantly upregulated in the AH after cataract surgery for more than 1 year postsurgery. MCP-1 (CCL2) is known to recruit and activate inflammatory cells and to be important for tissue healing. MCP-1 expression has also been detected in eyes with diabetic retinopathy.¹⁸ Likewise, it is known to be involved in the process of developing a fibrotic capsule.¹⁹ Previous research showed that MCP-1 was elevated after cataract surgery for 30 to 90 days,²⁰ while Inoue et al.²¹ and Jakobsson et al.¹¹ demonstrated a significant increase of MCP-1 for more than 6 months after cataract surgery in adults. We report the same trend of MCP-1 activity in children.

Many of these studies also report that IL-6 is significantly increased in eyes with Posterior Capsular Opacity (PCO).³ Ma et al.²² suggest that IL-6 contributes to the development of PCO by promoting TGF- β 2 activation. Other studies comparably demonstrate increased levels of IL-6 in the AH after cataract surgery.²³ Therefore, the upregulation of MCP-1 and IL-6 in the AH of patients might be indicative of a proinflammatory state in these postsurgical eyes.

Although TGF- β 2 was not significantly different between the postsurgical and nonsurgical eye groups, we observed a higher trend in postsurgical group eyes. Interestingly, TGF- β 2 was significantly correlated with IOP in nonsurgery and postsurgery eyes. A previous study reported that in aphakic rabbit eyes, there were significantly higher levels of TGF- β 2 than in normal eyes.²⁴ Elevated TGF- β 2 in the AH may promote epithelial-myofibroblast transdifferentiation, triggering contraction of the capsule.²⁵ Inoue et al.²¹ revealed that the expression of TGF- β 2 in the AH was significantly increased in patients with primary open-angle glaucoma. Furthermore, TGF- β 2 may induce cytoskeletal changes within the trabecular meshwork.²⁶ Further studies are still warranted to confirm the suspected associations, but this may lead

to a better understanding of the mechanism of developing secondary glaucoma in aphakic eyes following surgery.

Also within this study, our results yielded that the level of IP-10 (CXCL10) in the AH was significantly higher in postsurgical eyes. This is consistent with previous studies.¹¹ IP-10 (CXCL10) has been reported to have both antiangiogenic and anti-inflammatory properties, and it has been shown that upregulated IP-10 (CXCL10) was correlated with development of PCO in congenital cataract patients.²

We did not, however, observe a significant difference in cytokine levels between eyes with different degrees of iris adhesion, capsular fibrosis, and capsular contraction. Thus, we hypothesize that iris adhesion and capsular fibrosis may be induced by an early inflammatory response, rather than chronic exposure to increased cytokine levels. It is not known if increased cytokine levels affect zonular fibers or the trabecular meshwork. Such studies require longer follow-up times and further investigation.

We suggest that there are two hypotheses for the chronic inflammatory state in postsurgical eyes: (1) the surgery causes a prolonged blood-aqueous barrier dysregulation, leading to the release of inflammatory factors, and (2) the disruption of normal cytokine homeostasis surgery leads to changes in LEC physiology. Thus, residual or proliferative LECs may be triggered to produce inflammatory cytokines.

Within the study, we further investigated the cytokine levels in the AH of eyes in which the proliferative cortex was exposed to the AH compared to eyes in which the proliferative cortex was closed in the residual capsular bag. We observed an increase in IL-6 in eyes with cortical exposure compared to eyes in which the capsule was closed. It is well known that the lens capsule creates a state of immune privilege to aid in the maintenance of the transparency of lens fibers.

In previous studies, it has been reported that residual lens fragments may cause a serious antigen-antibody reaction.^{27,28} Similarly, a rupture of the capsule, which exposes the lens to the AH, may cause cataracts.^{29,30} Contrarily, however, proliferative lens fibers are often stable and do not trigger serious antigen-antibody reactions in AH. These are examples of how exact mechanisms involved in immune responses to lens proteins are not well understood. Considering this, we believe elevated levels of IL-6 in eyes with a proliferative cortex exposed to the AH may affect the state of residual capsule material. This is an area that needs further study.

There are several known limitations of our study. First, due to regulatory and ethical concerns, we were unable to get AH from children who underwent

primary surgery at an early stage or normal children as controls. Second, the study was a case-control study. The patients with congenital or developmental cataracts before and after surgery were not the same patients. Third, we studied the age-matched difference of cytokines in postsurgery and nonsurgery eyes. It cannot be excluded that a long-standing cataract without surgery may influence cytokine levels. Fourth, children in aphakic states combined with glaucoma will have delayed secondary IOL implantation, so we excluded the patients with glaucoma.

Conclusion

In conclusion, to our knowledge, this is the first study to examine cytokine levels in the AH of patients with congenital or developmental cataracts before and after surgical treatment. Here, we report that IL-6, MCP-1 (CCL2), and IP-10 (CXCL10) were significantly upregulated after surgery, suggesting a chronic inflammatory state for an extended period of time. TGF- β 2 was significantly correlated with IOP in postsurgical and nonsurgical eyes. The significance of these increased levels of inflammatory mediators to influence the physiology of LECs is not fully understood, but these results provide new insight into potential long-term concerns after cataract surgery. By better understanding the inflammatory cytokine microenvironment of the aqueous humor, we aim to help explain long-term complications following surgery in patients with congenital or developmental cataracts.

Acknowledgments

Supported by research grants from the Natural Science Foundation of Zhejiang Province (LQ19H120001 to Yinying Zhao), research grants from the National Natural Science Foundation of China (81870680 to Yune Zhao), the Medical and Health Technology Program of Zhejiang Province (2017KY494 to Yinying Zhao), and the Innovation Discipline of Zhejiang Province (lens disease in children) (2016cxxxk1 to Yune Zhao).

Author contributions: design of the study (YEZ, YYZ); conduct of the study, data collection, analysis and interpretation (YYZ, XHD, PJC, MH, ZLL, FZ, XXD).

Disclosure: **Y. Zhao**, None; **X. Deng**, None; **P. Chang**, None; **M. Hu**, None; **Z. Li**, None; **F. Zhang**, None; **X. Ding**, None; **Y. Zhao**, None

References

1. Stevens GA, White RA, Flaxman SR, et al. Global prevalence of vision impairment and blindness: magnitude and temporal trends, 1990–2010. *Ophthalmology*. 2013;120:2377–2384.
2. Sauer A, Bourcier T, Gaucher D, Candolfi E, Speeg-Schatz C. Intraocular cytokines imbalance in congenital cataract and its impact on posterior capsule opacification. *Graefes Arch Clin Exp Ophthalmol*. 2016;254:1013–1018.
3. Nishi O, Nishi K, Ohmoto Y. Synthesis of interleukin-1, interleukin-6, and basic fibroblast growth factor by human cataract lens epithelial cells. *J Cataract Refract Surg*. 1996;22(suppl 1):852–858.
4. Lewis AC. Interleukin-6 in the pathogenesis of posterior capsule opacification and the potential role for interleukin-6 inhibition in the future of cataract surgery. *Med Hypotheses*. 2013;80:466–474.
5. Zhu XJ, Wolff D, Zhang KK, et al. Molecular inflammation in the contralateral eye after cataract surgery in the first eye. *Invest Ophthalmol Vis Sci*. 2015;56:5566–5573.
6. Gu R, Zhou M, Jiang C, Yu J, Xu G. Elevated concentration of cytokines in aqueous in post-vitrectomy eyes. *Clin Exp Ophthalmol*. 2016;44:128–134.
7. Lin H, Ouyang H, Zhu J, et al. Lens regeneration using endogenous stem cells with gain of visual function. *Nature*. 2016;531:323–328.
8. Jia Y, Hu DN, Zhu DQ, et al. MMP-2, MMP-3, TIMP-1, TIMP-2, and TIMP-3 protein levels in human aqueous humor: relationship with axial length. *Invest Ophthalmol Vis Sci*. 2014;55:3922–3928.
9. Huang W, Chen S, Gao X, et al. Inflammation-related cytokines of aqueous humor in acute primary angle-closure eyes. *Invest Ophthalmol Vis Sci*. 2014;55:1088–1094.
10. Kruger A, Schauersberger J, Findl O, Petternel V, Svolba G, Amon M. Postoperative inflammation after clear corneal and sclerocorneal incisions. *J Cataract Refract Surg*. 1998;24:524–528.
11. Jakobsson G, Sundelin K, Zetterberg H, Zetterberg M. Increased levels of inflammatory immune mediators in vitreous from pseudophakic eyes. *Invest Ophthalmol Vis Sci*. 2015;56:3407–3414.
12. You C, Wu X, Zhang Y, Dai Y, Huang Y, Xie L. Visual impairment and delay in presentation for surgery in Chinese pediatric patients with cataract. *Ophthalmology*. 2011;118:17–23.

13. Solebo AL, Russell-Eggitt I, Cumberland PM, Rahi JS; British Isles Congenital Cataract Interest Group. Risks and outcomes associated with primary intraocular lens implantation in children under 2 years of age: the IoLunder2 cohort study. *Br J Ophthalmol*. 2015;99:1471–1476.
14. Zhu X, Zhang K, He W, et al. Proinflammatory status in the aqueous humor of high myopic cataract eyes. *Exp Eye Res*. 2016;142:13–18.
15. Zhang K, Zhu X, Chen M, et al. Elevated transforming growth factor- β 2 in the aqueous humor: a possible explanation for high rate of capsular contraction syndrome in high myopia. *J Ophthalmol*. 2016;2016:5438676.
16. Liu DT, Chan VC, Chan WM, Lam DS. Relationship between anterior capsule contraction and posterior capsule opacification after cataract surgery in patients with diabetes mellitus. *J Cataract Refract Surg*. 2005;31:2042.
17. Sauer A, Candolfi E, Gaucher D, et al. Intraocular cytokine levels in post-cataract endophthalmitis and their association with visual outcome. *Ocul Immunol Inflamm*. 2018;26:964–970.
18. Taghavi Y, Hassanshahi G, Kounis NG, Koniari I, Khorramdelazad H. Monocyte chemoattractant protein-1 (MCP-1/CCL2) in diabetic retinopathy: latest evidence and clinical considerations. *J Cell Commun Signal*. 2019;13:451–462.
19. Wu X, Liu Z, Wang D, et al. Preoperative profile of inflammatory factors in aqueous humor correlates with postoperative inflammatory response in patients with congenital cataract. *Mol Vis*. 2018;24:414–424.
20. Kawai M, Inoue T, Inatani M, Tsuboi N, Shobayashi K, Matsukawa A, et al. Elevated levels of monocyte chemoattractant protein-1 in the aqueous humor after phacoemulsification. *Invest Ophthalmol Vis Sci*. 2012;53:7951–7960.
21. Inoue T, Kawaji T, Inatani M, Kameda T, Yoshimura N, Tanihara H. Simultaneous increases in multiple proinflammatory cytokines in the aqueous humor in pseudophakic glaucomatous eyes. *J Cataract Refract Surg*. 2012;38:1389–1397.
22. Ma B, Yang L, Jing R, et al. Effects of Interleukin-6 on posterior capsular opacification. *Exp Eye Res*. 2018;172:94–103.
23. Malecaze F, Chollet P, Cavrois E, Vita N, Arné JL, Ferrara P. Role of interleukin 6 in the inflammatory response after cataract surgery: an experimental and clinical study. *Arch Ophthalmol*. 1991;109:1681–1683.
24. Allen JB, Davidson MG, Nasisse MP, Fleisher LN, McGahan MC. The lens influences aqueous humor levels of transforming growth factor-beta 2. *Graefes Arch Clin Exp Ophthalmol*. 1998;236:305–311.
25. Wernecke L, Keckeis S, Reichhart N, Strauß O, Salchow DJ. Epithelial-mesenchymal transdifferentiation in pediatric lens epithelial cells. *Invest Ophthalmol Vis Sci*. 2018;59:5785–5794.
26. Trivedi RH, Nutaitis M, Vroman D, Crosson CE. Influence of race and age on aqueous humor levels of transforming growth factor-beta 2 in glaucomatous and nonglaucomatous eyes. *J Ocul Pharmacol Ther*. 2011;27:477–480.
27. Norton JC, Goyal S. Patient characteristics and outcomes of retained lens fragments in the anterior chamber after uneventful phacoemulsification. *J Cataract Refract Surg*. 2018;44:848–855.
28. Zavodni ZJ, Meyer JJ, Kim T. Clinical features and outcomes of retained lens fragments in the anterior chamber after phacoemulsification. *Am J Ophthalmol*. 2015;160:1171–1175.e1.
29. Banitt MR, Malta JB, Mian SI, Soong HK. Rupture of anterior lens capsule from blunt ocular injury. *J Cataract Refract Surg*. 2009;35:943–945.
30. Iida F, Matsushima Y, Hiai H, Uga S, Honda Y. Rupture of lens cataract: a novel hereditary recessive cataract model in the mouse. *Exp Eye Res*. 1997;64:107–113.