

# Atlantoaxial Chordoma in Two Patients with Occipital Neuralgia and Cervicalgia

Won Seop Kim, Jong Taek Park, Young Bok Lee, Woo Young Park\*

Department of Anesthesiology and Pain Medicine, Yonsei University Wonju College of Medicine, Wonju, Korea

Chordoma arises from cellular remnants of the notochord. It is the most common primary malignancy of the spine in adults. Approximately 50% of chordomas arise from the sacrococcygeal area with other areas of the spine giving rise to another 15% of chordomas. Following complete resection, patients can expect a 5-year survival rate of 85%. Chordoma has a recurrence rate of 40%, which leads to a less favorable prognosis. Here, we report two cases of chordoma presenting with occipital neuralgia and cervicalgia. The first patient presented with a C1-C2 chordoma. He rejected surgical intervention and ultimately died of respiratory failure. The second patient had an atlantoaxial chordoma and underwent surgery because of continued occipital neuralgia and cervicalgia despite nerve block. This patient has remained symptom-free since his operation. The presented cases show that the patients' willingness to participate in treatment can lead to appropriate and aggressive management of cancer pain, resulting in better outcomes in cancer treatment.

**Key Words:** Atlantoaxial, Chordoma, Occipital, Neuralgia, Block

## INTRODUCTION

Chordoma originates from the cellular remnants of the notochord. It is the most common primary malignancy of the spine in adults, and is typically seen in adolescents and young and middle-aged adults. Approximately 50% of chordomas originate from the sacrococcygeal area. Other areas of the spine give rise to another 15% of chordomas [1]. The 5-year survival rate is 85% in patients with complete resection. Chordomas have a recurrence rate of 40%. With recurrence, a secondary surgery becomes necessary, however, recurrence portends a poor prognosis even with additional radiotherapy and chemotherapy [2]. Additional treat-

ments can lead to general weakness because of a longer duration of treatment, and cancer pain can be a threat to quality of life. We report on two patients with chordoma that presented with occipital neuralgia and cervicalgia. The first patient had a C1-C2 vertebral body chordoma that was diagnosed at another center. The patient refused surgical resection and, despite pain management and nerve block, ultimately succumbed to death. The second case presented with sustained occipital neuralgia and cervicalgia unresponsive to nerve block. Following MRI imaging and diagnosis, the patient underwent surgery and remained symptom-free. The presented cases have different outcomes and prognoses stemming from the difference in intensive surgical management and pain control.

Received: August 22, 2014, Accepted: September 5, 2014

\*Corresponding author: Woo Young Park

Department of Anesthesiology and Pain Medicine, Yonsei University Wonju College of Medicine, 20 Ilsan-ro, Wonju 220-701, Republic of Korea

Tel: 82-33-741-1521, Fax: 82-33-742-8198

E-mail: [ulung@yonsei.ac.kr](mailto:ulung@yonsei.ac.kr)

## CASE REPORT

### 1. Case Report 1

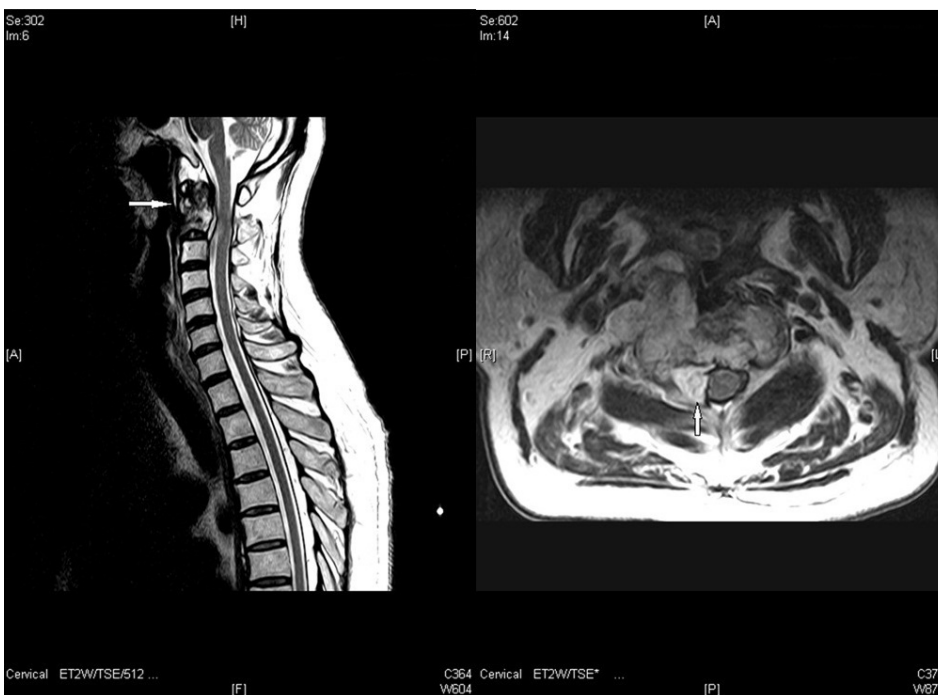A 71-year-old man was referred to our pain clinic with

the complaint of persistent occipital neuralgia. Three months before his presentation, he had undergone transoral biopsy and subtotal removal of a large retropharyngeal tumor. In the computed tomography (CT) imaging, the tumor was seen in the cervical spine, and further magnetic resonance imaging (MRI) studies identified the tumor around the first and second cervical vertebrae (Fig. 1). During a clinic visit, the patient was alert and primarily complained of right-sided occipital headache. Additionally, the patient complained of generalized weakness, fatigue, poor intake, and sleep disturbance. His headache was described as being persistent and not changing with position. The right-sided occipital pain was 6-7 on the visual analogue scale (VAS) score. He also had breakthrough pain occurring 2-3 times everyday that was determined to be of 7-8 severity on the VAS score. He was given tramadol hydrochloride 37.5 mg, acetaminophen 325 mg, prednisolone 5 mg, diazepam 2 mg, and fentanyl patch 25 mg/h. For the control of breakthrough pain, he was given IR-codon 5 mg as needed. Right occipital nerve block was performed five times during his 13-day admission, and the fentanyl patch dose was increased to 50 mcg/h. With these treatment measures, his pain decreased to 2-3 on the VAS score with reduction of breakthrough pain to 1-2 times a day. After discharge, an occipital nerve

block was performed once a week for 2 months, and his VAS score remained 4-6. The patient refused surgical removal of the spinal tumor and radiotherapy. Therefore, he was kept on his existing medications. On 4-month follow-up imaging, we found that the cervical spinal tumor had increased in size. After 6 months of follow-up, the patient was admitted to our institution's intensive care unit because of pain and drowsiness, and ultimately passed away due to respiratory failure.

## 2. Case Report 2

A 75-year-old man with the chief complaint of neck pain and tingling in his upper extremities was referred to our institution's pain clinic. On physical examination, his upper extremities had normal motor function but the left thumb and index finger had diminished sensation. There was tenderness on the back of the neck. Bilateral occipital cervicalgia was 7-8 on the VAS score. The patient also complained of a persistent and dull pain in his left shoulder. To control his neck pain, a cervical epidural block was performed at the C6-C7 level using a mixture of mepivacaine 0.5% 5 mL and dexamethasone 2 mg. Despite the block, occipital cervicalgia persisted, and an MRI was performed. In cervical spine MRI images, atlantoaxial bony fragmentation



**Fig. 1.** Sagittal and axial T2-weighted MRI image of atlantoaxial chordoma in case 1. It shows damaged bony structures and soft tissue invasion. Arrow points to the chordoma mass.

and a soft tissue mass in the epidural and prevertebral spaces was identified. In addition, left lateral canal stenosis was observed between the second and third cervical vertebrae and between the seventh cervical and the first thoracic vertebrae (Fig. 2). Over 15 days after discharge, a cervical epidural block, bilateral occipital nerve block, and left supra-clavicular nerve block were performed. In addition, the patient was given tramadol hydrochloride 37.5 mg b.i.d. and acetaminophen 325 mg b.i.d. After these treatments, the patient had a VAS score of 3-4. The patient was referred to another hospital to receive cervical spine surgery and underwent tumor excision of the second cervical spine and posterior C1-C2 fixation. The mass was pathologically confirmed as chordoma. The patient's neck pain and tingling disappeared after the surgery.

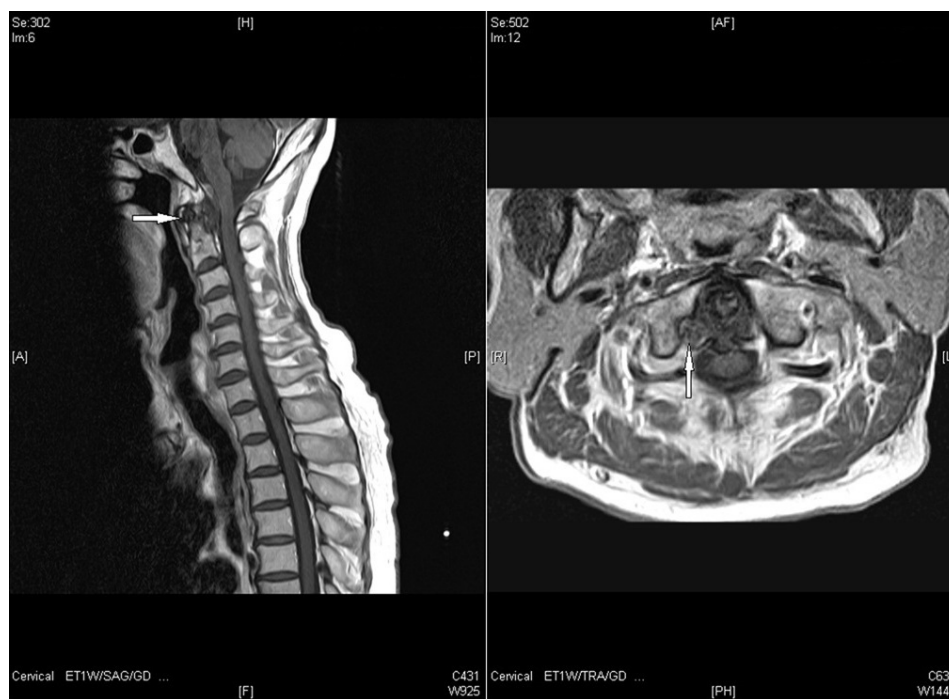## DISCUSSION

Chordoma is a relatively rare tumor that primarily occurs in the axial skeleton. Approximately 6% of chordomas arise from the cervical spine as a slowly growing tumor, which makes the tumor symptomatic at relatively later stages [3,4]. Upper cervical tumors often are accidentally discovered during investigation of cervical radiculopathy. The tumor

causes compression of the cervical nerve roots or gives rise to referred pain in the neck due to invasion into the cervical facet joints. Occasionally, the lesion is mistaken for a facet joint pathology or cervical disc herniation. It also can create a mass effect in the retropharyngeal area and cause symptoms such as dysphagia and dysphonia [4,5]. There is a 5-43% rate of metastasis to lung and other spinal areas. Although the tumor is histologically benign, it is clinically malignant as it infiltrates the neighboring tissues, such as bone, lymph nodes, skin, liver, and brain [6].

Gadolinium-enhanced MRI imaging shows heterogeneous lesions with low- to moderate- signal intensities on T1-weighted images and high-signal intensities on T2-weighted images [7,8]. Definitive diagnosis of chordoma requires histologic evaluation in which physaliferous cells with cytoplasmic vacuoles and positive periodic acid-Schiff (PAS) staining are observed [9].

The prognosis of chordoma is significantly affected by the first operation; the chance of clinical resolution diminishes with recurrence even with additional treatments. In surgery, en-bloc resection with cancer-free margins ensures long-term survival [10]. If en-bloc resection is not possible, adjuvant radiotherapy is used to remove remnant parts of the tumor. Palliative care of chordoma includes sympto-



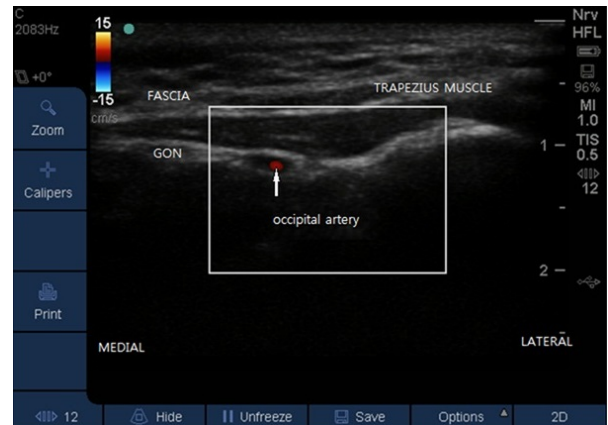
**Fig. 2.** Sagittal and axial T1-weighted MRI image of atlantoaxial chordoma in case 2. It shows atlantoaxial bony fragmentation and a soft tissue mass in the epidural and prevertebral spaces. Arrow points to the chordoma mass.

matic treatment, palliative surgery, radiotherapy, and post-operative local chemotherapy with cisplatin on the resected margins [11]. In cases with recurrence or incomplete resection, pain control lets the patients return to their previous daily activities and reinforces their willingness to partake in treatment and rehabilitation [12].

Atlantoaxial chordoma frequently becomes clinically symptomatic when it has grown considerably in size. Nerve compression and intraspinal invasion may result in severe neurologic complications [13]. In our presented cases, the tumor had invaded the second cervical spine root, and neuralgia of the greater occipital nerve led to headache. Occipital neuralgia develops when the atlantoaxial chordoma invades the second cervical spinal nerve root or compresses neighboring tissues. When the mass invades the atlanto-occipital joint or the zygapophysial joint of the second and third cervical vertebrae, referred pain is experienced in the lower occipital and posterior upper cervical areas. If the symptoms persist without appropriate treatment, they may progress to neuropathy. Once the neuralgia becomes a neuropathy, symptoms may persist despite tumor resection.

Pain management is affected by tumor involvement. The tumor is frequently covered with a capsule and causes a deviation in the vertebral artery and nerve roots to disrupt the normal anatomy, which makes transforaminal epidural approaches and root block procedures difficult. We had a multimodal approach for pain management via ultrasound-guided greater occipital nerve block, and an interlaminar approach for cervical epidural block and medications. The second cervical nerve originates between the first and second cervical vertebrae. The medial branch of the dorsal primary ramus joins the medial branch of the third cervical nerve underneath the inferior obliquus capitis muscle to form the occipital nerve. Then, it surrounds the suboccipital triangle and runs upward. After penetration of the trapezius muscle, the occipital nerve innervates the skin on the posterior parts of the scalp and vertex [14]. The greater occipital nerve runs upward through the trapezius muscle and 2 cm lateral to the occipital artery and 2 cm inferior to theinion.

Ultrasound-guided greater occipital nerve block is a more precise procedure that requires less local anesthesia (Fig. 3). It also prevents complications such as arterial puncture or nerve injury [15]. In our patients, we achieved acceptable



**Fig. 3.** Ultrasound image of the right greater occipital nerve. GON: greater occipital nerve.

results of pain relief using multimodal pain management that included ultrasound-guided occipital nerve block. Our patients had atlantoaxial chordoma and suffered from occipital neuralgia due to compression of the second cervical ganglion. The first presented patient gave up aggressive pain control and, with aggravation of symptoms, loss of willingness to participate in treatment was evident. Along with the refusal to have a surgical resection, suffering from pain significantly reduced quality of life in this patient. In contrast, the other patient had a successful surgical resection and aggressive pain management, which led to reinforcement of his willingness to continue treatment and this increased his quality of life.

In conclusion, the presented cases show that the patients' willingness to participate in treatment can lead to appropriate and aggressive management of cancer pain, resulting in better outcomes in cancer treatment.

## REFERENCES

1. Martin MP, Olson S. Intradural drop metastasis of a clival chordoma. *J Clin Neurosci* 2009;16:1105-7.
2. Wu AJ, Bilsky MH, Edgar MA. Near complete pathological response of chordoma to high dose single-fraction radiotherapy: Case report. *Neurosurgery* 2009;64:389-90.
3. Currier BL, Papagelopoulos PJ, Krauss WE, Unni KK, Yaszemski MJ. Total en bloc spondylectomy of C5 vertebra for chordoma. *Spine (Phila Pa 1976)* 2007;32:E294-9.
4. Singh N, Soo M, De Cruz M, Gomes L, Maclean F, Dandie G. Cervical chordoma presenting as retropharyngeal mass and dysphonia: case report and liter-

- ature review. *Australas Radiol* 2007;B183-8.
5. Barrenechea IJ, Perin NI, Triana A, Lesser J, Costantino P, Sen C. Surgical management of chordomas of the cervical spine. *J Neurosurg Spine* 2007; 6:398-406.
  6. Boriani S, Chevalley F, Weinstein JN, Biagini R, Campancci L, De lure F, Piccilli P. Chordoma of the spine above the sacrum: Treatment and outcome in 21 cases. *Spine (Phila Pa 1976)* 1996;21:1569-77.
  7. Soo M. Chordoma: review of clinicoradiological features and factors affecting survival. *Australas Radiol* 2001; 45:427-34.
  8. Kishimoto R, Omatsu T, Hasegawa A, Imai R, Kandatsu S, Kamada T. Imaging characteristics of metastatic chordoma. *Jpn J Radiol* 2012;30:509-16.
  9. Bjornsson J, Wold L, Ebersold M, Laws E. Chordoma of the mobile spine - a clinicopathological analysis of 40 patients. *Cancer* 1993;71:735-40.
  10. Barrenechea IJ, Perin NI, Triana A, Lesser J, Costantino P, Sen C. Surgical management of chordomas of the cervical spine. *J Neurosurg Spine* 2007;6:398-406.
  11. Stigen O, Ottesen N, Gamlem H, Akesson CP. Cervical chondroid chordoma in a standard dachshund: a case report. *Acta Vet Scand* 2011;53:55.
  12. Lim JJ, Kim SH, Cho KH, Yoon do H, Kim SH: Chordomas involving multiple neuraxial bones. *J Korean Neurosurg Soc* 2009;45:35-8.
  13. Jiang L, Liu ZJ, Liu XG, Ma QJ, Wei F, Lv Y, Dang GT. Upper cervical spine chordoma of C2-C3. *Eur Spine J* 2009;18:293-300.
  14. Cho JC, Haun DW, Kettner NW, Scali F, Clark TB. Sonography of the normal greater occipital nerve and obliquus capitis inferior muscle. *J Clin Ultrasound* 2010;38:299-304.
  15. Jung SJ, Moon SK, Kim TY, Eom KS. A case of occipital neuralgia in the greater and lesser occipital nerves treated with neurectomy by using transcranial doppler sonography: technical aspects. *Korean J Pain* 2011;24: 48-52.