

Ectopic Pancreas Causing Partial Gastric Outlet Obstruction: A Case Report and Review of Literature

Abdurrahaman Abba Sheshe, Ibrahim Yusuf^f

Departments of Surgery and ¹Pathology, Bayero University/Aminu Kano Teaching Hospital, Kano, Nigeria

ABSTRACT

Ectopic pancreas is a rare cause of gastric outlet obstruction, perhaps rarer still among Africans. Although the entity is known, the diagnostic challenges are enormous, especially in the poor-resource environment. Gastric outlet obstruction resulting from ectopic pancreas in an adult is the first of its kind in our center; we, therefore, present this case to describe the challenges faced with diagnosis, treatment, and the lesson learned. Ectopic pancreas should be considered in the differential diagnosis of gastric outlet obstruction.

KEYWORDS: *Ectopic, gastric, obstruction, outlet, pancreas*

INTRODUCTION

Ectopic pancreas refers to pancreatic tissue found in an organ or tissue distinct from and without anatomic or vascular continuity with the normal pancreas. This condition is also called aberrant pancreas, heterotopic pancreas, or pancreatic rest. The exact mechanism remains controversial, but it has been theorized that it most likely arises congenitally during embryonic development. These lesions are most commonly found in the distal stomach, duodenum, and jejunum.^[1,2] Majority of ectopic pancreas are asymptomatic and are discovered incidentally during endoscopy. When symptomatic, these lesions can present with pancreatitis, gastric outlet obstruction, ulceration, bleeding, cyst formation, or malignancy.^[3-5] We report a case of ectopic pancreas in gastric antrum and causing gastric outlet obstruction to enumerate the pitfalls involved in the diagnosis, treatment, and how the experience will modify surgical practice in our environment.

CASE REPORT

The patient was a 20-year-old female who presented with recurrent vomiting, upper abdominal pain, and progressive weight loss. The vomitus contained recently ingested foods but denied the presence of stale food materials. No history of abdominal distension, hematemesis, or melena. No previous symptoms suggestive of peptic ulcer disease. She habitually has a low appetite. There

were no associated constitutional symptoms, and system review was nil of note. Specifically, she had no history of cough or contact. She had no previous abdominal surgery or abdominal condition warranting admission.

On examination, she was found to be lean, afebrile, not pale, moderately dehydrated, no peripheral lymph nodes were palpable, and there was no pedal edema. Her cardiovascular examination was stable. Findings on examination of the abdomen were that of being scaphoid in shape, with visible peristalsis waves and tender epigastrium. Succussion splash could not be ascertained. There were no palpable enlarged organs. The bowel sounds were active. Per-rectal examination was essentially normal.

A clinical impression of gastric outflow obstruction possibly due to active peptic ulcer disease was made. She was admitted for resuscitation, gastric drainage, antibiotics, and antiulcer regimen. Her condition gradually improved; however, the vomiting reoccurred upon removal of the nasogastric tube, especially following ingestion of solid or large amount of foods. Further nonoperative treatments instituted were to no avail.

Address for correspondence: Dr. Ibrahim Yusuf, Department of Pathology, Bayero University/Aminu Kano Teaching Hospital, Kano, Nigeria.
E-mail: yusufeebrah@yahoo.com

This is an open access journal, and articles are distributed under the terms of the Creative Commons Attribution-NonCommercial-ShareAlike 4.0 License, which allows others to remix, tweak, and build upon the work non-commercially, as long as appropriate credit is given and the new creations are licensed under the identical terms.

For reprints contact: reprints@medknow.com

How to cite this article: Sheshe AA, Yusuf I. Ectopic pancreas causing partial gastric outlet obstruction: A case report and review of literature. Niger J Surg 2018;24:56-9.

Access this article online

Quick Response Code:



Website: www.nigerianjsurg.com

DOI: 10.4103/njs.NJS_27_17

Gastroendoscopy showed a smooth narrowing from the antrum extending toward the pylorus giving an impression of submucosal mass possibly gastrointestinal stromal tumor (GIST) [Figures 1 and 2]. Abdominal X-rays were found to be normal. Abdominal ultrasound revealed cystic collections around the pylorus. A needle aspiration showed a straw-colored fluid which was sent for microbial assessment. No organism was cultured.

Following optimization, an exploratory laparotomy was done. During the procedure, a search was made for possible malrotation or paraduodenal hernia since there was no evidence of fibrosis on pylorus. A gastrostomy was done to inspect the stomach more carefully. This revealed an adequate pylorus, smooth surfaced mucosa, and a firm mass in the posterior and lesser curvature of the stomach extending into the pylorus. A diagnosis could not be decided, and the condition of the patient under the circumstances would not allow a more extensive

operation. In view this, biopsy, gastrojejunostomy, and excision of the cystic swelling were done.

Abdomen was cleaned and closed. She did well postoperatively. Abdominal pain and vomiting subsided, and she continued to gain weight.

The tissue biopsy was sent to histopathology laboratory for histologic assessment. The laboratory received two fragments of grayish-white tissue measuring 5 cm × 4 cm × 3 cm and 3 cm × 2 cm × 1 cm, respectively. Cut sections showed grayish-white to tan, firm surfaces. Microscopy revealed a focally attenuated mucosa. The submucosa showed lobules of pancreatic acini and dilated ducts surrounded by extensive areas of fibrosis and lymphohistiocytic infiltrates. The muscularis propria appeared remarkably hypertrophied. A diagnosis of ectopic pancreas involving the gastric antrum was made [Figures 3 and 4].

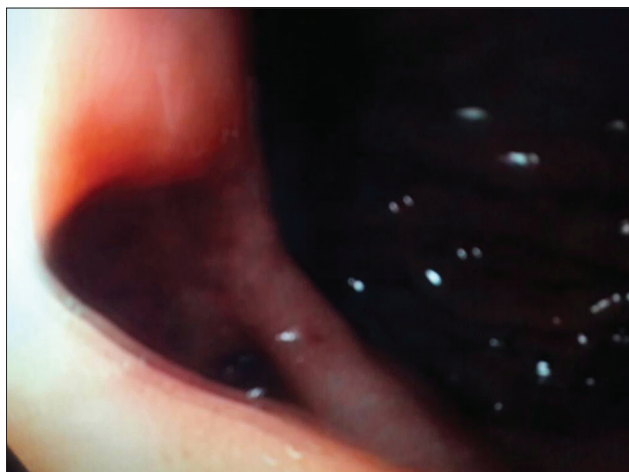

Figure 1: Gastroendoscopy showed a smooth narrowing from the antrum extending toward the pylorus giving an impression of submucosal mass

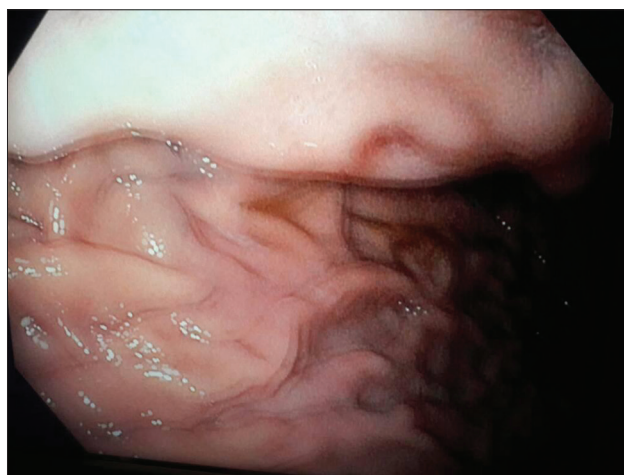


Figure 2: Gastroendoscopy showing a smooth narrowing from the antrum extending toward the pylorus giving an impression of submucosal mass causing partial outlet obstruction

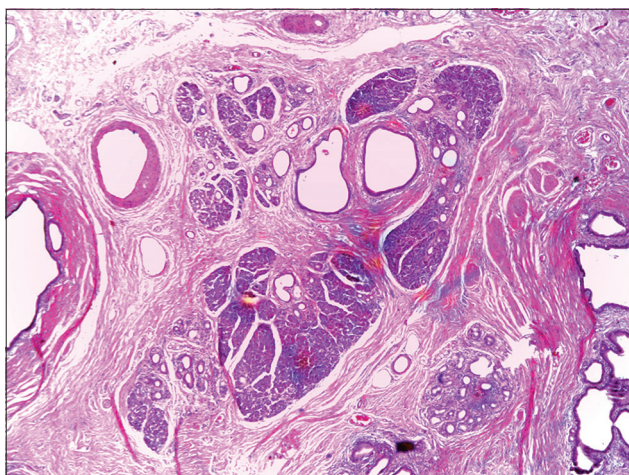


Figure 3: Pancreatic ducts and lobules within the muscularis of gastric antrum (H and E, ×10)

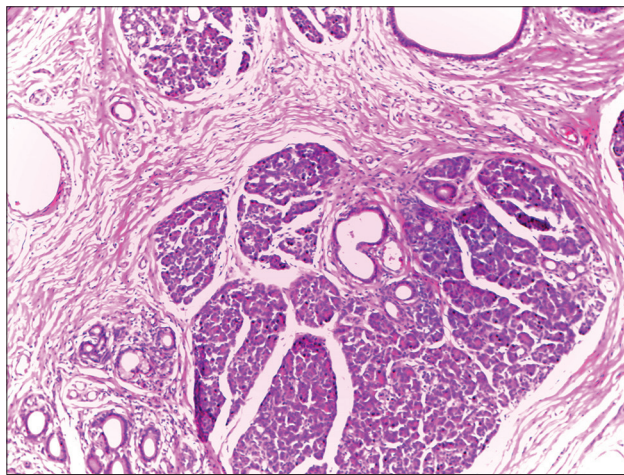


Figure 4: Lobules of pancreatic tissue and ducts within the muscularis of gastric antrum (H and E, ×40)

DISCUSSION

There is scanty information on the incidence of ectopic pancreas in African literatures; however, the lesion is found in 0.2% (1 in 500 surgeries) of abdominal surgeries, and in a large autopsy studies, the frequency of ectopic pancreas ranged from 0.6% to 13.7% and is seen commonly at 30–50 years of age with a male preponderance.^[6,7] Ectopic pancreas is mostly found in the stomach like the patient being presented, duodenum, and jejunum, but it may also be found anywhere in the digestive tract, intra-abdominally, in the mediastinum and in the lungs.^[8] Involvement of the stomach is seen in 25%–40% of cases and most frequently located along the greater curvature of the gastric antrum.^[9,10] In the stomach, the submucosal layer is the most common location of the pancreatic rest.^[11]

Ectopic pancreas is frequently an asymptomatic and incidental finding and rarely diagnosed preoperatively.^[4,5,9] Presentation may, however, be symptomatic; the index case presented with weight loss, epigastric pain which is the most common presentation, and vomiting resulting from mechanical gastric outlet obstruction.^[9,12,13] In addition to these, patients may also present with colicky abdominal pain, abdominal fullness, dyspepsia, melena, and gastric/duodenal ulceration.^[14] Patients may also develop complications such as pancreatitis, pseudocyst, insulinoma, and pancreatic carcinoma.^[1,7,10,14] The incidence of malignant transformation in ectopic pancreas was reported by Nakao *et al.* to be as high as 12.7%.^[15]

Ectopic pancreas is usually difficult to clinically differentiate from GIST, leiomyomas, adenomatous polyps, peptic ulcer disease, metastatic disease, or even primary gastric malignancy.^[9,16] Endoscopy, sonogram, and computed tomogram may be helpful in diagnosis, but only histology is definitive to differentiate ectopic pancreas from other lesions.^[8,9,17,18]

In the asymptomatic patient, periodic monitoring is recommended. Medical treatment is not effective for symptomatic patients, and localized surgical excision has been shown to be safe and adequate procedure for these patients unless malignant transformation has occurred.^[8,9,19,20] Intraoperative frozen section is useful to exclude malignancy, deciding extent of resection, and avoiding unnecessary radical surgery.^[9,16,21] Prognosis following excision is excellent.

CONCLUSION

Ectopic pancreas though uncommon is a relatively known entity, and the diagnosis is often challenging. It should always be considered as one of the rare

differentials of the causes of gastric outlet obstruction in young adults.

Declaration of patient consent

The authors certify that they have obtained all appropriate patient consent forms. In the form the patient(s) has/have given his/her/their consent for his/her/their images and other clinical information to be reported in the journal. The patients understand that their names and initials will not be published and due efforts will be made to conceal their identity, but anonymity cannot be guaranteed.

Financial support and sponsorship

Nil.

Conflicts of interest

There are no conflicts of interest.

REFERENCES

- Burke GW, Binder SC, Barron AM, Dratch PL, Umlas J. Heterotopic pancreas: Gastric outlet obstruction secondary to pancreatitis and pancreatic pseudocyst. *Am J Gastroenterol* 1989;84:52-5.
- Pang LC. Pancreatic heterotopia: A reappraisal and clinicopathologic analysis of 32 cases. *South Med J* 1988;81:1264-75.
- Matsushita M, Hajiro K, Okazaki K, Takakuwa H. Gastric aberrant pancreas: EUS analysis in comparison with the histology. *Gastrointest Endosc* 1999;49:493-7.
- Riyaz A, Cohen H. Ectopic pancreas presenting as a submucosal gastric antral tumor that was cystic on EUS. *Gastrointest Endosc* 2001;53:675-7.
- Jeng KS, Yang KC, Kuo SH. Malignant degeneration of heterotopic pancreas. *Gastrointest Endosc* 1991;37:196-8.
- Allison JW, Johnson JF 3rd, Barr LL, Warner BW, Stevenson RJ. Induction of gastroduodenal prolapse by antral heterotopic pancreas. *Pediatr Radiol* 1995;25:50-1.
- Mulholland KC, Wallace WD, Epanomeritakis E, Hall SR. Pseudocyst formation in gastric ectopic pancreas. *JOP* 2004;5:498-501.
- Ormarsson OT, Gudmundsdottir I, Márvik R. Diagnosis and treatment of gastric heterotopic pancreas. *World J Surg* 2006;30:1682-9.
- Hsia CY, Wu CW, Lui WY. Heterotopic pancreas: A difficult diagnosis. *J Clin Gastroenterol* 1999;28:144-7.
- Hickman DM, Frey CF, Carson JW. Adenocarcinoma arising in gastric heterotopic pancreas. *West J Med* 1981;135:57-62.
- DeBord JR, Majarakis JD, Nyhus LM. An unusual case of heterotopic pancreas of the stomach. *Am J Surg* 1981;141:269-73.
- Jiang LX, Xu J, Wang XW, Zhou FR, Gao W, Yu GH, *et al.* Gastric outlet obstruction caused by heterotopic pancreas: A case report and a quick review. *World J Gastroenterol* 2008;14:6757-9.
- Bromberg SH, Camilo Neto C, Borges AF, Franco MI, França LC, Yamaguchi N, *et al.* Pancreatic heterotopias: Clinicopathological analysis of 18 patients. *Rev Col Bras Cir* 2010;37:413-9.
- Kaneda M, Yano T, Yamamoto T, Suzuki T, Fujimori K, Itoh H, *et al.* Ectopic pancreas in the stomach presenting

- as an inflammatory abdominal mass. *Am J Gastroenterol* 1989;84:663-6.
15. Nakao T, Yanoh K, Itoh A. Aberrant pancreas in japan. Review of the literature and report of 12 surgical cases. *Med J Osaka Univ* 1980;30:57-63.
 16. Sukumar N, Teoh CM. Heterotopic pancreas in the stomach. *Med J Malays* 2004;59:541-3.
 17. Dolan RV, ReMine WH, Dockerty MB. The fate of heterotopic pancreatic tissue. A study of 212 cases. *Arch Surg* 1974;109:762-5.
 18. Armstrong CP, King PM, Dixon JM, Macleod IB. The clinical significance of heterotopic pancreas in the gastrointestinal tract. *Br J Surg* 1981;68:384-7.
 19. Ayantunde AA, Pinder E, Heath DI. Symptomatic pyloric pancreatic heterotopia: Report of three cases and review of the literature. *Med Sci Monit* 2006;12:CS49-52.
 20. Erkan N, Vardar E, Vardar R. Heterotopic pancreas: Report of two cases. *JOP* 2007;8:588-91.
 21. Yuan Z, Chen J, Zheng Q, Huang XY, Yang Z, Tang J, *et al.* Heterotopic pancreas in the gastrointestinal tract. *World J Gastroenterol* 2009;15:3701-3.