

ORIGINAL ARTICLE

CT appearances following laparoscopic partial nephrectomy for renal cell carcinoma using a rolled cellulose bolster

Deepa Pai^a, Jonathon M. Willatt^a, Melvyn Korobkin^a, Richard H. Cohan^a, James H. Ellis^a, Isaac R. Francis^a, J. Stuart Wolf Jr^b and Matthew Schipper^c

^aDepartments of Radiology, ^bUrology and ^cRadiation Oncology, University of Michigan Hospitals, Ann Arbor, MI 48109, USA

Corresponding address: Jonathon M. Willatt, MBChB, Taubman B-1/132, Box 5302, University of Michigan Hospital, 1500 East Medical Center Drive, Ann Arbor, MI 48109-0030, USA.

Email: jwillatt@med.umich.edu

Date accepted for publication 9 July 2007

Abstract

Abstract Purpose: To describe the evolving computed tomography (CT) appearances of a cellulose surgical bolster used as a hemostatic agent in patients who undergo laparoscopic partial nephrectomy for renal cell carcinoma. **Materials and methods:** We retrospectively reviewed the follow-up CT studies of 33 patients with stage T1N0M0 renal carcinoma who underwent laparoscopic partial nephrectomy using a rolled, oxidized, regenerated cellulose sheet sutured in place as a bolster in the parenchymal defect. Thirteen patients undergoing laparoscopic partial nephrectomy without the use of a bolster were also evaluated to differentiate imaging features. **Results:** The bolster-related masses were significantly larger than those seen in the non-bolster patients. There was a decrease in size of the post-operative bolster-related mass with time. The bolster shape evolved with time, initially appearing oval, and becoming irregular with decreasing size. Equivocal increase in attenuation of 10–20 HU was seen in 6 patients. Increase in attenuation of greater than 20 HU was seen in 3 patients. There was no evidence of tumor recurrence in any of the patients. Invagination of fat was seen in two bolster-related masses at 18 months or greater. **Conclusions:** Cellulose bolster has a variable appearance on follow-up CT exams. Evolutionary features include reduction in bolster size and shape with time leading finally to non-visualization. Bolster enhancement can mimic abscesses and tumor recurrence.

Keywords: Renal; carcinoma; laparoscopic; bolster.

Introduction

Laparoscopy has become the standard of care for those patients requiring radical nephrectomy. For those requiring partial nephrectomy, the laparoscopic technique is a recently developed minimally invasive alternative to open partial nephrectomy. The oncologic results are similar, and with growing expertise worldwide, the laparoscopic technique is being refined and standardized. Several techniques have been described to achieve closure and hemostasis, each of which provides challenges for the radiologist in the post-operative computed tomography (CT) evaluation for residual or recurrent tumor.

A rolled bolster consisting of oxidized cellulose, used in combination with a gelatin matrix sealant, provides greater hemostatic control than the gelatin matrix in isolation. This combination is used for masses that are located deep within the renal parenchyma or when the renal sinus is entered. The bolster also serves to assist in the prevention of urinary leak, although this is a rare complication. When cellulose is exposed to blood, it becomes engorged, forming a gelatinous mass^[1]. The primary hemostatic mechanism of oxidized cellulose is its ability to bind to hemoglobin and facilitate the formation of a thrombus. Platelet aggregation and adjacent foreign body reaction also contribute to its hemostatic properties^[2].

The cellulose and gelatin bolster mass in our institution is frequently interpreted as recurrence of tumor or abscess due to its morphology and enhancement characteristics because of a lack of awareness of the placement of this sealing agent. The purpose of this study is to describe the evolution of the CT appearances of the cellulose bolster material following laparoscopic partial nephrectomy for renal cell carcinoma.

Materials and methods

Institutional review board approval was obtained before the initiation of this retrospective study. In view of the retrospective nature of the study, written informed consent of study participants was not required. We retrospectively reviewed the CT studies of patients who underwent laparoscopic partial nephrectomy with the use of a bolster (Surgicel Nu-Knit, Ethicon, Cincinnati, OH) as a hemostatic agent between October 2003 and February 2008 at our institution.

Patients who were identified with histologic stage T1N0M0 tumors and deemed appropriate surgical candidates underwent laparoscopic partial nephrectomy utilizing surgical techniques described by Johnston *et al.*^[31]. Masses that extended to within 5 mm of the renal sinus, as seen by intraoperative ultrasound, were excised with scissors without using electrocautery. If the resection entered the renal sinus or collecting system, the site was closed with a running polyglycolic acid running suture. A gelatin matrix thrombin tissue sealant (FloSeal, Baxter, Deerfield, IL) was then applied to the defect and a rolled Surgicel Nu-Knit sheet was sutured in place as a bolster to achieve hemostasis (Fig. 1a,b).

CT follow-up was performed according to our institutional-based algorithm which is determined by the aggressiveness of the tumor subtype. CT was performed at 1 and 3 years for low risk tumors (low grade), at 6 and 12 months and then annually thereafter for moderate risk tumors (moderate grade) and at 6, 12, 18, and 24 months and then annually thereafter for high risk tumors (high grade). CT examinations were performed on either a 16- or 64-slice scanner (LightSpeed 16, LightSpeed 16 pro, LightSpeed 64 VCT; GE Medical Systems, Milwaukee, WI) using pre- and post-contrast nephrographic phase imaging. Post-operative imaging studies were divided into four groups determined by time elapsed following surgery: less than 6 months, 6–11 months, 12–17 months and >18 months.

From an initial group of 97 patients who underwent laparoscopic partial nephrectomy with use of a sutured bolster during the study period, those patients who had post-operative magnetic resonance imaging (MRI) only, those with benign pathology such as oncocytoma, and those who received all post-operative imaging at outside institutions were excluded from the study. Eleven patients in the study group had available pre-operative CT imaging (Fig. 2). Post-operative CT examinations

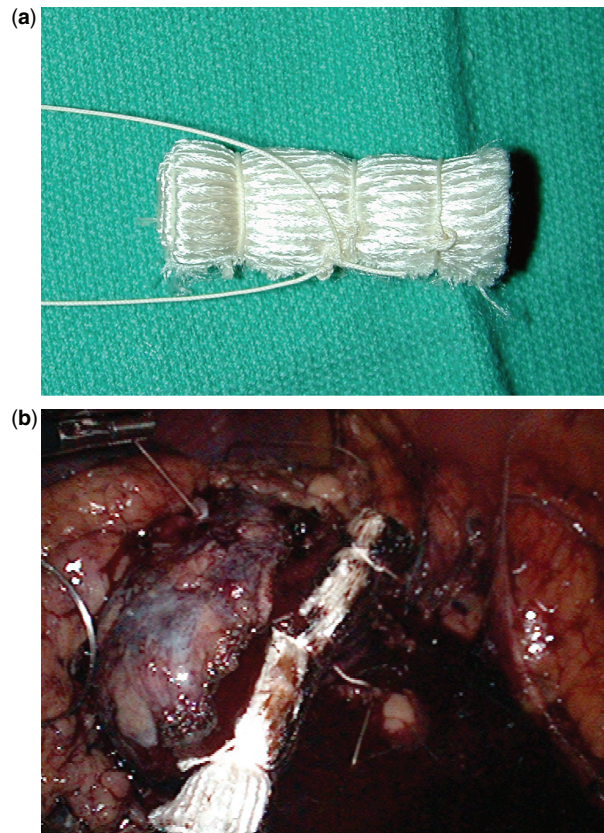


Figure 1 Rolled, oxidized, regenerated cellulose sheet (a) which is sutured in place as a bolster during laparoscopic partial nephrectomy to achieve hemostasis (b).

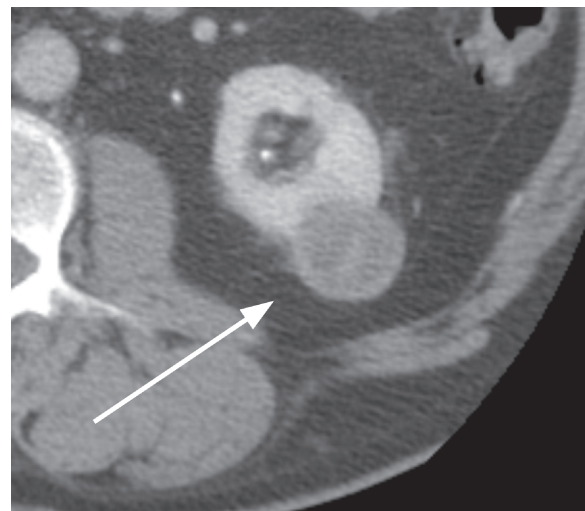


Figure 2 A 69-year-old male. Axial post-contrast image through the level of the kidneys demonstrates a heterogeneous enhancing mass (arrow) arising from the superior pole of the left kidney representing a renal cell carcinoma.

were available for the remaining 33 patients, all of whom had a histologic diagnosis of renal cell carcinoma. Thirteen patients had post-operative imaging within 6 months after partial nephrectomy. Only 3 of these

13 patients had both pre- and post-contrast studies. There were 14 patients who had post-operative imaging in the 6–11 months period, of whom 9 had both pre and post-contrast imaging. There were 23 patients who had post-operative imaging between 12 and 18 months, of whom 19 had both pre- and post-contrast imaging. Twelve patients had post-operative imaging at greater than 18 months, all of whom had both pre- and post-contrast imaging. One patient within this time period had two CT scans.

Two radiologists (MK and JW) reviewed by consensus each CT study for a predetermined set of radiologic variables. Attributes assessed on pre-operative CT imaging studies included the axial dimensions of the mass and pre- and post-enhancement attenuation values. Post-operative CT radiologic variables included size and shape of the post-operative mass, visualization of surgical material and assessment of enhancement. At least 3 regions of interest (ROI) were acquired and the ROI was placed at the same location in the pre- and post-operative CT images. Adjacent non-renal tissue was not included in the any of the measurements and an average of the 3 measurements was calculated and interpreted as the true mass density. Enhancement of greater than 20 HU was considered abnormal, less than 10 HU as within normal limits or accounted for by CT noise and between 10 and 20 as indeterminate. Additional findings relevant to image interpretation such as the presence of hemorrhage or gas were also noted.

A control group of 13 patients undergoing laparoscopic partial nephrectomy with the use of FloSeal as a hemostatic agent, but without the addition of a bolster, was also evaluated to differentiate imaging features. These patients underwent surgery during the same time period as the primary cohort, but had shallower tumors that did not require a sutured bolster. The size and shape of the surgical site/hematoma was measured, change in size with time elapsed after surgery and presence of enhancement were assessed. Similar to the study group, additional findings relevant to image interpretation such as the presence of gas were also noted.

To test whether the largest dimension in the axial plane changed over time we used a mixed effects regression model. Regression models were also used to assess whether the average degree of enhancement and the proportion of subjects exhibiting enhancement changed over time. Correlation between longitudinal measurements on the same subject was handled via subject level random effects in the regression models. Model fitting was performed via maximum likelihood.

Results

Pre-operative CT

Out of the 11 patients in the study group who had had available pre-operative CT imaging, the mean

pre-operative renal tumor size was 2.8 cm (range 1.7–3.6 cm) measured in greatest axial dimension (Fig. 2). Mean pre-contrast attenuation of the renal tumors was 32 HU (range 0–70 HU) and mean post-contrast attenuation was 81 HU (range 55–109 HU). On average, the renal tumors enhanced 49 HU (range 22–92 HU).

Morphology of bolster-related mass

Of the 13 patients imaged at less than 6 months, the bolster-related mass was visible in 12 cases and was obscured by post-operative hemorrhage in the other case. No bolster-related mass could be detected in 21% (3/14) of patients at 6–11 months, 35% (8/23) of patients at 12–17 months, and 42% (5/12) of patients imaged at 18 months or greater.

Evaluation of the 19 patients who had imaging studies performed in greater than one time category revealed that there was a decrease in size of the post-operative bolster-related mass with time (Fig. 3a,b) with the exception of one patient whose mass remained stable in size (Table 1). Mean largest dimension in the axial plane of masses that were visible (Fig. 4) was 3.2 cm at <6 months (range 2.5–4.3 cm), 2.4 cm at 6–11 months (range 1.1–5.1 cm), 2.3 cm at 12–17 months (range 1.1–3.6 cm) and 2.0 cm at 18 months or greater (range 1.6–3.0 cm) ($p = 0.0042$). The average change in size of the bolster mass per month was -0.53 mm/month (SE = 0.1526).

In addition, the shape of the post-operative mass also seemed to evolve with time. Sixteen of the 19 masses initially appeared oval-shaped and became more irregular in outline as they decreased in size (Fig. 3a,b).

Enhancement of bolster-related mass

Enhancement of greater than 10 HU was not seen in the 13 patients imaged within 6 months after nephrectomy. Mean pre and post-contrast bolster-related mass attenuation values were 28 HU (range 11–42 HU) and 33 HU (range 17–50 HU).

In the 6–11 months period, of the 9 patients who had both pre and post-contrast imaging, mean pre-contrast HU was 19 (range 6–31 HU) and mean post-contrast HU was 24 (range 6–41). Average increase in attenuation of the renal post-operative bolster-related mass was 5 HU (range -1 to 16 HU). One of these 9 patients demonstrated enhancement within the indeterminate range of 16 HU.

In the 12–17 months period, of the 19 patients who had both pre- and post-contrast imaging only 12 patients demonstrated masses that were detectable/measurable. Out of these 12 patients, mean pre-contrast HU was 19 (range 5–38 HU) and mean post-contrast HU was 30 (range 9–54 HU). Average post-contrast attenuation difference was 11 HU (range 2–16 HU) in this group. Four out of 12 cases (33%) demonstrated contrast enhancement of greater than 10 HU (Fig. 5a,b). Out of

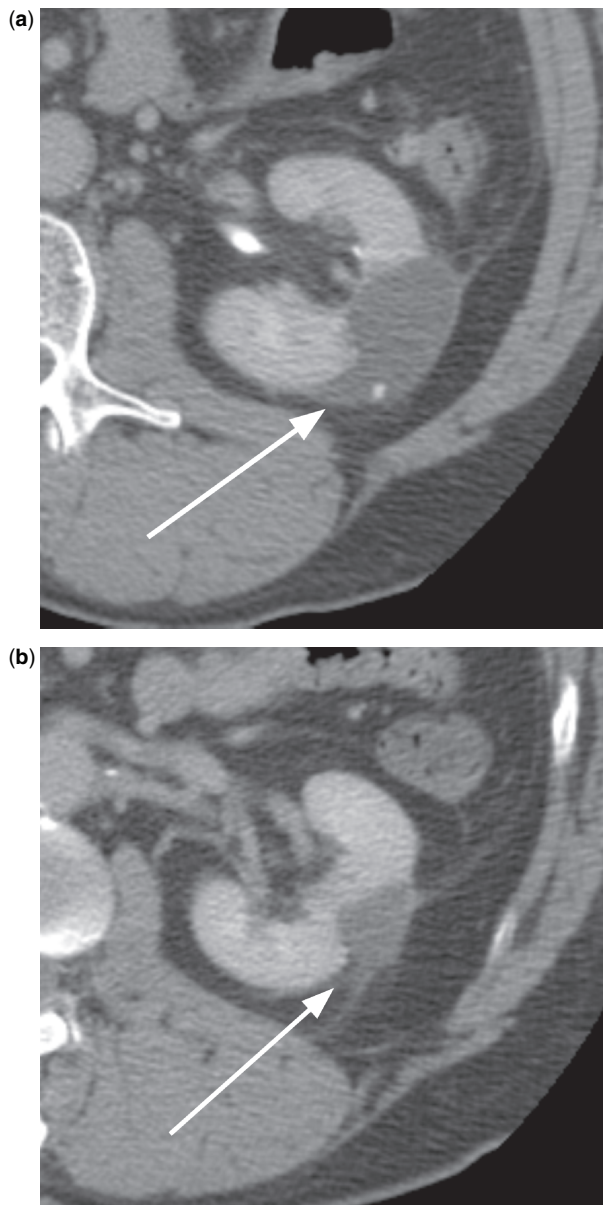


Figure 3 A 61-year-old male. Axial post-contrast images through the level of the kidneys obtained at 6–11 months (a) and 12–18 months (b) after left partial nephrectomy demonstrate decrease in size (arrows) of bolster-related mass and also change of shape of surgical bolster with time.

these four patients, three patients demonstrated contrast enhancement in the intermediate range (13, 14 and 16 HU) and one patient demonstrated unequivocal enhancement (33 HU).

In the greater than 18 months period, 12 patients had both pre and post-contrast imaging, of whom only 7 patients had detectable masses. Mean pre-contrast HU was 30 HU (range 11–50 HU) and mean post-contrast HU was 42 HU (range 29–61 HU). Average enhancement in this group was 13 HU. Out of these 7 patients, 4 demonstrated enhancement of greater than 10 HU

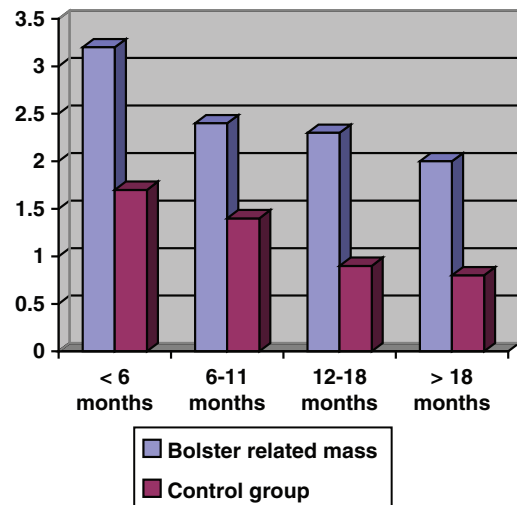


Figure 4 Bar graph shows mean largest dimension of bolster-related mass (blue columns) and control group post-operative change (red columns) in centimeters.

(Fig. 6). Specifically, 2 patients demonstrated enhancement in the intermediate range (12 and 18 HU) and 2 patients demonstrated unequivocal enhancement (20 and 27 HU). The overall change in enhancement of the bolster mass changed significantly over time ($p = 0.04$).

Continuing evaluation of all of the patients to March 2010 has revealed no findings to suggest tumor recurrence.

Other findings

Within the first 6 months after nephrectomy, suture material was visible in 9 of the 13 patients imaged in this time period. One patient also had visible surgical clips. In the 6–11 months time period, 11 of 14 patients had appreciable suture material on CT imaging and there was redemonstration of the surgical clips at the nephrectomy site in the one patient in whom clips were seen on an earlier study. Nineteen out of 23 patients imaged at 12–18 months demonstrated appreciable surgical material including suture material and clips. All of the 12 patients imaged at greater than 18 months also had identifiable sutures, even when no residual bolster mass was visible.

Foci of gas and hemorrhage were only noted at the resection site within 6 months of surgery (Fig. 7). Out of 10 patients imaged in this interval, 3 demonstrated foci of gas and 3 demonstrated hemorrhage. There were also adjacent fluid collections in 3 cases. These findings were not noted on any of the examinations performed at later time periods.

Two of the patients in the group imaged at greater than 18 months demonstrated foci of fat density within the post-operative bolster mass itself (Fig. 8a). The fat was located in areas previously occupied by soft tissue density (Fig. 8b).

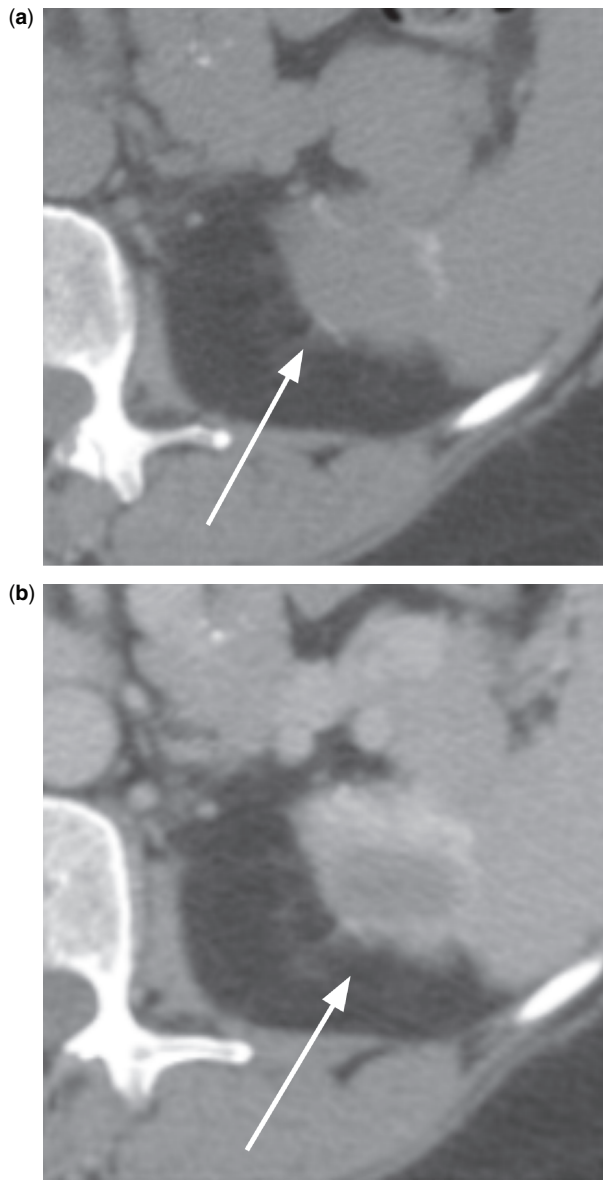


Figure 5 An 82-year-old female. Axial (a) pre- and (b) post-contrast images through the level of the kidneys obtained at 12–18 months after left partial nephrectomy demonstrate enhancement of 16 HU of the bolster-related mass.

Control group

Comparison with post-operative imaging in 13 patients who underwent laparoscopic partial nephrectomy with the use of a gelatin matrix without bolster material revealed several differences. Mean largest dimension was 1.7 cm at <6 months, 1.4 cm at 6–11 months, 1.1 cm at 12–18 months and 0.8 cm at greater than 18 months after surgery (Fig. 9a,b). As with the bolster group, the size decreased with time elapsed after surgery, but the sizes were smaller during each of these two intervals in the non-bolster group ($p = 0.0348$). None of the

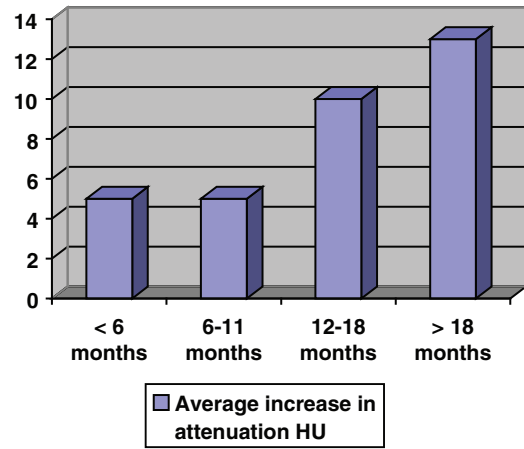


Figure 6 Bar graph shows degree of enhancement of bolster-related mass in Hounsfield units.

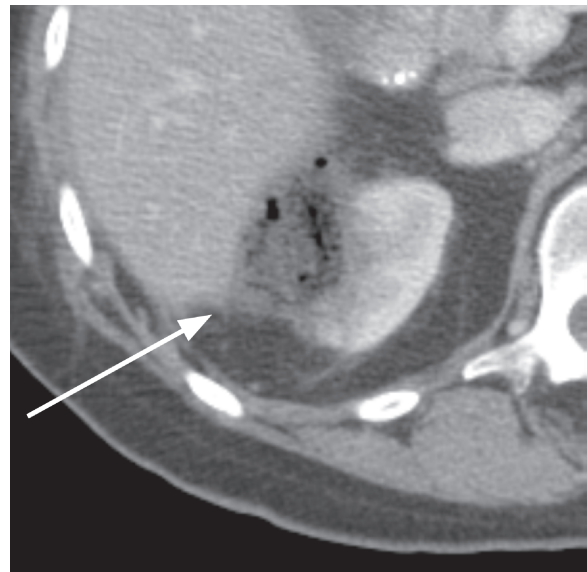


Figure 7 A 59-year-old male. Post-contrast axial image through the level of the right kidney obtained within 6 months after right partial nephrectomy and insertion of bolster demonstrates gas bubbles and hemorrhage at the nephrectomy site which could be confused with abscess formation.

non-bolster cases demonstrated significant enhancement after contrast administration.

Discussion

There are now several surgical alternatives for the treatment of stage 1 renal cell carcinoma. The CT and MRI appearances of tumors treated by partial nephrectomy and by radiofrequency ablation have been described. After partial nephrectomy a wedge-shaped defect in the

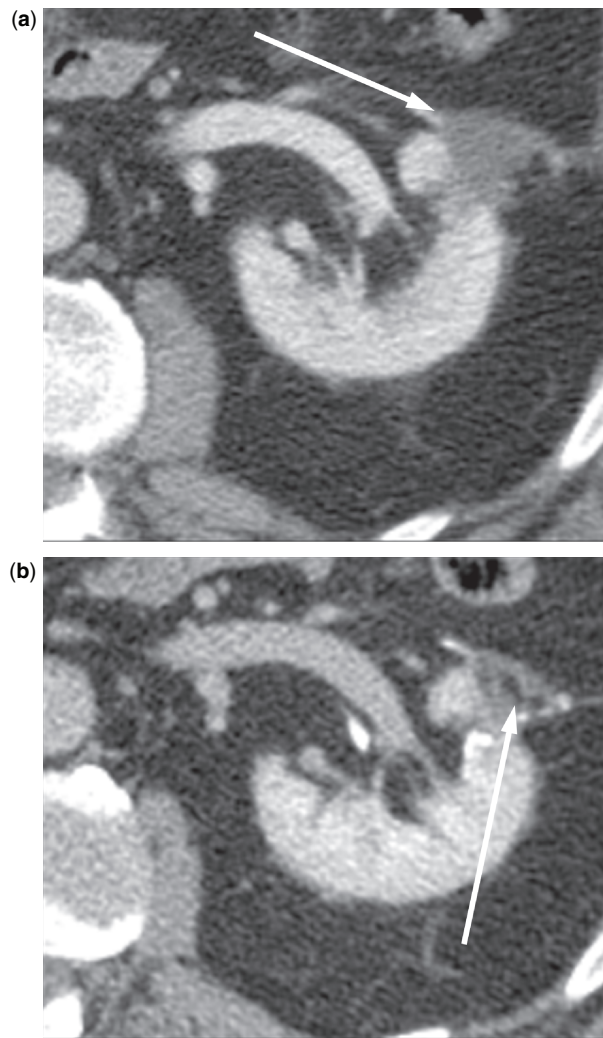


Figure 8 A 61-year-old male. Post-contrast axial image (a) at 6–11 months shows a 21×18 mm mass. At greater than 18 months (b) there has been development of fat interposed within the mass (arrows) as well as reduction in size.

kidney is typically seen^[4], unless perinephric fat is packed into the defect to help achieve hemostasis, in which case a fatty mass which can be mistaken for an angiomyolipoma can be seen. Biologically absorbable hemostatic sponges are also used to control intraoperative bleeding, and these can be confused for abscesses on post-operative CT because of the presence of air bubbles, which can persist for up to a month^[5,6]. This is in contrast with the bolster-related mass, which can persist for over 18 months.

Following radiofrequency ablation a transient increase in size of the post-ablation beds can be seen in small masses^[7]. After 12 months there is a decrease in size but not complete resolution of the ablation beds. Although no enhancement is seen on contrast enhanced CT, a thin rim of enhancement can be seen on post-gadolinium MRI. This is distinct from the nodular or

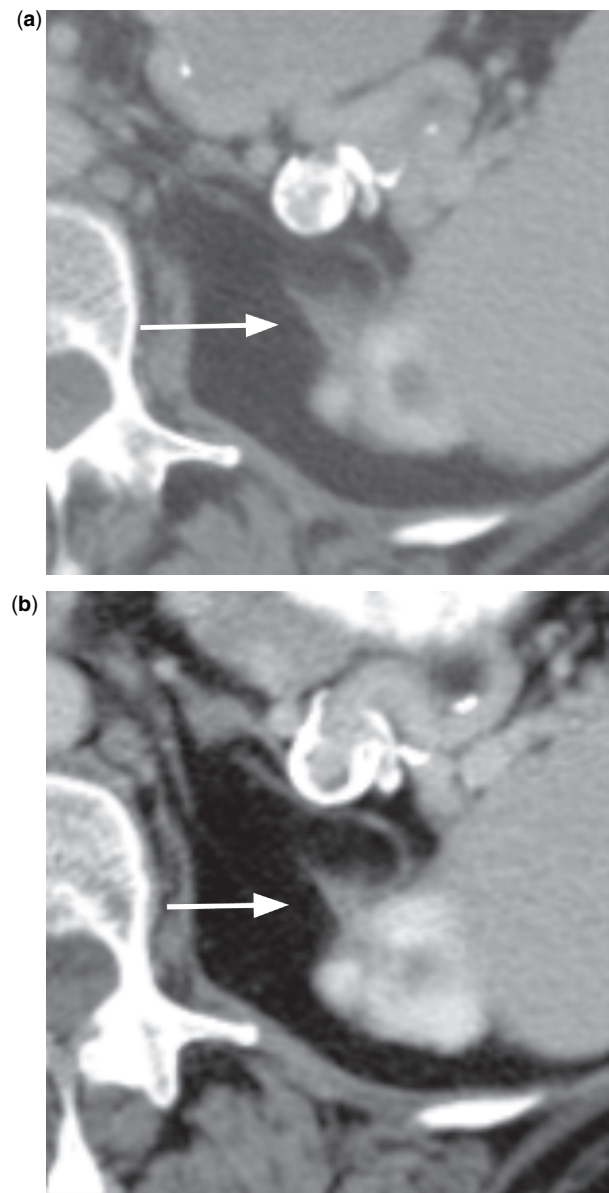


Figure 9 A 77-year-old male. Post-contrast axial images through the level of the left kidney obtained at 6–11 months (a) and at 12–18 months (b) after left partial nephrectomy and use of fibrin glue without a bolster demonstrate interval reduction in size of ill-defined post-operative change.

crescentic enhancement seen in cases of disease recurrence^[8,9]. Perinephric stranding is seen in most cases after ablation, but this frequently evolves into a halo representing either a fibrotic scar or coalescence of the stranding itself^[7]. Invagination of fat is also seen infrequently after ablation^[7], explained as resulting from retraction of the ablated tumor bed away from normal renal parenchyma.

Surgical granulomas have previously been described in the literature in the liver, central nervous system, aortic valve and adjacent to the ovaries^[10–14]. In our study a bolster was used following laparoscopic partial

nephrectomy to achieve hemostasis for lesions located deep within the renal parenchyma, especially if the renal sinus was entered in patients with increased blood pressure, in whom hemostasis is more difficult to achieve otherwise^[15].

Several pertinent imaging features were noted in our study. Typical features that were noted within 6 months after nephrectomy included gas and hemorrhage at the resection site (Fig. 7). As with the bioabsorbable sponges placed following partial nephrectomy, misinterpretation of these findings as a post-operative abscess is a danger. The appearances of surgical bolsters used elsewhere in the body mimicking abscesses has also been described previously^[16–18].

In all but one of our cases in which there were multiple post-operative studies, there was a reduction in size of the bolster-related mass over time (Fig. 3). There was no transient increase as seen in some of the cases after radiofrequency ablation. Indeed, over time, there was complete resolution of the mass in 3 of 14 cases imaged at 6–11 months, 8 of 23 patients imaged at 12–17 months and 5 out of 12 patients imaged at greater than 18 months. In addition to the change in size, the bolster-related mass also changed in shape with time. Initially, the majority of bolster-related masses appeared oval-shaped. They became more irregular in outline as they decreased in size.

There was equivocal or borderline enhancement of the bolster-related mass in one patient at 6–11 months, 3 of 12 patients imaged at 12–18 months and in 2 of 7 patients imaged at greater than 18 months. The mean increase in attenuation also went up with time, averaging 5 HU at 6–11 months, 10 HU at 12–17 months and 13 HU at greater than 18 months.

There were also 3 patients who demonstrated unequivocal enhancement, 2 in the 12–17 months period and 1 in the 18 months or greater period. Comparison with previous time periods revealed that all 3 of these had demonstrated some reduction in size. They also showed no apparent enhancement on the previous studies. Possible explanations for this finding include growth of granulation tissue at the resection site, partial volume averaging or pseudoenhancement^[19]. Our results suggest that equivocal or unequivocal enhancement of a mass following the use of a Surgicel bolster, which otherwise might be concerning for tumor recurrence, should be regarded in the context of change in size. If the size of the mass is decreasing, the increase in attenuation should be regarded as related to the bolster material and not to tumor recurrence.

In 2 examinations obtained at more than 18 months after surgery fat density replaced a portion of the soft tissue density within the bolster mass as it evolved. This is comparable with the findings described in patients after radiofrequency ablation in which fat can be seen interposed between normal renal tissue and the ablated lesion^[20,21].

Compared with the post-nephrectomy group using only fibrin glue as a hemostatic agent, 2 main differences were noted. The average size of the non-bolster masses decreased with time as with the bolster group. However, the size of the non-bolster masses was smaller in each time group compared with the bolster cases. In addition, no appreciable enhancement was visualized in any of the non-bolster cases.

Attention should also be paid to the presence of surgical material such as clips or sutures, even if poorly defined, as this can alert the reader to the presence of a bolster in the surgical bed in cases where interpreters are unsure of the surgical history.

Limitations of our study include the small number of patients and the heterogeneity in follow-up, resulting in varying numbers of patients evaluated in each time period. The former is related to the fact that this is an early developing technique for hemostasis. The latter is due to the retrospective nature of our study. In addition, there were no cases of tumor recurrence in our group. This is not surprising given the low grade of the tumors resected. In cases of tumor recurrence it would be expected that tumor would grow either outside of the booster-related mass, or that there would be evidence of nodular enhancement within the mass. However, we have no evidence to support this and further studies illustrating this would be valuable.

We have shown that the immediate post-operative imaging features of partial nephrectomy with bolster material can mimic abscess at the resection site due to the presence of gas and that they can be confused with recurrent tumor on follow-up imaging studies. In addition, we have outlined the evolution of the Surgicel granuloma with respect to size, shape and enhancement characteristics. Understanding of these appearances should minimize false interpretations of bolster material granulomas as renal carcinoma recurrences and therefore decrease morbidity and mortality related to unnecessary subsequent procedures or surgery.

References

- [1] Ito H, Onishi H, Shoin K, Nagatani H. Granuloma caused by oxidized cellulose following craniotomy. *Acta Neurochir (Wien)* 1989; 100: 70–3. doi:10.1007/BF01405278. PMID:2816537.
- [2] Bradley M, Singh G. Case report: an oxidized cellulose granuloma – another hepatic pseudotumour? *Clin Radiol* 1991; 44: 206–7. doi:10.1016/S0009-9260(05)80876-1.
- [3] Johnston 3rd WK, Montgomery JS, Seifman BD, Hollenbeck BK, Wolf Jr JS. Fibrin glue v sutured bolster: lessons learned during 100 laparoscopic partial nephrectomies. *J Urol* 2005; 174: 47–52. doi:10.1097/01.ju.0000162041.64143.08. PMID:15947575.
- [4] Israel GM, Hecht E, Bosniak MA. CT and MR imaging of complications of partial nephrectomy. *Radiographics*. 2006; 26: 1419–29. doi:10.1148/rg.265065701. PMID:16973773.
- [5] Turley BR, Taupmann RE, Johnson PL. Postoperative abscess mimicked by Surgicel. *Abdom Imaging* 1994; 19: 345–6.
- [6] Sandrasegaran K, Lall C, Rajesh A, Maglinte DT. Distinguishing gelatin bioabsorbable sponge and postoperative abdominal abscess on CT. *AJR Am J Roentgenol* 2005; 184: 475–80.

- [7] Davenport MS, Caoili EM, Cohan RH, *et al.* MRI and CT characteristics of successfully ablated renal masses: imaging surveillance after radiofrequency ablation. *AJR Am J Roentgenol* 2009; 192: 1571–8. doi:10.2214/AJR.08.1303. PMID:19457820.
- [8] Gervais DA, Kalva S, Thabet A. Percutaneous image-guided therapy of intra-abdominal malignancy: imaging evaluation of treatment response. *Abdom Imaging* 2009; 34: 593–609.
- [9] Wile GE, Leyendecker JR, Krehbiel KA, Dyer RB, Zagoria RJ. CT and MR imaging after imaging-guided thermal ablation of renal neoplasms. *Radiographics* 2007; 27: 325–39; discussion 339–40. doi:10.1148/rg.272065083. PMID:17374856.
- [10] Gao HW, Lin CK, Yu CP, Yu MS, Chen A. Oxidized cellulose (Surgicel) granuloma mimicking a primary ovarian tumor. *Int J Gynecol Pathol* 2002; 21: 422–3. doi:10.1097/00004347-200210000-00015. PMID:12352194.
- [11] Johnston 3rd WK, Wolf Jr JS. Laparoscopic partial nephrectomy: technique, oncologic efficacy, and safety. *Curr Urol Rep* 2005; 6: 19–28. doi:10.1007/s11934-005-0063-9. PMID:15610693.
- [12] Krizova P, Masova L, Suttner J, *et al.* The influence of intrinsic coagulation pathway on blood platelets activation by oxidized cellulose. *J Biomed Mater Res A* 2007; 82: 274–80.
- [13] Sandhu GS, Elexpuru-Camiruaga JA, Buckley S. Oxidized cellulose (Surgicel) granulomata mimicking tumour recurrence. *Br J Neurosurg* 1996; 10: 617–19.
- [14] Stringer MD, Dasgupta D, McClean P, Davison S, Ramsden W. “Surgicel abscess” after pediatric liver transplantation: a potential trap. *Liver Transpl* 2003; 9: 197–8. doi:10.1053/jlts.2003.50059. PMID:12548515.
- [15] Permpongkosol S, Bagga HS, Romero FR, Sroka M, Jarrett TW, Kavoussi LR. Laparoscopic versus open partial nephrectomy for the treatment of pathological T1N0M0 renal cell carcinoma: a 5-year survival rate. *J Urol* 2006; 176: 1984–8; discussion 1988–9. doi:10.1016/j.juro.2006.07.033. PMID:17070227.
- [16] Finelli A, Gill IS. Laparoscopic partial nephrectomy: contemporary technique and results. *Urol Oncol* 2004; 22: 139–44.
- [17] Moinzadeh A, Gill IS, Finelli A, Kaouk J, Desai M. Laparoscopic partial nephrectomy: 3-year followup. *J Urol* 2006; 175: 459–62. doi:10.1016/S0022-5347(05)00147-3.
- [18] Young ST, Paulson EK, McCann RL, Baker ME. Appearance of oxidized cellulose (Surgicel) on postoperative CT scans: similarity to postoperative abscess. *AJR Am J Roentgenol* 1993; 160: 275–7.
- [19] Birnbaum BA, Hindman N, Lee J, Babb JS. Renal cyst pseudoenhancement: influence of multidetector CT reconstruction algorithm and scanner type in phantom model. *Radiology* 2007; 244: 767–75. doi:10.1148/radiol.2443061537. PMID:17709828.
- [20] Gervais DA, McGovern FJ, Arellano RS, McDougal WS, Mueller PR. Renal cell carcinoma: clinical experience and technical success with radio-frequency ablation of 42 tumors. *Radiology* 2003; 226: 417–24. doi:10.1148/radiol.2262012062. PMID:12563135.
- [21] Matsumoto ED, Watumull L, Johnson DB, *et al.* The radiographic evolution of radio frequency ablated renal tumors. *J Urol* 2004; 172: 45–8. doi:10.1097/01.ju.0000132124.01060.0c. PMID:15201734.