



Exenterate or Not: A Simple Proposed Management Algorithm for Mucormycosis During the Era of COVID-19 in a Tertiary Eye Care Center in Egypt

Reham Refaat Shabana, Mohamed Ashraf Eldesouky , Hazem A Elbedewy 

Department of Ophthalmology, Faculty of Medicine, Tanta University, Tanta, Gharbeya, Egypt

Correspondence: Hazem A Elbedewy, Department of Ophthalmology, Faculty of Medicine, Tanta University, Tanta, Gharbeya, Egypt, Tel +201276732425, Email hazemelbedewy@yahoo.com

Purpose: To construct a simple management algorithm for cases with orbital mucormycosis during the COVID-19 era.

Methods: Retrospective study included records of 30 Egyptian patients with post COVID-19 orbital mucormycosis. They underwent full clinical examination, laboratory investigations, Computed tomography (CT)/magnetic resonance imaging (MRI) of the paranasal sinuses and pathological specimen examination. The proposed algorithm was based on all the available data of the included patients.

Results: The mean age of the studied patients was 62.47 ± 11.13 years; 56.6% were females and 63.3% had uncontrolled diabetes mellitus. The main presentation was Orbital apex syndrome (OAS) in 43.3% of the cases. Twenty-six patients (86.6%) received systemic liposomal amphotericin B, while 4 patients (13.3%) received posaconazole. Orbital exenteration was done in 6 patients (20.0%), 4 of them died (66.7%). Twenty-four patients (80%) survived with clinical but not with visual improvement.

Conclusion: Systemic antifungal treatment and functional endoscopic sinus surgery (FESS) with extensive debridement of involved necrotic tissues were the main steps to control ROCM. Orbital exenteration should be kept for cases with periorbital tissue affection as it did not increase the final cure rate. The proposed management algorithm is supposed to be simple and easy to follow.

Keywords: mucormycosis, exenteration, COVID-19, ophthalmoplegia, Egypt

Introduction

Mucormycosis is a serious fungal infection and can lead to death.¹ A fungus from the family, Mucoraceae can cause the disease and usually, *Mucor*, *Rhizopus* and *Absidia* species are implicated.² Mucormycosis family is generally harmless to the immunocompetent individuals; however, they can cause a deadly opportunistic infection in immunocompromised hosts like those with uncontrolled diabetes, malignancies, on systemic steroids or other immunosuppressants.³⁻⁶

The global pandemic of Coronavirus disease 2019 (COVID-19) challenged the public health system all over the world and caused millions of morbidities and mortalities.⁷ The resulted acute respiratory distress syndrome (ARDS) required the administration of long-term broad-spectrum antibiotics, corticosteroids, or even respiratory support by invasive or non-invasive mechanical ventilation. In addition, the humidity in the mechanical ventilation system and the zinc supplements would raise the risk of co-infection in such patients.^{5,6,8}

The nature of mucormycosis is an invasive type of fungal infection. It invades the sinus tissues within a month and penetrates the blood vessels causing vasculitis, thrombosis, hemorrhage with characteristic neutrophilic infiltrates.⁶ Because of the proximity of the paranasal sinuses and the orbit to the brain; a progressive mucormycosis infection can spread into rhino-orbital-cerebral mucormycosis (ROCM).⁹

Research for fungal infection suffered chronic neglect worldwide. This resulted in very limited number of diagnostic and management tools in the hands of the medical personnel. The diagnosis depends mainly on the stained histological sections and tissue culture, which are invasive, time consuming and not highly sensitive.⁵

Some authors observed larger number of ROCM cases started to appear in Egypt after COVID-19 pandemic especially with the second wave. They reported increase from 1 to 2 cases per year to 12 cases during 2021.¹⁰

This study aimed to detect the different clinical manifestations and risk factors and to suppose a simple protocol of management of post COVID-19 ROCM.

Materials and Methods

A retrospective study, carried out in a tertiary center, included 30 medical records of patients presented to Tanta University Eye Hospital, between July 2020 and July 2021. Informed written consent (to participate and publish) was obtained from each patient/legal authority before including their medical records in the study (including their medically related images).

The study was approved by the Research Ethics Committee, Faculty of Medicine, Tanta University with approval code (34882/8/21) and was conducted according to the declaration of Helsinki and its later amendment.

The included records were reviewed for full personal and medical history including; age, sex, past history of diseases, eg, diabetes mellitus, previous infection with COVID-19 infection (confirmed by PCR & CT chest), medications received (including systemic steroids), invasive or non-invasive mechanical ventilation and the interval between COVID-19 infection and the appearance of clinical manifestations of mucormycosis.

The medical records were also reviewed for results of the ophthalmological examination including visual acuity measurement, ocular motility, pupil reactivity, proptosis, eyelid examination for ptosis, lid edema, anterior segment examination (involving corneal clarity and sensation) and posterior segment examination (including fundus examination or B-scan ultrasonography in case of media opacity).

Laboratory investigations were done to any suspected ROCM case in the form of complete blood count (CBC), blood glucose level and HbA1C. To confirm the diagnosis, specimens obtained from the nasal cavity and/or paranasal sinuses was prepared by 20% potassium hydroxide (KOH) and cultured on Sabouraud's Dextrose agar, where the fungus appear as broad aseptate hyphae with right-angled branching.

CT or MRI of paranasal sinuses, orbit, and brain were obtained to identify the disease's extent. In addition, otorhinolaryngological and neurological consultations were assessed to determine the disease's extent and severity.

For the management of included patients, the authors constructed the management algorithm described in [Chart 1 \(Additional File\)](#). The construction of the algorithm was based on the clinical, laboratory and imaging data of the previous and current mucormycosis patients.

Statistical analysis: the data were handled by Microsoft Excel® and were presented as numbers (No.), percentage (%), mean and standard deviations.

Results

The study included records of 30 patients with ROCM. Their age ranged from 42 to 87 years with a mean age of 62.47 ±11.13 years. There were 17 females (56.6%) and 13 males (43.3%). The major co-morbidity was diabetes mellitus in 27 patients (90%), which was uncontrolled in 19 (63.3%) of them. Twenty patients (66.6%) had systemic steroid therapy, and 4 (20%) of them were given steroids for more than 10 days. Twenty-two patients (73.3%) need oxygen therapy, but only 1 (3.3%) required mechanical ventilator support (3.3%), see [Table 1](#).

The interval between COVID-19 recovery and the first reporting of patient with mucormycosis ranged from 1 to 6 weeks with an average of 2.8 weeks. It was 2–3 weeks in 25 patients (83.3%).

The mean lag time between the onset of symptoms and ROCM diagnosis was 4.13 days (range: 2–7 days). The left eye was involved in 9 patients (30%), while the right was involved in 21 patients (70%).

Thirteen patients (43.3%) were presented by orbital apex syndrome (OAS), 6 (20.0%) by ocular ischemic syndrome (OIS), 4 (13.3%) by orbital cellulitis (OC) and 3 (10.0%) by both OC and OAS. Another 4 (13.3%) patients were presented by superior orbital fissure syndrome (SOFS).

Four patients (13.3%) had associated cerebral manifestations in the form of disturbed conscious level and CT and MRI brain confirmed cerebral involvement.

Table 1 Socio-Demographic and Clinical Characteristics of the Included Patients (n=30)

Variable	No. (%)
Age (mean±SD, range)	62.47±11.13, 42–87 years
Gender	
Male	13 (43.3)
Female	17 (56.6)
Eye:	
Right	21 (70.0)
Left	9 (30.0)
Comorbidities/risk factors:	
Diabetes mellitus	27 (90.0)
Systemic steroid therapy	20 (66.6)
Oxygen therapy	22 (73.3)
Ophthalmological presentation	
Orbital apex syndrome (OAS)	13 (43.3)
Ocular ischemic syndrome (OIS)	6 (20.0)
Orbital cellulitis (OC)	4 (13.3)
Both OC and OAS	3 (10.0)
Superior orbital fissure syndrome (SOFS)	4 (13.3)
Cerebral manifestations	4 (13.3)
Outcome	
Died	6 (20.0)
Survived	24 (80.0)

Only 11 patients (36.6%) had useful vision (6/60 or better) at the time of presentation, while 19 patients (63.3%) suffered from severe diminution of vision (less than 3/60). Leucopenia was detected in 12 cases (40%). The fungal culture was positive for the entire cohort. Only one patient (3.3%) had received COVID-19 vaccinations.

CT nose and paranasal sinuses showed that half of our patients had both mucormycosis pansinusitis and maxillary bone necrosis, while 6 patients (20%) had maxillary bone necrosis only.

A diagnostic sign of invasive fungal sinusitis was the appearance of black turbinate in MRI (Figure 1). Another characteristic sign that appeared in the CT & MRI of one patient presented with orbital cellulitis was tenting of the globe (the globe appeared more triangular than circular) due to increased intra-orbital volume (Figure 1).

Twenty-six patients (86.6%) received systemic liposomal Amphotericin B at a dose of 5–10 mg/kg/day, increasing a total dose of 2.5–3 g, while 4 patients (13.3%) received posaconazole as Amphotericin B was contraindicated due to renal impairment.

All the patients underwent functional endoscopic sinus surgery (FESS) with extensive debridement of the involved necrotic tissues until bleeding-healthy tissue was reached.

Orbital exenteration was done in 6 patients (20.0%), 4 of them died (66.7%) (2 because of cerebral involvement and 2 because of uncontrolled diabetes (Figure 2)).

Twenty-four patients (80%) patients survived with improvement of the lid edema, conjunctival chemosis and inflammatory manifestations of orbital cellulitis. Mild gradual improvement of the ophthalmoplegia occurred without improvement of visual acuity in patients presented initially with loss of vision (Figures 3 and 4). This improvement occurred within 3–4 months of treatment. The overall mortality among our patients was 20.0% (6 patients).

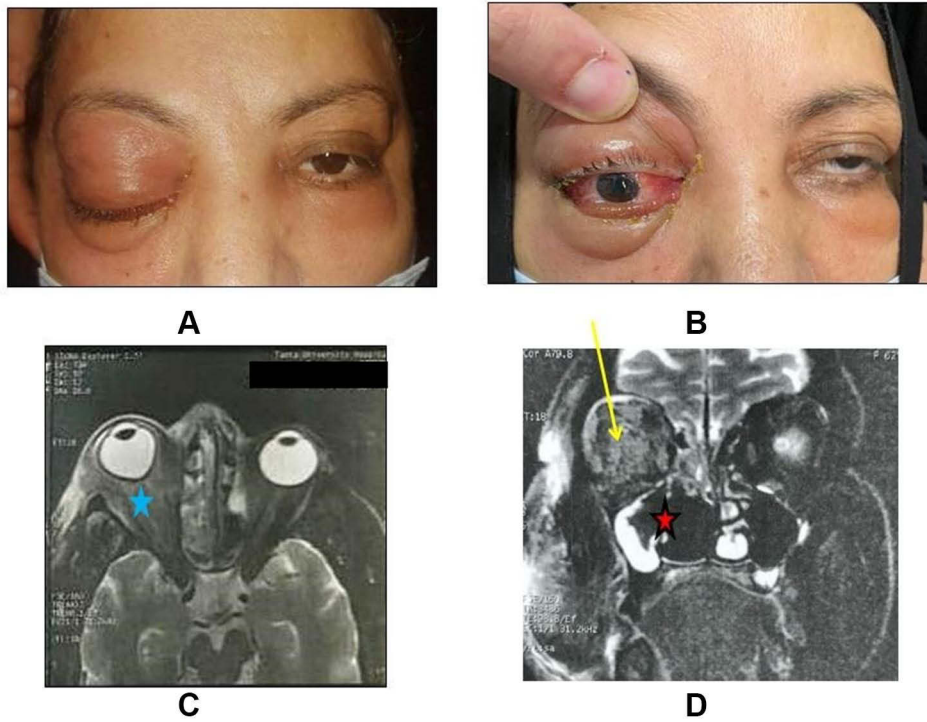


Figure 1 (A and B) A 62-year-old female patient with right combined OC & OAS not responding to aggressive debridement and retrobulbar Amphotericin B injection. **(C)** Axial fat-saturated T2W MRI showed tenting of the right eye ball (blue asterisk) and loss of all soft tissue details due to severe cellulitis. **(D)** Fat-saturated post-contrast T2W showed absence of enhancement of the involved retro-orbital fat and extraocular muscles (yellow arrow) denoting defective tissue perfusion. The red asterisk showed the black turbinate sign due to aggressive nasal debridement. The condition was controlled only after orbital exenteration.

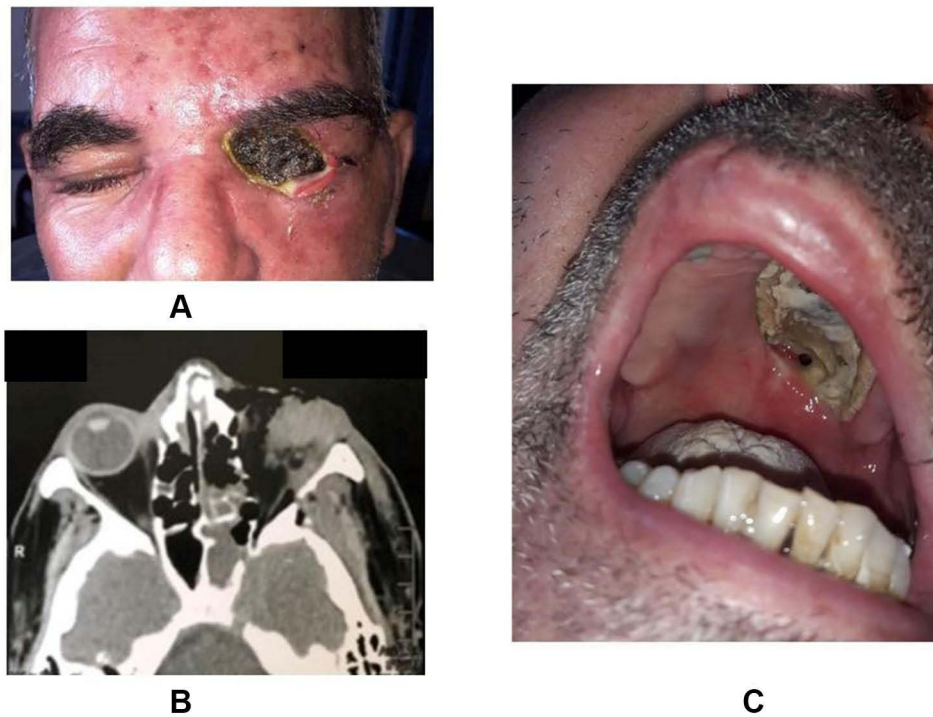


Figure 2 (A) A 79-year-old male patient presented with left severe orbital soft tissue necrosis. **(B)** Axial CT scan through the mid orbit showed complete loss of the anatomical details of all the orbit soft tissue including the eye ball. **(C)** The hard palates of the same patient showed severe necrosis. The condition was managed by exenteration; however, this did not save the patient's life.

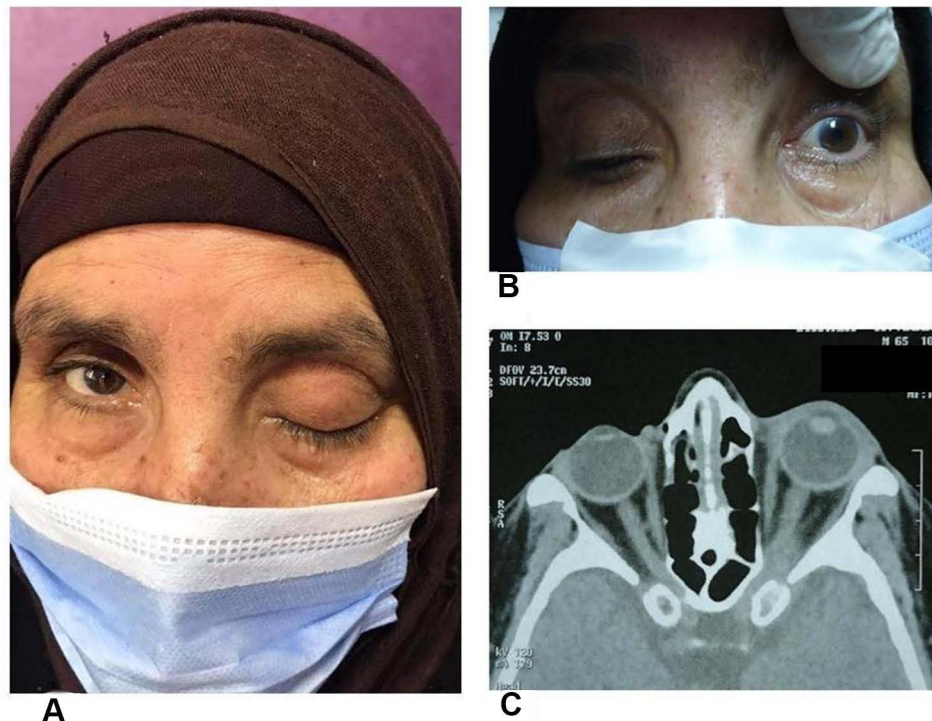

Figure 3 (A) A 65-year-old female patient presented with left eyelid severe ptosis, loss of vision (NPL) and total ophthalmoplegia. (B) The left eye was very quiet with minimal congestive manifestations. (C) CT scan showed mild proptosis, thickened optic nerve (red arrow). No bony erosion was evident. The patient received IV Amphotericin B and showed gradual improvement in ptosis and ophthalmoplegia after 4 months of therapy without the need for exenteration.

Discussion

Rhino-orbital-cerebral mucormycosis is a rare invasive life-threatening fungal infection.² However, its incidence increased dramatically during the COVID-19 pandemic. In Egypt, Fouad et al,¹⁰ in the year 2021, documented much higher incidence of ROCM cases in their study year than the previous 3 years.

In our study, we detected 30 cases of post COVID-19 ROCM in the period between July 2020 and July 2021. Their mean age was almost 60 years, without marked gender predominance. Uncontrolled diabetes mellitus, followed by systemic steroid therapy, was the major cause of the immunocompromised status of the affected patients.

Fouad et al¹⁰ reported very close results. They identified 12 cases with ROCM with mean age of 51 years, half of them were males and over 80% of them had poorly controlled diabetes mellitus. Also, Alloush et al,¹¹ Elkhly et al,¹² and Fouad et al¹³ reported the same findings.

Another comparable study carried out in India included 2826 COVID-19-associated ROCM patients from January 2020 to May 2021. Their mean age was around 50 years and about two-thirds of them were males and had diabetes mellitus. More than half of the included patients needed oxygen support, and the majority (87%) were treated with corticosteroids to control for the COVID-19 infection.¹⁴

Among our patients, only one had received COVID-19 vaccinations, while in the study of Mitra et al, 12.5% of the affected patients were fully vaccinated against COVID-19 and only one patient had received one vaccination shot before the appearance of ROCM symptoms.¹⁵

In our study, the main clinical presentation was OAS followed by OIS, OC, both OC and OAS and the least presentation was SOFS. In the study of Bayram et al,¹⁶ the patients were presented mainly by symptoms of OAS and vision loss as well. They had proptosis, ophthalmoplegia, ptosis, conjunctival hyperemia or chemosis. Endophthalmitis with posterior scleritis was present in more than half of them. Only two patients had retinochoroiditis followed by retinoschisis and only one patient had corneal edema. Notably, we observed that the severity of invasive fungal sinusitis

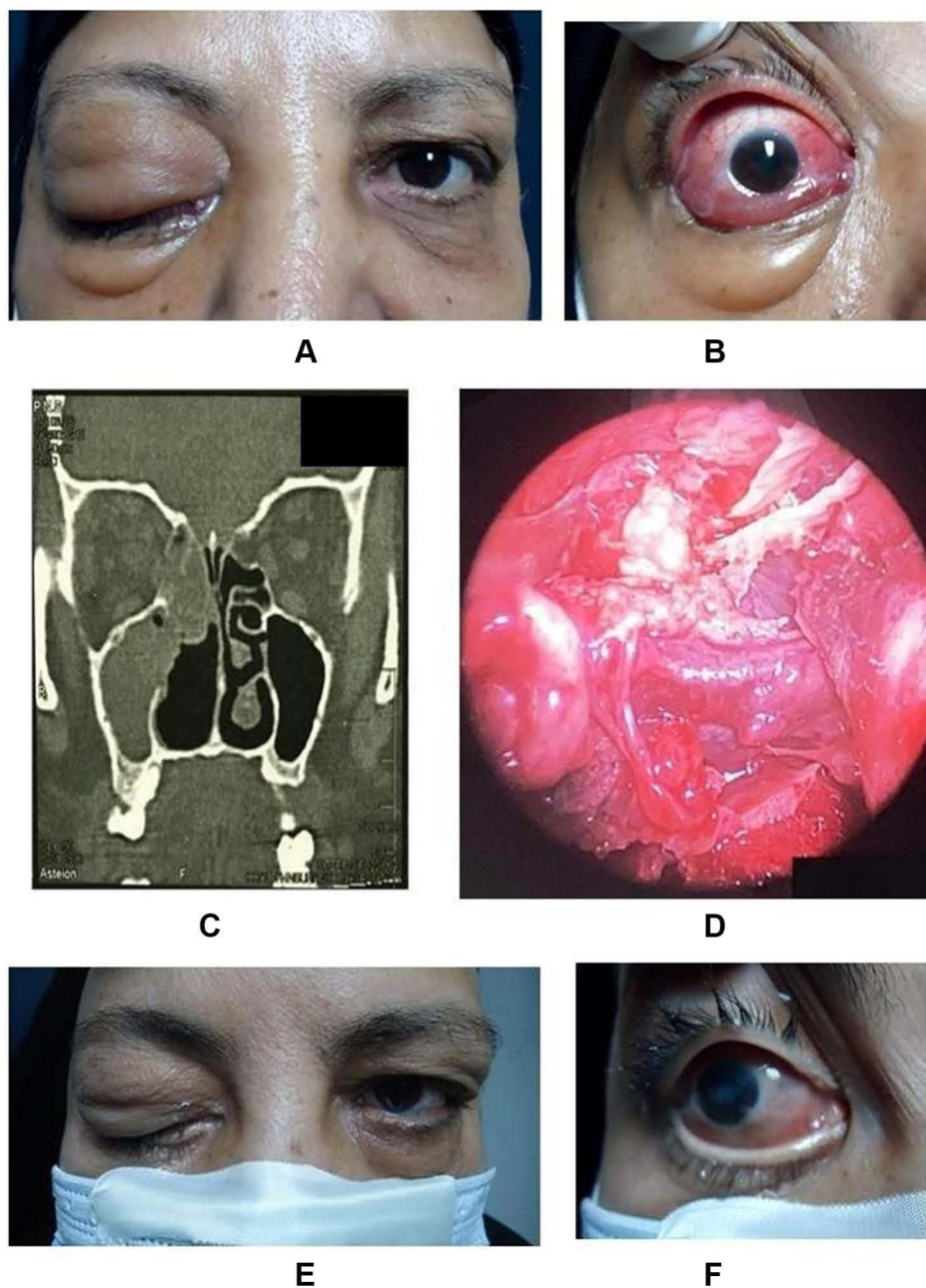


Figure 4 (A and B) A 58-year-old female patient with right combined OC and OAS. **(C)** Coronal CT scan-bone window showed right maxillary and ethmoidal sinusitis with osteomyelitis of the medial orbital wall. **(D)** Endoscopic view of the medial wall of the orbit after debridement of necrotic tissue until healthy bleeding edge was reached. The periorbita was intact. **(E and F)** Four months after retrobulbar Amphotericin B injection, the inflammatory reaction was markedly controlled.

was not always associated with the severity of orbital affection, as some cases presented with mild orbital manifestations despite aggressive sinusitis with tissue necrosis and eschar formation and severe tissue involvement in the CT/MRI scans.

Orbital debridement was helpful to most of our patients to be clinically improved; however, they did not gain any visual improvement. In the study of Mitra et al¹⁵ the majority of the patients underwent FESS with sinus debridement with/without orbital clearance. In some patients, the fungal infection and necrosis had involved the soft tissues of the cheek and eyelids, which had to be debrided as well. Orbital exenteration was required for 25% of their patients.

Many treatment modalities, either medical or surgical, have been tried in patients with ROCM in order to avoid exenteration, which did not improve the overall mortality rates among our patients (4 patients died out of 6 exenterated).

In addition, the multi-centric study of Fouad et al¹³ reported a very high mortality rate (46%) despite surgical intervention.

Joos et al¹⁷ tried a modified technique of daily intraorbital irrigation of Amphotericin B in a 38-year-old diabetic patient with ROMC after orbital and sinus debridement. Not only they avoided exenteration but the patient had excellent cosmetic outcome with final visual acuity of 20/25 as well.

Zhang et al⁴ succeeded to treat two patients with oral posaconazole in conjunction with intravenous (IV) Amphotericin B and sinus surgical debridement. They avoided exenteration in these two patients.

Hirabayashi et al¹⁸ reported the effect of retrobulbar injection of Amphotericin B in another 68-year old immunocompromised ROCM patient. Together with intravenous Amphotericin and endoscopic sinus debridement, retrobulbar injection of Amphotericin B could stop the inflammatory process with resolution of intraorbital edema and optic neuropathy. Their patient regained 6/6 vision in nearly a month.

Murthy et al¹⁹ suggested medial orbital wall decompression as a way to decrease intraorbital pressure in cases with ROCM. They tried it in 36 patients and none of them needed exenteration.

Elkholy et al¹² used both antifungal therapy and surgical intervention, which was tailored to each patient according to the clinical findings and extension of infection. They used all the available endoscopic or open surgical options to improve the clinical outcome of their patients. This could improve the overall mortality but can be sometimes time and money consuming.

Deciding the appropriate management for each patient is difficult most of the times. After prescribing systemic Amphotericin, our algorithm starts by observing how much the orbit is involved and how much the visual acuity is affected. Both of these signs are simple and easy to observe. For cases with severe orbital involvement and orbital infarction confirmed by MRI with contrast, orbital exenteration should be carried out as soon as possible as it may save the patient's life. For patients with extensive orbital involvement but without orbital infarction in the MRI, retro bulbar Amphotericin irrigation should be started immediately. High-risk patients presented by symptoms or signs suggestive of ROCM but still have good visual acuity, no or limited orbital involvement (mild ptosis, incomplete limitation of ocular motility and minimal or no chemosis.), should have early and aggressive debridement of the nasal cavity and paranasal sinuses until healthy tissue is reached. If the patient did not show any clinical improvement with 72 h, retrobulbar Amphotericin irrigation should be carried out with endoscopy or MRI guided debridement and if the patient still did not show any clinical improvement, orbital exenteration should be carried out. If the patient started to show clinical improvement after debridement or retrobulbar Amphotericin irrigation, another round of debridement and sinus irrigation with Amphotericin should be tried to ensure the tissues are clean and fungus free ([Chart 1](#)).

The proposed algorithm is not extremely novel, these are modifications of existing treatment and management guidelines and more studies are needed to confirm this.

Conclusions

Systemic antifungal treatment alone was ineffective in the treatment of ROCM. In most of the patients, the disease was controlled after functional endoscopic sinus surgery (FESS) with extensive debridement of involved necrotic tissues until bleeding healthy tissue was reached. Orbital exenteration was performed whenever the periorbital tissues were involved; however, it did not improve the final cure rate. The proposed algorithm was built to be simple and easy to follow, especially for young and general ophthalmologist and should help them to make a better clinical decision for orbital mucormycosis patients.

Study Limitations

The small sample size due to the limited number of completed medical records and the lack of long follow-up period of the included patients.

Acknowledgments

This submission has not been published anywhere previously and that it is not simultaneously being considered for any other publication.

Funding

This work was self-funded by the authors.

Disclosure

None of the authors have any proprietary interests or conflicts of interest related to this work.

References

1. Spellberg B, Kontoyiannis DP, Fredricks D, et al. Risk factors for mortality in patients with mucormycosis. *Med Mycol*. 2012;50(6):611–618. doi:10.3109/13693786.2012.669502
2. Wali U, Balkhair A, Al-Mujaini A. Cerebro-rhino orbital mucormycosis an update. *J Infect Public Health*. 2012;5(2):116–126. doi:10.1016/j.jiph.2012.01.003.
3. Yohai RA, Bullock JD, Aziz AA, Markert RJ. Survival factors in rhino-orbital-cerebral mucormycosis. *Surv Ophthalmol*. 1994;39(1):3–22. doi:10.1016/s0039-6257(05)80041-4.
4. Zhang J, Kim JD, Beaver HA, Takashima M, Lee AG. Rhino-orbital mucormycosis treated successfully with posaconazole without exenteration. *Neuroophthalmology*. 2013;37(5):198–203. doi:10.3109/01658107.2013.809463
5. Stone N, Gupta N, Schwartz I. Mucormycosis: time to address this deadly fungal infection. *Lancet Microbe*. 2021;2(8):E343–E344. doi:10.1016/S2666-5247(21)00148-8
6. Chavda VP, Apostolopoulos V. Mucormycosis - An opportunistic infection in the aged immunocompromised individual: a reason for concern in COVID-19. *Maturitas*. 2021;154:58–61. doi:10.1016/j.maturitas.2021.07.009
7. Tay MZ, Poh CM, Rénia L, MacAry PA, Ng LFP. The trinity of COVID-19: immunity, inflammation and intervention. *Nat Rev Immunol*. 2020;20(6):363–374. doi:10.1038/s41577-020-0311-8.
8. Lv Z, Cheng S, Le J, et al. Clinical characteristics and co-infections of 354 hospitalized patients with COVID-19 in Wuhan, China: a retrospective cohort study. *Microbes Infect*. 2020;22(4–5):195–199. doi:10.1016/j.micinf.2020.05.007
9. Ferguson BJ. Mucormycosis of the nose and paranasal sinuses. *Otolaryngol Clin North Am*. 2000;33(2):349–365. doi:10.1016/s0030-6665(00)80010-9.
10. Fouad YA, Abdelaziz TT, Askoura A, Saleh MI, Mahmoud MS, Ashour DM, Ashour MM. Spike in rhino-orbital-cerebral mucormycosis cases presenting to a tertiary care center during the COVID-19 pandemic. *Front Med*. 2021;8:645270. doi:10.3389/fmed.2021.645270
11. Alloush TK, Mansour O, Alloush AT, et al. Rhino-orbito-cerebral mucormycosis during the COVID-19 third wave in 2021: an Egyptian preliminary report from a single tertiary hospital. *Neurol Sci*. 2022;43(2):799–809. doi:10.1007/s10072-021-05740-y
12. El-Kholy NA, El-Fattah AMA, Khafagy YW. Invasive fungal sinusitis in post COVID-19 patients: a new clinical entity. *Laryngoscope*. 2021;131(12):2652–2658. doi:10.1002/lary.29632
13. Fouad YA, Bakre HM, Nassar MA, Gad MOA, Shaat AAK. Characteristics and outcomes of a series of COVID-associated mucormycosis patients in two different settings in Egypt through the third pandemic wave. *Clin Ophthalmol*. 2021;15:4795–4800. doi:10.2147/OPHTH.S344937
14. Bayram N, Ozsaygılı C, Sav H, et al. Susceptibility of severe COVID-19 patients to rhino-orbital mucormycosis fungal infection in different clinical manifestations. *Jpn J Ophthalmol*. 2021;65(4):515–525. doi:10.1007/s10384-021-00845-5
15. Sen M, Honavar SG, Bansal R, et al.; Members of the Collaborative OPAI-IJO Study on Mucormycosis in COVID-19 (COSMIC) Study Group. Epidemiology, clinical profile, management, and outcome of COVID-19-associated rhino-orbital-cerebral mucormycosis in 2826 patients in India - Collaborative OPAI-IJO Study on Mucormycosis in COVID-19 (COSMIC), report 1. *Indian J Ophthalmol*. 2021; 69(7):1670–1692. doi:10.4103/ijo.IJO_1565_21
16. Mitra S, Janweja M, Sengupta A. Post-COVID-19 rhino-orbito-cerebral mucormycosis: a new addition to challenges in pandemic control. *Eur Arch Otorhinolaryngol*. 2021;26:1–6. doi:10.1007/s00405-021-07010-1
17. Joos ZP, Patel BC. Intraorbital irrigation of amphotericin B in the treatment of rhino-orbital mucormycosis. *Ophthalmic Plast Reconstr Surg*. 2017;33(1):e13–e16. doi:10.1097/IOP.0000000000000377
18. Hirabayashi KE, Kalin-Hajdu E, Brodie FL, Kersten RC, Russell MS, Vagefi MR. Retrobulbar injection of amphotericin B for orbital mucormycosis. *Ophthalmic Plast Reconstr Surg*. 2017;33(4):e94–e97. doi:10.1097/IOP.0000000000000806.
19. Murthy R, Bagchi A, Gote YS. Role of medial orbital wall decompression in COVID-19-associated rhino-orbital mucormycosis management. *Indian J Ophthalmol*. 2021;69:3795–3796. doi:10.4103/ijo.IJO_1294_21

Clinical Ophthalmology

Dovepress

Publish your work in this journal

Clinical Ophthalmology is an international, peer-reviewed journal covering all subspecialties within ophthalmology. Key topics include: Optometry; Visual science; Pharmacology and drug therapy in eye diseases; Basic Sciences; Primary and Secondary eye care; Patient Safety and Quality of Care Improvements. This journal is indexed on PubMed Central and CAS, and is the official journal of The Society of Clinical Ophthalmology (SCO). The manuscript management system is completely online and includes a very quick and fair peer-review system, which is all easy to use. Visit <http://www.dovepress.com/testimonials.php> to read real quotes from published authors.

Submit your manuscript here: <https://www.dovepress.com/clinical-ophthalmology-journal>