

Received: 2014.01.27
Accepted: 2014.02.17
Published: 2014.05.25

ISSN 1941-5923
© Am J Case Rep, 2014; 15: 230-234
DOI: 10.12659/AJCR.890449

The forgotten disease: Bilateral Lemierre's disease with mycotic aneurysm of the vertebral artery

Authors' Contribution:
Study Design A
Data Collection B
Statistical Analysis C
Data Interpretation D
Manuscript Preparation E
Literature Search F
Funds Collection G

EF 1 **Tanush Gupta**
EF 1 **Kaushal Parikh**
EF 2 **Sonam Puri**
EF 1 **Sahil Agrawal**
E 3 **Nikhil Agrawal**
E 4 **Divakar Sharma**
E 4 **Lawrence DeLorenzo**

1 Department of Internal Medicine, Westchester Medical Center, New York Medical College, Valhalla, NY, U.S.A.
2 Department of Internal Medicine, University of Connecticut, Farmington, CT, U.S.A.
3 Department of Internal Medicine, University of Florida, Gainesville, FL, U.S.A.
4 Department of Pulmonary and Critical Care, Westchester Medical Center, New York Medical College, Valhalla, NY, U.S.A.

Corresponding Author: Tanush Gupta, e-mail: tanushgupta@gmail.com
Conflict of interest: None declared

Patient: Male, 25
Final Diagnosis: Lemierre's disease
Symptoms: Back pain • fever • headache • tachycardia • tachypnoea
Medication: —
Clinical Procedure: —
Specialty: Infectious Diseases

Objective: Rare disease





Background: Lemierre's disease, also known as the forgotten disease, postanginal sepsis, or necrobacillosis, was first reported in 1890 by Courmont and Cade, but it was Dr. Andre Lemierre, a professor of microbiology, who described this disease in 1936. The typical causative agent is *Fusobacterium necrophorum*, although other organisms may be involved. The pathogenesis of Lemierre's disease is not well understood. It is characterized by a primary oropharyngeal infection associated with septicemia, internal jugular vein thrombosis, and metastatic septic emboli.

Case Report: We report a case of Lemierre's disease with bilateral internal jugular vein (IJV) thrombosis and metastatic septic emboli to the lungs and brain, associated with epidural abscess and mycotic aneurysm of the vertebral artery, which is quite rare in Lemierre's disease. This is the first report of a case of Lemierre's disease associated with mycotic aneurysm of the vertebral artery.

Conclusions: Lemierre's disease is a rare and perplexing medical entity. Clinical suspicion should be high in previously healthy young adults presenting with fever and neck pain following oropharyngeal infection. Dr. Lemierre stated that 'symptoms and signs of Lemierre's disease are so characteristic that it permits diagnosis before bacteriological examination'. The prognosis of patients with Lemierre's disease is generally good, provided prompt recognition and appropriate treatment.

MeSH Keywords: Aneurysm • Infected – microbiology • Lemierre Syndrome • Thrombosis

Full-text PDF: <http://www.amjcaserep.com/download/index/idArt/890449>

 1624   2  47

Background

Lemierre's disease, also known as the forgotten disease, post-anginal sepsis, or necrobacillosis, was first reported in 1890 by Courmont and Cade [1], but it was Dr. Andre Lemierre, a professor of microbiology, who described this disease in 1936 [2].

He published a case series of 20 patients with a syndrome characterized by a history of recent oropharyngeal infection, clinical or radiological evidence of internal jugular vein thrombosis, and anaerobic septicemia caused primarily by *Bacillus funduliformis* (now known as *Fusobacterium necrophorum*). Lemierre's disease is now a rare illness with less than 100 cases reported since 1974 [3]. *Fusobacterium* species are responsible for majority of the cases. [4]. *F. necrophorum* is a gram-negative anaerobic rod that is a part of the normal oropharyngeal flora [5]. It is poorly understood what causes this typically non-invasive organism to penetrate mucosal surfaces, but it has been suggested that alteration of pharyngeal mucosa by viral or bacterial pharyngitis may play a role [6]. Before the introduction of antibiotics, Lemierre's disease was frequently encountered and often fatal. The fatality rate in the pre-antibiotic era was close to 90% [7], and has decreased to 15% in the current era of antimicrobials.

Case Report

A 25-year-old man with no past medical history and an unremarkable social history presented to the emergency department (ED) with complaints of scalp and cheek swelling for 2 days. He was evaluated in the ED, prescribed oral antibiotics, and discharged home. He failed to get his prescriptions and 4 days later presented again to the ED with new-onset neck swelling and pain.

On admission, his temperature was 38°C, the heart rate was 115 beats per minute (bpm) with a respiratory rate of 18 per minute and blood pressure of 140/79 mmHg. There was diffuse edematous swelling of the left side of the neck with minimal tenderness. The oropharynx was not infected and there were no obvious dental caries or abscess. The uvula was central in position. The remainder of the examination was unremarkable. Initial investigation revealed a total white count of 27 900/cmm, hemoglobin of 14.4 g/dl, and platelet count of 140 000/cmm. An electrocardiogram revealed sinus tachycardia at 106 bpm with no acute ST – T wave changes. Blood cultures were drawn and the patient was empirically started on ampicillin/sulbactam. On day 1 of admission, a CT scan of the neck/soft tissues was obtained, which showed a retropharyngeal hypodensity representing early abscess formation; near occlusive thrombus of left internal jugular vein extending from jugular foramen to C₄; small non-occlusive thrombus in the right

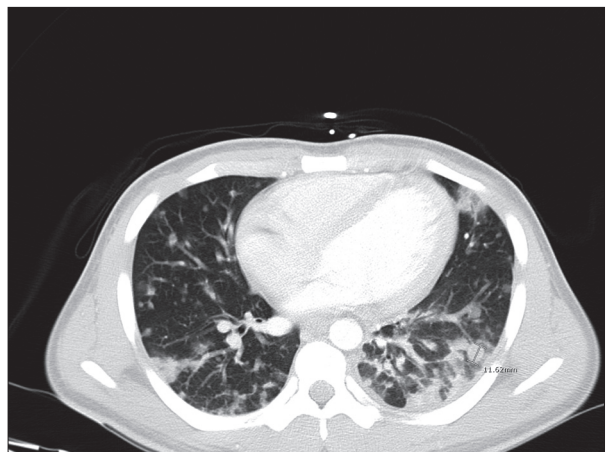


Figure 1. CT Chest with contrast: There are numerous bilateral pulmonary nodules of varying sizes, ranging from under a millimeter to 2.5 cm in the superior segment of the left lower lobe. The more peripheral lesions are larger in size and demonstrate early central cavitation.

internal jugular vein at the C₁ level, and marked dural/epidural enhancement of the cervical spine. He was therefore also started on anticoagulation with unfractionated heparin (UFH). A CT chest/abdomen/pelvis was done, which revealed multiple bilateral pulmonary nodules with signs of early cavitation (Figure 1). Based on the clinical presentation and radiographic findings, the diagnosis of Lemierre's disease was made.

Despite antibiotics, the patient continued to have high-grade fever of 38.9°C. On day 2 of admission, blood cultures revealed *Staphylococcus aureus*, which was subsequently identified as methicillin-resistant *Staphylococcus aureus* (MRSA). Ampicillin/sulbactam was discontinued and patient was started on IV vancomycin (maintaining higher trough levels). A transthoracic echocardiography performed on day 2 of hospitalization did not reveal any valvular vegetation.

The patient complained of persistent headache and back pain. He underwent brain MRI that revealed an ovoid region of T₁ and T₂ prolongation, restricted diffusion, and peripheral enhancement measuring approximately 2.2 cm within the parietal vertex scalp with surrounding soft tissue enhancement suggestive of soft tissue abscess. A CT angiogram of the head/neck revealed focal aneurysmal dilatation of the left vertebral artery at the C₄ level, likely representing a mycotic aneurysm; prevertebral phlegmonous changes with nonocclusive thrombus in the left internal jugular vein; and thrombus extending from left transverse sinus to left sigmoid dural venous sinus (Figure 2). Cervical thoracic lumbosacral spine imaging revealed a large circumferential epidural collection at C₃–C₆ level with near complete effacement of the thecal sac and left ventrolateral epidural abscess extending from T₅–T₇ level measuring 8×14×31 mm with no evidence of spinal cord compression.

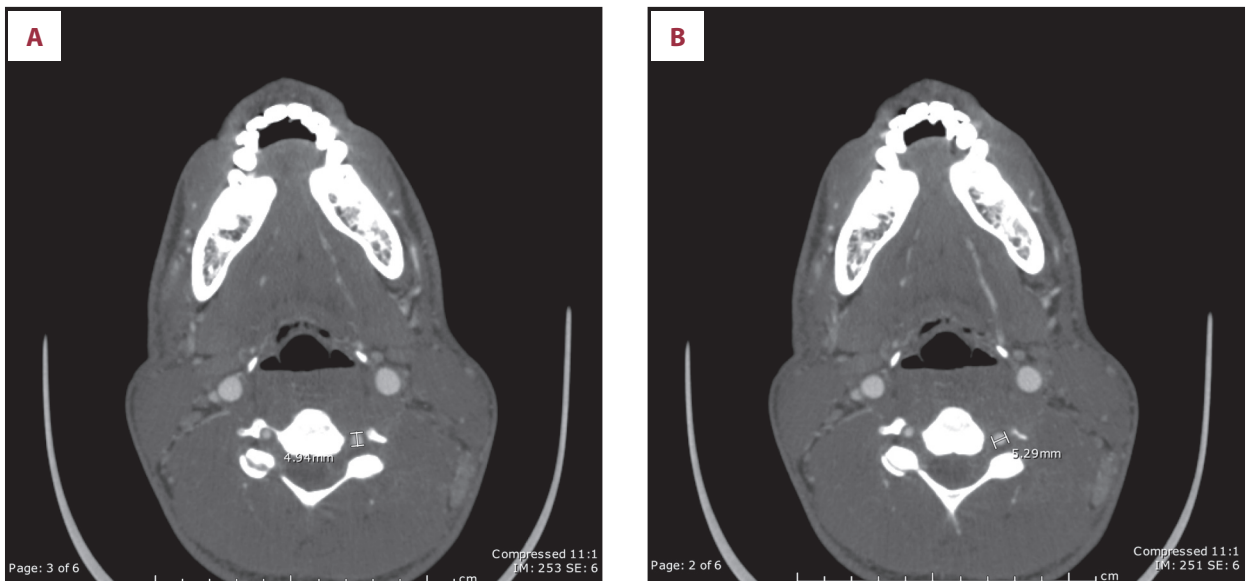


Figure 2. (A, B) CT angio head/neck: There is focal aneurysmal dilatation of the left vertebral artery at the C₄ level; this may be secondary to infectious changes. No definite dissection is seen at this level.

Neurosurgery was consulted and suggested no acute intervention. At the time of discharge, vancomycin was continued for a total of 6 weeks via a peripherally inserted central catheter. UFH was changed to warfarin bridging with low molecular weight heparin (LMWH) until INR was therapeutic.

Discussion

In his original case series, Lemierre stated “The appearance and repetition several days after the onset of a sore throat (and particularly of a tonsillar abscess) of several pyrexial attacks with an initial rigor, or still more certainly the occurrence of pulmonary infarcts and arthritic manifestations, constitute a syndrome so characteristic that mistake is almost impossible” [2]. Currently, Lemierre’s disease is rare. Its incidence has been estimated to be approximately 3.6 cases per million per year [8]. An increase in its incidence has been reported since the 1990s by several authors [8,9] due to increased awareness of the syndrome and more judicious antibiotic use for treatment of bacterial pharyngitis [10]. It primarily affects previously healthy children, adolescents, and young adults [11].

Lemierre’s disease is characterized by a primary oropharyngeal infection associated with septicemia, internal jugular vein thrombosis, and metastatic septic emboli. The lung is the most common metastatic focus. The primary focus of infection in Lemierre’s disease is usually pharyngitis, and rarely other sources like odontogenic infection, sinusitis, mastoiditis, and parotitis [12–14]. The infection then invades the peritonsillar tissue and spreads to the lateral pharyngeal space (containing the jugular vein) via lymphatics causing septic thrombophlebitis.

Diagnostic points favoring Lemierre’s disease are a primary source of infection in the oropharynx, positive blood cultures, radiographic evidence of jugular vein thrombosis, and at least one metastatic focus.

The typical causative agent is the gram-negative anaerobic bacilli *Fusobacterium necrophorum* [15–17], but other organisms like *Streptococcus*, *Staphylococcus* (as demonstrated in our case), *Eikenella*, and *Peptostreptococcus* have also been found. *Fusobacterium* is a commensal organism of the oropharynx, digestive tract, and female genital tract [18]. The cause of transition from commensal to virulent phenotype could be a result of a viral or bacterial throat infection that diminishes local immune defense mechanisms in the oropharynx, thus allowing mucosal bacterial invasion. Subsequent to mucosal invasion, several factors, including hemolysin, lipase, and leukotoxin, contribute to bacterial pathogenicity [19]. Platelet aggregation is a virulent property of *Fusobacterium* that causes thrombocytopenia, disseminated intravascular coagulation, and fibrin deposition [20]. Like *Fusobacterium*, MRSA also has the ability to produce platelet aggregation. Analogy between Pantone-Valentine leukocidin (produced by MRSA) and virulence factor (produced by *Fusobacterium*) is one of the probable explanations for the ability of both these organisms to cause Lemierre’s disease. Spread of the bacteria to the cervical region results in thrombosis of internal jugular vein or one of its tributaries.

Hematogenous seeding of the disease to distant sites occurs following involvement of the internal jugular vein. Lungs are the most common metastatic focus, presenting as necrotic cavitory lesions [19], but cases with pleural effusion, lung abscess, and necrotizing mediastinitis have also been reported

[19,21–24]. The second-most common site of septic embolization is the large joints: shoulders, hips, and knees [24,25]. Although atypical, cases of splenic abscess, liver abscess, renal abscess, hemolytic uremic syndrome, and pericarditis have also been reported [21–24]. Central nervous system (CNS) complications are rare because cerebral veins are located upstream from the IJV. Nonetheless, subdural empyema [26,27], cerebral infarcts [28–30], meningitis [29,31,32], encephalopathy [33], and cavernous sinus thrombosis have been reported, with the probable mechanism being retrograde extension of IJV thrombosis [30,34–42].

First described by Osler in 1885, mycotic aneurysms show a distinct infectious pathologic process [43]. They can develop as a result of: septic emboli, which tend to lodge at branching points of distal vessels, infecting and weakening the arterial wall [44]; contiguous inflammatory processes, which cause an infective aneurysm by involving the vasa vasorum and periarterial lymphatics [44]; or following an iatrogenic vascular complication precipitating infection in the arterial wall [45]. We did an extensive literature search and, to date, mycotic aneurysm of the vertebral artery in association with extensive metastatic seeding secondary to Lemierre's syndrome has never been reported.

Use of anticoagulation in Lemierre's disease remains controversial [46]. The risks and benefits of anticoagulation should always be individualized. Despite inconsistent results in randomized trials, our patient was successfully anticoagulated (thrombosis of cavernous sinus is regarded as an indication for anticoagulation, as demonstrated in our case [34,37], with UFH and later with LMWH and warfarin. Surgical intervention

is considered necessary if there is no evidence of clinical improvement in 48–72 hours. Unlike other cases and review articles on Lemierre's disease, our case consisted of bilateral jugular vein thrombosis with metastases to the lungs, brain, and epidural space with aneurysm of vertebral arteries (such a case has never been reported in the past, but the treatment regimen was more or less the same) and caused by MRSA in an immunocompetent host.

Conclusions

Lemierre's disease is a rare and perplexing medical entity. Clinical suspicion should be high in previously healthy young adults presenting with fever and neck pain following oropharyngeal infection. It is quite possible that the initial oropharyngeal infection could have resolved by the time the patient presents to the hospital, or there could be few or no findings on physical examination. Hence, Lemierre's disease should always be considered as one of the differential diagnoses in a patient with pharyngitis and neck pain, even without the presence of any obvious complications of Lemierre's disease (IJV thrombosis and pulmonary complications). Mycotic aneurysms develop as a result of septic emboli in Lemierre's disease. Prognosis of patients with Lemierre's disease is generally good [24], provided prompt recognition and appropriate treatment.

Acknowledgements

We would like to thank Dr Jalaj Garg for his critical appraisal of the manuscript.

References:

1. Courmont PCA: Sur une septic-pyohemie de l'homme stimulant la peste et cause par un streptobacille anaerobie. Archives de med exp et d'anat path. 1900; 4. [in French]
2. A L. On certain septicemia due to anaerobic organisms. Lancet. 1936; 227: 701–3
3. Singhal A, Kerstein MD: Lemierre's syndrome. South Med J: 2001; 94(9): 886–87
4. Ramirez S, Hild TG, Rudolph CN et al: Increased diagnosis of Lemierre syndrome and other Fusobacterium necrophorum infections at a Children's Hospital. Pediatrics, 2003; 112(5): e380
5. Pett E, Saeed K, Dryden M: Fusobacterium species infections: clinical spectrum and outcomes at a district general hospital. Infection. 2013 [Epub ahead of print]
6. Eilbert W, Singla N: Lemierre's syndrome. Int J Emerg Med, 2013; 6(1): 40
7. Bliss SJ, Flanders SA, Saint S: Clinical problem-solving. A pain in the neck. N Engl J Med, 2004; 350(10): 1037–42
8. Hagelskjaer LH, Prag J, Malczynski J, Kristensen JH: Incidence and clinical epidemiology of necrobacillosis, including Lemierre's syndrome, in Denmark 1990–1995. Eur J Clin Microbiol Infect Dis, 1998; 17(8): 561–65
9. Brazier JS, Hall V, Yusuf E, Duerden BI: Fusobacterium necrophorum infections in England and Wales 1990–2000. J Med Microbiol, 2002; 51(3): 269–72
10. Riordan T, Wilson M: Lemierre's syndrome: more than a historical curiosa. Postgrad Med J: 2004; 80(944): 328–34
11. Benhayoun M, Llor J, Van-Den-Abbeele T et al: [Bilateral jugular thrombosis in Lemierre syndrome]. Arch Pediatr, 2003; 10(12): 1071–74 [in French]
12. Goldenberg NA, Knapp-Clevenger R, Hays T, Manco-Johnson MJ: Lemierre's and Lemierre's-like syndromes in children: survival and thromboembolic outcomes. Pediatrics, 2005; 116(4): e543–48
13. Cook RJ, Ashton RW, Aughenbaugh GL, Ryu JH: Septic pulmonary embolism: presenting features and clinical course of 14 patients. Chest, 2005; 128(1): 162–66
14. Screation NJ, Ravenel JG, Lehner PJ et al: Lemierre syndrome: forgotten but not extinct – report of four cases. Radiology, 1999; 213(2): 369–74
15. Henry S, DeMaria A Jr, McCabe WR: Bacteremia due to Fusobacterium species. Am J Med, 1983; 75(2): 225–31
16. Moore-Gillon J, Lee TH, Eykyn SJ, Phillips I: Necrobacillosis: a forgotten disease. Br Med J (Clin Res Ed), 1984; 288(6429): 1526–27
17. Sinave CP, Hardy GJ, Fardy PW: The Lemierre syndrome: suppurative thrombophlebitis of the internal jugular vein secondary to oropharyngeal infection. Medicine, 1989; 68(2): 85–94
18. Dool H, Soetekouw R, van Zanten M, Grooters E: Lemierre's syndrome: three cases and a review. Eur Arch Otorhinolaryngol, 2005; 262(8): 651–54
19. Hagelskjaer Kristensen L, Prag J: Human necrobacillosis, with emphasis on Lemierre's syndrome. Clin Infect Dis, 2000; 31(2): 524–32
20. Forrester LJ, Campbell BJ, Berg JN, Barrett JT: Aggregation of platelets by Fusobacterium necrophorum. J Clin Microbiol, 1985; 22(2): 245–49

21. Armstrong AW, Spooner K, Sanders JW: Lemierre's Syndrome. *Curr Infect Dis Rep*, 2000; 2(2): 168-73
22. Leugers CM, Clover R: Lemierre syndrome: postanginal sepsis. *J Am Board Fam Pract*, 1995; 8(5): 384-91
23. Hughes CE, Spear RK, Shinabarger CE, Tuna IC: Septic pulmonary emboli complicating mastoiditis: Lemierre's syndrome revisited. *Clin Inf Dis*, 1994; 18(4): 633-35
24. Chirinos JA, Lichtstein DM, Garcia J, Tamariz LJ: The evolution of Lemierre syndrome: report of 2 cases and review of the literature. *Medicine*, 2002; 81(6): 458-65
25. Riordan T: Human infection with *Fusobacterium necrophorum* (Necrobacillosis), with a focus on Lemierre's syndrome. *Clin Microbiol Rev*, 2007; 20(4): 622-59
26. Westhout F, Hasso A, Jalili M et al: Lemierre syndrome complicated by cavernous sinus thrombosis, the development of subdural empyemas, and internal carotid artery narrowing without cerebral infarction. Case report. *J Neurosurg*, 2007; 106(1 Suppl): 53-56
27. Ridgway JM, Parikh DA, Wright R et al: Lemierre syndrome: a pediatric case series and review of literature. *Am J Otolaryngol*, 2010; 31(1): 38-45
28. Marangos MN, Fuchs-Ertman DA, Kourea HP et al: Cerebral infarct and adult respiratory distress syndrome in a patient with postanginal sepsis. *Clin Microbiol Inf*, 2000; 6(6): 337-39
29. Bentham JR, Pollard AJ, Milford CA et al: Cerebral infarct and meningitis secondary to Lemierre's syndrome. *Pediatr Neurol*, 2004; 30(4): 281-83
30. Touitou D, Deltour S, Bonneville F et al: Hemiplegia in Lemierre syndrome: a neuroimaging strategy. *Eur J Neurol*, 2006; 13(4): 424-26
31. Jaremko JL, Kirton A, Brenner JL: A 12-year-old girl with pharyngitis, meningitis and sinovenous thrombosis. *CMAJ*, 2003; 169(8): 811-12
32. van Dijk EJ, van Swieten JC, Koudstaal PJ: Meningitis, cranial nerve palsies and bilateral cerebral infarcts: a neurological variant of Lemierre's syndrome. *J Neurol*, 2008; 255(10): 1588-89
33. Vogel LC, Boyer KM: Metastatic complications of *Fusobacterium necrophorum* sepsis. Two cases of Lemierre's postanginal septicemia. *Am J Dis Child*, 1980; 134(4): 356-58
34. Jones TH, Bergvall V, Bradshaw JP: Carotid artery stenoses and thrombosis secondary to cavernous sinus thromboses in *Fusobacterium necrophorum* meningitis. *Postgrad Med J*, 1990; 66(779): 747-50
35. Stokroos RJ, Manni JJ, de Kruijk JR, Soudijn ER: Lemierre syndrome and acute mastoiditis. *Arch Otolaryngol Head Neck Surg*, 1999; 125(5): 589-91
36. Agarwal R, Arunachalam PS, Bosman DA: Lemierre's syndrome: a complication of acute oropharyngitis. *J Laryngology Otol*, 2000; 114(7): 545-47
37. Hope A, Bleach N, Ghiacy S: Lemierre's syndrome as a consequence of acute supraglottitis. *J Laryngol Otol*, 2002; 116(3): 216-18
38. Brown LM, Wallwork B: Lemierre's - the sinister sore throat. *J Laryngol Otol*, 2007; 121(7): 692-94
39. Repanos C, Chadha NK, Griffiths MV: Sigmoid sinus thrombosis secondary to Lemierre's syndrome. *Ear Nose Throat J*, 2006; 85(2): 98-101
40. Kahn JB, Baharestani S, Beck HC et al: Orbital dissemination of Lemierre syndrome from gram-positive septic emboli. *Ophthal Plast Reconstr Surg*, 2011; 27(3): e67-68
41. Thompson M, Awonuga AO, Bell J et al: Lemierre's syndrome complicating pregnancy. *Infect Dis Obstet Gynecol*, 2007; 2007: 68084
42. Maalikjy Akkawi N, Borroni B et al: Lemierre's syndrome complicated by carotid thrombosis. *Neurol Sci*, 2001; 22(5): 403-4
43. Rhodes EL, Stanley JC, Hoffman GL et al: Aneurysms of extracranial carotid arteries. *Arch Surg*, 1976; 111(4): 339-43
44. Papadoulas S, Zampakis P, Liamis A et al: Mycotic aneurysm of the internal carotid artery presenting with multiple cerebral septic emboli. *Vascular*, 2007; 15(4): 215-20
45. Kaviani A, Ouriel K, Kashyap VS: Infected carotid pseudoaneurysm and carotid-cutaneous fistula as a late complication of carotid artery stenting. *J Vasc Surg*, 2006; 43(2): 379-82
46. Bondy P, Grant T: Lemierre's syndrome: what are the roles for anticoagulation and long-term antibiotic therapy? *Ann Otol Rhinol Laryngol*, 2008; 117(9): 679-83
47. de Lima JE Jr, Levin M: Lemierre's syndrome: post-anginal septicemia. *Pediatr Radiol*, 2003; 33(4): 281-83