

# Endoscopic submucosal dissection: experience in an Australian tertiary center

Prayman T. Sattianayagam<sup>a,b</sup>, Paul V. Desmond<sup>b</sup>, Chatura Jayasekera<sup>b</sup>, Robert Y. Chen<sup>b</sup>

East Kent Hospitals University Foundation Trust, UK; St. Vincent's Hospital, Melbourne, Australia

## Abstract

**Background** Endoscopic submucosal dissection (ESD) is a technique for *en bloc* resection of superficial tumors of the gastrointestinal tract. In contrast to Japan and other Asian countries, few data are available in Western countries. The objective of the current study was to evaluate the experience of ESD in a single Australian tertiary center.

**Methods** The patient features, outcomes and complications of ESD of 20 lesions in 18 patients at a single center between 2008 and 2012, were evaluated retrospectively.

**Results** Twenty lesions, in 18 patients of median age 69.5 years, were resected with ESD. Ten patients had gastric lesions (of whom two had two synchronous lesions), four patients had rectal lesions, one had a colonic lesion, one had a duodenal lesion and two had esophageal lesions. The median (range) lesion size was 2.5 (0.5-6.5) cm. In the entire cohort, *en bloc* resection occurred in 80% cases and complete histological resection was achieved in 60% cases. Significant bleeding requiring repeat endoscopy and transfusion occurred in two cases and microscopic perforation occurred in 1 case. Surgery for unsuccessful ESD was pursued without complication in 6 cases. There were two recurrences during follow up of median 36 months, both of which occurred in cases of gastric ESD and one of which (carcinoid) occurred after surgery.

**Conclusions** ESD appears feasible in an Australian population. It should however be contemplated in carefully selected patients whilst there is refinement of pre-treatment diagnosis, the ESD technique and the management of its complications.

**Keywords** Endoscopic submucosal dissection, *en bloc* resection, perforation

*Ann Gastroenterol* 2014; 27 (3): 212-218

## Introduction

Endoscopic submucosal dissection (ESD) was first performed in Japan [1]. In a similar manner to endoscopic mucosal resection (EMR) [2], the aim of ESD is to treat gastrointestinal (GI) mucosal neoplasia. The principles for both techniques revolve around mucosal separation of a GI lesion from the muscularis propria with fluid lifting and

cushioning. However, the methodology of cutting the lesion differs between the two techniques.

With EMR, there is submucosal injection under the lesion and either snare resection or suction of the lesion into a cap on the endoscope followed by snare resection. Resection of lesions less than 2 cm can be achieved *en bloc* with this technique. However lesions larger than 2 cm in size are in general removed in a piecemeal fashion. In the event of piecemeal resection, it is difficult to accurately assess the histological clearance and there is a higher risk of local recurrence [3].

With ESD technique, there is use of a dissecting knife after submucosal injection. The dissecting knife is in general a fine electrocautery metal needle that may or may not have a ceramic cap to prevent perforation. ESD provides the ability to resect larger (>2 cm) GI neoplasms *en bloc*, which would otherwise require piecemeal resection via EMR technique. This ability to remove the lesion *en bloc* provides its major perceived advantage of precise histological assessment allowing assessment of the depth and margin of resection. In addition, there are consequently fewer local recurrences [4,5]. This technique was initially developed to treat early gastric neoplasms and has subsequently become

Departments of Gastroenterology <sup>a</sup>East Kent Hospitals University Foundation Trust, UK (Prayman T. Sattianayagam); <sup>b</sup>St. Vincent's Hospital, Melbourne, Australia (Prayman T. Sattianayagam, Paul V. Desmond, Chatura Jayasekera, Robert Y. Chen)

This work was carried out in the Department of Gastroenterology, St. Vincent's Hospital, Melbourne, Australia

Conflict of Interest: None

Correspondence to: Dr Robert Y. Chen, Department of Gastroenterology, Level 4, Daly Wing, St. Vincent's Hospital, Melbourne 3065, Australia, Tel.: +61 39 2882581, Fax: +61 21 39 2883590, e-mail: robert.chen@svhm.org.au

Received 1 December 2013; accepted 7 March 2014

the standard of care for such pathology in Japan. It has now evolved into a technique which can be performed throughout the GI tract [3].

Most of the data regarding ESD in the literature is from Japan and Korea where this technique was developed and refined [6-9]. Little data exists in Western populations and to date no data has been published in an Australian population [3]. We review the patient demographics, outcomes and complications of ESD in the largest single-center Australian case series reported to date. This includes esophageal, gastric, duodenal and colorectal ESD.

## Patients and methods

### Patient selection

ESD was performed in 18 patients at St Vincent's Hospital in Melbourne, Australia between April 2008 and October 2012 by a single endoscopist (R.C.). Informed consent was obtained prior to the procedure in all patients. The indication in each patient was according to consensus Japanese statements [3]. All patients were evaluated as having superficial tumors prior to ESD as outlined below. All therapeutic options and potential complications were explained to each patient. The study was approved as a Quality Assurance exercise by the Human Research and Ethics Committee of St. Vincent's Hospital.

### Pre-ESD assessment

All patients had an endoscopic procedure to assess the lesion being considered for ESD prior to an attempt at resection using a single-channel gastroscope for upper GI lesions or a colonoscope for lower GI lesions (Olympus HD-180). In preparation for the endoscopic procedures, patients fasted overnight and for colonoscopy two sachets of polyethylene glycol were given over the 24 h beforehand. During the initial assessment lesion morphology was assessed according to Paris and Kudo classifications and biopsies were taken [10,11]. Staging was also performed prior to consideration of ESD with endoscopic ultrasound (to assess T-staging and presence of nodal spread) and cross-sectional CT scanning to assess loco-regional spread. All procedures were performed with anesthetic support and all patients were intubated for upper GI ESD.

### ESD technique

The ESD technique involved a sequence of steps:

Step 1: Initially there was careful inspection of the lesion to determine the margins.

Step 2: Marking of the borders of the lesion to be resected was performed using pulsed argon plasma coagulation, a dual knife (Olympus KD-650L) or a needle knife (Olympus KD-11Q-1)

(ICC 200 ERBE, Tübingen, Germany - coagulation setting at 20W).

Step 3: Repeated submucosal fluid injection to form a cushion. This was followed by pre-cut around the lesion to separate the lesion from the surrounding normal mucosa. The fluid type used for injection was gelofusine mixed with methylene blue. In order to maintain longer lift times Synvisc-One (hyaluronic acid) was used in some cases [12]. Circumferential incision was predominantly performed with the Olympus IT knife (Olympus KD-611L) but also with other knives such as the dual, hook (Olympus KD-620QR), flex knives (Olympus KD-630L) or the hybrid water-jet in some cases (Rymed 20150-060) (60–80W endocut mode effect 3, cutting duration 3 and cutting interval 3; ICC 200 ERBE, Tübingen, Germany).

Step 4: Submucosal dissection was performed under the base of the lesion. This involved repeat submucosal injection of the same injection fluid and then a process of careful dissection under the base of the lesion predominantly using the Olympus IT knife or alternatively a hook knife or dual knife (60–80W endocut mode effect 3, cutting duration 3 and cutting interval 3; ICC 200 ERBE, Tübingen, Germany).

Step 5: Hemostasis of bleeding vessels complicating the ESD procedure was achieved with injection of 1:10,000 adrenaline and/or use of a coagulation grasper (Olympus FD-410LR) (80W soft coagulation setting, ICC 200 ERBE, Tübingen, Germany) and/or gold probe (Boston Scientific 6015). In areas suspicious for potential perforation resolution clips (Boston Scientific M00522601) were deployed.

All patients were admitted overnight after the procedure and in the patients who underwent upper GI ESD, high-dose proton pump inhibitor was commenced.

### Pathological review

All pathological specimens were reviewed by our institution's expert GI pathologists including assessment for clearance of both vertical and lateral margins.

### Endoscopic outcomes

*En bloc* resection was defined as when a lesion was removed in one piece. A successful histological resection (R0) was one where the lesion was removed with clear vertical and lateral margins. Curative resection was defined as tumor-free vertical or lateral margins in a resected lesion and absence of vascular or lymphatic involvement. It was also defined by invasion <1000 µm, <500 µm and <200 µm from the muscularis mucosa in colorectal, gastric and esophageal ESD respectively [13]. Significant bleeding was defined as that requiring blood transfusion and repeat endoscopy after the ESD procedure. A perforation was confirmed by radiological (CT) evidence of a perforation.

## Follow-up

All patients, except two who were lost to follow-up, had follow-up endoscopy usually at 3-6 monthly intervals to assess for local recurrence of tumor including re-biopsy of the area where ESD was performed.

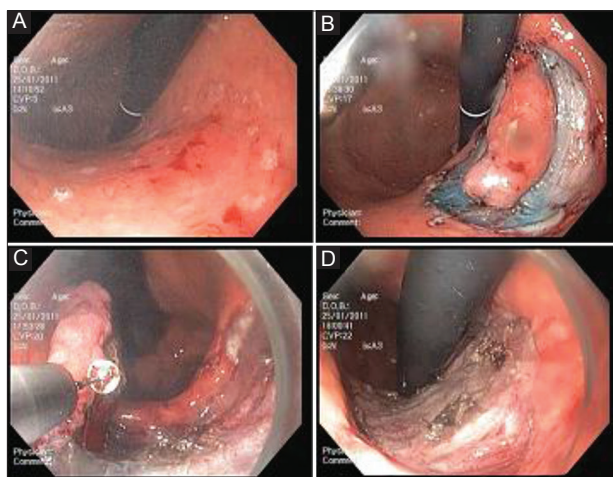
## Results

There were 20 lesions in 18 patients, resected with ESD. The median (range) age of the patients was 69.5 (31-86) years (Table 1). There were twelve gastric lesions, five colorectal lesions, one duodenal lesion and two esophageal lesions. In the entire cohort, *en bloc* resection was achieved in 16/20 (80%) cases and R0 resection achieved in 12/20 (60%) cases. Significant bleeding requiring repeat endoscopy and transfusion occurred in 2/20 (10%) cases and perforation occurred in 1/20 (5%) cases. Six patients, five of whom did not have R0/curative resections, went on to have surgery. No patient died during follow up of median (range) 36 (1-53) months.

### Gastric ESD

#### Clinical features of patients with gastric ESD

There were 12 gastric lesions in 10 patients resected with ESD (Fig. 1). The median (range) age of these patients was 75 (43-86) years. The median (range) follow-up, excluding one patient who was lost to follow-up, was 32 (1-49) months. Two patients had two synchronous lesions in the stomach. There were seven antral lesions, four lesions were in the body of the



**Figure 1** (A) Marking around the circumference of a low-grade dysplastic polyp in the gastric body. (B) Endoscopic submucosal dissection of the lesion revealing methylene blue injectate in the submucosal plane. (C) Lifting of the lesion off the submucosal plane. (D) Mucosal defect after polypectomy

stomach and one was in the fundus. The median (range) size of these lesions was 2.5 (1.5-6.5) cm. There was a prior attempt at resection by EMR in one patient. Histological analysis of the ESD specimens revealed four dysplastic polyps (two low-grade and two high-grade), five adenocarcinomas, two carcinoid lesions and one hamartomatous polyp.

### Patient outcomes in patients with gastric ESD

Of the twelve lesions resected with ESD, *en bloc* resection was achieved in eight lesions (67%) and R0 resection in six cases (50%). *En bloc*, but not R0, resection was achieved in patients with an adenocarcinoma and carcinoid. The patient with an adenocarcinoma was not fit enough for chemotherapy, but, despite this, had no evidence of recurrence 19 months after ESD and the patient with carcinoid proceeded to a subtotal gastrectomy without recurrence during follow-up of 42 months. There were two recurrences; 12 months after ESD in one patient with a hamartomatous polyp, initially deemed to be a R0 resection, and also in a patient with gastric carcinoid, which bled during ESD and therefore the procedure was terminated. ESD was also unsuccessful in three other patients, who had the largest lesions (measuring 5, 6 and 6.5 cm).

### Complications

There was delayed bleeding in 2 patients requiring a further gastroscopy within 3 days but in only one case was hemostasis required at the ESD defect. Clips were applied to an area of deep dissection in one patient.

### Non-gastric ESD

There were 4 patients who had rectal ESD aged 31, 60, 63 and 65 years. They had polyps of size 0.5, 4, 2 and 5 cm respectively. The youngest had carcinoid and the others had an adenocarcinoma and two dysplastic polyps. Two of these patients had prior resection attempts with EMR. *En bloc* and R0 resections were successfully achieved in all four cases with no evidence of recurrence on follow-up. All had mild bleeding at the time of ESD, successfully managed with a coagulation grasper, without evidence of delayed bleeding. One patient had a small perforation, treated conservatively.

There was a 1.5 cm descending colon lesion in one patient, resected *en bloc*, but this was not a R0 resection. She was not fit enough for surgery or chemotherapy but had no recurrence 34 months after ESD. There was a dysplastic duodenal polyp in one patient, resected *en bloc*, and which was a R0 resection with no recurrence 35 months after ESD. Esophageal ESD was performed in two patients with *en bloc* resection in both but a R0 resection only in one patient with no evidence of recurrence 44 months after ESD. The other had a clip applied at an area of deep dissection. He required a laparoscopic esophagectomy as histologically resection was incomplete.

**Table 1** Clinical features and outcomes of the ESD cases

Patient/ Sex <sup>a</sup> /Age	Co-morbidities <sup>b</sup>	Reason for ESD	Site/ Procedure time (min)	Size (cm)/ <i>En-bloc</i> removal <sup>c</sup>	Histology <sup>d</sup>	Invasion depth (µm) <sup>e</sup> / Lymphatic or venous permeation <sup>f</sup>	R0 resection <sup>g</sup>	Complication/ Treatment	Outcome
1/M/86	COPD	Co-morbidity	Gastric antrum/85	2/Y	A	<500/N	Y		Lost to follow-up
2/F/76		Preference to surgery	Gastric antrum/250	3.5×2/Y	HP	<500/N	Y		Recurrence after 12 months
3/M/70	CVA IHD Bladder cancer	Co-morbidity	Gastric body/150	5/N	A	>500/Y	N	Area of deep dissection/ Clips	Subtotal gastrectomy
4/M/43		Preference to surgery	Gastric antrum/100	1.5/Y	C	>500/Y	N	Bleeding/ Repeat gastroscopy, no hemostasis	Subtotal gastrectomy
5/M/71	Prostate cancer	Preference to surgery	Gastric body/150	6/N	A	>500/Y	N		Total gastrectomy
6/F/63		Preference to surgery	Gastric body/115	1.5/N	C	>500/Y	N	Bleeding/ Heater probe+ adrenaline	Partial gastrectomy Recurrent carcinoid 13 months after surgery
7/M/75	-	Preference to surgery	Gastric fundus/180	5×8/N	LGD	>500/Y	N		Partial gastrectomy
8/M/80	IHD COPD	Co-morbidity	1) Gastric body/250 2) Gastric antrum/150	1) 2.5/Y 2) 3×1.5/Y	A A	<500/N <500/N	1) Y 2) Y		No recurrence 19 months after ESD
9/M/78	IHD	Co-morbidity	Gastric antrum/210	3.5×2.5/Y	LGD	<500/N	Y		No recurrence 28 months after ESD
10/F/81	IHD	Co-morbidity	1) Gastric antrum/125 2) Gastric antrum/135	1) 5×3/Y 2) 5×4/Y	HGD HGD	<500/N <500/N	Y Y		No recurrence 1 month after ESD
11/M/31		To ensure resection of residual polyp after previous EMR	Rectal/110	0.5/Y	C	<1000/N	Y		No recurrence 29 months after ESD
12/F/60	Multiple abdominal surgeries	Co-morbidity/ Multiple abdominal operations	Rectal/225	4/Y	A	<1000/N	Y	Perforation/ Conservative management	No recurrence 47 months after ESD
13/F/63		Preference to surgery	Rectal/90	2/Y	HGD	<1000/N	Y		No recurrence 39 months after ESD
14/M/65		Preference to surgery	Rectal/190	6×4/Y	LGD	<1000/N	Y		Lost to follow-up
15/M/79	COPD Bronchiectasis IHD	Co-morbidity	Descending colon/120	1.5/Y	A	>1000/Y	N		No recurrence 34 months after ESD

Contd...

Table 1 *Contd...*

Patient/ Sex <sup>a</sup> /Age	Co-morbidities <sup>b</sup>	Reason for ESD	Site/ Procedure time (min)	Size (cm)/ <i>En-bloc</i> removal <sup>c</sup>	Histology <sup>d</sup>	Invasion depth (µm) <sup>e</sup> / Lymphatic or venous permeation <sup>f</sup>	R0 resection <sup>g</sup>	Complication/ Treatment	Outcome
16/M/69	Renal disease	Co-morbidity	Duodenum/90	0.5/Y	LGD		Y	Area of deep dissection/ Clips	No recurrence 35 months after ESD
17/M/66		Preference to surgery	Esophagus/230	2×1/Y	A	>200/N	N	Area of deep dissection/ clips	Laparoscopic esophagectomy
18/F/58		Preference to surgery	Esophagus/125	1/Y	A	<200/N	Y		No recurrence 43 months after ESD

<sup>c</sup>from the muscularis mucosa

<sup>a</sup>M, Male; F, Female; <sup>b</sup>COPD, Chronic obstructive pulmonary disease; CVA, Cerebrovascular accident; IHD, Ischemic heart disease; <sup>e,f</sup>Y, Yes, N, No;

<sup>d</sup>A, Adenocarcinoma; HP, Hamartomatous polyp; C, Carcinoid; LGD, low-grade dysplasia; HGD, High-grade dysplasia

## Discussion

ESD is a well-established endoscopic technique for the treatment of larger (>2 cm) mucosal neoplasms throughout the GI tract. Its use has been mainly in the stomach, in which setting it is the standard of care in countries such as Japan where gastric neoplasms are prevalent, but it has also been applied to the esophagus, colon and rectum. A recent meta-analysis comparing EMR versus ESD for resection of superficial GI lesions found that ESD had higher *en bloc* and curative resection rates irrespective of lesion size. However ESD was more time-consuming than EMR and showed more procedure-related bleeding and higher perforation rates [14]. The potential benefits of ESD therefore need to be carefully weighed up against possible complications, especially as there have been improvements in surgical techniques for GI lesions which have reduced morbidity and mortality [15].

However the option of ESD is attractive as it removes superficial tumors without the need for surgery, which is particularly beneficial in those who are older or those who have co-morbidities, both of which would increase operative risk. It may also be beneficial in those who have had prior abdominal surgery, possibly rendering surgery for GI lesions technically difficult. These represent some of the reasons for pursuing ESD in the cases in the current series where consensus criteria for ESD were met [3] and where the merits of ESD were weighed up against surgical risks. The current series is the only series from Australia, incorporating all of esophageal, gastric (antral, body and fundus), duodenal and colorectal ESD. The *en bloc* and R0 resection rates of 80% and 60% are not quite as good as the respective 77-92% and 73-100% in other Western series [16-18]. The main reason *en bloc* resection was not achieved in the current series was large lesion size (>5 cm in 3 patients) and severe bleeding in one patient with gastric carcinoid. The bleeding and perforation rates of 10 and 5% respectively however appear better than those from other series with respective rates of 5-12% and 8-20% [16-18]. The combination of a learning curve in ESD and attempts at resecting larger lesions in the stomach

in the current series may account for the difference in resection rates when compared to other series and the lower complication rates may suggest a more cautious approach. One stumbling block to the Western learning curve is the lower incidence of gastric lesions compared to esophageal and colonic lesions in the West but this has slowly improved with increased exposure [19,20]. However, with careful selection of cases, appropriate training, mentorship and visits to expert centers there is scope for the introduction of ESD to the West [21].

ESD for gastric lesions is well established. According to the Japanese Gastric Cancer Association the absolute indication is non-ulcerated, well differentiated-type mucosal carcinoma that measures ≤2 cm (Japanese Gastric Cancer Association 2011). The 67% *en bloc* resection rate and 50% R0 resection rate for gastric ESD in this series is less than the 79-90% and 64-89% respectively in the Western literature [22,23] or the 83-98% and 80-93% respectively observed in the Eastern literature [3]. The four patients with antral lesions had *en bloc* and R0 resections and no evidence of recurrence on follow-up. There is evidence that rates of curative *en bloc* resection are better and procedure times and perforation rates lower in the lower than in the middle and upper parts of the stomach [2]. The unsuccessful gastric ESD cases in the series were the three largest lesions and one case of gastric carcinoid, which bled at the time of ESD. The complication profile in the current gastric series is quite comparable to the Eastern and Western literature [9,22,23].

In the current series there were 8 non-gastric indications for ESD. All 5 cases of colorectal ESD were successful with *en bloc* and R0 resection and no evidence of recurrence on follow-up in all. Colorectal ESD is technically more challenging than other forms of ESD due to larger lesion size and the thinner wall of the colon with potential for a higher perforation rate. There can also be less scope control with more proximal lesions [24]. One meta-analysis of colorectal ESD highlighted *en bloc* and R0 resection rates of 85% and 75% respectively. These results compare well to *en bloc* and R0 resections achieved by EMR, reported to be between 7% and 34% for the treatment of similar large sessile polyps [25]. Complication rates for colorectal ESD

in the literature have been reported as 0-2% for bleeding and 5-8% for perforations [3]. The numbers of esophageal and duodenal ESD in this series were too small to make comparative inferences from. The absolute indication for esophageal ESD according to the Japanese Esophageal Society Guidelines includes intraepithelial cancer with lateral extension of lesions <2/3 of the luminal circumference [3]. *En bloc* and histological curative resection rates in the literature are 95-100% and 78-97% respectively. Complication rates in the same group have been reported as 0% for significant bleeding, 3-7% for perforation and 0-18% for strictures requiring dilatation [3]. Duodenal pathology is a relatively rarer indication for ESD and appears to be associated with more complications than other forms of ESD [26].

In conclusion, most series of ESD are from Eastern countries, such as Japan and Korea. There have been a few single-center series of ESD from the West but the current series of ESD is the only one from Australia described to date. Gastric lesions, as in the East, were the commonest indication. The endoscopic and histological curative resection rates of the present series were not as good as some other series, which in part may be accounted for by the learning curve of performing ESD and by the fact that some of the unresected lesions were large. The complication rates were however comparable. Colorectal ESD

was next commonest followed by esophageal and duodenal ESD and in these forms of ESD the endoscopic and histological curative resection rates and complications were comparable to other series. This series highlights the feasibility of ESD in an Australian population in curing superficial tumors without the need for surgery. It also highlights the stumbling blocks, which no doubt could be extrapolated to other Western centers beginning to introduce ESD.

## Acknowledgements

We wish to acknowledge the kind assistance of the staff of the Day Procedures Unit and the Department of Anatomical Pathology, St. Vincent's Hospital.

## References

1. Gotoda T, Kondo H, Ono H, et al. A new endoscopic mucosal resection procedure using an insulation-tipped electrosurgical knife for rectal flat lesions: report of two cases. *Gastrointest Endosc* 1999;**50**:560-563.
2. Ono H, Kondo H, Gotoda T, et al. Endoscopic mucosal resection for treatment of early gastric cancer. *Gut* 2001;**48**:225-229.
3. Yamamoto H. Endoscopic submucosal dissection-current success and future directions. *Nat Rev Gastroenterol Hepatol* 2012;**9**:519-529.
4. Ishihara R, Iishi H, Takeuchi Y, et al. Local recurrence of large squamous-cell carcinoma of the esophagus after endoscopic resection. *Gastrointest Endosc* 2008;**67**:799-804.
5. Ishihara R, Iishi H, Uedo N, et al. Comparison of EMR and endoscopic submucosal dissection for *en bloc* resection of early esophageal cancers in Japan. *Gastrointest Endosc* 2008;**68**:1066-1072.
6. Fujishiro M, Yahagi N, Kakushima N, et al. Endoscopic submucosal dissection of esophageal squamous cell neoplasms. *Clin Gastroenterol Hepatol* 2006;**4**:688-694.
7. Tanaka S, Oka S, Kaneko I, et al. Endoscopic submucosal dissection for colorectal neoplasia: possibility of standardization. *Gastrointest Endosc* 2007;**66**:100-107.
8. Watanabe K, Ogata S, Kawazoe S, et al. Clinical outcomes of EMR for gastric tumors: historical pilot evaluation between endoscopic submucosal dissection and conventional mucosal resection. *Gastrointest Endosc* 2006;**63**:776-782.
9. Chung IK, Lee JH, Lee SH, et al. Therapeutic outcomes in 1000 cases of endoscopic submucosal dissection for early gastric neoplasms: Korean ESD Study Group multicenter study. *Gastrointest Endosc* 2009;**69**:1228-1235.
10. The Paris endoscopic classification of superficial neoplastic lesions: esophagus, stomach, and colon: November 30 to December 1, 2002. *Gastrointest Endosc* 2003;**58**:S3-S43.
11. Kudo S, Hirota S, Nakajima T, et al. Colorectal tumours and pit pattern. *J Clin Pathol* 1994;**47**:880-885.
12. Uraoka T, Kawahara Y, Ohara N, et al. Carbon dioxide submucosal injection cushion: an innovative technique in endoscopic submucosal dissection. *Dig Endosc* 2011;**23**:5-9.
13. Asano M. Endoscopic submucosal dissection and surgical treatment for gastrointestinal cancer. *World J Gastrointest Endosc* 2012;**4**:438-444.
14. Cao Y, Liao C, Tan A, Gao Y, Mo Z, Gao F. Meta-analysis of endoscopic submucosal dissection versus endoscopic mucosal

### Summary Box

#### What is already known:

- Endoscopic submucosal dissection (ESD) is advantageous over endoscopic mucosal resection as it allows *en bloc* resection of gastrointestinal neoplasms
- Most data on the technique are from Japan and Korea, where it was developed and refined, and has now become the standard of care for gastric neoplasms, more prevalent in the East
- Data from the West is in the form of small series and there is no data to date from Australia

#### What the new findings are:

- Gastric lesions are the major indication for ESD in an Australian population, with endoscopic and histological curative rates not quite as good as that quoted in the literature. This is perhaps related to a combination of the learning curve with the technique and the large size of the resected lesions
- Esophageal, duodenal and colorectal ESD in an Australian population have comparable endoscopic and histological curative rates to other series from the literature
- There is feasibility for ESD use in Australia in curing superficial tumors without need for surgery

- resection for tumors of the gastrointestinal tract. *Endoscopy* 2009;**41**:751-757.
15. Kim KH, Kim MC, Jung GJ, Kim HH. Long-term outcomes and feasibility with laparoscopy-assisted gastrectomy for gastric cancer. *J Gastric Cancer* 2012;**12**:18-25.
  16. Coda S, Trentino P, Antonellis F, et al. A Western single-center experience with endoscopic submucosal dissection for early gastrointestinal cancers. *Gastric Cancer* 2010;**13**:258-263.
  17. Farhat S, Chaussade S, Ponchon T, et al. Endoscopic submucosal dissection in a European setting. A multi-institutional report of a technique in development. *Endoscopy* 2011;**43**:664-670.
  18. Hulagu S, Senturk O, Aygun C, et al. Endoscopic submucosal dissection for premalignant lesions and noninvasive early gastrointestinal cancers. *World J Gastroenterol* 2011;**17**:1701-1709.
  19. Neuhaus H. Endoscopic submucosal dissection in the upper gastrointestinal tract: present and future view of Europe. *Dig Endosc* 2009;**21**(Suppl 1):S4-S6.
  20. Probst A, Golger D, Arnholdt H, Messmann H. Endoscopic submucosal dissection of early cancers, flat adenomas, and submucosal tumors in the gastrointestinal tract. *Clin Gastroenterol Hepatol* 2009;**7**:149-155.
  21. Coman RM, Gotoda T, Draganov PV. Training in endoscopic submucosal dissection. *World J Gastrointest Endosc* 2013;**8**:369-378.
  22. Schumacher B, Charton JP, Nordmann T, Vieth M, Enderle M, Neuhaus H. Endoscopic submucosal dissection of early gastric neoplasia with a water jet-assisted knife: a Western, single-center experience. *Gastrointest Endosc* 2012;**75**:1166-1174.
  23. Dinis-Ribeiro M, Pimentel-Nunes P, Afonso M, Costa N, Lopes C, Moreira-Dias L. A European case series of endoscopic submucosal dissection for gastric superficial lesions. *Gastrointest Endosc* 2009;**69**:350-355.
  24. Deprez PH, Bergman JJ, Meisner S, et al. Current practice with endoscopic submucosal dissection in Europe: position statement from a panel of experts. *Endoscopy* 2010;**42**:853-858.
  25. Puli SR, Kakugawa Y, Saito Y, Antillon D, Gotoda T, Antillon MR. Successful complete cure *en bloc* resection of large nonpedunculated colonic polyps by endoscopic submucosal dissection: a meta-analysis and systematic review. *Ann Surg Oncol* 2009;**16**:2147-2151.
  26. Matsumoto S, Miyatani H, Yoshida Y. Endoscopic submucosal dissection for duodenal tumors: a single-center experience. *Endoscopy* 2013;**4**:136-137.