

Case
Report

Successful Surgical Closure of an Esophagobronchial Fistula Caused by a Foreign Body in the Esophagus of a Female Octogenarian with a Delayed Diagnosis: A Case Report

Takahiro Yanagihara, MD,¹ Hideo Ichimura, MD,^{1,2} Keisuke Kobayashi, MD,¹
and Yukio Sato MD²

Esophagobronchial fistula (EBF) caused by an esophageal foreign body is rare in adults. All surgical interventions in the reported cases were performed via right thoracotomy. We have successfully treated an 88-year-old woman with EBF caused by a thick 2 × 2 cm piece of cake decorating paper that was swallowed accidentally. There was a 2-month interval between ingestion of the foreign body and correct diagnosis. The bronchial opening of the EBF was on the cephalic wall of the proximal left main bronchus (LMB), so we planned a primary repair of the bronchial wall with sutures via left thoracotomy. We performed a division of the fistula and primary closure of the openings on the esophageal and bronchial walls and covered the suture sites with an intercostal muscle flap and pericardial fat, respectively. The patient resumed oral intake on postoperative day 11 and was subsequently transferred to other hospital for rehabilitation.

Keywords: esophagobronchial fistula, esophageal foreign body, surgical repair, thoracotomy, pedicled flap

Introduction

Benign esophagobronchial fistula (EBF) in adults is rare and may be secondary to trauma, infection, chemical injury, iatrogenic injury, or a foreign body.¹⁾ A bronchial foreign body in adults usually causes noticeable symptoms

¹Department of Thoracic Surgery, Hitachi General Hospital, Hitachi, Ibaraki, Japan

²Department of Thoracic Surgery, Faculty of Medicine, University of Tsukuba, Tsukuba, Ibaraki, Japan

Received: March 23, 2018; Accepted: May 6, 2018

Corresponding author: Hideo Ichimura, MD. Department of Thoracic Surgery, Faculty of Medicine, University of Tsukuba, Hitachi Medical Education and Research Center, 2-1-1 Jyounan, Hitachi, Ibaraki 317-0077, Japan
Email: ichimura@md.tsukuba.ac.jp



This work is licensed under a Creative Commons Attribution-NonCommercial-NoDerivatives International License.

©2021 The Editorial Committee of *Annals of Thoracic and Cardiovascular Surgery*

that result in early retrieval, so all reported foreign bodies causing EBF except for therapeutic stents have been esophageal.^{2,3)} An esophageal foreign body resulting from unintentional ingestion could be overlooked in the elderly if the history is ambiguous and symptoms are nonspecific. We have encountered a case of EBF attributable to a long-lodged esophageal foreign body in an elderly woman who was successfully treated by surgery.

Case Report

Two months before diagnosis of EBF, an 88-year-old woman who was independent of activities of daily living noticed that she had accidentally ingested something hard while eating a piece of cake. She had a full upper denture, had never smoked, was a hepatitis C carrier, and had hypertension but no dementia. A month after the accidental ingestion, she complained of difficulty swallowing and cough that worsened on swallowing. She was admitted to a local hospital where she was diagnosed to

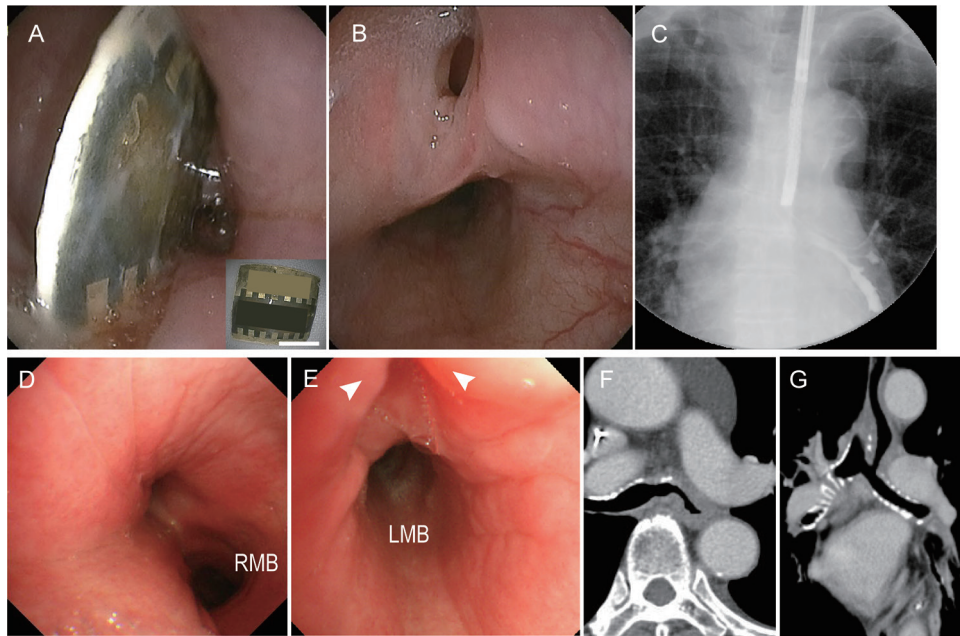


Fig. 1 (A) Upper endoscopy shows a foreign body lodged in the esophagus. The inset is a photograph of the foreign body, which was a piece of thick paper measuring 2×2 cm. (B) Upper endoscopy performed 1 week after removal of the foreign body shows a deep indentation. (C) X-ray fluoroscopy with contrast medium injected through an endoscopic channel shows a fistula connecting to the LMB. (D) A bronchoscopic image shows mucosal redness and edema on the left side of the wall of the lower trachea and stenotic change at the orifice of the LMB. (E) A close-up bronchoscopic image of the orifice of the LMB shows a deep indentation in the thickened bronchial wall. (F) An enhanced CT image shows luminal continuity between the LMB and the esophagus. (G) The reconstructed frontal plane on CT also shows luminal continuity between the LMB and esophagus. LMB: left main bronchus; RMB: right main bronchus; CT: computed tomography

have aspiration pneumonia and received antibiotics and parenteral nutrition through a central venous catheter with nil by mouth for a month. Her symptoms did not improve on antibiotics and it became apparent that she had pain when swallowing saliva. An upper endoscopy at this time revealed a foreign body lodged in the mid-esophagus that was removed using endoscopic forceps. The foreign body was a thick $2 \text{ cm} \times 2 \text{ cm}$ piece of cake decorating paper (**Fig. 1A** and inset). A week after the procedure, endoscopy was repeated because of worsening of cough and revealed a deep indentation at the site where the foreign body had been lodged (**Fig. 1B**). A contrast agent injected through an endoscopic channel showed a fistula connecting to the left main bronchus (LMB; **Fig. 1C**). She was then diagnosed as having an EBF caused by an esophageal foreign body and transferred to our hospital for treatment.

On admission, she was afebrile and her oxygen saturation was 95% on room air. Although her performance status was 3, she was ambulatory for rehabilitation.

Laboratory data showed a C-reactive protein level of 2.5 mg/dL and an albumin level of 2.9 g/dL. Bronchoscopy revealed mucosal redness and edema on the left side of the lower trachea and narrowing of the orifice of the LMB. The fistula opened on the cephalic wall of the LMB and had a deep dimple-like appearance (**Fig. 1D** and **1E**). Computed tomography (CT) revealed the EBF to be between the mid-esophagus and the LMB. The esophagus and bronchial wall including the fistula were thickened, but the density of the surrounding fat tissue was not increased, so it was possible to distinguish the mediastinal anatomy (**Fig. 1F** and **1G**). Given that she had been receiving parenteral nutrition for more than a month beforehand, we inserted a percutaneous endoscopic gastrostomy with jejunal extension to improve her nutritional status preoperatively.

Ten days after starting enteral feeding, we closed the EBF via a left fifth intercostal thoracotomy. It was difficult to identify the fistula in the subaortic region because of inflammatory fibrotic change, so we first secured the

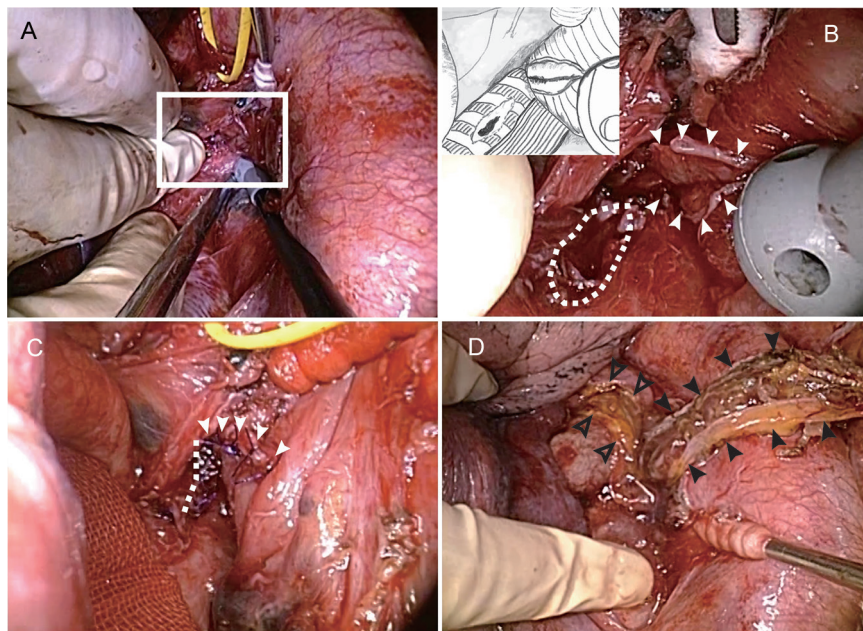


Fig. 2 Intraoperative photographs showing (A) a view of the entire surgical field and (B and C) close-up views of the area indicated by the square in (A). (B) is a close-up image of the subaortic region showing that division of the fistula resulted in esophageal (indicated as an arrowhead) and bronchial (indicated as a dotted circle) wall defects. The inset in (B) is a sketch of the identical photograph. (C) shows the repaired esophageal wall (arrowhead) and bronchial wall (dotted line). (D) shows the pedicled pericardial fat (outlined arrowheads) and intercostal muscle flap (arrowheads) covering the sutured bronchial and esophageal sites, respectively.

left recurrent laryngeal nerve to avoid accidental injury and subsequently attempted to dissect and identify the LMB and the esophagus. When we unexpectedly found the EBF on the LMB, we noticed that it was open; this facilitated recognition of its anatomy, which included an esophageal opening of the fistula, and further dissection of the mediastinum was performed. After adequate dissection of the mediastinal structures, including the left main pulmonary artery, LMB, and esophagus, we repaired the bronchial and esophageal walls with a single layer of interrupted sutures, placing five and six stitches using 4-0 PDS II (Ethicon, Inc., Somerville, NJ, USA), respectively (Fig. 2A–2C). After confirmation that the bronchial suture site was air-tight under 20 cm H₂O pressure, we covered the suture site at the esophagus with a pedicled intercostal muscle flap and the suture site at the LMB with pedicled pericardial fat and applied fibrin glue (Fig. 2D).

The patient's postoperative course was uneventful. She resumed enteral nutrition via a percutaneous endoscopic gastrostomy with jejunal extension and started swallowing training on postoperative day 1. Esophagography on

postoperative day 10 showed no leakage or obstruction, and she resumed oral intake on postoperative day 11. She was transferred to another hospital for further rehabilitation on postoperative day 21. Thirty months after her surgery, she was alive at home and attending a day-care center for seniors.

Discussion

EBF caused by an esophageal foreign body is rare. A search of the English and Japanese literature revealed only eight cases of EBF or esophagotracheal fistula attributable to an esophageal foreign body. **Table 1** summarizes the details of those cases^{1–6} as well as those of our present case. Although Mangi et al.¹ reported that benign EBF was mainly right-sided in their case series, EBF caused by a foreign body in the esophagus was observed more frequently on the left side in other reports. This would be attributable to physiologic narrowing of the esophagus. An esophageal foreign body in a healthy adult is unusual but would be more likely to occur in association with old age, a psychiatric disorder, developmental

Table 1 Reported cases of esophagobronchial and esophagotracheal fistula caused by an esophageal foreign body

Age (years), sex	Symptoms	Foreign body	Airway location	Esophageal location	Treatment	Surgical approach	Therapeutic manipulation	Postoperative course	Reference
17 M	Unknown	Wire	RM	Mt	Surgery	RTH	Division + repair	Atelectasis Transfer to rehabilitation facility on POD 43	1
89 F	Dysphagia, cough, anorexia	Fish bone	LM	Mt	Endoscopy		Fibrin glue + clipping	Uneventful Discharge to home on POD 10	2
32 M	Dysphagia, vomiting	cloth cord	TR (+LM)	Mt	Surgery	RTH + Lap	Esophagectomy + repair + omentopexy	Anastomotic leak Discharge to home at POD 103	4
56 M	Fever, anorexia	Denture	TR	Ce	Surgery	Cervical	Division + repair + musculocutaneous flap	Recurrent laryngeal nerve palsy Discharge on POD 81	5
55 M	Unknown	Denture	TR	Ut	Surgery	RTH	Division + repair	Uneventful	6
24 ?	Unknown	Denture	TR	Ut	Surgery	RTH + Lap	Esophagectomy + airway reinforcement	Not described	3
53 ?	Unknown	Denture	LM	Mt	Surgery	RTH + Lap	Esophagectomy + airway reinforcement with esophageal wall	Uneventful	3
51 ?	Unknown	Denture	TR	Ce	Surgery	RTH + Lap	Esophagectomy + airway reinforcement with esophageal wall	Not described	3
88 F	Cough, dysphagia, odynophagia	Thick paper	LM	Mt	Surgery	LTH	Division + repair	Anastomotic leak Transfer to rehabilitation hospital on POD 21	Present case

Ce: cervical esophagus; Lap: laparotomy; LM: left main bronchus; Lt: lower thoracic esophagus; LTH: left thoracotomy; Mt: middle thoracic esophagus; POD: postoperative day; RM: right main bronchus; RTH: right thoracotomy; TR: trachea; Ut: upper thoracic esophagus

delay, or alcohol intoxication.⁷⁾ Our patient was a late octogenarian but had no dementia. Accidental ingestion of the foreign body was attributable partly to her upper full denture that interfered with sensation in her mouth. She had complained of difficulty swallowing and cough at the time of her initial presentation at another hospital. Her symptoms at that time were recognized to be attributed to aspiration rather than dysphagia, leading to an initial diagnosis of aspiration pneumonia and a delay in correct diagnosis by a month. Moreover, the patient's claim that she swallowed something hard a month earlier might have been dismissed as unreliable in view of her advanced age. This case is noteworthy as it demonstrates that an incorrect diagnosis based on an initial impression may take a long time to reverse. In this patient's case, it was not until 1 month of unsuccessful antibiotic treatment had elapsed that her symptoms were finally recognized as dysphagia and odynophagia and an upper endoscopy was performed.

In our patient, the foreign body was lodged in the mid-esophagus, which would be consistent with the physiologic narrowing at that level. However, preoperative CT and endoscopy showed mild extension of the mid-esophagus. Although this was likely to be a consequence of the esophageal foreign body, it would have been impossible to rule out a wide-necked esophageal diverticulum as an etiology.

Seven of the eight cases reported in the literature were treated surgically and one was treated endoscopically.¹⁻⁶⁾ All thoracic surgical interventions were performed through a right thoracotomy, which may simply reflect the fact that many thoracic surgeons prefer to perform esophageal surgery via right thoracotomy. We agree that right thoracotomy has advantages when there is a need to manipulate the esophagus. However, in our patient, the bronchial opening of the EBF was on the cephalic wall of the LMB and located very proximal of the LMB. Anticipating that it would be difficult to perform direct closure of the fistula on the cephalic wall of the LMB via right thoracotomy, we opted for a left thoracotomy that would allow direct closure of the fistula on the esophageal and bronchial walls although the operative field was deep and narrow. Mangi et al.¹⁾ reported that 3 of their 13 cases of benign EBF were located on the LMB. In all three cases, the pathogenesis originated from an esophageal condition, such as ingestion of lye or Boerhaave syndrome, and the bronchial opening of the fistula was located on the membranous portion of the LMB. If the bronchial opening had been located on the membranous

portion of the LMB in our patient, we might have selected a right thoracotomy approach. However, a search of the literature did not reveal any reports of benign EBF with the bronchial opening on the cephalic wall of the LMB. Another reason for choosing a left thoracotomy approach in this case was that we are thoracic surgeons and mainly perform lung resections, so are familiar with the operative field involved. Although a bronchial repair at this location would be difficult regardless of whether the approach was via a right or left thoracotomy, a left thoracotomy approach in this case allowed us to perform a sealing test under direct vision. Suspecting that the bronchial cartilage adjacent to the fistula would be destroyed by inflammation, we took care to prevent further stenotic change by placing sutures with minimal bite.

A failed surgical repair would be a major cause of morbidity in patients with EBF.⁸⁾ Therefore, we covered the two suture sites using pedicled tissue flaps. Our concern that insertion of these flaps into such a narrow space might cause further stenosis proved to be unfounded on postoperative upper endoscopy and bronchoscopy.

Conclusion

Here, we have described successful surgical repair of an EBF caused by an esophageal foreign body in an elderly woman in whom a correct diagnosis was delayed. Our experience with this patient demonstrates that if an EBF opens on the cephalic wall of the LMB, a left thoracotomy could be an option for single-stage repair. This case also highlights the dangers of ignoring and/or trivializing a patient's symptoms when they are not fully compatible with the presumptive diagnosis.

Disclosure Statement

None of the authors has any conflict of interest to report.

References

- 1) Mangi AA, Gaissert HA, Wright CD, et al. Benign broncho-esophageal fistula in the adult. *Ann Thorac Surg* 2002; **73**: 911-5.
- 2) De Luca G, Griffo S, Monaco M, et al. Combined endoscopic approach in the treatment of benign broncho-oesophageal fistula. *Thorax* 2008; **63**: 1024-5.
- 3) Deshpande G, Samarasam I, Banerjee S, et al. Benign esophagorespiratory fistula: a case series and a novel technique of definitive management. *Dis Esophagus* 2013; **26**: 141-7.

- 4) Moroga T, Yamamoto S, Anami K, et al. [Surgical treatment of esophagotracheal fistula caused by esophageal foreign body]. *J Jpn Bronchoesophagol Soc* 2010; **61**: 515-20. (in Japanese)
- 5) Nakayama N, Yoshida A, Shingaki K, et al. A case of esophageal foreign body causing tracheo-esophageal fistula. *J Jpn Bronchoesophagol Soc* 1989; **40**: 488-93. (in Japanese)
- 6) Darbari A, Suryavanshi A, Tandon S, et al. Non malignant tracheo-esophageal fistula: our experience. *Indian Journal of Thoracic and Cardiovascular Surgery* 2005; **21**: 272-76.
- 7) Birk M, Bauerfeind P, Deprez PH, et al. Removal of foreign bodies in the upper gastrointestinal tract in adults: european society of gastrointestinal endoscopy (ESGE) clinical guideline. *Endoscopy* 2016; **48**: 489-96.
- 8) Shen KR, Allen MS, Cassivi SD, et al. Surgical management of acquired nonmalignant tracheoesophageal and bronchoesophageal fistulae. *Ann Thorac Surg* 2010; **90**: 914-8; discussion 919.